







Abdominal Wall Hernias Following High-intensity Focused Ultrasound Therapy: Three Case Reports

Woo Yeon Han, MD, MS¹  Yeongsong Kim, MD²  Pyeong Hwa Kim, MD, PhD³ 
Eun Key Kim, MD, PhD² 

¹ Department of Plastic Surgery, Yongin Severance Hospital, Yonsei University College of Medicine, Yongin, Korea

² Department of Plastic Surgery, Asan Medical Center, University of Ulsan College of Medicine, Seoul, Korea

³ Department of Radiology, Asan Medical Center, University of Ulsan College of Medicine, Seoul, Korea

Address for correspondence Eun Key Kim, MD, PhD, Department of Plastic Surgery, Asan Medical Center, University of Ulsan College of Medicine, 88 Olympic ro 43 gil, Songpa gu 05505, Seoul, Korea (e-mail: nicekek@korea.com).

Arch Plast Surg 2024;51:363–366.

Abstract

Although many studies reported the safety and efficacy of high-intensity focused ultrasound (HIFU) therapy, there are still worries about internal organ injury. However, reports of abdominal wall hernias after HIFU therapy are rare.

We present three cases of abdominal wall hernias without skin injury after HIFU therapy in uterine adenomyosis or fibroids. The diagnosis was often delayed because of vague symptoms, inadequate clinical suspicion, and delayed proper image studies.

Abdominal wall hernia should be recognized as a possible complication after HIFU and be suspected when the patient presents with unordinary abdominal swelling and/or pain that lasts for more than a few months after the procedure.

Keywords

- ▶ hernia
- ▶ HIFU
- ▶ uterine adenomyosis

Introduction

Uterine adenomyosis is a common gynecologic disorder affecting females of reproductive age. Increasing focus on uterine preservation and advances in technology have led to the development of minimally invasive treatment options. High-intensity focused ultrasound (HIFU) therapy uses focused ultrasonic energy for coagulative necrosis of the target area without affecting adjacent tissue. Since ultrasound-guided HIFU therapy was approved by the U.S. Food and Drug Administration in 2004, it has been widely used for clinical treatment of uterine adenomyosis.¹ Although many studies reported the safety and efficacy of HIFU therapy, there are still worries about internal organ injury. However, reports of abdominal wall hernias after HIFU therapy are rare.^{1–4} We present three cases of abdominal wall hernias without skin injury after HIFU therapy in

uterine adenomyosis or fibroids. This study was approved by the Institutional Review Board of the authors' institution (2202-0895). Informed consent has been obtained from the patient for the use of clinical photographs and medical images.

Cases

Case 1

A 51-year-old female patient visited the outpatient clinic with painful abdominal swelling lasting for 1 year. She was asymptomatic except for abdominal swelling. She was a parous woman without diabetes (BMI = 23.5 kg/m²). She had previously received HIFU therapy for the management of uterine adenomyosis 15 months ago. Abdominal pain and swelling had not subsided for a few weeks after the procedure, and magnetic resonance imaging was recommended for screening for possible complications of HIFU. The

received

May 15, 2023

accepted after revision

January 30, 2024

accepted manuscript online

February 14, 2024

DOI <https://doi.org/>

10.1055/a-2268-6986.

eISSN 2234-6171.

© 2024. The Author(s).

This is an open access article published by Thieme under the terms of the Creative Commons Attribution License, permitting unrestricted use, distribution, and reproduction so long as the original work is properly cited. (<https://creativecommons.org/licenses/by/4.0/>)

Thieme Medical Publishers, Inc., 333 Seventh Avenue, 18th Floor, New York, NY 10001, USA

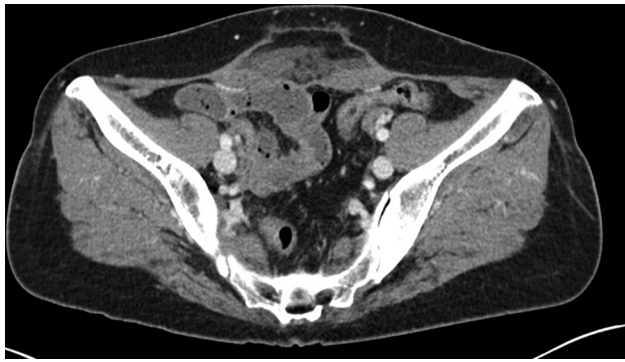


Fig. 1 Axial contrast-enhanced CT image of case 1 showing abdominal wall hernia without overlying skin injury after HIFU therapy. Rectus abdominis muscle injury, fascia rupture, and subcutaneous fluid collection were noted 1 year after HIFU. CT, computerized tomography; HIFU, high-intensity focused ultrasound.

clinician found rectus abdominis muscle injury with fascial rupture and subcutaneous fluid collection but intact skin barrier. A follow-up computerized tomography (CT) after 1 year showed no improvement in musculofascial injury and aggravated overlying subcutaneous fat necrosis and localized fluid collection (→**Fig. 1**). Patient is reluctant to undergo open surgery. Regular follow-up of her worsening symptoms is planned.

Case 2

A 54-year-old female patient visited the outpatient clinic for treatment of an abdominal wall hernia (→**Fig. 2**). She was a parous woman without diabetes (BMI = 20.6 kg/m²). She had previously received HIFU therapy for debulking a large-sized uterine fibroid 12 months ago. The patient first returned to

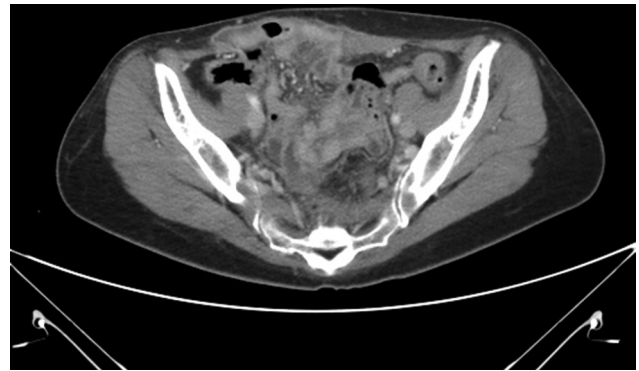

Fig. 3 Axial contrast-enhanced CT image of case 2 showing abdominal wall hernia without overlying skin injury after HIFU therapy. Abdominal wall hernia with rectus abdominis muscle atrophy was noted. CT, computerized tomography; HIFU, high-intensity focused ultrasound.

ordinary life without any obvious complications after HIFU. Four months later, she felt like something was breaking in her abdomen when lifting heavy objects. She found lower abdominal bulging and the gynecologist suspected recurrent myoma and recommended CT imaging. On the CT scan, 10-cm-sized abdominal wall hernia and rectus abdominis muscle atrophy containing small bowel loops through the right anterior aspect of the abdominal wall was found (→**Fig. 3**). Patient underwent abdominal wall reconstruction with abdominal flap elevation, musculofascial coaptation followed by acellular dermal matrix onlay graft. Deep fascia disruption with fluid collection was noted during operation. No complications or recurrence at 10 months postoperatively (→**Fig. 4**).

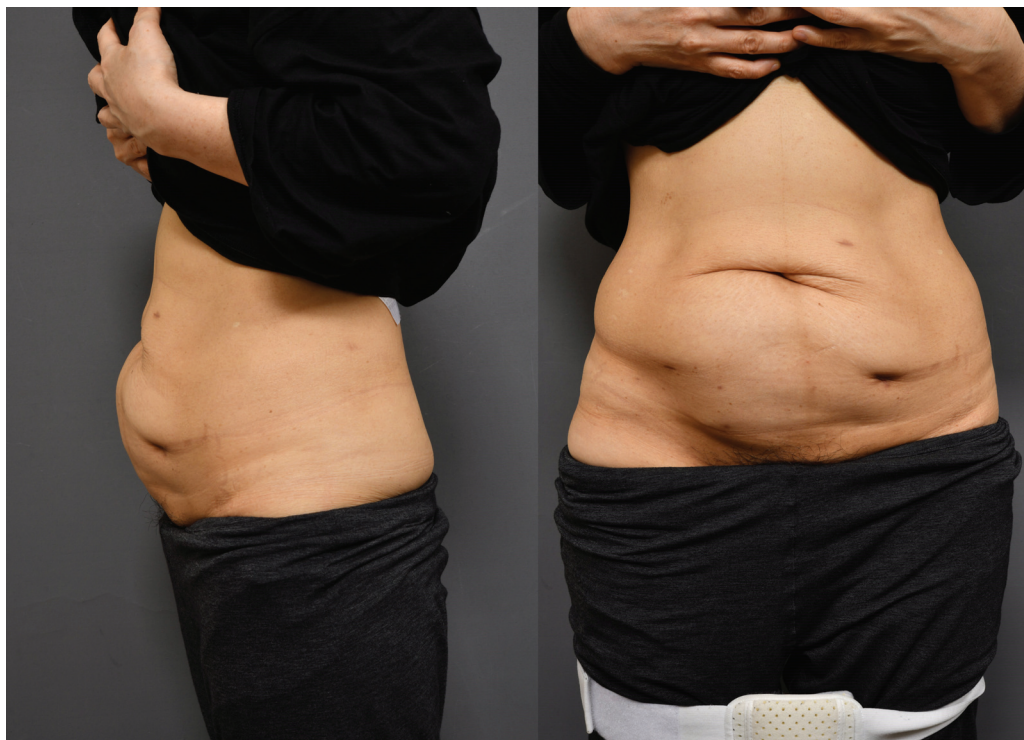

Fig. 2 Abdominal wall bulging 12 months after HIFU therapy (lateral view, anteroposterior view). HIFU, high-intensity focused ultrasound.

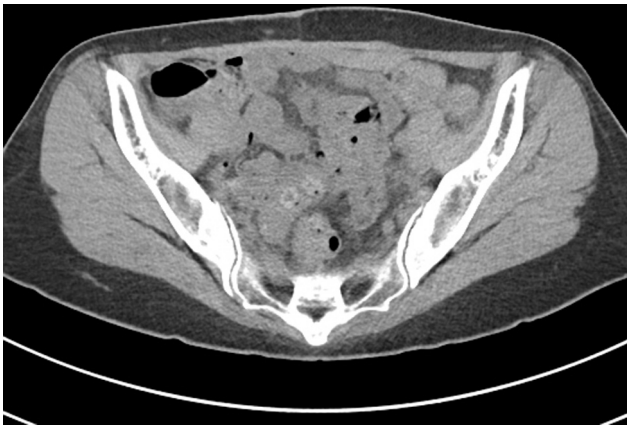

Fig. 4 Axial contrast-enhanced CT image of case 2. Postoperative 3 months. CT, computerized tomography.

Case 3

A 46-year-old female visited the outpatient clinic for fluctuation in her abdomen. She was asymptomatic, except for abdominal fluctuation with normal C-reactive protein level. She was a parous woman without diabetes (BMI = 24 kg/m²). She underwent HIFU therapy for uterine adenomyosis 2 years ago. Minor abdominal bulging developed soon after HIFU therapy, and slowly progressed thereafter. One year later, she was suffering from recurrent cellulitis on her lower abdomen, and a CT scan found subcutaneous fluid collection with 9-cm-sized rectus abdominis muscle injury. Needle aspiration and antibiotics therapy was repeatedly prescribed for symptomatic relief without any definite resolution of the situation (► Fig. 5). Patient underwent abdominal wall reconstruction with abdominal flap elevation, musculofascial coaptation followed by acellular dermal matrix onlay graft; 9 × 6 cm²-sized hernia sac and fluid collection was found during operation. No complications or recurrence at 1 year postoperatively (► Fig. 6).

Period of symptom development after HIFU, hernia diagnosis after HIFU (► Table 1) show the relative delay in the diagnosis of abdominal wall hernia after HIFU therapy in cases 1 to 3.

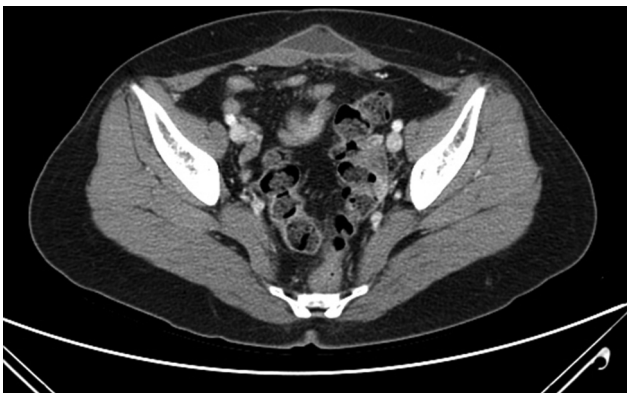

Fig. 5 Axial contrast-enhanced CT image of case 3 showing abdominal wall hernia without overlying skin injury after HIFU therapy. Rectus abdominis muscle injury and the overlying fluid collection lasted for more than 1 year in spite of repeated needle aspiration. CT, computerized tomography; HIFU, high-intensity focused ultrasound.

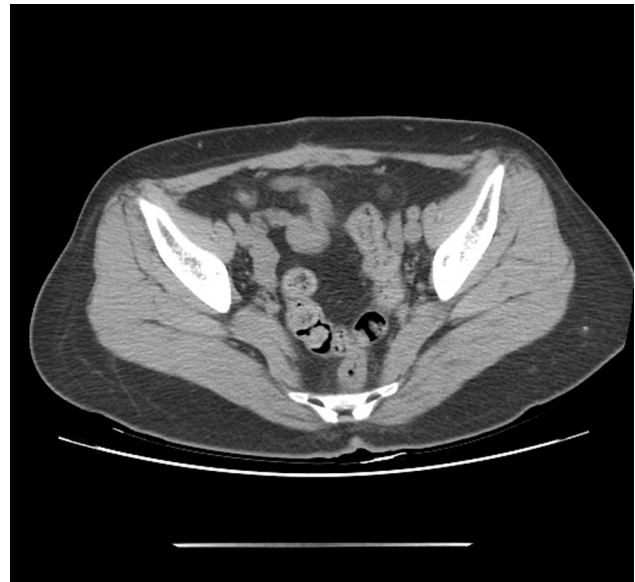


Fig. 6 Axial contrast-enhanced CT image of case 3. Postoperative 12 months. CT, computerized tomography.

Discussion

HIFU is a noninvasive therapy that uses nonionizing ultrasonic waves to heat or ablate tissue. HIFU delivers higher time intensities of ultrasound in focal regions than diagnostic ultrasound. It generates heat of over 60°C in tissues, causing coagulation necrosis and cavitation, which is the creation of a gas cavity causing disruption to cell membranes.⁵ Because of its advantages, it is used in many medical fields, including the treatment of uterine adenomyosis and fibroids.^{6,7} Several studies have reported the safety and efficacy of HIFU therapy.¹⁻⁴ Liu et al reported that ultrasound-guided HIFU significantly improves the quality of life safely and with lower cost than hysterectomy.⁸ For those reasons, HIFU therapy is now a preferred treatment option of uterine adenomyosis and fibroids.

However, previous studies have also reported complications of HIFU therapy. Chen et al reported that out of 9,998 patients, lower abdominal pain occurred in 225 patients (2.25%) within 7 days and was graded as Class A according to the Society of Interventional Radiology classification system. However, an abdominal wall hernia occurred in only one patient (0.01%) after 90 days and was graded as Class D, needing major therapy with prolonged hospitalization.²

Table 1 Period of symptom development after high-intensity focused ultrasound, hernia diagnosis after high-intensity focused ultrasound

	Symptom development after HIFU	Hernia diagnosis after HIFU
Patient 1	A few weeks	3 months
Patient 2	4 months	7 months
Patient 3	A few days	2 years

Abbreviation: HIFU, high-intensity focused ultrasound.

However, it was uncertain whether proper physical examinations and/or imaging studies were performed in all patients for evaluation of abdominal wall hernias.

During HIFU procedure, reflection of high-energy by intestinal gas or skeletal structure can cause tissue damage to adjacent tissue near target organ. However, unlike other complications, patients with abdominal wall hernias after HIFU can have deep tissue damage including abdominal muscles without realizing it, as they experience only vague symptoms such as abdominal pain or bulging but no visible skin injury. In current cases, we found that abdominal wall hernias can occur after HIFU without recognition of the abdominal wall weakening. Even worse, the patients who receive HIFU for uterine adenomyosis often have diastasis recti and subsequent abdominal bulging already, and they are used to abdominal discomfort and pain due to their previous uterine adenomyosis, all of which further delay the diagnosis of abdominal wall hernia. There is no consensus on the risk factors for abdominal wall complications following HIFU.

To the best of our knowledge, this is the first case report of abdominal wall hernia without skin injury after HIFU therapy. The diagnosis was often delayed because of vague symptoms, inadequate clinical suspicion, and delayed proper image studies. Abdominal wall hernia should be recognized as a possible complication after HIFU and be suspected when the patient presents with unordinary abdominal swelling and/or pain that last for more than a few months after the procedure.

Authors' Contributions

Study conception and design: E.K.K. Y.K.; data collection: P.H.K.; analysis and interpretation of results: P.H.K., W.Y.H., E.K.K.; draft manuscript preparation: W.Y.H., Y.K. All authors reviewed the results and approved the final version of the manuscript.

Ethical Approval

This study was approved by the Institutional Review Board of the authors' institution (2202-0895).

Patient Consent

Informed consent has been obtained from the patients for the use of clinical photographs and medical images.

Funding

None.

Conflict of Interest

E.K.K. is an editorial board member of the journal but was not involved in the peer reviewer selection, evaluation, or decision process of this article. No other potential conflicts of interest relevant to this article were reported.

References

- Cheung VY. Current status of high-intensity focused ultrasound for the management of uterine adenomyosis. *Ultrasonography* 2017;36(02):95–102
- Chen J, Chen W, Zhang L, et al. Safety of ultrasound-guided ultrasound ablation for uterine fibroids and adenomyosis: a review of 9988 cases. *Ultrason Sonochem* 2015;27:671–676
- Lee JS, Hong GY, Lee KH, Song JH, Kim TE. Safety and efficacy of ultrasound-guided high-intensity focused ultrasound treatment for uterine fibroids and adenomyosis. *Ultrasound Med Biol* 2019; 45(12):3214–3221
- Lee JS, Hong GY, Park BJ, Kim TE. Ultrasound-guided high-intensity focused ultrasound treatment for uterine fibroid & adenomyosis: a single center experience from the Republic of Korea. *Ultrason Sonochem* 2015;27:682–687
- Dubinsky TJ, Cuevas C, Dighe MK, Kolokythas O, Hwang JH. High-intensity focused ultrasound: current potential and oncologic applications. *AJR Am J Roentgenol* 2008;190(01):191–199
- Lodeizen O, de Bruin M, Eggen S, et al. Ablation energies for focal treatment of prostate cancer. *World J Urol* 2019;37(03):409–418
- Park J, Lee JS, Cho JH, Kim S. Effects of high-intensity-focused ultrasound treatment on benign uterine tumor. *J Korean Med Sci* 2016;31(08):1279–1283
- Liu XF, Huang LH, Zhang C, Huang GH, Yan LM, He J. A comparison of the cost-utility of ultrasound-guided high-intensity focused ultrasound and hysterectomy for adenomyosis: a retrospective study. *BJOG* 2017;124(Suppl 3):40–45