

ANIMAL

# Assessing the relationship between muscle-to-fat ratio in pork belly and Boston butt using magnetic resonance imaging

Sheena Kim<sup>1,†</sup>, Jeongin Choi<sup>2,†</sup>, Eun Sol Kim<sup>1</sup>, Gi Beom Keum<sup>1</sup>, Hyunok Doo<sup>1</sup>, Jinok Kwak<sup>1</sup>, Sumin Ryu<sup>1</sup>, Yejin Choi<sup>1</sup>, Juyoun Kang<sup>1</sup>, Haram Kim<sup>1</sup>, Yeongjae Chae<sup>1</sup>, Yujung Lee<sup>2</sup>, Dongjun Kim<sup>2</sup>, Kuk-Hwan Seol<sup>3</sup>, Sun Moon Kang<sup>3</sup>, Yunseok Kim<sup>4</sup>, Pil Nam Seong<sup>4</sup>, In-Seon Bae<sup>4</sup>, Soohyun Cho<sup>4</sup>, Hyo Jung Kwon<sup>2</sup>, Samooel Jung<sup>5</sup>, Youngwon Lee<sup>2,\*</sup>, Hyeun Bum Kim<sup>1,\*</sup>

<sup>1</sup>Department of Animal Biotechnology, Dankook University, Cheonan 31116, Korea

<sup>2</sup>College of Veterinary Medicine and Research Institute of Veterinary Medicine, Chungnam National University, Daejeon 34134, Korea

<sup>3</sup>Planning & Coordination Division, National Institute of Animal Science, Rural Development Administration, Wanju 55365, Korea

<sup>4</sup>Animal Products Utilization Division, National Institute of Animal Science, Rural Development Administration, Wanju 55365, Korea

<sup>5</sup>Division of Animal and Dairy Science, Chungnam National University, Daejeon 34134, Korea

<sup>†</sup>These authors equally contributed to this study as first author.

\*Corresponding authors: lywon@cnu.ac.kr, hbkim@dankook.ac.kr

## OPEN ACCESS

**Citation:** Kim S, Choi J, Kim ES, Keum GB, Doo H, Kwak J, Ryu S, Choi Y, Kang J, Kim H, Chae Y, Lee Y, Kim D, Seol KH, Kang SM, Kim Y, Seong PN, Bae IS, Cho S, Kwon HJ, Jung S, Lee Y, Kim HB. 2024. Assessing the relationship between muscle-to-fat ratio in pork belly and Boston butt using magnetic resonance imaging. Korean Journal of Agricultural Science 51:187-192. <https://doi.org/10.7744/kjoas.510209>

**Received:** March 29, 2024

**Revised:** May 03, 2024

**Accepted:** May 16, 2024

**Copyright:** © 2024 Korean Journal of Agricultural Science



This is an Open Access article distributed under the terms of the Creative Commons Attribution Non-Commercial License (<https://creativecommons.org/licenses/by-nc/4.0/>) which permits unrestricted non-commercial use, distribution, and reproduction in any medium, provided the original work is properly cited.

## Abstract

This research aimed to investigate the relationship between meat quality and muscle-to-fat ratio in specific cuts of pork (pork belly and Boston butt) utilizing magnetic resonance imaging (MRI). Twenty-eight pigs were selected, and 24 hours post-slaughter, pork belly and Boston butt samples were individually extracted from the left half carcass for MRI assessment. The MRI scans were reviewed using the Picture Archiving and Communications System. Muscle and fat volumes in the pork belly and Boston butt from the cross-sectional images captured by MRI were estimated using Vitrea workstation version 7. Subsequently, these data were processed using Vitrea post-processing software to automatically determine the volumes, measured in milliliters (mL). Additionally, a three-dimensional reconstruction of the organ being studied was generated. The relationship between regions (pork belly and Boston butt) was assessed using Pearson's correlation coefficient, and statistical analysis was conducted using Graph Pad Prism 8. The muscle-to-fat ratio determined by MRI for pork belly was 1 : 0.64, whereas for Boston butt it was 1 : 0.35. Results of comparing the muscle-fat ratio, the correlation coefficient between pork belly and Boston butt was found to be 0.6127 ( $R^2 = 0.3754$ ,  $p < 0.001$ ) based on MRI analysis. As a result of measuring the muscle-to-fat ratio using MRI as a non-destructive approach, there was a positive correlation between the muscle-to-fat ratios of pork belly and Boston butt.

**Keywords:** Boston butt, magnetic resonance imaging, muscle and fat ratio, pork belly

## Introduction

Meat quality evaluation is an important issue for consumers and producers. In particular, pork is one of the main food ingredients for Koreans, and consumers are very interested in pork quality (Kim and Kim, 2009). Recently, as the tendency to avoid meat with excessive fat has increased, the need for labeling the muscle fat content and quality of meat parts, such as pork belly and Boston butt which are preferred by consumers, is increasing (Lim, 2018). In Korea, the quality grade of pork is determined in two stages according to the grading standard of the Korea Institute for Animal Products Quality Evaluation (KAPE) (KAPE, 2018). In the first stage, warm carcass weight and back fat thickness are evaluated, while in the second stage, visual and textural characteristics such as marbling, color of meat and fat, and texture are assessed in the *longissimus dorsi* muscle exposed on the between the last rib and the first lumbar vertebra. The final decision is made based on the lower of the two evaluations (Hoa et al., 2021). Therefore, the traditional grading system based on warm carcass assessment is not suitable for evaluating the quality of unexposed meat cuts, leading to difficulties for consumers in selecting the desired meat quality for specific cuts. Adding physical dissection to confirm meat quality results in increased manpower and costs, and sometimes introduces differences in evaluation outcomes due to the subjectivity of the evaluator. (Monziols et al., 2005; Kim et al., 2021). One of the factors that determines meat quality is the ratio of muscle to fat (Monziols et al., 2006). The appropriate muscle-to-fat ratio plays an important role in determining the taste and texture of meat (Rosenvold and Andersen, 2003). Muscle contributes to improving the elasticity and quality of meat, while fat makes meat tender and delicious. Therefore, it is very important to judge meat quality by accurately assessing the ratio of muscle to fat. Recent technological advancements have introduced advanced imaging techniques such as magnetic resonance imaging (MRI) (Szabo et al., 1999; Gronemeyer et al., 2000; Baulain-Neustadt et al., 2004). MRI provides non-invasive and excellent soft tissue contrast that can quantify the muscle and fat content in specific cuts and tissues of pork. Therefore, this study aims to quantitatively assess the ratio of muscle to fat in pork using MRI (magnetic resonance imaging) technology. Research investigating the correlation between the muscle-to-fat ratio of Boston butt meat and pork belly is very meaningful. This study can provide foundational data on the muscle-to-fat ratio in each area, and enhance understanding of specific cuts that consumers prefer. We can help consumers make better choices. This research is expected to provide benefits to the meat industry and consumers.

## Materials and Methods

### Animals, slaughter, and dissection

The present study was conducted on 28 crossbred (Duroc × [Landrace × Large White]) gilt carcasses of grade 1+ with an average live weight of 115 kg. The animals were slaughtered following the standard procedures of the Korea Livestock Product Evaluation Institute at a slaughterhouse approved for the humane management and use of animals. The left half carcass was used in this study. At 24 h after slaughter, the Boston butt and pork belly were dissected from the carcass for imaging examination.

### Magnetic resonance imaging

Each of the 28 pork belly and pork neck were scanned by magnetic resonance imaging (MRI). All magnetic reso-

nance imaging examinations were performed using 1.5 Tesla magnets (Vantage Elan™; Canon Medical Systems, Japan) with an Atlas SPEEDER 1.5T body coil (Canon Medical Systems, Japan). The acquired MRI sequence was 3D T1-weighted (TR/TE = 6.2/3.2 on sagittal plane) fast field echo imaging. The scan parameters were varied for each organ. The field of view was 20 × 20 cm for pork neck, 40 × 40 cm for pork belly, with a matrix of 256 × 256 for Boston butt and 512 × 256 for pork belly. The slice thickness was the same, at 2 mm with no gap, for both organs.

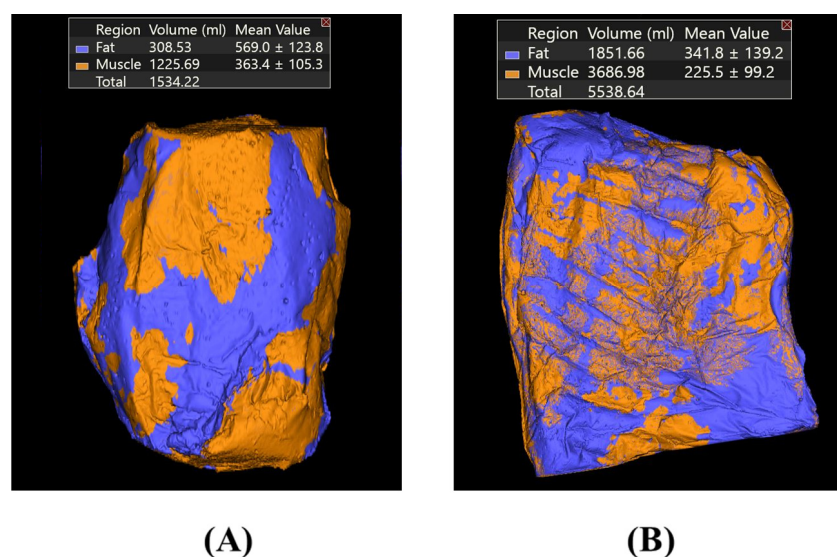
## Image & statistical analysis

The images from MRI examinations of pork belly and Boston butt were reviewed using a system called picture archiving and communications system (PACS). Using Vitrea workstation version 7 (Vital Images, USA), the muscle and fat volume of pork belly and Boston butt were estimated through cross-sectional images of MRI. Initially, manual identification of muscle and fat regions with the corresponding signal intensity on MRI exams was done. The Vitrea post-processing software helped in semi-automated detection of regions with similar signal values, with manual adjustments made as needed. Data from these regions was collected and processed to calculate volumes in milliliters (mL) through Vitrea post-processing software. Additionally, a three-dimensional reconstruction of the organ was generated for visualization. Pearson's correlation coefficient was computed to assess the association between regions (pork belly and Boston butt), and statistical analysis was conducted using GraphPad Prism 8.

## Results and Discussion

### Estimates of muscle and fat contents in the cuts

While conducting MRI scans on pork tissue (specifically the belly and Boston butt regions), the absorption rate, which is affected by fluctuations in muscle and fat density, was rendered into a three-dimensional (3D) image and depicted in Hounsfield Units (HU) through reconstruction technology, as illustrated in Fig. 1. The muscle volume of

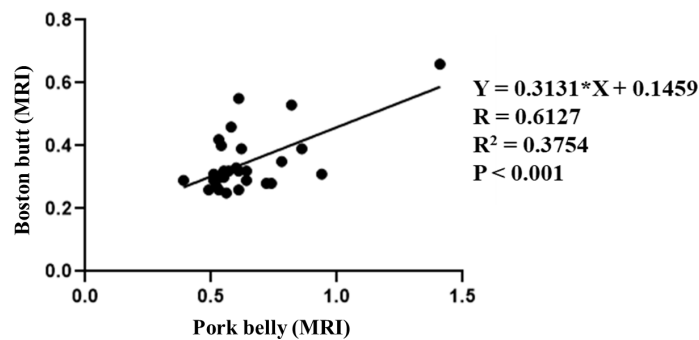


**Fig. 1.** Example of muscle and fat volume in MRI images of (A) Boston butt and (B) pork belly analyzed by Vitrea workstation version 7 (blue = fat, orange = muscle).

the dissected pork belly was measured at 2,150.7 mL, and that of the Boston butt at 1,564.1 mL. The fat content of the pork belly and Boston butt was measured at 1,351.3 mL and 538.45 mL, respectively (Table 1). Subsequent to MRI imaging and automated calculation utilizing the Vitrea workstation, the muscle-to-fat ratios for pork belly and Boston butt were determined to be 1 : 0.64 and 1 : 0.35, respectively (Table 1). Following the MRI analysis, a correlation coefficient of 0.6127 (with  $R^2 = 0.3754$  and  $p < 0.001$ ) was observed regarding the relationship between muscle-to-fat ratio in pork belly and Boston butt, as shown in Fig. 2.

**Table 1.** Muscle and fat content of pork belly and Boston butt.

Segmented volume and tissue ratios	Pork belly	Boston butt
Muscle (mL)	2,150.7	1,564.1
Total fat (mL)	1,351.3	538.45
Subcutaneous fat (mL)	855.9	261.2
Muscle : fat ratio	1 : 0.64	1 : 0.35
Total fat : subcutaneous fat ratio	1 : 0.67	1 : 0.50



**Fig. 2.** Correlation between muscle-fat ratio of pork belly and Boston butt compared through magnetic resonance imaging (MRI).

Chemical analysis and dissection are the best methods for measuring body composition, but they are time-consuming and can only be performed once on the same sample due to the loss of carcasses (Szabo et al., 1999; Monziols et al., 2005; Kloareg et al., 2006). There are several non-invasive methods for evaluating biological tissues, including MRI, CT, and ultrasound, which offer the advantage of assessing tissue composition without causing harm to the animals (Collewet et al., 2005). MRI is widely acknowledged as a powerful diagnostic tool in modern medicine (Mitchell et al., 2001), providing valuable insights into body composition for both humans (Ross et al., 2000; Goodpaster, 2002; Williams et al., 2013) and live animals (Baulain, 1997; Szabo et al., 1999; Monziols et al., 2006). In previous studies comparing tissue weight and MRI measurements, Mitchell et al. (2001) analyzed previous studies comparing tissue weight and MRI measurements and reported a range of  $R^2$  values (from 0.48 to 0.98) (Mitchell et al., 1991; Fowler et al., 1992). Monziols et al. (2005) reported that MRI was a good predictor of muscle content in cuts and carcasses, with  $R^2 = 0.970$  to  $0.997$ , while fat was somewhat less predictive. However, Fowler et al. (1992) analyzed adipose tissue from 13 areas of the pig's body and found that MRI measurements correlated with anatomy ( $R = 0.98$ ) and chemical analysis ( $R = 0.98$ ). By applying MRI in this way, it is possible to non-invasively evaluate the composition of pork parts or tissues. Recent studies have extended its usefulness to assessing animal carcass composition

(Baulain-Neustadt et al., 2004), Kremer et al. (2013) reported that MRI provides accurate information on important ‘carcass traits’ in pigs and can be used to reliably predict body composition in living organisms. However, most of these studies did not focus on the main body parts of the pig. On the other hand, Kim’s study, which used color image scanning techniques, reported muscle fat percentages of 54.17% and 48.16% in Landrace and Yorkshire breeds, respectively (Kim, 2015). In this study, the muscle-to-fat ratio of pork belly measured using MRI was found to be 64%; however, this difference may be caused by various factors such as the test subject (breed, age, etc.), imaging device, and slice interval.

There are several key considerations that must be addressed for widespread use. The presence of intramuscular fat cannot be easily excluded from MRI volume measurements, so it is included in muscle measurements (Mitchell et al., 2001), and intermuscular adipose tissue is often partially visible on MRI images as fine fatty tissue inserted between muscles (Monziols et al., 2005). Postmortem studies require caution in their approach due to the significant physico-chemical changes resulting from slaughter and post-mortem muscle water loss and fat crystallization (Monziols et al., 2005). In this study, a protocol utilizing MRI was chosen to provide optimized contrast between fat and muscle tissues, but the accuracy of volume measurements obtained through MRI primarily depends on edge detection and tissue segmentation, slice thickness, and the relationship between the total volume of the region of interest (Mitchell et al., 2001). Therefore, accurate estimation of muscle and fat content from MRI images still requires improvement.

## Conclusion

This study used MRI imaging technology to investigate the relationship between meat quality and muscle-fat composition in specific pork cuts (pork belly and Boston butt) that are not exposed during meat quality evaluation. By using MRI, it was possible to non-invasively evaluate the tissue composition of a specific area, which provided an estimate of the muscle-to-fat ratio of pork belly and Boston butt with domestic 1+ grade pork. These results are expected to provide objective data that can serve as a benchmark for predicting and grading carcass quality. Nonetheless, further comprehensive investigations are warranted to validate these findings.

## Conflict of Interests

No potential conflict of interest relevant to this article was reported.

## Acknowledgements

This work was carried out with the support of “Cooperative Research Program for Agriculture Science and Technology Development (Project No. PJ0162112024, RS-2021-RD010001)” Rural Development Administration, Republic of Korea.

## References

Baulain U. 1997. Magnetic resonance imaging for the *in vivo* determination of body composition in animal science.

- Computers and Electronics in Agriculture 17:189-203.
- Baulain-Neustadt U, Wiese M, Tholen-Bonn E, Horeth-Kulmbach R, Hoppenbrock KH. 2004. Magnetic resonance tomography as a reference technique to determine body composition in pig performance testing. *Fleischwirtschaft* 84:101-104.
- Collewet G, Bogner P, Allen P, Busk H, Dobrowolski A, Olsen E, Davenel A. 2005. Determination of the lean meat percentage of pig carcasses using magnetic resonance imaging. *Meat Science* 70:563-572.
- Fowler PA, Fuller MF, Glasbey CA, Cameron GG, Foster MA. 1992. Validation of the *in vivo* measurement of adipose tissue by magnetic resonance imaging of lean and obese pigs. *The American Journal of Clinical Nutrition* 56:7-13.
- Goodpaster BH. 2002. Measuring body fat distribution and content in humans. *Current Opinion in Clinical Nutrition and Metabolic Care* 5:481-487.
- Gronemeyer SA, Steen RG, Kauffman WM, Reddick WE, Glass JO. 2000. Fast adipose tissue (FAT) assessment by MRI. *Magnetic Resonance Imaging* 18:815-818.
- Hoa VB, Seol K, Seo H, Kang S, Kim Y, Seong P, Moon S, Kim J, Cho S. 2021. Investigation of physicochemical and sensory quality differences in pork belly and shoulder butt cuts with different quality grades. *Food Science of Animal Resources* 41:224-236.
- KAPE (Korea Institute for Animal Products Quality Evaluation). 2018. Article 35. Grading of livestock products in Livestock Industry Act. Accessed in <http://www.ekape.or.kr/index.do> on 22 May 2024.
- Kim GW, Kim SE. 2009. Analysis of the domestic consumer's preference and consumption behaviors on pork. *Journal of Animal Science and Technology* 51:81-90.
- Kim H. 2015. Shape and characteristics of Korean's favorit pork belly. *Food Science of Animal Resources and Industry* 4:30-44.
- Kim J, Han HD, Lee WY, Wakholi C, Lee J, Jeong YB, Bae JH, Cho BK. 2021. Economic analysis of the use of VCS2000 for pork carcass meat yield grading in Korea. *Animals* 11:1-16.
- Kloareg M, Noblet J, Van Milgen J. 2006. Estimation of whole body lipid mass in finishing pigs. *Animal Science* 82:241-251.
- Kremer PV, Förster M, Scholz AM. 2013. Use of magnetic resonance imaging to predict the body composition of pigs *in vivo*. *Animal* 7:879-884.
- Lim D. 2018. Effect of Carcass weight and thickness of back fat on the ratio of Intramuscular Fat in Pork Belly and Shoulder Butt. *Food Science of Animal Resources and Industry* 7:74-83.
- Mitchell AD, Elsasser TH, Wang PC. 1991. Determination of fat and water content *in vitro* and *in vivo* by proton nuclear magnetic resonance. *Journal of the Science of Food and Agriculture* 56:265-276.
- Mitchell AD, Scholz AM, Wang PC, Song H. 2001. Body composition analysis of the pig by magnetic resonance imaging. *Journal of Animal Science* 79:1800-1813.
- Monziols M, Collewet G, Bonneau M, Mariette F, Davenel A, Kouba M. 2006. Quantification of muscle, subcutaneous fat and intermuscular fat in pig carcasses and cuts by magnetic resonance imaging. *Meat Science* 72:146-154.
- Monziols M, Collewet G, Mariette F, Kouba M, Davenel A. 2005. Muscle and fat quantification in MRI gradient echo images using a partial volume detection method. Application to the characterization of pig belly tissue. *Magnetic Resonance Imaging* 23:745-755.
- Rosenvold K, Andersen HJ. 2003. Factors of significance for pork quality-a review. *Meat Science* 64:219-237.
- Ross R, Goodpaster B, Kelley D, Boada F. 2000. Magnetic resonance imaging in human body composition research. From quantitative to qualitative tissue measurement. *Annals of the New York Academy of Sciences* 904:12-17.
- Szabo C, Babinszky L, Versteegen MWA, Vangen O, Jansman AJM, Kanis E. 1999. The application of digital imaging techniques in the *in vivo* estimation of the body composition of pigs: A review. *Livestock Production Science* 60:1-11.
- Williams SE, Heemskerk AM, Welch EB, Li K, Damon BM, Park JH. 2013. Quantitative effects of inclusion of fat on muscle diffusion tensor MRI measurements. *Journal of Magnetic Resonance Imaging* 38:1292-1297.