



Prevalence and Management of Venous Rupture Following Percutaneous Transluminal Angioplasty in Dysfunctional Arteriovenous Access: A Comparative Study of Primary Patency Rates with Non-Ruptured Access Circuits

동정맥루 기능 부전에서 경피적 혈관성형술 후 발생한 정맥 파열의 유병률 및 관리: 파열되지 않은 혈관과의 일차 개통 비교 연구

Yoon Soo Park, MD¹, Seung Boo Yang, MD^{2*},
Chae Hoon Kang, MD¹, Dong Erk Goo, MD³

¹Department of Radiology, Eulji University Hospital, Daejeon, Korea

²Department of Radiology, Nowon Eulji Medical Center, Seoul, Korea

³Department of Radiology, Hangeil Radiology Clinic, Seoul, Korea

Purpose This study aims to evaluate the incidence and management of venous ruptures after percutaneous transluminal angioplasty (PTA) for dysfunctional arteriovenous (AV) access.

Materials and Methods From January 1998 to December 2015, 13506 PTA, mechanical thrombectomy, and thrombolysis procedures were performed in 6732 patients. The venous rupture rate following PTA was obtained, and access circuit primary patency (ACPP) was compared according to the etiology (PTA, thrombotic occlusion, and treatment type) of the venous rupture present.

Results Venous rupture developed in 604 of the 13506 procedures. Venous ruptures were more frequent in female, AV graft cases, and in cases accompanied by thrombosis. Balloon

Received September 18, 2023
Revised October 2, 2023
Accepted October 5, 2023
Published Online January 15, 2024

*Corresponding author
Seung Boo Yang, MD
Department of Radiology,
Nowon Eulji Medical Center,
327 Gongneung-ro, Nowon-gu,
Seoul 01830, Korea.

Tel 82-2-970-8290
Fax 82-2-970-8346
E-mail ysbysb28@gmail.com

This is an Open Access article distributed under the terms of the Creative Commons Attribution Non-Commercial License (<https://creativecommons.org/licenses/by-nc/4.0>) which permits unrestricted non-commercial use, distribution, and reproduction in any medium, provided the original work is properly cited.

tamponade was performed in 604 rupture cases, and stents were deployed in 119 cases where contrast extravasation and flow stasis persisted. ACPP was significantly better in the non-ruptured AV access circuits than in the ruptured group. However, AV access type and thrombosis was not associated with primary patency. In ruptured cases, ACPP is 8.4 months for prolonged balloon tamponade and 11.2 months for bare-metal stent insertion, showing statistically significant difference.

Conclusion Balloon tamponade and bare-metal stent placement are effective treatment for PTA-induced venous ruptures. In particular, stent placement showed a similar ACPP to that of non-ruptured AV access circuits.

Index terms Hemodialysis Access; Percutaneous Transluminal Angioplasty; Prevalence; Patency

INTRODUCTION

Venous rupture is a common complication of percutaneous transluminal angioplasty (PTA) for the treatment of arteriovenous (AV) access stenosis and thrombosis. PTA-related venous rupture has been reported to occur in 1.7%–14.9% of cases (1-7). Manual compression or balloon tamponade is initially attempted for venous rupture treatment and bare-metal stent is used if contrast extravasation with venous stasis continues afterwards (1, 2, 4-9). Some recent studies have used stent grafts to treat venous rupture (10). Balloon tamponade is a widely used method for treating PTA-induced venous rupture; however, published data determining the effectiveness of this procedure are lacking. Furthermore, in many cases, stent installation is done for reasons other than the failure of tamponade. Therefore, the factors causing primary patency after balloon tamponade remain unclear (1, 5-7, 11).

Herein, the venous rupture rates following PTA were evaluated in a relatively large number of patients, and access circuit primary patency (ACPP) was calculated according to the persistence of rupture following PTA depending on the types of treatment offered after rupture (Balloon tamponade vs. bare metal stent installation).

MATERIALS AND METHODS

PATIENT POPULATION

This retrospective study was approved by the Institutional Review Board, and the requirement for informed consent was waived (IRB No. SCHGM 2017-14).

In this study, 13506 procedures of dysfunctional AV access in 6732 patients excluding central vein stenosis and occlusion were consecutively included from January 1998 to December 2015. There were 3047 male (45%) and 3685 female (55%) patients (mean age: 58.6 years, standard deviation: 5.57). Their baseline characteristics are presented in Table 1. Of the 13506 procedures, 5875 (43.5%) were indicated for native AV fistulas, and 7631 (56.5%) were for prosthetic AV grafts. Stenosis was identified in 9797 cases (72.5%), and thrombotic occlusion was present in 3709 cases (27.5%). Treatment methods included simple PTA ($n = 9782$), PTA with mechanical thrombectomy ($n = 3617$), and catheter-directed thrombolysis using urokinase ($n = 107$). Graft-to-vein anastomosis was the most common stenotic site (49.4%), fol-

Table 1. Baseline Patient Characteristics

Characteristic	
Patients	6732
Male/female	3407 (45.3)/3685 (54.7)
Age (years)	58.60 ± 12.84
Hemodialysis duration (years)	6.12 ± 5.57
Vascular access age (months)	34.32 ± 39.35
Cause of chronic renal failure	
Diabetes mellitus	2904 (46)
Hypertension	1750 (26)
Glomerulonephritis	147 (2.2)
Others	1931 (25.8)
Arteriovenous fistula/arteriovenous graft	3509 (52.1)/3223 (47.9)
Right/left	1592 (23.6)/5140 (47.9)

Data are presented as mean ± standard deviation or *n* (%).

Table 2. Location of Stenosis

Location	<i>n</i> (%)
Artery	39 (0.3)
Arterial anastomosis	329 (2.4)
Venous anastomosis	6670 (49.4)
Swing point	1252 (9.3)
Distal cephalic vein	1732 (12.8)
Proximal cephalic vein	825 (6.1)
Cephalic arch	481 (3.6)
Basilic vein	587 (4.3)
Brachial vein	148 (1.1)
Femoral vein	5 (0.0)
Intra-graft	615 (4.6)
Vein to vein anastomosis	710 (5.3)
Cubital vein	77 (0.6)
Others	36 (0.3)

lowed by the distal cephalic vein (12.8%) and swing point of AV (Table 2).

TECHNIQUES

Physical examinations and Doppler US were performed to confirm the presence of thrombosis. In the absence of a thrombus, the location and extent of stenosis was assessed using diagnostic fistulography. PTA was performed when > 50% stenosis was observed on the fistulography. We used 6–8 Fr sheaths to correspond to the balloon catheter (Boston, Marlborough, MA, USA) size, which was 10%–20% larger than the adjacent normal vein. The length of the balloon was between 2–8 cm, averaging 4 cm. A wire was placed in the stenotic portion and the balloon catheter was slowly inflated using an inflation device until the waist disappeared. The balloon inflation pressure was usually 15–25 atm and the inflation time was 60 s. To con-

firm recoil or rupture after PTA, a guidewire was left in the lesion and an angiogram was obtained. If calcified intimal hyperplasia and elastic recoil lesions did not respond to PTA, a high-pressure balloon (Boston) was applied at a rate (> 30 atm) for 2–3 minutes of inflation. Occasionally, cutting balloons (Boston) were used when high-pressure balloons were ineffective; all cutting balloons were 1 mm smaller than the previously inflated balloons.

THROMBECTOMY AND THROMBOLYSIS

No diagnostic fistulography was performed for thrombosed access. Physical examination and Doppler US were used to confirm the location and extent of the thrombus, and a thrombotic graft or fistula was punctured using a micropuncture set (Cook, Bloomington, IN, USA). The apex puncture technique was used for thrombotic U graft and the cross-catheter technique was used for straight grafts and fistulas. In most patients, aspiration thrombectomy was performed using a Desilets-Hoffman sheath (Cook), while urokinase thrombolysis was done in cases of thrombotic occlusion of graft. Aspiration thrombectomy was performed as follows: first, a thrombotic graft or fistula was punctured using a micropuncture set and the Desilets-Hoffman sheath was advanced into the venous limb or draining vein. A 10-mL syringe was then connected to the rear end of the sheath, and the Desilets-Hoffman sheath was slowly withdrawn by thromboaspiration with constant manual suction. After injecting a small amount of contrast agent, the sheath was moved back and forth to aspirate the thrombi in the graft or vein; this was repeated several times. Aspiration was repeated until the thrombus could no longer be aspirated, and angioplasty was performed on the remaining stenosis of the outflow vein. Arterial limb or vein thrombus adjacent to the anastomotic site was removed in the same manner. After aspiration thrombectomy, a residual arterial plug or adherent thrombus was pulled back into the graft or vein using a 5-F Fogarty balloon catheter (Baxter, Santa Ana, CA, USA) and crushed using an angioplasty balloon. Routinely, 5000 IU of heparin was administered prior to thrombotic access. Urokinase thrombolysis was performed using urokinase 100000 U and heparin 5000 U. The remaining thrombus was subjected to aspiration thrombectomy, and PTA was performed for outflow stenosis.

TREATMENT OF VENOUS RUPTURE AFTER PTA

Venous rupture was defined as contrast extravasation causing flow stasis of AV access at the balloon angioplasty area during fistulography. If a venous rupture was detected, the balloon is re-inserted at the rupture site and inflated at low pressure for 3–5 minutes. If contrast extravasation and flow disturbance remained despite prolonged balloon tamponade, a bare-metal stent was placed. Size of bare-metal stent was determined based on size of balloon catheter.

DEFINITION AND STATISTICAL ANALYSIS

ACPP was defined as the interval between index intervention until one of the following events: access thrombosis, or any intervention to maintain or reestablish patency, according to the reporting standards and quality improvement guidelines of the Society of Interventional Radiology (12). Primary patency was compared and analyzed according to AV access type (i.e., graft or fistula), presence of thrombus, and treatment type (i.e., stent or balloon

tamponade). The primary patency in the AV graft vs. AV fistula groups, presence or not of a thrombus, and treatment type were also determined when a rupture was present. The X^2 test was used to analyze differences between categorical variables for rupture occurrence. Kaplan-Meier survival analysis was used to evaluate access patency. The Log-rank test was used to compare patency between variables over time, with a significance level of $p < 0.05$. All statistical analyses were performed using SPSS (version 14.0, Chicago, IL, USA).

RESULTS

Venous rupture developed in 604 of the 13506 procedures (4.5%) (Fig. 1). Venous ruptures following PTA were more frequent in female and in cases of AV graft, thrombosis, and with the thrombolysis technique as the treatment method (Table 3). In the AV fistula group, venous rupture occurred in 230 of the 5875 procedures (3.9%). Females (4.7% vs. 3.1% in males; $p = 0.002$), thrombosis (9.8% vs. 3.6% in stenosis; $p = 0.001$), and thrombolysis technique (20% vs. 3.6% in simple PTA vs. 9.2% in aspiration thrombectomy; $p = 0.001$) were the significant variables. In the AV graft group, venous rupture occurred in 374 of 7631 procedures (4.9%). Fe-

Fig. 1. A 67-year-old male with venous rupture following balloon angioplasty.
A. Postprocedural fistulography shows contrast leakage in balloon angioplasty site of cephalic vein.
B. Balloon tamponade was performed for 5 minutes.
C. Post-balloon tamponade fistulography shows a cephalic vein without contrast leakage.

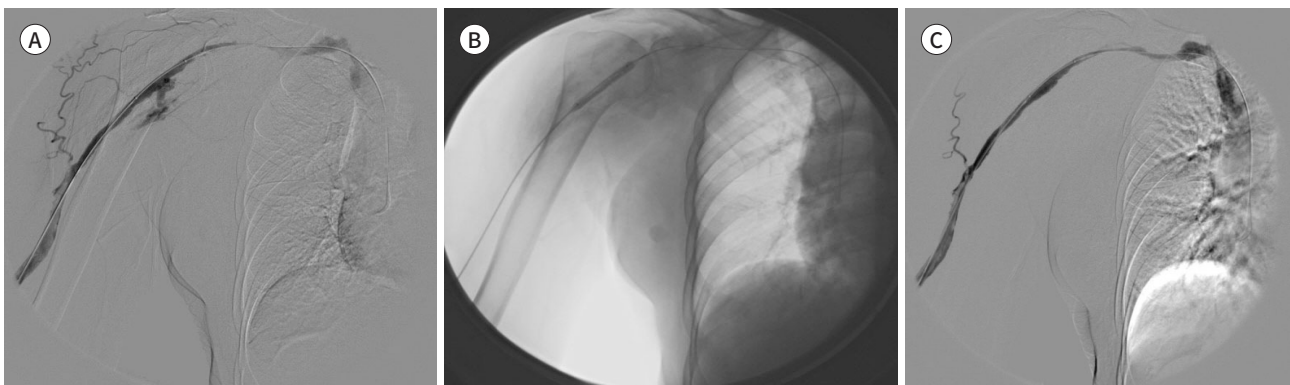


Table 3. Venous Rupture Following Percutaneous Transluminal Angioplasty

Characteristic	n (%)	p-Value
Venous rupture	604 (4.5)	
Male/female	200 (3.6)/404 (5.1)	0.001
Right/left	133 (4.1)/471 (4.6)	0.197
AVF/AVG	230 (3.9)/374 (4.9)	0.006
Stenosis/thrombus	318 (3.3)/286 (7.7)	0.001
Treatment methods		0.001
Only PTA	317 (3.2)	
Aspiration thrombectomy	277 (7.7)	
Thrombolysis technique	10 (9.4)	

AVF = arteriovenous fistula, AVG = arteriovenous graft, PTA = percutaneous transluminal angioplasty

males (5.3% vs. 4.1% in males; $p = 0.015$), thrombosis (7.5% vs. 2.8% in stenosis; $p = 0.001$), and aspiration thrombectomy (7.5% vs. 2.8% in simple PTA vs. 6.9% in thrombolysis; $p = 0.001$) were the identical variables significant here too. Balloon tamponade was performed in 604 rupture cases, and stents were deployed in 119 cases where contrast extravasation and flow stasis persisted. The ACPP was significantly better in the non-ruptured AV access circuits than in the ruptured AV access circuits (11.0 vs. 8.9 months; $p = 0.001$). However, access type ($p = 0.372$) and presence or absence of thrombus ($p = 0.358$) did not significantly differ in terms of patency time. The ACPP in the stent group was significantly better than that in the balloon tamponade group in patients with rupture (11.2 vs. 8.4 months; $p = 0.014$). In the ruptured AV fistula group, ACPP was not significantly different between the stenosis and thrombus groups ($p = 0.305$) or between the balloon tamponade and stent placement groups ($p = 0.185$). The ACPP was 8.1 months in the balloon tamponade group and 10.4 months in the stent tamponade group ($p = 0.040$), thus duration of primary patency was statistically significant when comparing the balloon to the stent groups. However, no significant difference in patency duration was observed between the stenosis and thrombus groups ($p = 0.975$).

DISCUSSION

PTA-induced venous rupture is a relatively common complication, with an incidence of 1.7%–14.9% (1-7). The mean rupture rate in our study was 4.5% being higher in female, AV graft cases, cases of thrombosis, and cases utilizing urokinase thrombolysis techniques. The rupture rate in the presence of thrombosis was 7.7%, which was higher than that in its absence. Raynaud et al. (1) reported a rupture rate of 1.7% in a study of 2414 PTA, of which thrombosed access occurred in 289/2414 (12%) of cases. According to Turmel-Rodrigues et al. (4), who reported a relatively high rupture rate, the rate of the declotting procedure was 257/1118 (23%). However, the rupture rates of stenosis and thrombus were not compared in either study. We believe that the use of routine heparin for thrombosis access, the effect of urokinase in some patients, and the frequent use of balloon catheters in thrombectomy procedures might have been related to this finding. AV graft had a 4.9% higher rupture rate than that associated with AV fistula (3.9%). However, Turmel-Rodrigues et al. (4) reported rupture rates of 8.3% in forearm AV fistula and 14.9% in upper-arm AV fistula, while the AV graft rupture rate was 3.8%. Kornfield et al. (13) reported rupture rates of 5.6% and 2.8% in fistulas and grafts, respectively. In these two studies, AV fistula had a higher rupture rate than AV graft, contrary to our studies. The difference in the study of Turmel-Rodrigues et al. (4) was thought to be due to the large proportion of thrombotic occlusion in the AV fistula, whereas in the study of Kornfield et al. (13), only stenosis was targeted.

Several treatment tools are available for venous rupture, including manual compression, prolonged balloon tamponade, use of bare stents, and stent graft installation. The Primary treatment of venous rupture is usually a low-pressure balloon tamponade, but continued bleeding in 119 cases in our study required insertion of the bare metal stent. Primary patency in the ruptured cases was slightly lower than in the non-ruptured cases with balloon tamponade. And it also showed relatively good and similar patency in cases with stent.

This study has several limitations. First, there was no analysis of the secondary patency fol-

lowing the treatment. Further studies are needed to confirm the accuracy of this study. Second, we need to confirm any complications following the installation of stent.

In conclusion, balloon tamponade and bare-metal stent placement are treatment methods for PTA-induced venous ruptures. In particular, stent placement showed a similar ACPP to that of the non-rupture group.

Availability of Data and Material

The datasets generated or analyzed during the study are available from the corresponding author on reasonable request.

Author Contributions

Conceptualization, Y.S.B.; data curation, P.Y.S., Y.S.B.; formal analysis, P.Y.S., K.C.H.; methodology, Y.S.B., G.D.E.; supervision, Y.S.B., K.C.H.; writing—original draft, P.Y.S.; and writing—review & editing, Y.S.B., K.C.H., G.D.E.

Conflicts of Interest

The authors have no potential conflicts of interest to disclose.

ORCID iDs

Yoon Soo Park  <https://orcid.org/0000-0001-5158-9220>
Seung Boo Yang  <https://orcid.org/0000-0003-3350-2704>
Chae Hoon Kang  <https://orcid.org/0000-0002-3714-0467>
Dong Erk Goo  <https://orcid.org/0000-0003-1042-8265>

Funding

None

REFERENCES

1. Raynaud AC, Angel CY, Sapoval MR, Beyssen B, Pagny JY, Auguste M. Treatment of hemodialysis access rupture during PTA with Wallstent implantation. *J Vasc Interv Radiol* 1998;9:437-442
2. Pappas JN, Vesely TM. Vascular rupture during angioplasty of hemodialysis raft-related stenoses. *J Vasc Access* 2002;3:120-126
3. Beathard GA. Percutaneous transvenous angioplasty in the treatment of vascular access stenosis. *Kidney Int* 1992;42:1390-1397
4. Turmel-Rodrigues L, Pengloan J, Baudin S, Testou D, Abaza M, Dahdah G, et al. Treatment of stenosis and thrombosis in haemodialysis fistulas and grafts by interventional radiology. *Nephrol Dial Transplant* 2000; 15:2029-2036
5. Funaki B, Szymiski GX, Leef JA, Rosenblum JD, Burke R, Hackworth CA. Wallstent deployment to salvage dialysis graft thrombolysis complicated by venous rupture: early and intermediate results. *AJR Am J Roentgenol* 1997;169:1435-1437
6. Rundback JH, Leonardo RF, Poplasky MR, Rozenblit G. Venous rupture complicating hemodialysis access angioplasty: percutaneous treatment and outcomes in seven patients. *AJR Am J Roentgenol* 1998;171: 1081-1084
7. Welber A, Schur I, Sofocleous CT, Cooper SG, Patel RI, Peck SH. Endovascular stent placement for angioplasty-induced venous rupture related to the treatment of hemodialysis grafts. *J Vasc Interv Radiol* 1999;10:547-551
8. Kim DH, Goo DE, Yang SB, Moon C, Choi DL. Endovascular management of immediate procedure-related complications of failed hemodialysis access recanalization. *Korean J Radiol* 2005;6:185-195
9. Vesely TM. Role of stents and stent grafts in management of hemodialysis access complications. *Semin Vasc Surg* 2007;20:175-183

10. Dale JD, Dolmatch BL, Duch JM, Winder R, Davidson IJ. Expanded polytetrafluoroethylene-covered stent treatment of angioplasty-related extravasation during hemodialysis access intervention: technical and 180-day patency. *J Vasc Interv Radiol* 2010;21:322-326
11. Rajan DK, Clark TW. Patency of Wallstents placed at the venous anastomosis of dialysis grafts for salvage of angioplasty-induced rupture. *Cardiovasc Intervent Radiol* 2003;26:242-245
12. Gray RJ, Sacks D, Martin LG, Trerotola SO; Society of Interventional Radiology Technology Assessment Committee. Reporting standards for percutaneous interventions in dialysis access. *J Vasc Interv Radiol* 2003;14(9 Pt 2):S433-S442
13. Kornfield ZN, Kwak A, Soulen MC, Patel AA, Kobrin SM, Cohen RM, et al. Incidence and management of percutaneous transluminal angioplasty-induced venous rupture in the "fistula first" era. *J Vasc Interv Radiol* 2009;20:744-751

동정맥루 기능 부전에서 경피적 혈관성형술 후 발생한 정맥 파열의 유병률 및 관리: 파열되지 않은 혈관과의 일차 개통 비교 연구

박윤수¹ · 양승부^{2*} · 강채훈¹ · 구동역³

목적 본 연구는 기능 부전의 동정맥루에 대한 경피적 혈관성형술 후 발생한 정맥 파열의 유병률 및 관리에 대하여 다루고자 하였다.

대상과 방법 1998년 1월부터 2015년 12월까지, 6732명의 환자(여성 3685명, 남성 3047명, 평균 나이 58.60 ± 12.84세; 평균 혈액투석 접근 시기: 34.32 ± 39.35개월)에 대하여 시행된 13506건의 경피적 혈관성형술, 기계적 혈전제거술, 그리고 혈전용해술이 검토되었다. 경피적 혈관성형술 후 정맥 혈관이 파열된 비율을 확인하였고 일차 개통은 시술 후 정맥 혈관의 파열된 상태, 혈전의 존재 유무, 치료 방법에 따라 결정되었다.

결과 정맥 파열은 13506건의 시술 중 604건에서 발생했다. 정맥 혈관 파열은 여성, 동정맥 이식, 그리고 혈전이 동반되었을 경우 호발하였다. 풍선 탐포네이드는 604건의 파열 사례에서 시행되었고 스텐트 시술은 조영제 유출과 혈류 정체는 지속되었을 때, 119건에서 시행되었다. 일차 개통은 파열군보다 비파열군에서 더 우수하게 나타났다. 그러나, 접근 유형과 혈전의 존재 유무는 개통 측면에서 유의한 차이가 없었다. 파열 환자의 일차 개통 시간은 지속적인 풍선 탐포네이드 후 8.4개월 이었고 스텐트 시술 후 11.2개월이었다.

결론 풍선 탐포네이드와 비파열형 스텐트 설치의 경피적 혈관성형술 관련 정맥 파열에서 적용될 수 있는 치료 방법이다. 특히, 스텐트 설치의 비파열군과 유사한 개통 시간을 보여주었다.

¹울지대학교병원 영상의학과,

²노원울지대학교병원 영상의학과,

³한길영상의학과의원 영상의학과