

Long-term follow-up of patients developing gastric mucosal lesions after initiating the potassium-competitive acid blocker vonoprazan

Kimitoshi Kubo¹, Noriko Kimura²

Departments of ¹Gastroenterology and ²Pathology, National Hospital Organization Hakodate National Hospital, Hakodate, Japan

Vonoprazan has recently been developed and approved for clinical use in Japan¹ as a drug of the potassium-competitive acid blocker (P-CAB) class reported to reversibly inhibit gastric acid output through K⁺-competitive ionic binding to H⁺/K⁺-ATPase.² Vonoprazan has been shown to selectively accumulate in gastric parietal cells in the mucosal layer of the rat stomach,³ and gastric cracked mucosa (GCM), redness, white spots (WS), and gastric polyps (GP) have been reported as P-CAB-associated gastric mucosal lesions.⁴⁻¹⁰ However, only a few cases have demonstrated a causal relationship between vonoprazan and gastric mucosal lesions through long-term follow-up from before drug initiation to after its discontinuation.^{5,6} We herein report two cases in which GCM, WS, and GP newly appeared after the initiation of vonoprazan treatment and were followed up after switching to proton pump inhibitors (PPIs).

The study protocol was reviewed and approved by the Institutional Review Board of the National Hospital Organization Hakodate National Hospital (approval number: R5-0105001). Written informed consent was obtained from the patients for the publication of this brief report and accompanying images.

Case 1. A 67-year-old woman had taken vonoprazan (20 mg) once daily for gastroesophageal reflux disease (GERD).

Esophagogastroduodenoscopy (EGD) performed before the initiation of vonoprazan treatment demonstrated atrophic mucosal changes in the gastric antrum due to past *Helicobacter pylori* infection, although no atrophic or mucosal changes were noted in the gastric body (Fig. 1A, B). EGD performed 1 and 2 years later demonstrated newly appearing GCM (Fig. 1C–E) and multiple WS and GP in the greater curvature of the lower gastric body on white-light imaging (WLI) (Fig. 1F), respectively. To provide further evidence, texture and color enhancement imaging (TXI) mode 1 and narrow-band imaging (NBI) highlighted the GCM, WS, and GP observed on close-up WLI (Fig. 1G–I). Furthermore, magnifying endoscopy with NBI (M-NBI) revealed WS to be rich in microscopic vessels on the mucosal surface (Fig. 1J). Repeated EGD performed 1 year after switching from vonoprazan to esomeprazole (20 mg) demonstrated no change in GCM, although the WS disappeared and the GP size decreased (Fig. 1K, L).

Case 2. An 81-year-old man had taken vonoprazan (20 mg) once daily for GERD. The patient had no history of *H. pylori* infection and tested negative for serum immunoglobulin G antibodies against *H. pylori*. EGD performed before the initiation of vonoprazan treatment revealed normal gastric mucosa, with no atrophic or mucosal changes in the gastric body (Fig. 2A). EGD performed 2 and 4 years later demonstrated newly appearing GCM and GP (Fig. 2B) and enlarged GP and newly appearing multiple WS in the greater curvature of the lower gastric body on WLI (Fig. 2C, D), respectively. GCM and WS observed on close-up WLI (Fig. 2E) were highlighted in both TXI mode 1 and NBI (Fig. 2F, G). M-NBI revealed the WS to be rich in microscopic vessels on the mucosal surface (Fig. 2H),

Received: July 20, 2023 Revised: August 4, 2023 Accepted: August 5, 2023

Correspondence: Kimitoshi Kubo

Department of Gastroenterology, National Hospital Organization Hakodate National Hospital, Hakodate, 18-16 Kawahara-cho, 041-8512 Hokkaido, Japan.

E-mail: kubotti25@yahoo.co.jp

© This is an Open Access article distributed under the terms of the Creative Commons Attribution Non-Commercial License (<https://creativecommons.org/licenses/by-nc/4.0/>) which permits unrestricted non-commercial use, distribution, and reproduction in any medium, provided the original work is properly cited.

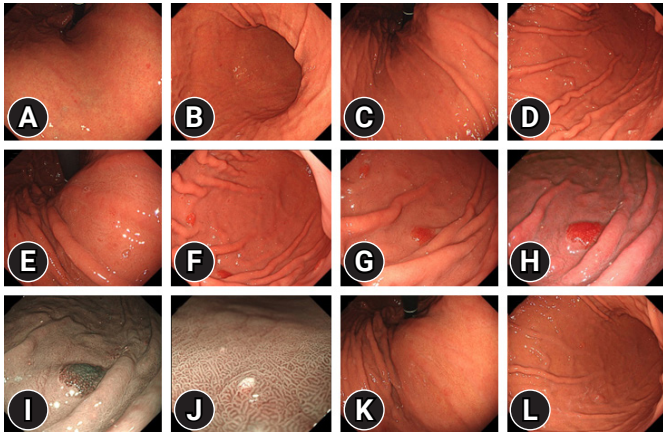


Fig. 1. Esophagogastroduodenoscopy (EGD). Case 1. EGD performed before initiation of vonoprazan treatment reveals an atrophic change in the antrum owing to past *Helicobacter pylori* infection, although no atrophic or mucosal changes are noted in the gastric body (A, B). EGD performed 1 and 2 years after initiation of vonoprazan treatment demonstrates newly appearing gastric cracked mucosa (GCM) (C–E) and multiple white spot (WS) and gastric polyps (GP) in the greater curvature of the lower gastric body on white-light imaging (WLI) (F), respectively. The GCM, WS, and GP observed on close-up WLI (G) are each highlighted as such on texture and color enhancement imaging mode 1 and narrow-band imaging (NBI) (H, I), respectively. Magnifying endoscopy with NBI indicates WS to be rich in microscopic vessels on the mucosal surface (J). Repeated EGD performed 1 year after switching from vonoprazan to esomeprazole demonstrates no change in GCM except for the disappearance of the WS and reduction of the GP size (K, L).

and repeated EGD performed 1 year after switching from vonoprazan to esomeprazole (20 mg) demonstrated no change in GCM except for the disappearance of WS and a slight reduction in GP size (Fig. 2I, J).

In each case, a tissue biopsy from WS revealed a mucus pool within a dilated duct that tested positive for Alcian-periodic acid-Schiff staining (Case 1, Fig. 3A, B; Case 2, Fig. 3C, D).

Our findings have important implications for clinical practice. Long-term follow-up after the initiation of vonoprazan revealed that GCM, WS, and GP newly appeared as P-CAB-associated gastric mucosal lesions, and that switching from vonoprazan to PPI led to clear changes in WS and GP, that is, their disappearance or reduction.

Nishiyama et al.⁷ characterized a white hemispheric protrusion observed during WLI as WS, whose surface is rich in microscopic vessels on M-NBI, thus reporting WS as a vonoprazan-associated gastric lesion. Additionally, Yoshizaki et al.⁸ have reported that WS (which they defined as “stardust gastric

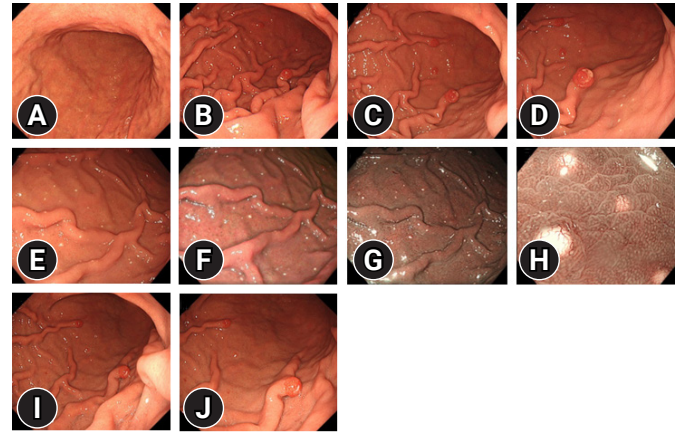


Fig. 2. Esophagogastroduodenoscopy (EGD). Case 2. EGD performed before initiation of vonoprazan treatment reveals a normal gastric mucosa with no atrophic or mucosal changes in the gastric body (A). EGD performed 2 years after vonoprazan initiation demonstrates newly appearing gastric cracked mucosa (GCM) and gastric polyps (GP) (B), and EGD performed 4 years later demonstrates enlarged GP and newly appearing multiple white spot (WS) in the greater curvature of the lower gastric body on white-light imaging (WLI) (C, D). The GCM and WS observed on close-up WLI (E) are highlighted on texture and color enhancement imaging mode 1 and narrow-band imaging (NBI) (F, G), respectively. Magnifying endoscopy with NBI indicates the WS to be rich in microscopic vessels on the mucosal surface (H). Repeat EGD performed 1 year after switching from vonoprazan to esomeprazole reveals no change in the GCM except for the disappearance of the WS and a slight decrease in the size of the GP (I, J).

mucosa”) is endoscopically characterized as small white protrusions in the upper and middle parts of the stomach not amenable to elimination by washing and are histologically characterized as a mucus pool located within a dilated duct. Similarly, in this study, white hemispheric protrusions were shown to be present in the gastric body on WLI and image-enhanced endoscopy (TXI and NBI), which was later confirmed as such by a multidisciplinary diagnosis combining M-NBI and pathological findings. Thus, although gastrin levels were not measured in this study, vonoprazan-induced hypergastrinemia may have led to the dilation of the fundic glands and delayed or blocked mucus release, which likely accounted for the pathogenesis of WS.^{7,8} However, at present, the exact mechanisms involved remain unclear.

Although PPI-associated GP are well documented, reports on P-CAB-associated GP are few. Iwamuro et al.⁹ have reported a case in which hyperplastic and fundic gland polyps regressed after vonoprazan cessation. Subsequently, Goto et al.¹⁰ have

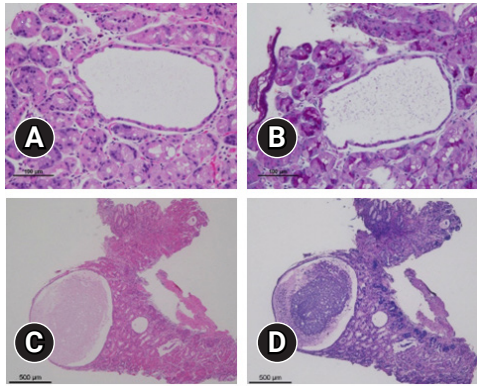


Fig. 3. Pathological findings. A tissue biopsy from white spots reveals a mucus pool within a dilated duct, which tested positive for Alcian-periodic acid-Schiff staining. (A, B) Case 1, scale bar: 100 µm. (C, D) Case 2, scale bar: 500 µm.

reported another case in which replacement of vonoprazan with a histamine-2 receptor blocker led not only to shrinkage of the hyperplastic polyps involved, but also to an improvement of anemia. In both cases, the causal relationship between vonoprazan and the appearance of GP was unclear; however, the long-term follow-up of two cases in this study revealed that initiation of vonoprazan treatment led to the emergence of new GP (i.e., hyperplastic polyps). Further research involving pathological examinations is required to determine whether P-CAB-associated GP share the same mechanism of onset as those associated with PPIs.

The novelty of this report is that the long-term follow-up captured the appearance of GCM, WS, and GP after the initiation of P-CAB treatment, as well as changes in the mucosal lesions after switching to PPI in two patients. Further follow-up is required to determine if any further changes may occur in the morphology of GCM and GP over time.

Conflicts of Interest

The authors have no potential conflicts of interest.

Funding

None.

Author Contributions

Conceptualization: KK; Data curation: all authors; Formal analysis: all authors; Investigation: all authors; Methodology: all authors; Project administration: KK; Resources: all authors; Su-

pervision: all authors; Validation: all authors; Visualization: all authors; Writing-original draft: KK; Writing-review & editing: all authors.

ORCID

Kimitoshi Kubo

<https://orcid.org/0000-0002-1424-1011>

Noriko Kimura

<https://orcid.org/0000-0001-8160-3687>

REFERENCES

1. Arikawa Y, Nishida H, Kurasawa O, et al. Discovery of a novel pyrrole derivative 1-[5-(2-fluorophenyl)-1-(pyridin-3-ylsulfonyl)-1H-pyrrol-3-yl]-N-methylmethanamine fumarate (TAK-438) as a potassium-competitive acid blocker (P-CAB). *J Med Chem* 2012; 55:4446–4456.
2. Parsons ME, Keeling DJ. Novel approaches to the pharmacological blockade of gastric acid secretion. *Expert Opin Investig Drugs* 2005;14:411–421.
3. Matsukawa J, Kogame A, Tagawa Y, et al. Radiographic localization study of a novel potassium-competitive acid blocker, vonoprazan, in the rat gastric mucosa. *Dig Dis Sci* 2016;61:1888–1894.
4. Miyamoto S, Matsuno Y, Kato M, et al. Parietal cell protrusions and dilated oxyntic glands from use of vonoprazan. *Am J Gastroenterol* 2017;112:1899–1901.
5. Kubo K, Kimura N, Matsuda S, et al. Vonoprazan-associated gastric mucosal redness: a report of four cases. *Intern Med* 2020;59:507–511.
6. Kubo K, Kimura N, Watanabe R, et al. Vonoprazan-associated gastric mucosal redness in non-*Helicobacter pylori*-infected and *Helicobacter pylori*-eradicated stomach. *Case Rep Gastroenterol* 2021;15:751–758.
7. Nishiyama N, Kobara H, Ayaki M, et al. White spot, a novel endoscopic finding, may be associated with acid-suppressing agents and hypergastrinemia. *J Clin Med* 2021;10:2625.
8. Yoshizaki T, Morisawa T, Fujinami M, et al. Propensity score matching analysis: incidence and risk factors for "stardust" gastric mucosa, a novel gastric finding potentially induced by vonoprazan. *Aliment Pharmacol Ther* 2021;53:94–102.
9. Iwamuro M, Shiraha H, Okada H. Gastric polyps' regression after potassium-competitive acid blocker cessation. *J Gen Fam Med* 2022;23:358–359.
10. Goto C, Okimoto K, Matsusaka K, et al. Long-term vonoprazan administration causes gastric fundic gland-type hyperplastic polyps and chronic bleeding. *Clin J Gastroenterol* 2023;16:159–163.