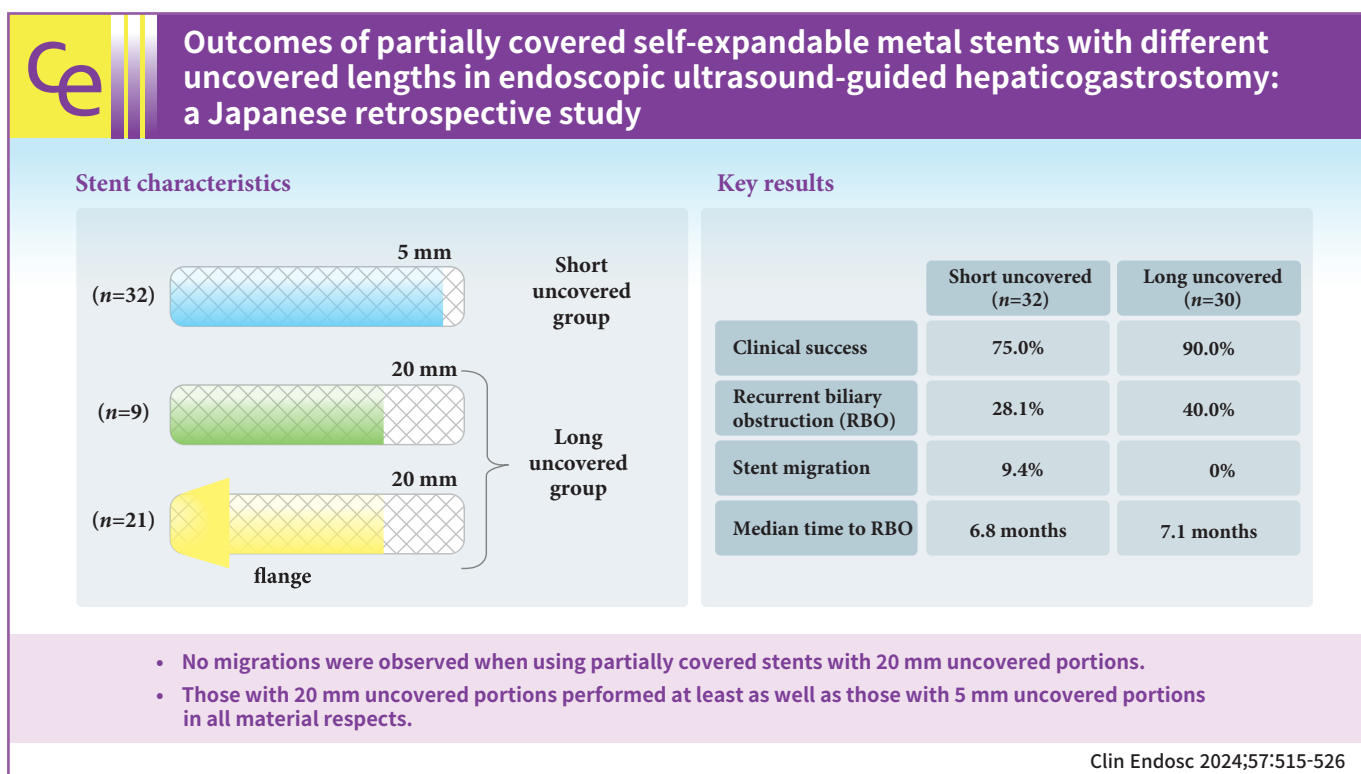


Outcomes of partially covered self-expandable metal stents with different uncovered lengths in endoscopic ultrasound-guided hepaticogastrostomy: a Japanese retrospective study

Takeshi Okamoto, Takashi Sasaki, Tsuyoshi Takeda, Tatsuki Hirai, Takahiro Ishitsuka, Manabu Yamada, Hiroki Nakagawa, Takafumi Mie, Takaaki Furukawa, Akiyoshi Kasuga, Masato Ozaka, Naoki Sasahira

Department of Hepato-Biliary-Pancreatic Medicine, Cancer Institute Hospital of Japanese Foundation for Cancer Research, Tokyo, Japan



Received: May 24, 2023 Revised: August 28, 2023

Accepted: September 4, 2023

Correspondence: Naoki Sasahira

Department of Hepato-Biliary-Pancreatic Medicine, Cancer Institute Hospital of Japanese Foundation for Cancer Research, 3-8-31, Ariake Koto-ku, Tokyo, 135-8550, Japan

E-mail: naoki.sasahira@jfcrr.or.jp

© This is an Open Access article distributed under the terms of the Creative Commons Attribution Non-Commercial License (<https://creativecommons.org/licenses/by-nc/4.0/>) which permits unrestricted non-commercial use, distribution, and reproduction in any medium, provided the original work is properly cited.

Background/Aims: The optimal length of the uncovered portion of partially covered self-expandable metal stents (PCSEMSs) used in endoscopic ultrasound-guided hepaticogastrostomy (EUS-HGS) remains unclear. This study investigated the safety and efficacy of PCSEMSs with different uncovered lengths, with a focus on stent migration and time to recurrent biliary obstruction (RBO).

Methods: Outcomes of patients undergoing EUS-HGS using PCSEMSs with 5-mm and 20-mm uncovered portions at our institution from January 2016 to December 2021 were compared.

Results: Sixty-two patients underwent EUS-HGS using PCSEMS (5/20-mm uncovered portions: 32/30). Stent migration occurred only in the 5-mm group. There were no differences in RBO rates (28.1% vs. 40.0%) or median time to RBO (6.8 vs. 7.1 months) between the two groups. Median overall survival (OS) was longer in the 20-mm group (3.1 vs. 4.9 months, $p=0.037$) due to the higher number of patients that resumed chemotherapy after EUS-HGS (56.7% vs. 28.1%, $p=0.029$). Good performance status, absence of hepatic metastases, and chemotherapy after EUS-HGS were independent predictors of longer OS.

Conclusions: No migration was observed in patients treated with PCSEMS with 20-mm uncovered portions. Patients treated with PCSEMS with 20-mm uncovered portions performed at least as well as those treated with 5-mm uncovered portions in all material respects.

Keywords: Bile duct obstruction; Biliary tract; Endosonography; Pancreatic neoplasms; Self expandable metallic stents

INTRODUCTION

Endoscopic ultrasound-guided biliary drainage (EUS-BD) has recently been added to the arsenal of endoscopic techniques for treating malignant biliary obstruction. Current guidelines recommend EUS-BD in cases where biliary drainage with endoscopic retrograde cholangiopancreatography (ERCP) fails or is not feasible.^{1,2}

Japanese guidelines suggest the use of covered self-expandable metal stents (SEMS) over plastic stents in EUS-guided hepaticogastrostomy (EUS-HGS) because of the lower rate of adverse events, including bile leakage and stent migration.¹⁻³ However, fully covered SEMS are associated with stent migration and side branch obstruction, which may lead to segmental cholangitis or abscess formation.^{1,4-6}

Recently, partially covered SEMS (PCSEMS) have been suggested as an alternative to overcome these issues, and their safety, effectiveness, and long-term outcomes in EUS-HGS have been reported.^{1,7,8} The uncovered portion on the liver side aims to reduce stent migration from the liver into the stomach, while also preventing obstruction of side branches that arise at the uncovered part, at the expense of potential mucosal hyperplasia in that part.⁸

PCSEMS with various lengths of uncovered portions on the liver side are currently available; however, the optimal length of the uncovered portion has not been examined. In this study, we evaluated the outcomes of EUS-HGS using PCSEMS with short (5 mm) and long (20 mm) uncovered portions on the liver side. We focused on adverse events, particularly on stent migration, because it is potentially fatal, and time to recurrent biliary ob-

struction (RBO). We also explored reinterventions after RBO and factors affecting overall survival (OS) after EUS-HGS.

METHODS

Patients

From our prospectively maintained database, we retrospectively reviewed the records of all patients who had undergone EUS-HGS at our institution between January 1, 2016, and December 31, 2021. Only patients who had received PCSEMS with 5-mm or 20-mm uncovered portions on the liver side were included, whereas those who had received fully covered SEMS or PCSEMS with other uncovered lengths were excluded. Patients in whom the procedure was terminated before stent placement were also excluded. Written informed consent was obtained from all patients before SEMS placement.

Definitions

The procedure time was defined as the time from the first liver puncture to completion of stent deployment. Technical success was defined as the successful placement of a stent extending from the intended intrahepatic branch (B2 or B3) to the stomach. Clinical success was defined as at least 50% improvement or normalization of the total bilirubin level without the need for further biliary intervention within 14 days after the procedure. Adverse events were defined based on the American Society of Gastrointestinal Endoscopy lexicon for endoscopic adverse events.⁹ Only early adverse events that occurred within 14 days from the procedure were considered for the analyses.

RBO was defined according to the TOKYO criteria 2014.¹⁰

However, only RBO involving the HGS route was included. Time to RBO was defined as the time between EUS-HGS and the next intervention involving the HGS route or intrahepatic branches drained by the HGS stent.

Endoscopic procedures

In our institution, we performed ERCP in the first session, where it was possible to achieve biliary drainage, remove any transpapillary plastic stents or SEMS, and place a nasobiliary tube in one of the left intrahepatic ducts (generally B3). After resolution of cholangitis or jaundice, EUS-HGS was performed in the second session by injecting saline from the nasobiliary tube to dilate the target intrahepatic duct, as required. EUS-HGS was occasionally preceded by percutaneous transhepatic biliary drainage in patients who were hemodynamically unstable and/or for whom ERCP was challenging. Although EUS-HGS was initially reserved for patients with end-stage disease, we gradually expanded its indications in line with our institutional learning curve.

All procedures were performed by expert endoscopists with >5 years of experience in therapeutic pancreatobiliary endoscopy. All EUS-HGS procedures were performed using a convex echoendoscope (GF-UCT260; Olympus Corp.). Reinterventions through the HGS route were generally performed using duodenoscopes with 4.2-mm working channels (TJF-260V or TJF-Q290V; Olympus Corp.).

Self-expandable metal stents

From January 2016 to June 2019, we used the Niti-S Biliary S-type Stent (Niti-S S-type Stent; Taewoong Medical Co., Ltd.), a PCSEMS with a 5-mm uncovered portion on the liver side and a short, 2-mm flare on the stomach side (Fig. 1A). From July 2019 to June 2020, we used a modified EGIS Biliary Stent, Double Covered (EGIS Stent; Biotech Inc.) (Fig. 1B). The stent was initially designed with a short, uncovered portion on the liver side,¹¹ but was modified via an extension to 20-mm to reduce the risk of migration towards the stomach during EUS-HGS. From July 2020 onward, we used the Niti-S S-type Spring Stopper Stent (Spring Stopper Stent; Taewoong Medical Co., Ltd.), which has an uncovered portion on the liver side and a flange on the stomach side to prevent migration from the stomach towards the peritoneum/liver (Fig. 1C).¹² While stents with uncovered portions measuring 15 and 20 mm are available, only cases using the 20-mm type were included in this study. We placed the 5-mm uncovered portion of the Niti-S S-type

Stent in the punctured branch (B2 or B3) immediately proximal to the B2/3 bifurcation, to avoid covering the bifurcation. However, we placed the 20-mm uncovered portion of the other two stents in the B2/3 branch (beyond the bifurcation) due to the reduced risk of side branch obstruction associated with the EGIS Stent and the Spring Stopper Stent.

Postprocedural follow-up

Chemotherapy was initiated or resumed after EUS-HGS at the oncologist's discretion. The response to chemotherapy was evaluated based on the Response Evaluation Criteria in Solid Tumors guidelines (ver. 1.1).¹³ OS was defined as the time from EUS-HGS to death from any cause or the last follow-up date. Progression-free survival (PFS) was defined as the time from EUS-HGS to death from any cause, disease progression confirmed by imaging studies, or the last follow-up date. Follow-up data were confirmed up to June 30, 2022.




Fig. 1. (A) Niti-S Biliary S-type Stent, a partially covered self-expandable metal stent (PCSEMS) with a 5-mm uncovered portion on the liver side (right) and a short, 2-mm flare on the stomach side (left). (B) Modified EGIS Biliary Stent, Double Covered, a PCSEMS modified to extend the short uncovered portion on the liver side (right) to 20 mm. (C) Niti-S S-type Spring Stopper Stent, a PCSEMS with a 20-mm uncovered portion on the liver side (right) and a flange on the stomach side (left).

Statistical analysis

Categorical variables are presented as absolute numbers (percentages), whereas continuous variables are presented as medians (range). Denominators of ratios were adjusted for missing data. Statistical analyses were conducted using Pearson’s chi-square test or Fisher exact test for categorical variables and the Mann-Whitney *U* test for continuous variables. Survival analysis using Kaplan-Meier curves and log-rank analyses were conducted to evaluate OS and time to RBO. Cox regression analyses were performed to evaluate factors affecting OS. Multivariate analysis was performed on variables with *p*<0.1 in univariate analysis. Statistical significance was set at *p*<0.05. All statistical analyses were conducted using IBM SPSS Statistics ver. 28.0 (IBM Corp.).

Ethical considerations

This study was approved by the Institutional Review Board of Cancer Institute Hospital of Japanese Foundation for Cancer Research (2021-GB-110). Patient consent for inclusion in the study was waived owing to its retrospective study design. The

study was publicized on the hospital website and patients were permitted to opt out without any impact on their care.

RESULTS

Patient characteristics

Sixty-two patients underwent EUS-HGS during the study period. Thirty-eight patients had pancreatic cancer, 19 had biliary tract cancer, and the remaining five had stomach, liver, and duodenal cancer. Thirty-two patients received PCSEMS with 5-mm uncovered portions on the liver side (Niti-S S-type Stent: short uncovered group), while 30 received PCSEMS with 20-mm uncovered portions on the liver side (EGIS Stent: 9/Spring Stopper Stent: 21; long uncovered group).

The short uncovered group was more likely than the long uncovered group to have received previous chemotherapy (78.1% vs. 53.3%, *p*=0.039) and to have been undergoing chemotherapy at the time of EUS-HGS (68.8% vs. 40.0 %, *p*=0.023). No other baseline characteristics differed significantly between the two groups were observed (Table 1).

Table 1. Baseline characteristics

Characteristic	Short uncovered (n=32)	Long uncovered (n=30)	<i>p</i> -value*
Age at EUS-HGS (yr)	67 (43–88)	65 (38–92)	
Male	15 (46.9)	17 (56.7)	
Performance status, 0/1/2	18/12/2	15/11/4	
Primary cancer, pancreatic/biliary tract/other	21/10/1	17/9/4	
Obstruction site			
Hilar or diffuse	10 (31.3)	9 (30.0)	
Extrahepatic	22 (68.8)	21 (70.0)	
Laboratory markers before EUS-HGS			
Total bilirubin (mg/dL)	1.2 (0.3–15.9)	1.4 (0.3–16)	
Alkaline phosphatase (IU/L, JSCC)	984 (230–2,554)	900 (275–4314)	
C-reactive protein (mg/dL)	2.4 (0.0–17.8)	4.3 (0.3–15.5)	
Carbohydrate antigen 19-9 (IU/mL)	245 (2–50,000)	681 (2–50000)	
Status of disease			
Hepatic metastasis	18 (56.3)	14 (46.7)	
Duodenal invasion	19 (59.4)	17 (56.7)	
Ascites	12 (37.5)	13 (43.3)	
Peritoneal dissemination	7 (21.9)	11 (36.7)	
Surgically-altered anatomy	8 (25.0)	6 (20.0)	
Previous chemotherapy	25 (78.1)	16 (53.3)	0.039
Ongoing chemotherapy at the time of EUS-HGS	22 (68.8)	12 (40.0)	0.023
Previous duodenal stent placement	11 (34.4)	7 (23.3)	
Previous biliary drainage	24 (75.0)	20 (66.7)	

Values are presented as median (range) or number (%).

EUS-HGS, endoscopic ultrasound-guided hepaticogastrostomy; JSCC, Japan Society of Clinical Chemistry.

**p*<0.1.

Endoscopic procedures

EUS-HGS was caused by duodenal tumor invasion in 35 patients (56.5%) and surgically-altered anatomy in 12 patients (19.4%). Other reasons included other causes of ERCP failure, repeated RBO after ERCP drainage, and inability to perform additional interventions through a previously placed SEMS in hilar malignant biliary obstruction, peribiliary abscess, and concurrent pancreatitis. EUS-HGS was performed after the resolution of cholangitis via endoscopic or percutaneous biliary drainage in 32 patients (51.6%). Twenty-nine patients underwent endoscopic nasobiliary drainage and three underwent

percutaneous transhepatic biliary drainage prior to EUS-HGS during the same admission.

There were no significant procedural differences between the short uncovered and long uncovered groups, although patients in the former tended to be treated more commonly with 10-cm stents (75% vs. 53.3%, $p=0.086$) (Table 2). The technical success rate was 100% and clinical success was achieved in 51 patients (82.3%). Adverse events were observed in 11 patients (short/long uncovered groups: 6/5 patients), most of which resolved spontaneously. Two patients required admission to the intensive care unit (due to biliary hemorrhage [long uncovered group]

Table 2. Procedure-related characteristics

Characteristic	Short uncovered (n=32)	Long uncovered (n=30)	p-value*
Main reason for EUS-HGS			
Duodenal invasion	18 (56.3)	17 (56.7)	
Surgically-altered anatomy	7 (21.9)	5 (16.7)	
Other	7 (21.9)	8 (26.7)	
Nasobiliary or percutaneous drainage in previous session	19 (59.4)	13 (43.3)	
Cholangitis before EUS-HGS	22 (68.8)	15 (50.0)	
Stent length (cm), 8/10/12	0/24/8	2/16/12	0.086
Stent diameter (mm), 6/8/10	2/27/3	0/28/2	
Procedure time (min)	23 (10–100)	17 (7–113)	
Target branch (B2/B3)	2/30	3/27	
Target branch diameter (mm)	3.0 (2–9)	2.5 (1–13)	
Puncture distance on endoscopic ultrasound (mm)	20 (10–38)	20 (15–30)	
No. of punctures (time)	1 (1–6)	1 (1–20)	
Stent length in liver (mm)	55 (31–80)	54 (28–72)	
Stent length in peritoneum (mm)	11 (4–35)	12 (3–30)	
Stent length in stomach (mm)	35 (14–77)	41 (12–70)	
Technical success	32 (100.0)	30 (100.0)	
Clinical success	24 (75.0)	27 (90.0)	
Adverse events ^{a)}	6 (18.8)	5 (16.7)	
Peritonitis (due to bile leak)	1 (3.1)	3 (10.0)	
Biloma/abscess	1 (3.1)	1 (3.3)	
Hemorrhage	0 (0)	1 (3.3)	
Sepsis	1 (3.1)	0 (0)	
Segment cholangitis	1 (3.1)	0 (0)	
Complete migration towards the liver ^{b)}	1 (3.1)	0 (0)	
Incomplete migration towards the liver	1 (3.1)	0 (0)	
Death ^{b)}	1 (3.1)	0 (0)	
Length of hospital stay after stent placement (day)	10 (1–59)	9 (3–59)	
Chemotherapy after stenting	9 (28.1)	17 (56.7)	0.029
RBO involving EUS-HGS stent	9 (28.1)	12 (40.0)	
Early RBO (within 3 mo)	3 (9.4)	5 (16.7)	

Values are presented as number (%) or median (range).

EUS-HGS, endoscopic ultrasound-guided hepaticogastrostomy; RBO, recurrent biliary obstruction.

^{a)}One case of incomplete migration towards the stomach was not considered an adverse event, as the situation was remedied by the addition of a second self-expandable metal stent during the same session, with no harm to the patient. ^{b)}Occurred in the same patient.

* $p<0.1$.

and sepsis [short uncovered group]), and one patient died (due to bleeding and peritonitis secondary to complete stent migration towards the liver [short uncovered group]).

This fatal case involved an 80-year-old man with malignant biliary obstruction due to pancreatic head cancer. EUS-HGS was performed on the B2 intrahepatic branch. After tract dilation with a 6-mm balloon dilator, a 6 mm×10 cm Niti-S S-type Stent was successfully deployed (Supplementary Fig. 1A). Bleeding was observed during the session, but hemostasis was confirmed endoscopically (Supplementary Fig. 1B). However, the patient experienced cardiopulmonary arrest before dawn the following day. Plain computed tomography after successful resuscitation revealed complete stent migration, with the proximal end inside the peritoneal cavity, accompanied by peritoneal free air and new-onset ascites (Supplementary Fig. 1C). Blood was observed in the stomach; however, no active bleeding was confirmed, and the puncture site could not be visualized on emergency esophagogastroduodenoscopy (Supplementary Fig. 1D). The patient was unfit for surgery and died several hours later, despite multiple blood transfusions, and administration of catecholamines and antibiotics.

Stent migration (three cases, including the previously described fatal case, one patient with incomplete migration towards the liver requiring additional SEMS placement four days later and one patient with incomplete migration towards

the stomach requiring the addition of a second SEMS during the same session) occurred only in the short uncovered group. While both groups exhibited similar postprocedural courses, more patients in the long uncovered group underwent chemotherapy (28.1% vs. 56.7%, $p=0.029$). Among those who received chemotherapy after EUS-HGS, the long uncovered group exhibited no association with longer median OS (5.0 vs. 5.5 months, $p=0.319$).

Recurrent biliary obstruction

RBO was observed in 21 patients (9 [28.1%] in the short uncovered group vs. 12 [40.0%] in the long uncovered group, $p=0.213$) (Table 3). Mucosal hyperplasia of the uncovered portion occurred in six (18.8%) and seven patients (23.3%) in the short and long uncovered groups, respectively ($p=0.628$). The causes of RBO did not differ significantly between the two groups.

All patients with RBO were endoscopically treated with 100% clinical success. Most patients were treated with balloon cleaning (57.1%), followed by stent-in-stent placement (76.2%). Stent-in-stent placement was performed more frequently in the long uncovered group (55.6% vs. 91.7%, $p=0.055$). Plastic stents were placed more often in the long uncovered group (22.2% vs. 91.7%, $p<0.001$), whereas metal stents were placed more often in the short uncovered group (33.3% vs. 0%, $p=0.031$); multi-

Table 3. Recurrent biliary obstruction

	Total (n=21)	Short uncovered (n=9)	Long uncovered (n=12)	p-value*
Causes				
Hyperplasia	13 (61.9)	6 (66.7)	7 (58.3)	
Debris	4 (19.0)	1 (11.1)	3 (25.0)	
Kink	2 (9.5)	1 (11.1)	1 (8.3)	
Food impaction	2 (9.5)	1 (11.1)	1 (8.3)	
Interventions performed^{a)}				
Balloon cleaning	12 (57.1)	4 (44.4)	8 (66.7)	
Balloon dilatation	9 (42.9)	4 (44.4)	5 (41.7)	
Temporary nasobiliary drainage tube placement	10 (47.6)	6 (66.7)	4 (33.3)	
Stent-in-stent placement	16 (76.2)	5 (55.6)	11 (91.7)	0.055
Plastic stent	13 (61.9)	2 (22.2)	11 (91.7)	<0.001
Metal stent	3 (14.3)	3 (33.3)	0 (0)	0.031
Radiofrequency ablation within stent	1 (4.8)	0 (0)	1 (8.3)	
Stent trimming (argon plasma coagulation)	2 (9.5)	1 (11.1)	1 (8.3)	
Clinical success	21 (100.0)	9 (100.0)	12 (100.0)	
Re-recurrent biliary obstruction	5 (23.8)	2 (22.2)	3 (25.0)	

Values are presented as number (%).

^{a)}Multiple interventions performed in most cases.

* $p<0.1$.

ple RBOs occurred in two (22.2%) and three (25.0%) patients ($p=0.633$), respectively, all of whom were also treated endoscopically.

RBO was generally observed in patients with less advanced disease who had lived long enough to experience it. Specifically, patients experiencing RBO were less likely than those not experiencing RBO to have peritoneal dissemination (4.8% vs. 41.5%, $p=0.003$) or to receive chemotherapy before EUS-HGS (42.9% vs. 78.0%, $p=0.010$), but were more likely to receive chemotherapy after EUS-HGS (66.7% vs. 29.3%, $p=0.007$) or to have longer median OS (7.3 vs. 2.4 months, $p<0.001$). The length of the uncovered portion had no effect on the RBO rate (long uncovered group: 57.1% vs. short uncovered group: 48.8%, $p=0.423$).

Chemotherapy after EUS-HGS

Forty-one patients received chemotherapy before EUS-HGS, of which 34 continued to receive chemotherapy up to less than 4 weeks before EUS-HGS. Of these, chemotherapy resumed in 14 patients after EUS-HGS, while the remaining 20 patients received the best supportive care. Twelve patients received chemotherapy for the first time after EUS-HGS, while nine never received chemotherapy before or after EUS-HGS; therefore, 26 patients (16 with pancreatic cancer, seven with biliary tract cancer, and three with other cancers) received chemotherapy after EUS-HGS (Supplementary Material 1, Supplementary Table 1).

Patients who received chemotherapy after EUS-HGS were more likely to be in the long uncovered group (17 patients [65.4%] vs. 13 patients [36.1%], $p=0.023$), to achieve clinical success (100% vs. 75.0%, $p=0.008$), to have shorter median lengths of stay after EUS-HGS (8 vs. 11 days, $p=0.015$), to subsequently experience RBO (57.7% vs. 25.0%, $p=0.009$), and to have longer median OS (6.1 vs. 2.7 months, $p<0.001$) than those of patients who did not resume chemotherapy (Supplementary Table 1). These patients also tended to have better Eastern Cooperative Oncology Group performance status (all had a performance status of 0 or 1; $p=0.059$), lower preprocedural total bilirubin (median 1.2 vs. 1.8 mg/dL, $p=0.065$), and lower likelihood to have a history of previous chemotherapy (53.8% vs. 75.0%, $p=0.082$). The median PFS of patients who had resumed chemotherapy was 3.4 months. Nine and three patients remained progression-free after 6 and 12 months, respectively.

OS and time to RBO

The short uncovered group had significantly shorter median OS than that of the long uncovered group (3.1 vs. 4.9 months,

$p=0.037$). Five patients in the short uncovered group and three in the long uncovered group died during the admission for the EUS-HGS procedure ($p=0.509$). However, all patients were on best supportive care before the procedure, and only one died due to an adverse event. The median time to RBO (6.8 vs. 7.1 months, $p=0.760$; Fig. 2), 3-month patency rate (82.4% vs. 84.2%, $p=0.881$), and 6-month patency rate (62.5% vs. 75.0%, $p=0.551$) did not differ significantly between the two groups.

According to Cox regression analysis, the predictors of longer OS included performance status of 0 or 1 (hazard ratio [HR], 0.33; $p=0.032$), absence of hepatic metastases (HR for the presence of hepatic metastases, 3.30; $p<0.001$), use of stents with long uncovered portions (HR, 0.58; $p=0.040$), and chemotherapy after EUS-HGS (HR, 0.36; $p<0.001$) (Table 4). While performance status, hepatic metastases, and chemotherapy after EUS-HGS remained significant in multivariate analysis (HR for presence of hepatic metastases: 3.63, 95% confidence interval [CI], 2.03–6.51; $p<0.001$; HR for performance status of 0 or 1, 0.22; 95% CI, 0.09–0.57; $p=0.002$; HR for chemotherapy after EUS-HGS, 0.34; 95% CI, 0.18–0.63; $p<0.001$), the use of stents with long uncovered portions was not an independent predictor of OS (HR, 0.64; 95% CI, 0.36–1.14; $p=0.130$).

Regarding the time to RBO, peritoneal dissemination was an independent predictor for a longer time to RBO (HR, 0.11; 95% CI, 0.01–0.78), although only one patient with peritoneal dissemination survived long enough to experience RBO (Supplementary Table 2). Hilar or diffuse biliary obstruction also tended to predict longer time to RBO, but this was not significant in multivariate analysis.

DISCUSSION

In this study, we evaluated outcomes after EUS-HGS using PCSEMS with 5-mm and 20-mm uncovered portions on the liver side. The RBO rates and the median time to RBO did not differ significantly between the two groups. Clinical success was achieved in all reinterventions after RBO, with the long uncovered group being more likely to undergo stent-in-stent placement. Median OS was longer in the long uncovered group; however, this was due to the higher number of patients who were able to resume chemotherapy, reflecting the time period of EUS-HGS rather than the choice of SEMs. Good performance status, the absence of hepatic metastases, and chemotherapy after EUS-HGS were independent predictors of longer OS in patients who had undergone EUS-HGS. While RBO was also

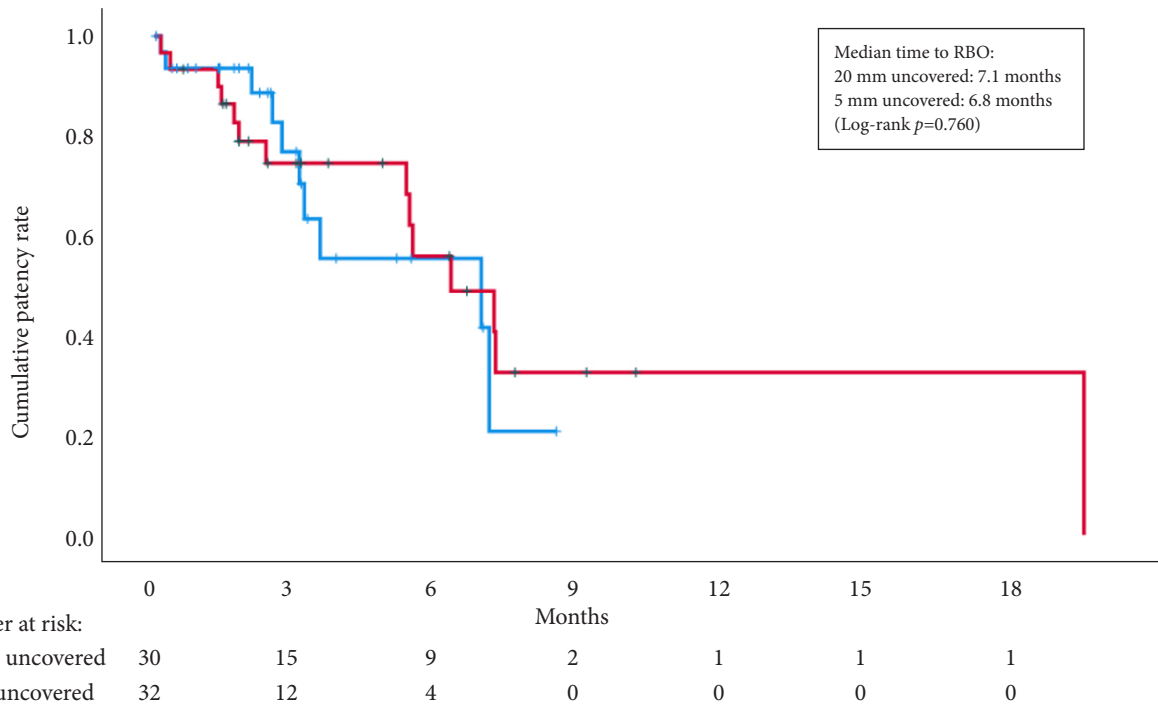


Fig. 2. Kaplan-Meier curve for time to recurrent biliary obstruction (RBO), stratified by length of the uncovered portion.

Table 4. Factors affecting overall survival

	Univariate		Multivariate	
	HR (95% CI)	p-value	HR (95% CI)	p-value
Old age (65 yr or older)	0.93 (0.55–1.58)	0.793		
Male sex	1.02 (0.61–1.73)	0.928		
Good performance status (0 or 1)	0.33 (0.13–0.82)	0.032	0.39 (0.14–0.99)	0.048
Pancreatic cancer	0.84 (0.50–1.43)	0.522		
Hepatic metastasis	3.30 (1.84–5.90)	<0.001	4.41 (2.40–68.10)	<0.001
Peritoneal dissemination	1.02 (0.57–1.82)	0.951		
Stent length (12 cm)	0.92 (0.73–1.16)	0.916		
Long uncovered portion	0.58 (0.34–0.98)	0.040	0.64 (0.36–1.14)	0.130
Short stent length in peritoneum (>20 mm)	1.70 (0.70–3.86)	0.206		
Hilar or diffuse biliary obstruction	0.99 (0.57–1.73)	0.976		
Chemotherapy after EUS-HGS	0.36 (0.21–0.64)	<0.001	0.34 (0.18–0.63)	<0.001

HR, hazard ratio; CI, confidence interval; EUS-HGS, endoscopic ultrasound-guided hepaticogastrostomy.

associated with longer OS, RBO was most likely the result, rather than a cause, of longer OS.

Review of the literature

A review of eight studies (including ours) with at least 20 patients who had undergone EUS-HGS with PCSEMS with sufficient data revealed weighted average technical and clinical success rates of 98.6% and 88.5%, respectively (Table 5),^{4,12,14-19}

which are consistent with data from a review of 27 studies (96% and 90%, respectively).²⁰ Interestingly, no two studies used the same PCSEMS or same uncovered length, highlighting the lack of consensus on the optimal uncovered length. Early adverse events were observed in a weighted average of 19.4% of the cases, but most resolved with conservative treatment alone. Our RBO rate of 33.9% was comparable to the weighted average of 33.4%, although the different follow-up periods across studies

Table 5. Reports of EUS-HGS with partially covered self-expandable metal stents

Study ^{a)}	Year	n	PCSEMS	Uncovered length (mm)	Primary cancer (pancreatic/biliary tract/other)	Technical success (%)	Clinical success (%)	Early adverse events (%)	RBO (%)	Time to RBO (mo)	Overall survival (mo)
Artifon et al. ¹⁴	2015	25	Wallstent	NA	16/2/7	96.0	91.7	20.0	NA	NA	2.5
Cho et al. ¹⁵	2017	21	Hybrid	25-50	3/14/4	100.0	85.7	19.0	47.6	5.5	5.8
De Cassan et al. ¹⁶	2017	41	Giobor	40/50	17/18/6	90.2	65.5	31.7	27	NA	NA
Miyano et al. ¹⁷	2018	41	NA	NA	13/14/14	100.0	100.0	14.6	NA	NA	NA
Nakai et al. ⁸	2020	110	Modified Giobor	10	55/34/21	100.0	93.6	24.5	32.7	6.3	NA
Emmanuel et al. ¹⁸	2020	20	BPD Hanaro	30	13/2/5	100.0	95.0	0	NA	NA	NA
Yamamura et al. ¹⁹	2022	31	Spring Stopper	15	20/9/2	100.0	93.5	6.5	NA	3.2	NA
Present study	2022	62	3 Types	5/20	38/19/5	100.0	82.3	17.7	33.9	6.8	3.6
Total/weighted average		351			175/112/64	98.6	88.5	19.4	33.4	5.9	3.7

EUS-HGS, endoscopic ultrasound-guided hepaticogastrostomy; NA, not available; RBO, recurrent biliary obstruction.

^{a)}Includes studies in which EUS-HGS was performed using PCSEMS on at least 20 subjects. Studies with insufficient data or with overlapping institutions and time periods were excluded.

preclude a direct comparison. Only a few studies provided data on the median time to RBO (weighted average, 5.9 months) and median OS (weighted average, 3.7 months).

Adverse events

In our study, early adverse events occurred in 17.7% of the cases, with no significant difference between groups. However, all three cases of stent migration occurred in the short uncovered group. The case of stent migration towards the stomach triggered our transition to PCSEMS with longer uncovered portions, which serve as anchors and permit deeper stent insertion with less concern about side branch obstruction. In addition, the anti-migration flange of the Spring Stopper Stent may have reduced the risk of migration towards the liver.¹² The two groups did not differ in terms of the distance between the stomach and liver, which has been reported as a risk factor for stent migration.²¹

One case of incomplete stent migration towards the stomach occurred in the short uncovered group. A systematic review of 1,192 EUS-guided biliary drainage procedures revealed stent migration in 2.68% of cases, although the study was not limited to EUS-HGS cases.²² Our review of all 42 studies included in the systematic review revealed seven cases of outward stent migration towards the stomach, one of which was fatal.²³⁻²⁹ Although it is rarer than stent migration towards the liver, care is required to avoid this potentially catastrophic event.

Recurrent biliary obstruction

Consistent with past reports, the majority of RBO cases resulted from hyperplasia of the uncovered portion.⁸ The length of the uncovered portion did not significantly affect the likelihood of RBO due to hyperplasia in our study. Although differences in patient backgrounds preclude direct comparisons, PCSEMS with various uncovered lengths had similar RBO rates (Table 5), and longer uncovered portions may not necessarily be associated with increased risk of hyperplasia. Reintervention was successful in all cases through the HGS route, requiring stent-in-stent placement in 75% of the cases and only balloon cleaning or dilatation in the remaining cases. Plastic stents were primarily used in stent-in-stent placement, particularly when biliary access was only possible through the mesh of the EUS-HGS stent. This was especially the case in the long uncovered group, in which 91.7% of the RBO cases were treated with stent-in-stent placement of plastic stents. This difference between the groups reflects our increased understanding over time that

hyperplasia eventually develops in the uncovered portion, even when it is not the primary cause of RBO. Thus, when we transitioned to the EGIS Stent, stent-in-stent placement of plastic stents became our main strategy for RBO.

Chemotherapy after EUS-HGS

The effect of chemotherapy on stent patency and OS in patients undergoing EUS-HGS has not been studied in depth. One study with 51 participants found that patients on chemotherapy before EUS-HGS had longer patency than those who did not undergo chemotherapy, with a HR of 3.02 (95% CI, 1.45–6.30).²⁰ However, the study did not clarify the number of patients who were able to resume chemotherapy after EUS-HGS. Another study with 21 participants reported that only one received chemotherapy (concurrent chemoradiotherapy) after EUS-HGS.¹⁵ We found that longer uncovered portion, clinical success, and shorter length of stay after EUS-HGS were associated with the ability to commence or resume chemotherapy after EUS-HGS. Median PFS was mediocre, at 3.4 months. Resuming chemotherapy after EUS-HGS was also an independent predictor for longer OS and, therefore, led to higher likelihood of survival until RBO.

In addition to chemotherapy after EUS-HGS, good performance status and absence of hepatic metastases were independent predictors of longer OS in patients who had undergone EUS-HGS. Hepatic metastases not only signify advanced disease, but may also limit the available EUS-HGS puncture routes or cause segmental biliary obstruction. The use of stents with 20-mm uncovered portions was associated with longer OS, although this association was not significant based on multivariate analysis. No notable factors predicting the time to RBO were identified in this study, as one significant factor in the multivariate Cox analysis reflected a single patient with peritoneal dissemination who happened to enjoy long stent patency.

Limitations

This study had several limitations. This was a retrospective study conducted at a single institution with a limited sample size, making selection bias inevitable. Patients who had received two different types of PCSEMS were included in the long uncovered group. As the choice of PCSEMS was dictated by the period during which EUS-HGS was conducted, institutional learning curves and advances in chemotherapy or supportive treatment might have worked in favor of the long uncovered group. Characteristics of SEMS other than the length of the

uncovered portion, such as proximal flares and flanges, wires used, stent type (e.g., braided or laser-cut), and membranes for the covered portion, which were not analyzed in this study, might also have affected stent migration and other causes of RBO. The stents used in this study were not available in some regions, limiting the generalizability of our results.

In conclusions, PCSEMSs with 20-mm uncovered portions on the liver side performed at least as well as those with 5-mm uncovered portions in all material respects. RBO due to hyperplasia and the time to RBO did not increase, when the uncovered portion was extended. The ability to reduce potentially fatal stent migration to the stomach may be an advantage of PCSEMSs with longer uncovered portions. Additional studies are warranted to determine the optimal uncovered length and to investigate whether certain patient subgroups may benefit from longer or shorter uncovered lengths.

Supplementary Material

Supplementary Fig. 1. (A) A 6 mm×10 cm Niti-S S-type Stent was successfully deployed in the B2 intrahepatic branch. (B) Bleeding was observed at the puncture site; however, hemostasis was confirmed on endoscopy. (C) The proximal end of the stent has migrated into the peritoneal cavity. (D) On emergency esophagogastroduodenoscopy, blood was observed in the stomach; however, no active bleeding was observed. The puncture site could not be visualized on emergency esophagogastroduodenoscopy. The endoscopic nasobiliary drainage tube remained in place.

Supplementary Material 1. The following chemotherapy was given after endoscopic ultrasound-guided hepaticogastrostomy (EUS-HGS) to the short uncovered group.

Supplementary Table 1. Chemotherapy after endoscopic ultrasound-guided hepaticogastrostomy (EUS-HGS).

Supplementary Table 2. Factors affecting time to recurrent biliary obstruction.

Supplementary materials related to this article can be found online at <https://doi.org/10.5946/ce.2023.142>.

Conflicts of Interest

Takashi Sasaki received honoraria from Boston Scientific Corp. and Century Medical, Inc. Naoki Sasahira received consulting fees from Gadelius Medical K.K. and honoraria from Boston Scientific Corp., Cook Medical Japan G.K., Gadelius Medical K.K., Kaneka Medix Corp., Olympus Corp., and SB Kawasumi Laboratories Inc. The other authors have no potential conflicts of interest.

Funding

None.

Author Contributions

Conceptualization: TO, NS; Data curation: all authors; Formal analysis: TO; Investigation: TO; Methodology: TO, NS; Project administration: TO, NS; Software: TO; Supervision: NS; Validation: TO, NS; Visualization: TO; Writing–original draft: TO; Writing–review & editing: all authors.

ORCID

Takeshi Okamoto	https://orcid.org/0000-0001-9719-0282
Takashi Sasaki	https://orcid.org/0000-0001-7109-9835
Tsuyoshi Takeda	https://orcid.org/0000-0002-0786-8166
Tatsuki Hirai	https://orcid.org/0009-0007-9222-0594
Takahiro Ishitsuka	https://orcid.org/0009-0000-1700-6925
Manabu Yamada	https://orcid.org/0009-0005-0566-1822
Hiroki Nakagawa	https://orcid.org/0000-0001-9077-9289
Takafumi Mie	https://orcid.org/0000-0002-7561-5558
Takaaki Furukawa	https://orcid.org/0000-0002-9746-6776
Akiyoshi Kasuga	https://orcid.org/0000-0002-2234-1135
Masato Ozaka	https://orcid.org/0000-0002-5666-1970
Naoki Sasahira	https://orcid.org/0000-0002-0672-7214

REFERENCES

1. Isayama H, Nakai Y, Itoi T, et al. Clinical practice guidelines for safe performance of endoscopic ultrasound/ultrasonography-guided biliary drainage: 2018. *J Hepatobiliary Pancreat Sci* 2019;26:249–269.
2. van der Merwe SW, van Wanrooij RL, Bronswijk M, et al. Therapeutic endoscopic ultrasound: European Society of Gastrointestinal Endoscopy (ESGE) Guideline. *Endoscopy* 2022;54:185–205.
3. Khashab MA, Messallam AA, Penas I, et al. International multicenter comparative trial of transluminal EUS-guided biliary drainage via hepatogastrostomy vs. choledochoduodenostomy approaches. *Endosc Int Open* 2016;4:E175–E181.
4. Ochiai K, Fujisawa T, Ishii S, et al. Risk factors for stent migration into the abdominal cavity after endoscopic ultrasound-guided hepatogastrostomy. *J Clin Med* 2021;10:3111.
5. Martins FP, Rossini LG, Ferrari AP. Migration of a covered metallic stent following endoscopic ultrasound-guided hepatogastrostomy: fatal complication. *Endoscopy* 2010;42 Suppl 2:E126–E127.
6. Okuno N, Hara K, Mizuno N, et al. Stent migration into the peritoneal cavity following endoscopic ultrasound-guided hepatogastrostomy. *Endoscopy* 2015;47 Suppl 1 UCTN:E311.
7. Nakai Y, Isayama H, Yamamoto N, et al. Safety and effectiveness of a long, partially covered metal stent for endoscopic ultrasound-guided hepatogastrostomy in patients with malignant biliary obstruction. *Endoscopy* 2016;48:1125–1128.
8. Nakai Y, Sato T, Hakuta R, et al. Long-term outcomes of a long, partially covered metal stent for EUS-guided hepatogastrostomy in patients with malignant biliary obstruction (with video). *Gastrointest Endosc* 2020;92:623–631.
9. Cotton PB, Eisen GM, Aabakken L, et al. A lexicon for endoscopic adverse events: report of an ASGE workshop. *Gastrointest Endosc* 2010;71:446–454.
10. Isayama H, Hamada T, Yasuda I, et al. TOKYO criteria 2014 for transpapillary biliary stenting. *Dig Endosc* 2015;27:259–264.
11. Asai S, Takeshita K, Ichinona T, et al. A novel partially covered metallic stent with a 20-mm long distal bare portion for EUS-guided hepatogastrostomy. *VideoGIE* 2021;6:322–324.
12. Ishii S, Isayama H, Sasahira N, et al. A pilot study of Spring Stopper Stents: novel partially covered self-expandable metallic stents with anti-migration properties for EUS-guided hepatogastrostomy. *Endosc Ultrasound* 2023;12:266–272.
13. Eisenhauer EA, Therasse P, Bogaerts J, et al. New response evaluation criteria in solid tumours: revised RECIST guideline (version 1.1). *Eur J Cancer* 2009;45:228–247.
14. Artifon EL, Marson FP, Gaidhane M, et al. Hepaticogastrostomy or choledochoduodenostomy for distal malignant biliary obstruction after failed ERCP: is there any difference? *Gastrointest Endosc* 2015;81:950–959.
15. Cho DH, Lee SS, Oh D, et al. Long-term outcomes of a newly developed hybrid metal stent for EUS-guided biliary drainage (with videos). *Gastrointest Endosc* 2017;85:1067–1075.
16. De Cassan C, Bories E, Pesenti C, et al. Use of partially covered and uncovered metallic prosthesis for endoscopic ultrasound-guided hepatogastrostomy: results of a retrospective monocentric study. *Endosc Ultrasound* 2017;6:329–335.
17. Miyano A, Ogura T, Yamamoto K, et al. Clinical impact of the intra-scope channel stent release technique in preventing stent migration during EUS-guided hepatogastrostomy. *J Gastrointest Surg* 2018;22:1312–1318.
18. Emmanuel J, Omar H, See LT. Endoscopic ultrasound-guided hepatogastrostomy using a partially covered metal stent in patients with malignant biliary obstruction after failed endoscopic retrograde cholangiopancreatography. *JGH Open* 2020;4:1059–1064.
19. Yamamura M, Ogura T, Ueno S, et al. Partially covered self-expandable metal stent with antimigratory single flange plays important role during EUS-guided hepatogastrostomy. *Endosc Int Open* 2022;10:E209–E214.

20. Paik WH, Park DH. Outcomes and limitations: EUS-guided hepaticogastrostomy. *Endosc Ultrasound* 2019;8(Suppl 1):S44–S49.
21. Ogura T, Yamamoto K, Sano T, et al. Stent length is impact factor associated with stent patency in endoscopic ultrasound-guided hepaticogastrostomy. *J Gastroenterol Hepatol* 2015;30:1748–1752.
22. Wang K, Zhu J, Xing L, et al. Assessment of efficacy and safety of EUS-guided biliary drainage: a systematic review. *Gastrointest Endosc* 2016;83:1218–1227.
23. Bories E, Pesenti C, Caillol F, et al. Transgastric endoscopic ultrasonography-guided biliary drainage: results of a pilot study. *Endoscopy* 2007;39:287–291.
24. Paik WH, Park DH, Choi JH, et al. Simplified fistula dilation technique and modified stent deployment maneuver for EUS-guided hepaticogastrostomy. *World J Gastroenterol* 2014;20:5051–5059.
25. Ogura T, Kurisu Y, Masuda D, et al. Novel method of endoscopic ultrasound-guided hepaticogastrostomy to prevent stent dysfunction. *J Gastroenterol Hepatol* 2014;29:1815–1821.
26. Panpimanmas S, Ratanachu-ek T. Endoscopic ultrasound-guided hepaticogastrostomy for advanced cholangiocarcinoma after failed stenting by endoscopic retrograde cholangiopancreatography. *Asian J Surg* 2013;36:154–158.
27. Attasaranya S, Netinasunton N, Jongboonyanuparp T, et al. The spectrum of endoscopic ultrasound intervention in biliary diseases: a single center's experience in 31 cases. *Gastroenterol Res Pract* 2012;2012:680753.
28. Kim TH, Kim SH, Oh HJ, et al. Endoscopic ultrasound-guided biliary drainage with placement of a fully covered metal stent for malignant biliary obstruction. *World J Gastroenterol* 2012;18:2526–2532.
29. Ramírez-Luna MA, Téllez-Ávila FI, Giovannini M, et al. Endoscopic ultrasound-guided biliodigestive drainage is a good alternative in patients with unresectable cancer. *Endoscopy* 2011;43:826–830.