



Morphometric analysis of sacral corridor in the upper three sacral segments to prevent neurovascular injury

Binita Chaudhary¹, Prem Kumar², Ruchika Narayan², Adil Asghar¹, Padamjeet Panchal¹, Neelam Kumari¹
Departments of ¹Anatomy and ²Radiodiagnosis, All India Institute of Medical Sciences Patna, Patna, India

Abstract: Although studies of the sacral corridor dimension have been reported in the European population, little attention has been paid to this issue in the Asian population. The purpose of the study is to estimate the safe dimension of the corridor to avoid neurovascular damage during the fixation of the sacral fracture. The study aimed to examine the cephalocaudal (vertical) and the anteroposterior diameter of the bony passage in the upper three sacral segments. The study further examines the effect of age and sex on corridor dimensions at different sacral levels. Three-dimensionally reconstructed sacra from computed tomography of normal subjects were included in the study. Cephalocaudal and anteroposterior diameters were measured in coronal and axial sections using Geomagic Freeform Plus software. Anteroposterior diameter of the sacral corridor at the first, second, and third sacral segments are significantly higher in males ($P=0.013$, 0.0011 , and <0.0001 , respectively). The length of the sacrum also revealed sexual dimorphism ($P<0.00016$). The anteroposterior diameter of the second sacral segment (ap-S2c) correlated moderately with the first sacral anteroposterior diameter (ap-S1c) ($R=0.519$, $P<0.001$). The ap-S2c exhibited a moderate correlation to the third sacral segment (ap-S3c) ($R=0.677$, $P<0.001$). The sacral corridor at the level of S1 has the largest cephalocaudal (18.25 mm) and anteroposterior diameter (17.11 mm). Placement of the screw in the first sacral corridor may avoid damage to the neurovascular bundle during the fixation of the sacral fracture.

Key words: Computed tomography, Sacrum, Corridor, Three-dimensional, Lumbosacral

Received October 26, 2023; Revised January 8, 2024; Accepted February 17, 2024

Introduction

The fusion of five vertebrae forms the sacrum and transfers the body weight from the trunk to the pelvis [1]. The sacral corridor (Sc) is the area on the sacral vertebra through which a screw is inserted to fix a sacral fracture. It (Sc) is a bony bridge that extends throughout the sacral segments. The bony corridors of the first, second, and third sacral seg-

ments are represented as first sacral corridor (S1c), second sacral corridor (S2c), and third sacral corridor (S3c), respectively (Fig. 1A).

The cephalocaudal (cc) dimension of the S1c is measured between the ala of the sacrum above and the first sacral foramina (F1) below (Fig. 1B). The S2c is bounded above and below by the F1 and second sacral foramina (F2), respectively. Similarly, the vertical limits of the S3c are the F2 and third sacral foramina (F3) (Fig. 1). All three Sc are bounded in front by the anterior sacral cortex (asc) and spinal canal (spc) behind (Fig. 2). The anteroposterior (ap) distance of each corridor was measured as the maximum distance from asc to spc. The neurovascular bundle lies in close vicinity of the sacral segments. So, to prevent nerves and vessels from being damaged, the screw needs to be placed uniformly within the

Corresponding author:

Binita Chaudhary 
Department of Anatomy, All India Institute of Medical Sciences Patna,
Phulwarisharif, Patna, Bihar 801507, India
E-mail: binitachaudhary18@gmail.com

Copyright © 2024. Anatomy & Cell Biology

This is an Open Access article distributed under the terms of the Creative Commons Attribution Non-Commercial License (<http://creativecommons.org/licenses/by-nc/4.0/>) which permits unrestricted non-commercial use, distribution, and reproduction in any medium, provided the original work is properly cited.

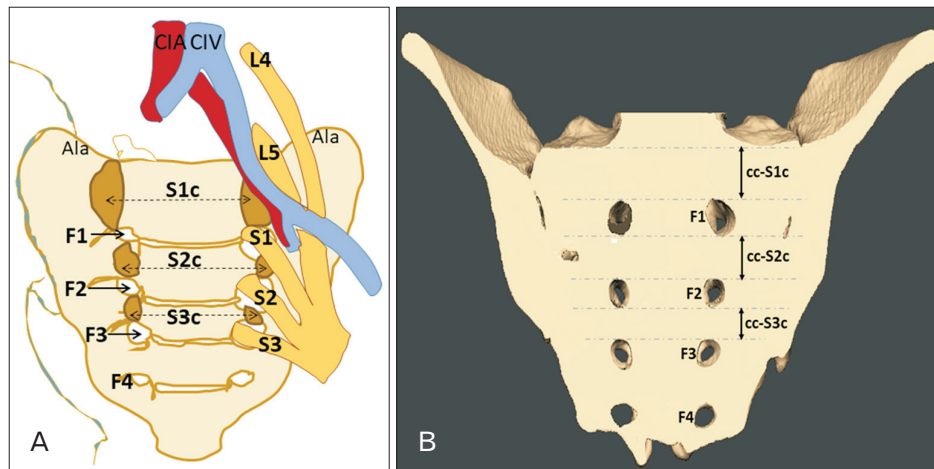


Fig. 1. (A) Shows the corridor at the first, second, and third sacral segments (colored in golden). The close association of nerves and vessels to the corridors can be seen. (B) Shows the cephalocaudal (cc) or vertical dimension of all three corridors in the coronal section. The cephalocaudal dimension of the S1c extends between the ala of the sacrum and the F1. The S2c spans the F1 and F2. The cc dimension of the S3c lies between the F2 and the F3. S1c, first sacral corridor; S2c, second sacral corridor; S3c, third sacral corridor; Ala, ala of the sacrum; F1, first sacral foramina; F2, second sacral foramina; F3, third sacral foramina; F4, fourth sacral foramina; L4, fourth lumbar spinal nerve; L5, fifth lumbar spinal nerve; S1, first sacral spinal nerve; S2, second sacral spinal nerve; S3, third sacral spinal nerve; CIA, common iliac artery; CIV, common iliac vein. The abbreviations' full term see Table 1.

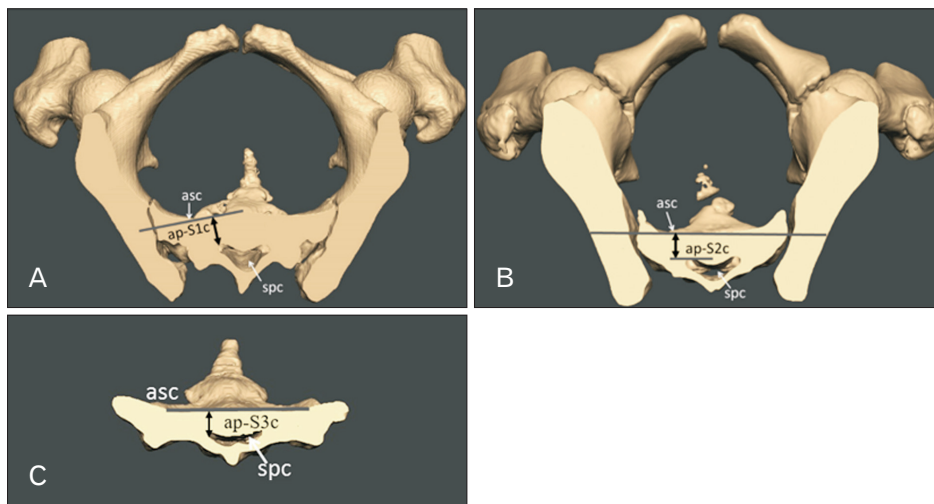


Fig. 2. (A-C) Shows the anteroposterior width of the corridor at different sacral segments in the axial section. asc, anterior sacral cortex; spc, spinal canal; The abbreviations' full term see Table 1.

bony sacral bridge. The anatomy of the upper sacral segment is highly variable [2, 3]. The total number of vertebrae in the lumbosacral region remains the same, but the fusion level of a transitional vertebra differs. Such variants are known as lumbosacral transitional vertebra (LSTV), which include sacralized fifth lumbar (L5) and lumbarized first sacral (S1) vertebra [4]. These variations may change the sacral inclination. Lack of awareness of adequacy of the intraosseous space (corridor) in these variable sacra leads to malpositioning of the screw. Routt et al. [2] described that screw malpositioning could be prevented with the help of a lateral sacral

radiographic image. Due to limited bio-morphometric data, Gras et al. [5] detailed the precise sacral anatomy to look for anatomic variation in the European population. Some authors have given quantitative parameters to avoid the failure of the technique. Few morphometric studies on Sc have been investigated in different populations. The adequacy of the Sc varies in different ethnic groups and sex. Wagner et al. [3] studied Sc in European and Japanese populations, but their results cannot be generalized to the other ethnic groups [6]. Mendel et al. [7] reported a triangle ratio of 1.5 (anterior height and superior width ratio of S1 body), rep-

representing a reliable variable for screw placement. The sacral dysmorphic score was developed by some authors based on the angulation of the upper sacral segment [8]. Gardner et al. [9] quantified safe zones in normal and dysmorphic sacra using computed tomography (CT). Appropriate morphometric data of Sc are required by the surgeons to prevent screw mal-positioning and neurovascular complications. The diameter of the implant required for sacral fracture fixation is 7.3 mm. The consideration of 2 mm of additional safe space on each side (7.3+2+2 mm) leads to a total anatomical corridor width of 11.3 mm (approx \approx 12 mm). In the present study, the corridor \geq 12 mm was assumed as adequate [6]. Limited studies exist regarding the Sc dimension in the Indian population [6]. In the present study, ten dimensions of the sacrum were measured, which included the cc and ap dimensions of the upper three Sc, length of the sacrum (L), the trans-sacral distance (TSD-S1, TSD-S2) at the level of the S1c and S2c, and iliosacral distance (ISD-S1) at the level of the first sacral segment (Table 1). The purpose of the study is to estimate the safe dimension of the corridor to avoid neurovascular damage during the fixation of sacral fractures in the Indian population. The study aimed to evaluate the cc and the ap dimension of the Sc in the upper three sacral segments (S1c, S2c, and S3c). The study further examines the effect of age and sex on the dimensions of the Sc at different sacral levels. In addition, the Sc dimensions of normal and LSTV sacra were explored.

Materials and Methods

This retrospective study was conducted in the Department of Anatomy to determine the dimension of the Sc of the upper three sacral segments. The research protocol was submitted for assessment and was approved by Institutional Ethics Committee of AIIMS Patna (IEC/2021/800 dated 16 September 2021).

Data synthesis

The study included pelvic CT of 180 patients. The patient's informed consent was not required as the archived CT data of previous years were retrieved. The high-quality CT images were randomly selected from the Picture archiving and communication system patient database of the Radiodiagnosis department. Permission to access CT scans and conduct this research was sought and approved by the institution. Anonymized Digital Imaging and Communication

in Medicine (DICOM) data were collected to preserve the patient's confidentiality. The sample size was obtained from the study by Wagner et al. [3] to achieve a power of 80% at a 5% significance level.

Three-dimensional-reconstructed sacra from computed tomography imaging

CT scans included images in axial, coronal, and sagittal planes. All the data were available in DICOM. Inclusion criteria included the pelvis over eighteen years of age. Normal sacra and LSTV of both sexes with complete ossification were included in the study. Age <18 years, CT scans with bony pathology and pelvic or sacral fracture were excluded from the study.

The software

CT scans were processed using D2P software (Dicom to print software Version 1.0.2.2043, 3D Systems). Bone, soft tis-

Table 1. List of study variables

Code	Study variable (parameter)
cc-S1c	Cephalo caudal dimension of the first sacral corridor. It is the maximum distance between the superior plane of the ala and the upper extent of the first sacral foramina (F1).
ap-S1c	Anteroposterior dimension of the first sacral corridor. It is the maximum distance between the anterior lateral corner of the sacral canal to the anterior cortical surface at the level of the first sacral segment.
cc-S2c	Cephalo caudal dimension of the second sacral corridor. Maximum distance between the inferior extent of the first sacral foramina (F1) and the superior extent of the second sacral foramina (F2).
ap-S2c	Anteroposterior dimension of the second sacral corridor. It is the maximum distance from the anteriormost extent of the sacral canal to the anterior sacral cortex at the level of the second sacral segment.
cc-S3c	Cephalo caudal dimension of the third sacral corridor. It is the maximum distance between the inferior and superior extent of the second (F2) and third sacral foramina (F3), respectively.
ap-S3c	Anteroposterior dimension of the third sacral corridor. It is the maximum distance from the anteriormost extent of the sacral canal to the anterior sacral cortex at the level of the third sacral segment.
L	Length of the sacrum.
TSD-S1	The maximum trans-sacral distance at the level of the first sacral segment.
TSD-S2	The maximum trans-sacral distance at the level of the second sacral segment.
ISD-S1	Iliosacral distance at the level of the first sacral segment.

sue, and other anatomical features were identified and semi-automatically segmented into separate areas. After segmentation, a three-dimensional (3D) digital model of the sacrum and innominate bones was generated and saved as Standard Tessellation Language (STL) files. “Geomagic Freeform Plus; 3D Systems” (STL editor software) was used to post-process the STL files to prepare the sacrum for morphometric analysis. The study variables were measured in 3D reconstructed sacra at the workstation. A coronal section of the sacrum was taken after aligning the L5-S1 disc space horizontally. The cc or vertical (cc-S1c, cc-S2c, cc-S3c) dimensions were recorded in the coronal section (Fig. 1). The axial section (Fig. 2) of the sacral segments was taken to measure the ap dimension (ap-S1c, ap-S2c, and ap-S3c) in the path of the bony corridor.

Study variables

The present study focussed on the cc and ap dimensions of the Sc. Other parameters, e.g., L, TSD-1, TSD-2, and ISD-1, were taken to assess the correlation among the sacral variables. The study variables are listed in (Table 1). Specific points for each of the given measurements are defined. Each measurement was made three times, and the mean value was considered for further evaluation.

Statistical analysis

The statistical analysis was conducted with the help of Microsoft Excel 2007 and statistical package R Version 4.3.0. The Shapiro–Wilks test was used to analyze the distribution of each data set into parametric and nonparametric data. Parametric data were analyzed using the independent sample *t*-test for sex comparison and comparison between normal vs. LSTV. Nonparametric data were analyzed using the Mann–Whitney U-test. The descriptive statistics of the study variables were calculated (i.e., median and interquartile range) (Table 2). Spearman’s correlation coefficient was used to determine the possible correlation between the parameters (Fig. 3). The Kruskal–Wallis H-test was applied to compare the dimensions of Sc at the upper three sacral segments.

Results

The sample’s median age is 43 years (age range, 18–85 years). In the given sample, there are 91 males and 89 females. The median age of the male sample was 44 years, with an interquartile range of 31.0 years (range, 18–82 years), and the median age of the female sample was 41 years, with an

Table 2. Descriptive statistics of the upper three sacral segments (based on sex, normal/lumbosacral transitional vertebra)

	N	Age (yr)	cc-S1c (mm)	ap-S1c (mm)	cc-S2c (mm)	ap-S2c (mm)	cc-S3c (mm)	ap-S3c (mm)	TSD-S1 (mm)	TSD-S2 (mm)	ISD-S1 (mm)	L
Total	180	43.00 (32.00), 18–85	18.252 (3.692)	17.119 (4.798)	10.741 (2.992)	11.142 (2.785)	6.133 (2.068)	8.235 (2.052)	145.960 (13.755)	124.862 (13.374)	69.907 (6.531)	101.998 (14.642)
Male	91	44.00 (31.00), 18–82	18.874 (3.62)	17.747 ^{a,†} (4.702)	10.957 (2.836)	11.566 ^{a,†} (2.783)	6.258 (2.226)	8.673 ^{a,†} (2.353)	144.946 (13.369)	123.415 (13.377)	69.206 (6.590)	103.854 ^{a,†} (13.576)
Female	89	41.00 (31.00), 18–85	17.987 (3.216)	16.448 ^{a,†} (3.929)	10.438 (2.941)	10.763 ^{a,†} (2.857)	5.992 (1.874)	7.642 ^{a,†} (1.761)	146.563 (13.995)	127.642 (12.347)	70.137 (6.225)	97.623 ^{a,†} (13.840)
Normal	154	44.00 (30.75), 18–82	18.300 (3.565)	17.119 (4.480)	10.867 (2.874)	11.186 (2.698)	6.200 (2.069)	8.289 (1.989)	146.556 (13.984)	126.362 (13.396)	70.146 (6.537)	101.551 (14.187)
LSTV	26	36.500 (29.75), 18–85	17.849 (4.018)	17.474 (8.097)	9.492 (3.207)	10.666 (3.495)	5.906 (1.934)	7.538 (2.257)	142.359 (16.750)	122.174 (11.749)	67.465 (5.621)	103.296 (15.377)

Values are presented as median (IQR), range or median (IQR). Mann–Whitney U-test. LSTV, lumbosacral transitional vertebra; IQR, interquartile range. The abbreviations’ full term see Table 1. ^a*P*<0.05. [†]*P*=0.013. ^b*P*=0.0011. ^{††}*P*<0.0001. ^{†††}*P*<0.00016.

interquartile range of 31.0 years (range, 18–85). A total of 154 sacra are normal (median age, 44 years [range, 18–82 years]), and the rest are LSTV (median age, 36.5 years [range 18–85 years]). The first corridor provided the maximum space (vertical and ap) compared to the others (Table 2). The details of descriptive statistics are given in (Table 2).

Effect of the age

There is no significant correlation between age and Sc parameters.

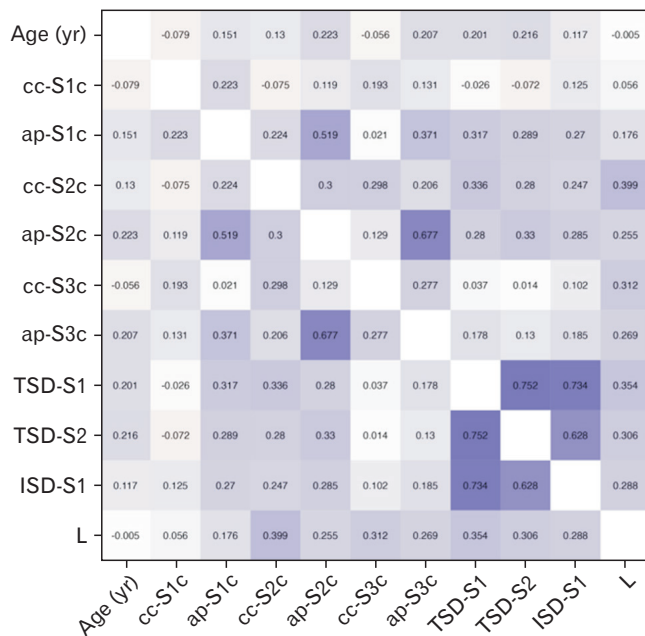


Fig. 3. Shows “Spearman’s correlation (Rho) heatmap” among variables. All significant values are shown in the gradient of blue shades. The abbreviations’ full term see Table 1.

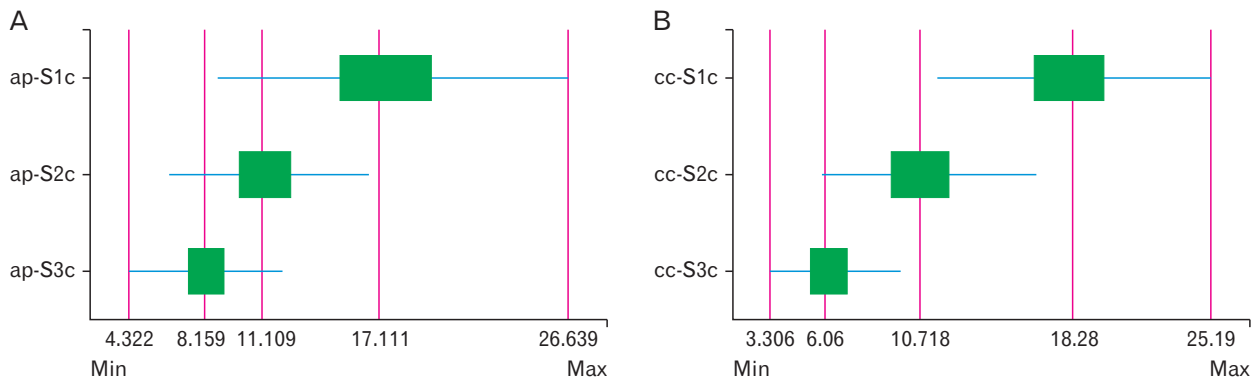


Fig. 4. Shows boxplot (A) significant difference among anteroposterior corridor dimensions. (B) Significant difference among the cephalocaudal corridor dimensions. Green box, 95% confidence interval; red vertical line, median value; blue horizontal line, range. Min, minimum value; Max, maximum value. The abbreviations’ full term see Table 1.

Effect of sex

The ap diameter of the Sc at the S1, S2, and S3 are significantly higher in males ($P=0.013$, 0.0011 , and <0.0001 , respectively). The sacral length was also significantly higher in males ($P=0.00016$; Table 2).

Difference between normal and lumbosacral transitional vertebra

No significant difference was observed between the normal and LSTV sacra in the present sample.

Relations among the variables

The relationship among the variables is shown in Spearman’s correlation (Rho) heatmap (Fig. 3). The ap-S2c correlated moderately with ap-S1c ($R=0.519$, $P<0.001$). In addition, ap-S2c exhibited a moderate correlation to ap-S3c ($R=0.677$, $P<0.001$). All significant values are shown in the gradient of the blue shade.

The difference in sacral corridor dimension

There is a significant difference between the cc dimensions (cc-S1c, cc-S2c, and cc-S3c) and ap dimensions (ap-S1c, ap-S2c, and ap-S3c) of the Scs (Fig. 4).

Discussion

“Safe zone” is the area within the sacrum where the screw can be ideally placed to fix the fractured sacral segments without damaging the nerve roots and vessels lying in its vicinity. To pass a screw safely without a cortical breach, it must traverse the ipsilateral and contralateral osseous corridor, which must be of sufficient size [3, 10]. In the present

study, S1c had the maximum corridor space, followed by S2c and S3c. The corridor space in normal sacra and LSTV showed no significant difference ($P>0.05$). The S3c is the least preferable corridor for the screw placement. The ap diameter of all three corridors showed sexual dimorphism ($P=0.013$, 0.0011 , and <0.0001). The length of the sacrum also showed significant differences among males and females ($P<0.00016$). The ap dimension of the second sacral corridor (ap-S2c) has a moderate correlation with ap-S1c ($R=0.519$) and ap-S3c ($R=0.677$).

In time, authors have detailed the morphological divergences of the sacrum and its developmental malformations [1, 11]. These variations could change the symptoms and the surgical techniques during operations [8, 12]. The lumbosacral junction is one of the most variable regions of the spinal column. When the fifth lumbar vertebra (L5) fuses to the first sacral segment (S1), it is called sacralization of the lumbar. In contrast, the fusion of S1 to the L5 is known as the lumbarization of the sacrum. The LSTV includes sacralized L5 and lumbarized S1 [4]. The vertebral body develops by combining the caudal part of the sclerotome above and the cranial part of the sclerotome below. The intervertebral disc is formed by the mesenchymal cells. However, during the development, a variable fusion pattern between the caudal lumbar vertebra and the upper sacral segment has been observed [12]. Based on a study by Woods et al. [13], the corridor at the level of the first sacral body may be narrow or absent. Authors have reported a high rate of neurological complications during screw fixation. It is due to difficulty visualizing the complex anatomy of the upper sacral segments [9]. In the current study, the cc and ap diameter of the upper three sacral segments have been accurately determined in both normal and LSTV sacra. The surgeons should keep this data in mind to avoid errant screw placement and neurovascular injury. Some published data regarding the Sc's critical dimensions are available in the literature with varying results. The reported dimension varies greatly among researchers and populations (Table 3). Wagner et al. [3] considered >12 mm an adequate corridor. They found 48% adequate (non-critical) corridor at the S1 level and 79% at the S2 level in the European and Japanese populations. In the present sample, 97.2% of the corridor at the S1 level and 29.4% at the S2 level were adequate. The results of Keereewan et al. [14] showed that all sacral dimensions of males were larger than those of females. Trikha et al. [6] reported that the cc and ap diameters were significantly higher in males at the S1c level (Table

3). The present study found no significant difference between males and females in the cc dimension (Table 2). Other authors also did not find a similar difference [3, 5, 15]. Trikha et al. [6] might have observed the difference due to a lower sample size. However, the ap diameter was significant at all three sacral levels (*i.e.*, ap-S1c, ap-S2c, and ap-S3c) (Table 2). Age-related changes in vertebral dimensions have been mentioned by some authors [16]. The increase in vertebral body size among the elderly population due to periosteal apposition is a notable observation made by Junno et al. [16]. This (periosteal apposition) results in increased cross-sectional area (CSA) of the vertebral body. These changes are observed to be sex-specific, as a marked increase in CSA of the vertebral body is found only in elderly males. Our findings align with the results of Junno et al. [16] up to a certain extent. In the present study, the significant ap dimensions among the sexes may be due to the increased CSA in males. Understanding the age-related changes in vertebral dimensions becomes crucial for addressing implications for spinal health and function in elderly individuals. In the population aged 50 years or older, the prevalence of osteoporosis was reported to be 21% in females and 6% in males. Osteoporosis does reduce bone mineral density, leading to pelvic fractures in elderly females [17]. We agree with the authors, but age does not affect the Sc dimension according to our observation in the present study. In a study by Iga [15], 40.5% of the Japanese sample had adequate horizontal corridors (*i.e.*, >10 mm) in S1 and 69% in S2. The rest of the sample had less than 10 mm (inadequate) of dimension in S1 (59.5%) and S2 level (31%). The present study shows that S1c is appropriate for screw placement in 97.8% of males and 96.6% of females. The S2c allows safe space only in 34% and 24% of Indian males and females, respectively.

The data belongs to the north Indian region, so it may not be generalized to other populations. This is the limitation of this study. The corridor dimensions were measured by one observer. Therefore, interobserver reliability is not provided. We have not included the fractured sacrum in this study, which could have altered the result. In the present study, morphometry was done in a three-dimensional reconstructed image. Whereas in hospitals, two-dimensional images are commonly used. A comparative study with other populations was not done due to a lack of data.

In conclusion, S1c has the largest cc and ap diameter in the Indian population. The ap diameter of the corridor at S1c, S2c, and S3c levels was significant among males and fe-

Table 3. Comparison of sacral corridors and their adequacy in different population

Sl no.	Author	Population	Corridor	Number	Adequate/non-critical	Inadequate/critical	P-value		
1.	Wagner et al. [3]	European & Japanese	cc-S1c	Total (n=156)	75 (48)	81 (52)	0.06		
				Male (n=79)	44 (55)	35 (45)*			
				Female (n=77)	31 (40)	46 (60)*			
			cc-S2c	Total (n=156)	123 (79)	33 (21)		0.01	
				Male (n=79)	68 (86)	11 (14)*			
				Female (n=77)	55 (71)	22 (29)*			
2.	Gras et al. [5] ^{a)}	European	S1	Total (n=280)	191 (68)	89 (32)			
			S2	Total (n=280)	245 (88)	35 (12)			
3.	Iga [15] ^{b)}	Japanese	S1	Total (n=42)	17 (40)	21 (50)			
			S2	Total (n=42)	29 (69)	13 (31)			
4.	Tripathi et al. [6]	Indian	S1	Male (n=70)*	70 (100)	-	<0.005		
				Female (n=35)*	35 (100)	-			
			S2	Male (n=70)	42.9	57.1		0.93	
				Female (n=35)	25.7	74.3			
5.	Present study	Indian	cc-S1c	Total (n=180)	175 (97.2)	5 (2.8)	0.06		
				Male (n=91)	89 (97.8)	2 (2.2)			
				Female (n=89)	86 (96.6)	3 (3.4)			
			cc-S2c	Total (n=180)	53 (29.4)	127 (70.6)		0.09	
				Male (n=91)	31 (34.1)	60 (65.9)			
				Female (n=89)	22 (24.7)	67 (75.3)			
			cc-S3c	Total (n=180)	1 (0.6)	179 (99.4)			0.155
				Male (n=91)	0 (0.0)	91 (100)			
				Female (n=89)	1 (1.1)	88 (98.9)			

Values are presented as number (%) or percentage only. The abbreviations' full term see Table 1. ^{a)}Diameter threshold set at 9 mm. ^{b)}>10 mm width considered as adequate in both coronal and axial image. * $P<0.05$.

males ($P<0.05$). The length of the sacrum also showed sacral dimorphism ($P<0.05$). The screw can be placed in the first sacral segment taking the safe margin in both LSTV and normal sacra, avoiding cortical breach and neurovascular damage. Knowledge of the adequacy of the corridor is helpful to orthopedic surgeons for placing screws during the fixation of the sacral fracture.

ORCID

Binita Chaudhary: <https://orcid.org/0000-0002-1922-7630>

Prem Kumar: <https://orcid.org/0000-0001-9125-7669>

Ruchika Narayan: <https://orcid.org/0000-0001-5569-7499>

Adil Asghar: <https://orcid.org/0000-0002-1404-1298>

Padamjeet Panchal:

<https://orcid.org/0000-0002-4624-6853>

Neelam Kumari: <https://orcid.org/0000-0002-9182-2784>

Author Contributions

Conceptualization: BC, PK, AA, PP. Data acquisition: BC, PK, RN, NK. Data analysis or interpretation: BC, RN, AA. Drafting of the manuscript: BC, RN, AA, PP. Critical revision of the manuscript: BC, PK, AA, RN, PP, NK. Approval of the final version of the manuscript: all authors.

Conflicts of Interest

No potential conflict of interest relevant to this article was reported.

Funding

None.

Acknowledgements

The authors acknowledge Md Shamshad Ansari, a 3D

artist, and Mr. Ravikant, a 3D Lab application engineer, for reconstructing the sacra.

References

1. Nastoulis E, Karakasi MV, Pavlidis P, Thomaidis V, Fiska A. Anatomy and clinical significance of sacral variations: a systematic review. *Folia Morphol* 2019;78:651-67.
2. Routt ML Jr, Simonian PT, Agnew SG, Mann FA. Radiographic recognition of the sacral alar slope for optimal placement of iliosacral screws: a cadaveric and clinical study. *J Orthop Trauma* 1996;10:171-7.
3. Wagner D, Kamer L, Sawaguchi T, Geoff Richards R, Noser H, Uesugi M, Ossendorf C, Rommens PM. Critical dimensions of trans-sacral corridors assessed by 3D CT models: relevance for implant positioning in fractures of the sacrum. *J Orthop Res* 2017;35:2577-84.
4. Paik NC, Lim CS, Jang HS. Numeric and morphological verification of lumbosacral segments in 8280 consecutive patients. *Spine* 2013;38:E573-8.
5. Gras F, Gottschling H, Schröder M, Marintschev I, Hofmann GO, Burgkart R. Transsacral osseous corridor anatomy is more amenable to screw insertion in males: a biomorphometric analysis of 280 pelves. *Clin Orthop Relat Res* 2016;474:2304-11.
6. Trikha V, Gaba S, Kumar A, Mittal S, Kumar A. Safe corridor for iliosacral and trans-sacral screw placement in Indian population: a preliminary CT based anatomical study. *J Clin Orthop Trauma* 2019;10:427-31.
7. Mendel T, Noser H, Wohlrab D, Stock K, Radetzki F. The lateral sacral triangle - a decision support for secure transverse sacroiliac screw insertion. *Injury* 2011;42:1164-70.
8. Kaiser SP, Gardner MJ, Liu J, Routt ML Jr, Morshed S. Anatomic determinants of sacral dysmorphism and implications for safe iliosacral screw placement. *J Bone Joint Surg Am* 2014;96:e120.
9. Gardner MJ, Morshed S, Nork SE, Ricci WM, Chip Routt ML Jr. Quantification of the upper and second sacral segment safe zones in normal and dysmorphic sacra. *J Orthop Trauma* 2010;24:622-9.
10. Mendel T, Noser H, Kuervers J, Goehre F, Hofmann GO, Radetzki F. The influence of sacral morphology on the existence of secure S1 and S2 transverse bone corridors for iliosacroiliac screw fixation. *Injury* 2013;44:1773-9.
11. Chaudhary B, Asghar A, Naaz S, Satyam A. Estimation of the relationship between the sacral hiatus and other dorsal sacral parameters using principle component analysis. *Surg Radiol Anat* 2021;43:1545-54.
12. Miller AN, Routt ML Jr. Variations in sacral morphology and implications for iliosacral screw fixation. *J Am Acad Orthop Surg* 2012;20:8-16.
13. Woods D, Koerner J, Strage K, Chu X, Simon V, Hadeed M, Heare A, Parry JA, Mauffrey C. Defining sacral dysmorphism: what size corridor precludes transsacral screw placement. *J Orthop Trauma* 2022;36:498-502.
14. Keereewan W, Monum T, Prasitwattanaseree S, Mahakanukrauh P. Stature estimation using the sacrum in a Thai population. *Anat Cell Biol* 2023;56:259-67.
15. Iga T. Iliosacral screw corridors in Japanese subjects: a study using reconstruction CT scans. *OTA Int* 2021;4:e145.
16. Junno JA, Paananen M, Karppinen J, Niinimäki J, Niskanen M, Maijanen H, Väre T, Järvelin MR, Nieminen MT, Tuukkanen J, Ruff C. Age-related trends in vertebral dimensions. *J Anat* 2015;226:434-9.
17. Wagner D, Ossendorf C, Gruszka D, Hofmann A, Rommens PM. Fragility fractures of the sacrum: how to identify and when to treat surgically? *Eur J Trauma Emerg Surg* 2015;41:349-62.