

## Side-opening cutting forceps and esophageal lamina propria yield in pediatric patients with eosinophilic esophagitis

Adam T. Cardullo, Jacob O. Robson

Department of Pediatrics, Pediatric Gastroenterology, Hepatology, and Nutrition, University of Utah Health, Primary Children's Hospital, Salt Lake City, UT, USA

Eosinophilic esophagitis (EoE) is an increasingly recognized local inflammatory condition of the esophagus. Although EoE is defined and tracked by the number of eosinophils in the esophageal epithelium, lamina propria fibrosis is also considered a specific finding for EoE.<sup>1</sup> Fibrosis of the esophageal lamina propria (ELP) is thought to contribute to disease symptoms and severe sequelae, specifically early-onset esophageal fibrostenosis, dysmotility, and esophageal food impactions. It is unknown why some pediatric cases of EoE rapidly progress to esophageal fibrosis, but the fibrostenotic phenotype often requires more aggressive EoE management and serial esophageal dilations. Tissue biopsies in children are evaluated for ELP in only about 50% of cases, making it difficult to classify the degree of fibrosis and track the response of ELP fibrosis to treatment.<sup>2</sup> However, an adult study reported that side-opening cutting forceps increased the ELP diagnostic yield to >90%.<sup>3</sup> Thus, this pilot study used these side-opening forceps to assess the safety and yield of ELP in pediatric patients with known EoE. Our hypothesis was that the side-opening forceps would: (1) safely yield better oriented esophageal tissue biopsies compared to single-use alligator jaw forceps; and (2) enable the more reliable and informative assessment of ELP by histopathologists.

Over a 6-month study period, consecutive patients with previously diagnosed EoE were invited to participate in this study. All patients were under the care of the Primary Children's Hospital Food Allergies and Eosinophilic Disorders Program and recommended upper endoscopy with biopsy to assess the current EoE status. This study received approval from the institutional review board of Intermountain Primary Children's Hospital, University of Utah (No. 00106544) and all patients or their legal guardian provided informed consent. After obtaining informed consent, we used side-opening rounded-cup cutting forceps (FB-45Q-1; Olympus) (Fig. 1) to obtain esophageal biopsies during the upper endoscopy. All biopsies were obtained by a single gastroenterologist with expertise in pediatric EoE (JOR). During the endoscopy, a visual esophageal assessment was performed using the endoscopic reference score (EREFs).<sup>4</sup> Biopsies were obtained via the "turn and suction" method in which the side-opening forceps were appropriately oriented in the esophageal lumen, the flexible upper endoscope was turned toward the esophageal wall (to focus on areas of apparently active EoE based on visual hallmarks), and the endoscope suction was positioned so that the esophageal mucosa was sucked up toward the forceps before their closure.<sup>5</sup> Postoperatively, the patients' charts were reviewed for complications (pain, dysphagia, significant bleeding). All patients received a standard postoperative phone check within 48 hours by a trained endoscopy staff. Clinical pathologists reviewing biopsies were not alerted to the use of side-opening forceps and gave standard histopathology reports, including eosinophils per high-power field (HPF). As published previously, histologic analyses at our hospital are performed with a microscope (BX50; Olympus) with an HPF area of 0.309 mm<sup>2</sup>.

Over the study period, 27 children with previously diagnosed

Received: December 10, 2022    Revised: March 21, 2023  
Accepted: March 29, 2023

**Correspondence:** Adam T. Cardullo  
Department of Pediatrics, Pediatric Gastroenterology, Hepatology, and Nutrition, University of Utah Health, Primary Children's Hospital, 81 N. Mario Capecchi Drive, Salt Lake City, UT 84113, USA  
**E-mail:** Adam.cardullo@hsc.utah.edu

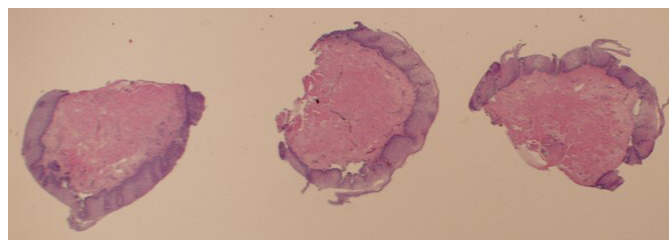
© This is an Open Access article distributed under the terms of the Creative Commons Attribution Non-Commercial License (<http://creativecommons.org/licenses/by-nc/4.0/>) which permits unrestricted non-commercial use, distribution, and reproduction in any medium, provided the original work is properly cited.

EoE were enrolled. There were 21 male patients (77.8%) in this study. The average age at diagnosis was (the authors should provide the age) years old.<sup>6</sup> At least four esophageal biopsies were obtained from each patient, and the tissue was adequate for standard histologic assessment for all participants. Active EoE was identified in just over half of the patients, with 75% of those cases having adequate ELP for assessment. Fibrosis was identified in 82% of those in whom ELP was present. **Figure 2** displays a well-oriented esophageal biopsy specimen with active EoE and abundant ELP with significant fibrosis. This result was characteristic of most study specimens obtained from patients with active EoE. Both of the children with active EoE but no ELP fibrosis were receiving medical and diet therapy for EoE. ELP was not mentioned in the pathology reports of any of the 12 patients with remitted EoE. Patients with fibrosis had higher EREFS, and three patients with ELP fibrosis had rings or other evidence of abnormal esophageal architecture (stenosis or stricture). There were no concerns reported by any of the 27 participants or their parents during the postoperative phone check-ins. There were no adverse events attributed to use of the side-opening forceps.

This pilot study found that side-opening biopsy forceps were



**Fig. 1.** The Olympus FB-45Q-1 forceps used in this study require a 2.2-mm working channel.



**Fig. 2.** Histopathology results obtained via side-opening round cups forceps (hematoxylin and eosin stain,  $\times 40$ ).

used safely in pediatric patients with EoE and reliable for obtaining stratified squamous epithelium samples for histopathologic assessment. Using side-opening forceps, the ELP yield in patients with active EoE was higher than previously reported.<sup>2</sup> This increased ELP yield allowed for comparison between ELP fibrosis and EREFS, which was notable (**Table 1**). Moreover, side-opening forceps are reusable, which lessens the endoscopy carbon footprint.<sup>7</sup> Their use also may confer significant cost savings for EoE patients who require repeated esophagoscopy and may be charged for single-use disposable forceps. Single-use forceps do not require processing, do not dull over time, and carry a significantly lower infection risk than reusable forceps.

Our study's limitations include its small sample size from a single center. However, in reviewing these samples with our chief histopathologist, there is reason for optimism. As reported by Bussmann et al.<sup>3</sup> in adults, the use of side-opening forceps in pediatric patients appeared to cause less tissue trauma (less tissue ripping and crushing) than the standard alligator jaw biopsy forceps, producing more consistently well-oriented biopsy samples. The factors that can influence increased yield of the side-opening forceps versus alligator jaw forceps include orienting the mobile open side perpendicular to the mucosa followed by suction, allowing for the cutting action of the forceps to penetrate deeper into the lamina propria as they are closed. Also, the cutting action likely contributes to smoother, more distinct margins of specimens compared to torn or smashed tissue specimens that are obtained by the two sets of gripping teeth of alligator forceps. There is likely a learning curve for the individual endoscopist in terms of proficiency with using the side-opening

**Table 1.** Side-open forceps biopsy results

Patient data	Active EoE (n=15)	Remitted EoE (n=12)
Age at diagnosis (mean, yr)	5.07	6.33
Age at study endoscopy (mean, yr)	8.73	9.25
Male	13 (86.7)	8 (66.7)
Peak eosinophils/high-power field (mean)	57	2
LP noted as present in pathologic report	11 (73.3)	0
LP reported to be fibrotic in pathologic report	9 (81.8)	0
EREFS if fibrosis present (mean)	4.67	N/A
EREFS if fibrosis absent (mean)	3	0.58

Values are presented as number (%).

EoE, eosinophilic esophagitis; LP, lamina propria; EREFS, endoscopic reference score; N/A, not applicable.

forceps that may contribute to ELP yield.

A common goal for EoE therapy is to reduce eosinophil inflammation, specifically to peak eosinophil counts <15/HPF, the threshold value that defines active EoE disease. However, our next goal is to study the correlation between ELP findings and patient-reported outcomes and other clinical metrics, specifically utilizing the pediatric EoE symptoms scores v2.0 (PEESS v2.0) questionnaire (which focuses on primary symptoms of dysphagia, pain, gastroesophageal reflux disease, nausea, and vomiting),<sup>8</sup> the Pediatric Quality of Life Inventory Eosinophilic Esophagitis Module,<sup>9</sup> and esophageal distensibility and measurement data obtained via the endoscopically obtained functional luminal imaging probe.<sup>10</sup> With exception of the dysphagia symptom domain, esophageal eosinophil counts do not match PEES severity particularly well<sup>4</sup>; thus, we intended to explore whether ELP fibrosis may correlate better with more severe symptoms, which would highlight ELP as a key pediatric EoE treatment target. Obtaining ELP biopsy samples for every patient could result in better individualized treatments resulting in better patient-centered outcomes as well as the determination of future treatment policies or prediction of prognosis. Future studies should focus on the use of side-opening forceps in larger pediatric cohorts (including intrasubject repeated measures in treated patients), with specific attention paid to which treatments have the greatest ability to resolve ELP fibrosis in those with early evidence of this issue.

In summary, side-opening cutting forceps are safe to use and appear more reliable for obtaining esophageal biopsy samples of ELP for determining fibrosis versus standard pediatric alligator jaw biopsy forceps in pediatric patients with active EoE.

### Conflicts of Interest

The authors have no potential conflicts of interest.

### Funding

This study received funding in the form of a North American Society for Pediatric Gastroenterology, Hepatology, and Nutrition (NASPGHAN) Innovations in Clinical Care Grant.

### Author Contributions

Conceptualization: JOR; Data curation: all authors; Formal analysis: all authors; Funding acquisition: JOR; Investigation: all authors; Methodology: JOR; Project administration: JOR; Resources: JOR; Supervision: JOR; Validation: all authors; Visualization: all authors; Writing—original draft: all authors; Writing—review & editing: all authors.

### ORCID

Adam T. Cardullo <https://orcid.org/0000-0002-2976-8668>  
Jacob O. Robson <https://orcid.org/0000-0002-9899-6963>

### REFERENCES

1. Parfitt JR, Gregor JC, Suskin NG, et al. Eosinophilic esophagitis in adults: distinguishing features from gastroesophageal reflux disease: a study of 41 patients. *Mod Pathol* 2006;19:90–96.
2. Wang J, Park JY, Huang R, et al. Obtaining adequate lamina propria for subepithelial fibrosis evaluation in pediatric eosinophilic esophagitis. *Gastrointest Endosc* 2018;87:1207–1214.
3. Bussmann C, Schoepfer AM, Safroneeva E, et al. Comparison of different biopsy forceps models for tissue sampling in eosinophilic esophagitis. *Endoscopy* 2016;48:1069–1075.
4. Wechsler JB, Bolton SM, Amsden K, et al. Eosinophilic esophagitis reference score accurately identifies disease activity and treatment effects in children. *Clin Gastroenterol Hepatol* 2018;16:1056–1063.
5. Levine DS, Reid BJ. Endoscopic biopsy technique for acquiring larger mucosal samples. *Gastrointest Endosc* 1991;37:332–337.
6. Dellon ES, Jensen ET, Martin CF, et al. Prevalence of eosinophilic esophagitis in the United States. *Clin Gastroenterol Hepatol* 2014;12:589–596.
7. Siau K, Hayee BH, Gayam S. Endoscopy's current carbon footprint. *Tech Innov Gastrointest Endosc* 2021;23:344–352.
8. Martin LJ, Franciosi JP, Collins MH, et al. Pediatric Eosinophilic Esophagitis Symptom Scores (PEESS v2.0) identify histologic and molecular correlates of the key clinical features of disease. *J Allergy Clin Immunol* 2015;135:1519–1528.
9. Franciosi JP, Hommel KA, Greenberg AB, et al. Development of the Pediatric Quality of Life Inventory™ Eosinophilic Esophagitis module items: qualitative methods. *BMC Gastroenterol* 2012;12:135.
10. Menard-Katcher C, Benitez AJ, Pan Z, et al. Influence of age and eosinophilic esophagitis on esophageal distensibility in a pediatric cohort. *Am J Gastroenterol* 2017;112:1466–1473.