

Relevance of the Watson–Jones anterolateral approach in the management of Pipkin type II fracture–dislocation: a case report and literature review

Nazim Sifi, MD , Ryad Bouguenna, MD 

Orthopaedic and Trauma Surgery Unit, EPH Beni Abbes, Beni Abbes, Algeria

Femoral head fractures with associated hip dislocations substantially impact the functional prognosis of the hip joint and present a surgical challenge. The surgeon must select a safe approach that enables osteosynthesis of the fracture while also preserving the vascularization of the femoral head. The optimal surgical approach for these injuries remains a topic of debate. A 44-year-old woman was involved in a road traffic accident, which resulted in a posterior iliac dislocation of the hip associated with a Pipkin type II fracture of the femoral head. Given the size of the detached fragment and the risk of incarceration preventing reduction, we opted against attempting external orthopedic reduction maneuvers. Instead, we chose to perform open reduction and internal fixation using the Watson-Jones anterolateral approach. This involved navigating between the retracted tensor fascia lata muscle, positioned medially, and the gluteus medius and minimus muscles, situated laterally. During radiological and clinical follow-up visits extending to postoperative month 15, the patient showed no signs of avascular necrosis of the femoral head, progression toward coxarthrosis, or heterotopic ossification. The Watson-Jones anterolateral approach is a straightforward intermuscular and internervous surgical procedure. This method provides excellent exposure of the femoral head, preserves its primary vascularization, allows for anterior dislocation, and facilitates the anatomical reduction and fixation of the fracture.

Received: January 27, 2024

Accepted: April 29, 2024

Correspondence to

Nazim Sifi, MD

Orthopaedic and Trauma Surgery Unit,

EPH Beni Abbes, Route de l'Hopital,

Beni Abbes 8002, Algeria

Tel: +213-50-53-50-73

Email: sifinazimjamil@gmail.com

Keywords: Hip dislocation; Femoral head fracture; Pipkin classification; Watson-Jones approach; Case reports

INTRODUCTION

Femoral head fracture associated with posterior hip dislocation is an uncommon injury that results from high-energy trauma, often occurring in road traffic accidents. This injury constitutes a therapeutic emergency, and its management can be challenging.

Achieving anatomical restoration of joint congruity is essential, requiring the reduction of both the dislocation and the fracture before securing stable fracture fixation. This must be accomplished while minimizing the risk of additional injury or femoral head ischemia. Selection of the optimal treatment approach is critical and remains a topic of debate.

CASE REPORT

A 44-year-old woman was involved in a road traffic accident, resulting in an isolated and closed trauma to her left hip. Clinical examination revealed a malposition of the left lower limb, characterized by hip flexion, adduction, and internal rotation, with palpation of the femoral head in the gluteal region (Fig. 1). No signs of sciatic nerve injury were evident, and distal pulses were present. Radiological assessment revealed a posterior iliac dislocation of the hip, associated with a fracture of the femoral head. This fracture detached a fragment, constituting approximately one-third of the sphere and encompassing the fovea of the round ligament. The injury was classified as a Pipkin type II fracture (Fig. 2). Due to the size of the detached fragment and the risk of incarceration preventing reduction, we avoided external orthopedic reduction maneuvers. Such a procedure could have exposed this young patient to the risk of iatrogenic fracture of the femoral neck, complicating treatment and increasing the risk of avascular necrosis (AVN) of the femoral head. Instead, we opted for the Watson-Jones anterolateral approach, positioning the patient in

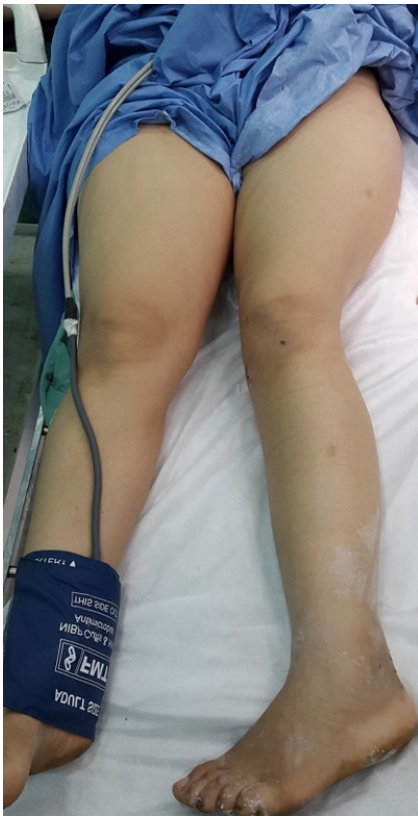

Fig. 1. Clinical photograph of the patient showing malposition of the left lower limb, with the hip in flexion, internal rotation, and adduction.

lateral decubitus under general anesthesia. Our approach passed between the retracted tensor fascia lata muscle, positioned medially, and the gluteus medius and minimus muscles, situated laterally. After reducing the dislocation, we dislocated the distal fragment of the femoral head via flexion and external rotation maneuvers of the lower limb to precisely assess the injury. The proximal fragment was confirmed to be viable and exhibited bleeding during the wire test. We repositioned the femoral head in alignment with its proximal fragment, which was left in place and attached to the round ligament. Our reduction was stabilized with two Kirschner wires. Notably, some surgeons opt to cut the round ligament to facilitate interfragmentary reduction.

Subsequently, due to the unavailability of suitable screws, we performed definitive fixation using two 3.5-mm cortical screws. We oriented these laterally to medially and introduced them at the proximal part of the femoral neck, as perpendicular as possible to the fracture line, adopting crossed directions for increased rotational stability. Additionally, we buried the screw heads (Fig. 3). We ensured that the screws were of sufficient length to reach the subchondral region without protruding, particularly in weight-bearing areas. No postoperative neurological deficit was observed, and radiographs depicted a well-aligned fracture with properly positioned screws (Fig. 4). The patient was referred for functional rehabilitation with immediate hip mobilization in all ranges and gradual weight-bearing from the 6th week onwards. No prophylactic medication for heterotopic ossification was prescribed. Fracture consolidation was achieved by the 8th week. During radiological and clinical follow-ups extending to postoperative month 15, no signs of AVN of the femoral head, progression toward coxarthrosis, or heterotopic ossification (HO) were observed. At the final follow-up, the patient exhibited very good

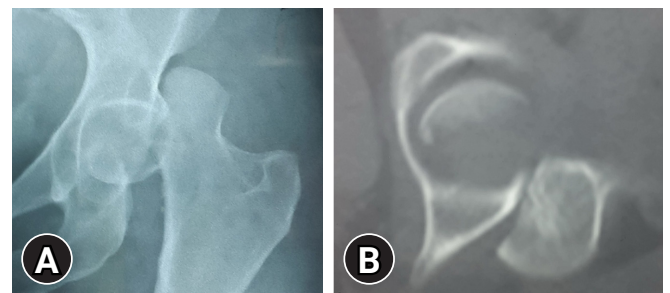


Fig. 2. Radiological images. (A) Anteroposterior x-ray of the hip revealing posterior hip dislocation accompanied by Pipkin type II fracture. (B) Axial computed tomography scan showing the posterior hip dislocation and the fractured femoral head fragment, which remained in the acetabulum.

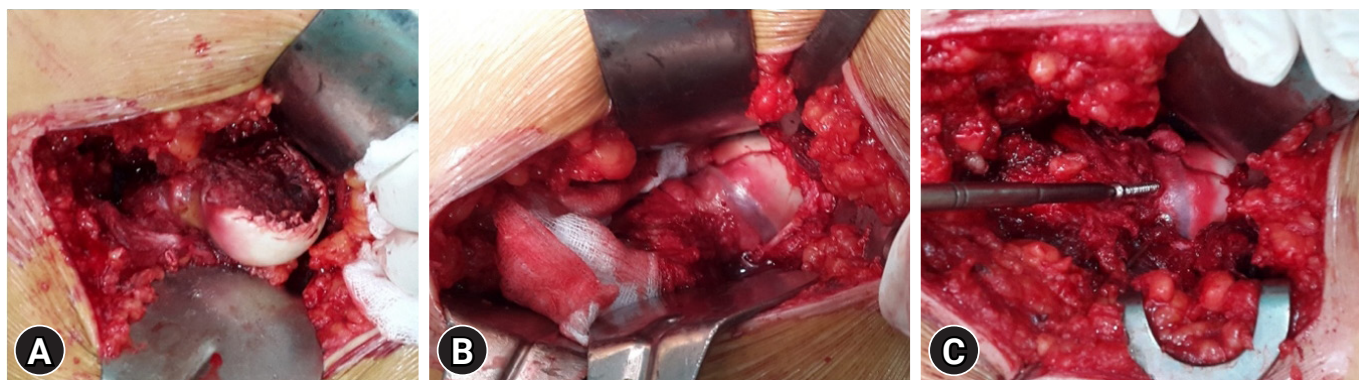

Fig. 3. Intraoperative photographs of (A) fractured femoral head, (B) reduction, and (C) fixation.

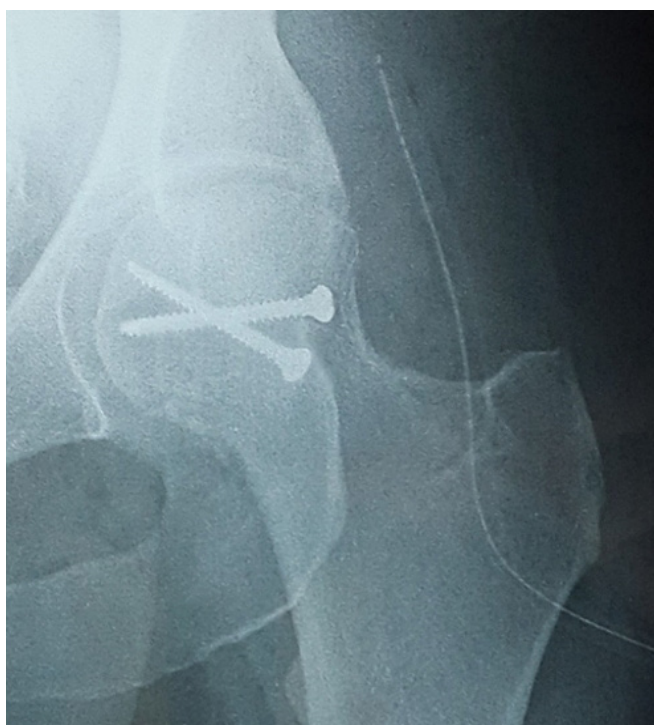


Fig. 4. Postoperative anteroposterior x-ray demonstrating satisfactory anatomical reduction of the fractured femoral head fragment, which was secured with two screws.

outcomes regarding the Merle d'Aubigné-Postel hip score and the Harris hip score (Fig. 5), and the radiological results—represented by the Epstein-Thompson score—were excellent. Nevertheless, the patient was informed about potential progressive complications that could affect her hip, including a risk of AVN, which can manifest up to 5 years posttrauma and could potentially necessitate total hip replacement.

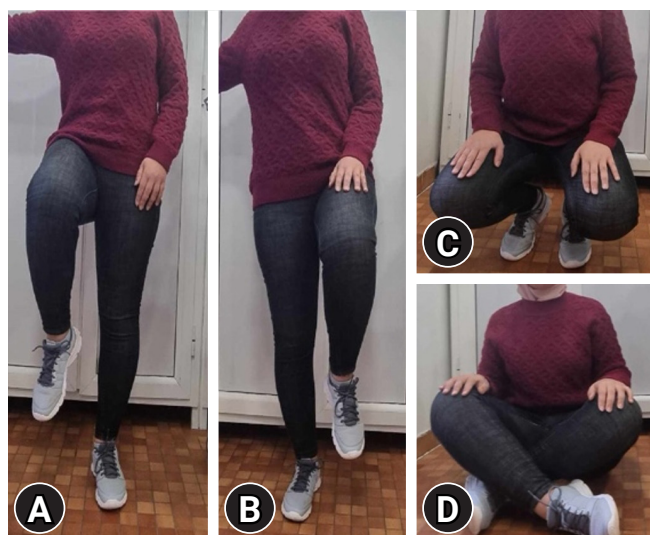

Fig. 5. Excellent functional outcomes observed 15 months after surgery. (A) Monopodal support position. (B) Hip flexion position. (C) Squatting position. (D) Cross-legged position.

Ethics statement

This study was approved by the Scientific Committee and the Medical Council of EPH Beni Abbes (No. CM 07-2022). Written informed consent was obtained from the patient for the publication of this case report and any accompanying images. The study was in accordance with the principles of the 1964 Declaration of Helsinki and its later amendments.

DISCUSSION

Femoral head fractures are serious joint injuries that occur in 6% to 17% of posterior hip dislocations [1,2]. These fracture dislocations result from high-energy trauma and substantially impact the functional prognosis of this crucial joint. They present a consider-

able challenge for surgeons, who must choose a safe approach that allows for osteosynthesis of the fracture while preserving the vascularization of the femoral head. Although consensus supports the prompt performance of dislocation reduction—ideally within the first 6 hours—to minimize the risk of femoral head ischemia and improve functional outcomes [1,3,4], subsequent management depends on various factors. These include patient age, comorbidities, the reducibility of the dislocation, fracture type, suprafoveal or infrafoveal involvement, fragment size and displacement, and the presence of associated injuries [1,5]. Computed tomography (CT), ideally performed after reduction of the dislocation, is crucial for formulating and tailoring the therapeutic strategy. Conservative nonsurgical treatment is rare and is reserved for cases in which CT analysis reveals a small infrafoveal fragment that is anatomically positioned after reduction, in a stable hip without intra-articular fragments requiring excision [6,7]. In contrast, surgical intervention is standard when the fragment is large and/or displaced with an interfragmentary gap exceeding 2 mm [6], or when the fracture line is suprafoveal and involves the weight-bearing area of the femoral head [7]. Various surgical approaches have been employed for managing Pipkin type II fracture dislocations, including anterior (Smith-Peterson), posterior (Kocher-Langenbeck), posterior with trochanteric osteotomy (Ganz), anterolateral (Watson-Jones), lateral (Gibson), and medial (Ludloff/Chiron) techniques. Each approach has advantages and disadvantages. Systematic literature reviews have primarily focused on the posterior and anterior approaches, without conclusively establishing the superiority of either, except for a higher incidence of HO with the anterior approach [8–11]. In light of this, some surgeons prefer the posterior approach with trochanteric osteotomy to minimize detachment of and trauma to the gluteal muscles, thus reducing the occurrence of HO. This technique, associated with anterior surgical dislocation of the femoral head according to the Ganz technique, improves access to the fracture and the entire femoral head [12].

Some experts advocate for a posterior approach in posterior fracture dislocations. They argue that the capsular, muscular, and vascular injuries are already established, and that opting for an anterior approach only adds instability—adversely impacting functional rehabilitation—and could further compromise the vascularization of the femoral head via the anterior vessels of the lateral circumflex femoral artery [3,13]. A posterior approach allows for the repair of soft tissue injuries but provides limited access to the anterior, inferior, and medial quadrants of the fracture due to the interposition of the femoral head. It also carries a significant risk of sciatic nerve damage and destabilization of the

pelvotrochanteric muscles. Others contend that since the anterior vascularization of the femoral head is less critical, an anterior approach avoids exacerbating lesions to the vessels of the medial circumflex femoral artery (MCFA), which are already impacted by traumatic posterior dislocation [6]. Proponents of the posterior approach counter this risk by using the Ganz approach, which preserves the MCFA, shielded by the external obturator muscle [2,5,12]. While the Ganz technique retains the benefits of the anterior approach and theoretically reduces the risk of HO, it also extends the operating time, demands technical expertise, requires additional equipment, and includes a risk of nonunion of the trochanteric fragments. Swiontkowski et al. [8] concluded that the anterior approach is superior to the posterior method in terms of shorter operating time, less blood loss, and better visualization of the fracture. Mostafa et al. [14] found similar advantages with the Ganz approach compared to the posterior approach. The choice of method may also depend on the fragment's location, with some surgeons opting for an anterior approach for anterior or anteromedial fragments and a posterior approach for posterior fragments. The Watson-Jones anterolateral approach is rarely mentioned and is typically associated with femoral neck fractures, making comparisons difficult [1,13]. However, the incidence of AVN of the femoral head is reportedly higher with posterior approaches than with anterior techniques [1,2,9,11]. This could be explained by the findings of Steffen et al. [15], who measured the oxygen concentration at the head-neck junction during the placement of a resurfacing prosthesis and found it preserved with the anterolateral approach but significantly reduced with the posterior approach.

However, these studies are all based on small heterogeneous series, in which the relatively uncommon anterolateral approach is modified and does not always match the description of Watson-Jones. In the systematic review by Giannoudis et al. [6] and meta-analysis by Bettinelli et al. [13], no significant differences between anterior and posterior approaches in terms of functional outcomes, AVN, or HO were found. In the absence of conclusive evidence, we believe the best approach is the one in which the surgeon is most proficient. We regard the Watson-Jones anterolateral approach as a straightforward intermuscular and internervous method that avoids extensive detachments potentially leading to HO. This safe, reliable technique provides adequate exposure of the femoral head while preserving its residual posterior vascularization. Cadaveric studies have confirmed that the primary vascular supply to the femoral head is the ascending branch of the MCFA, with penetrating branches entering the joint capsule at the head-neck junction in its posterosuperior

part—an area unaffected by an anterolateral approach. The Watson-Jones technique also sidesteps concerns associated with a Ganz posterior approach involving an osteotomy that requires synthesis. Additionally, it enables forward dislocation of the head and provides broad exposure to the fracture through flexion and external rotation of the limb, facilitated by the anatomical anteversion of the femoral neck. Moreover, research indicates that it can be useful in the management of certain injuries, such as Pipkin type III femoral neck fractures in young patients, through osteosynthesis induced after screw fixation.

In conclusion, in skilled hands, the Watson-Jones anterolateral approach is a straightforward intermuscular and internervous surgical procedure. This technique offers excellent exposure of the femoral head, preserves its primary vascularization, allows for anterior dislocation, and facilitates the anatomical reduction and fixation of the fracture. Additionally, it avoids the need for a trochanteric osteotomy and the subsequent osteosynthesis required for repair. Therefore, the Watson-Jones approach should be utilized more frequently in the management of Pipkin II femoral head fracture-dislocation.

ARTICLE INFORMATION

Author contributions

Conceptualization: NS; Methodology: all authors; Investigation: all authors; Writing—original draft: NS; Writing—review & editing: all authors. All authors read and approved the final manuscript.

Conflicts of interest

The authors have no conflicts of interest to declare.

Funding

The authors received no financial support for this study.

Data availability

Data sharing is not applicable as no new data were created or analyzed in this study.

REFERENCES

- Sen RK, Tripathy SK, Goyal T, et al. Complications and functional outcome of femoral head fracture-dislocation in delayed and neglected cases. *Indian J Orthop* 2021;55:595–605.
- Hosny H, Mousa S, Salama W. Management of femoral head fracture by Ganz surgical dislocation of the hip. *J Orthop Traumatol* 2022;23:24.
- Sahin V, Karakas ES, Aksu S, Atlihan D, Turk CY, Halici M. Traumatic dislocation and fracture-dislocation of the hip: a long-term follow-up study. *J Trauma* 2003;54:520–9.
- Peng SH, Wu CC, Yu YH, Lee PC, Chou YC, Yeh WL. Surgical treatment of femoral head fractures. *Biomed J* 2020;43:451–7.
- Henle P, Kloen P, Siebenrock KA. Femoral head injuries: which treatment strategy can be recommended? *Injury* 2007;38:478–88.
- Giannoudis PV, Kontakis G, Christoforakis Z, Akula M, Tsounidis T, Koutras C. Management, complications and clinical results of femoral head fractures. *Injury* 2009;40:1245–51.
- Kloub M, Holub K, Pendl M, Urban J, Latal P. Closed reduction and minimally invasive screw osteosynthesis of Pipkin femoral head fractures. *J Appl Biomed* 2023;21:1–6.
- Swiontkowski MF, Thorpe M, Seiler JG, Hansen ST. Operative management of displaced femoral head fractures: case-matched comparison of anterior versus posterior approaches for Pipkin I and Pipkin II fractures. *J Orthop Trauma* 1992;6:437–42.
- Guo JJ, Tang N, Yang HL, Qin L, Leung KS. Impact of surgical approach on postoperative heterotopic ossification and avascular necrosis in femoral head fractures: a systematic review. *Int Orthop* 2010;34:319–22.
- Wang CG, Li YM, Zhang HF, Li H, Li ZJ. Anterior approach versus posterior approach for Pipkin I and II femoral head fractures: a systemic review and meta-analysis. *Int J Surg* 2016;27:176–81.
- Scolaro JA, Marecek G, Firoozabadi R, Krieg JC, Routt ML. Management and radiographic outcomes of femoral head fractures. *J Orthop Traumatol* 2017;18:235–41.
- Ganz R, Gill TJ, Gautier E, Ganz K, Krugel N, Berlemann U. Surgical dislocation of the adult hip: a technique with full access to the femoral head and acetabulum without the risk of avascular necrosis. *J Bone Joint Surg Br* 2001;83:1119–24.
- Bettinelli G, Placella G, Moharamzadeh D, Belluati A, Salini V. Articular femoral head fracture management: a meta-analysis of literature. *Indian J Orthop* 2021;55(Suppl 2):304–13.
- Mostafa MF, El-Adl W, El-Sayed MA. Operative treatment of displaced Pipkin type I and II femoral head fractures. *Arch Orthop Trauma Surg* 2014;134:637–44.
- Steffen R, O'Rourke K, Gill HS, Murray DW. The anterolateral approach leads to less disruption of the femoral head-neck blood supply than the posterior approach during hip resurfacing. *J Bone Joint Surg Br* 2007;89:1293–8.