

# Distribution of the intraosseous branch of the posterior superior alveolar artery relative to the posterior maxillary teeth

Carsen R. McDaniel<sup>1</sup>, Thomas M. Johnson<sup>1,\*</sup>, Brian W. Stancoven<sup>1</sup>, Adam R. Lincicum<sup>1</sup>

<sup>1</sup>Department of Periodontics, Army Postgraduate Dental School, Postgraduate Dental College, Uniformed Services University, Fort Eisenhower, GA, USA

## ABSTRACT

**Purpose:** Preoperative identification of the intraosseous posterior superior alveolar artery (PSAA) is critical when planning sinus surgery. This study was conducted to determine the distance between the cemento-enamel junction and the PSAA, as well as to identify factors influencing the detection of the PSAA on cone-beam computed tomography (CBCT).

**Materials and Methods:** In total, 254 CBCT scans of maxillary sinuses, acquired with 2 different scanners, were examined to identify the PSAA. The distance from the cemento-enamel junction (CEJ) to the PSAA was recorded at each maxillary posterior tooth position. Binomial logistic regression and multiple linear regression were employed to evaluate the effects of scanner type, CBCT parameters, sex, and age on PSAA detection and CEJ-PSAA distance, respectively. *P*-values less than 0.05 were considered to indicate statistical significance.

**Results:** The mean CEJ-PSAA distances at the second molar, first molar, second premolar, and first premolar positions were  $17.0 \pm 4.0$  mm,  $21.8 \pm 4.1$  mm,  $19.5 \pm 4.7$  mm, and  $19.9 \pm 4.9$  mm for scanner 1, respectively, and  $17.3 \pm 3.5$  mm,  $16.9 \pm 4.3$  mm,  $18.5 \pm 4.1$  mm, and  $18.4 \pm 4.3$  mm for scanner 2. No independent variable significantly influenced PSAA detection. However, tooth position ( $b = -0.67$ ,  $P < 0.05$ ) and scanner type ( $b = -1.3$ ,  $P < 0.05$ ) were significant predictors of CEJ-PSAA distance.

**Conclusion:** CBCT-based estimates of CEJ-PSAA distance were comparable to those obtained in previous studies involving cadavers, CT, and CBCT. The type of CBCT scanner may slightly influence this measurement. No independent variable significantly impacted PSAA detection. (*Imaging Sci Dent* 2024; 54: 121-7)

**KEY WORDS:** Maxillary Sinus; Arteries; Cone-Beam Computed Tomography; Dental Implants

## Introduction

Sinus elevation surgery is a common and routine procedure used to increase the volume of bone available for dental implant placement in the posterior maxilla.<sup>1-3</sup> Among the most frequent intraoperative complications of this operation is excessive bleeding, primarily due to surgical trauma to the intraosseous branches of the infraorbital artery and posterior superior alveolar artery (PSAA).<sup>2,4</sup> The PSAA is located within the lateral wall of the maxillary sinus.<sup>2,4</sup> Since

excessive bleeding during surgery is a concern, identifying and (when possible) avoiding the PSAA can decrease morbidity and improve treatment outcomes. Accordingly, multiple studies have described the size, anatomical position, and trajectory of the PSAA. The existing literature on the position of the PSAA can be categorized based on the assessment methodology, including direct observations in human cadaver studies,<sup>4-7</sup> measurements on conventional computed tomography (CT) volumes,<sup>7-10</sup> and measurements on cone-beam computed tomography (CBCT) volumes,<sup>11,12</sup> with the most recent research utilizing CBCT technology.

Solar et al.<sup>4</sup> conducted the first study investigating the locations of both the intraosseous and extraosseous anastomoses of the PSAA and infraorbital artery. This landmark study provided a thorough analysis and description of key aspects of the maxillary sinus vasculature, utilizing 18 human skulls

Received July 24, 2023; Revised February 5, 2024; Accepted February 8, 2024

Published online April 2, 2024

\*Correspondence to : Prof. Thomas M. Johnson

Department of Periodontics, Army Postgraduate Dental School, Postgraduate Dental College, Uniformed Services University, 228 East Hospital Road, Fort Eisenhower, GA 30905, USA

Tel) 1-706-787-6819, E-mail) thomas.m.johnson34.mil@health.mil

Copyright © 2024 by Korean Academy of Oral and Maxillofacial Radiology

This is an Open Access article distributed under the terms of the Creative Commons Attribution Non-Commercial License (<http://creativecommons.org/licenses/by-nc/3.0>) which permits unrestricted non-commercial use, distribution, and reproduction in any medium, provided the original work is properly cited.

Imaging Science in Dentistry · pISSN 2233-7822 eISSN 2233-7830

that were edentulous in the posterior regions.<sup>4</sup> The authors successfully located the PSAA in 100% of the specimens.<sup>4</sup> In a subset of 8 skulls, the investigators measured the vertical distance from the alveolar bone margin to the PSAA.<sup>4</sup> The mean distance from the PSAA to the alveolar ridge at the assessed points was approximately 19 mm.<sup>4</sup>

Hur et al.<sup>5</sup> examined 42 human cadaver specimens of Korean descent. Their report documented the distance from the PSAA to the cervix of the maxillary posterior teeth. The investigators found that the mean distances from the PSAA to the cervix of the first premolar (PM1), second premolar (PM2), first molar (M1), and second molar (M2) were 26.9 mm, 24.1 mm, 21.1 mm, and 22.4 mm, respectively. The authors described the course of the PSAA as either linear or U-shaped, with the U-shaped arteries descending inferiorly near the zygoma.<sup>5</sup> Most arteries followed a linear path, with approximately 20% presenting as U-shaped.<sup>5</sup> The most inferior position of the PSAA was located at the site of the first molar, a finding supported by several other studies.<sup>5-8</sup>

Kqiku et al.<sup>6</sup> examined the relationship between the position of the PSAA and the alveolar ridge in 10 fully dentate human cadaver specimens. Measurements were taken from the buccal alveolar crest adjacent to the retained teeth. The mean bone-PSAA distances reported were 14.6 mm from PM2, 14.5 mm from M1, and 16.6 mm from M2. However, since the study measured the bone-PSAA distance at dentate sites, the values may not accurately represent the position following tooth extraction.

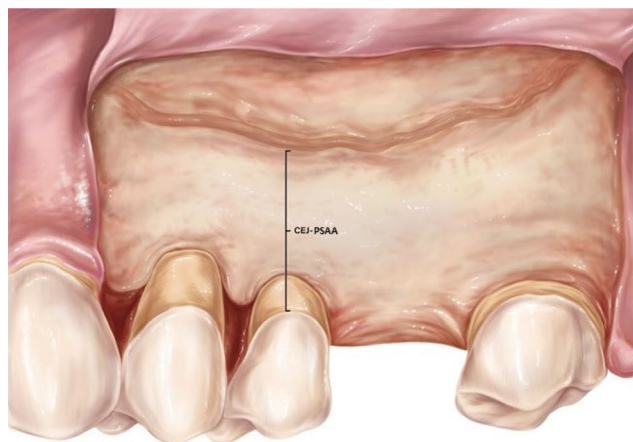
Rosano et al.<sup>7</sup> utilized both human cadaver specimens (n = 15) and conventional CT scans (n = 100) to investigate the minimum distance between the PSAA and the alveolar crest in highly atrophic ridges. In areas where the residual crest height was at least 3 mm, the mean recorded PSAA-crest measurement was 9.3 mm, indicating variability associated with alveolar resorption. In agreement with the findings of Hur et al., the minimum mean distance from the alveolar ridge to the PSAA was observed at the M1 site, with a measurement of 11.25 mm.

In early conventional CT studies, Mardinger et al.<sup>8</sup> and Elian et al.<sup>9</sup> reached similar conclusions regarding the distance from the alveolar ridge to the PSAA. Elian et al.<sup>9</sup> reported a mean distance of 16.4 mm across 50 CT volumes, while Mardinger et al.<sup>8</sup> found a mean distance of 16.9 mm for 114 scans. Consistent with the findings of Rosano et al.,<sup>7</sup> Mardinger et al.<sup>8</sup> observed that the PSAA was more than 15 mm from the alveolar crest in cases of comparatively little resorption, but this distance was approximately 7 mm at sites with a highly resorbed alveolar ridge.<sup>7,8</sup> In an eval-

uation of 101 conventional CT volumes, Rysz et al.<sup>10</sup> measured the distance between the PSAA and the cervical line of the teeth. The artery was identified in only 44% of dentate scans. The mean distances from the cervical line to the PSAA were 20.5 mm at PM1, 18.0 mm at PM2, 18.1 mm at M1, and 20.0 mm at M2.

Kang et al.<sup>11</sup> conducted a pioneering study on this topic using CBCT imaging. The researchers evaluated 150 CBCT volumes and found that the mean distance from the alveolar crest to the inferior border of the PSAA was 17.0 mm. In 31% of cases, this distance was less than 15 mm. The PSAA was identifiable for 64.3% of the CBCT volumes. Apostolakis and Bissoon<sup>12</sup> performed another study involving CBCT in 2014. They examined 156 CBCT volumes, measuring the diameter and position of the PSAA in relation to the maxillary sinus floor. Their study suggested that CBCT provides superior detection of the PSAA compared to previous conventional CT studies. The artery was visualized in 82% of the CBCT volumes assessed; however, it was only detected at the M1 and PM2 sites 40% and 44% of the time, respectively.<sup>12</sup>

CBCT has become the predominant method for preoperative assessment of the maxillary sinus before sinus elevation surgery, with conventional CT now rarely used for this purpose. However, existing CBCT studies have not evaluated the distance between the cemento-enamel junction (CEJ) and the PSAA at maxillary posterior tooth positions (Fig. 1).<sup>11,12</sup> Furthermore, performance testing using a standardized anthropomorphic phantom (a human skull encased in polyurethane to simulate soft tissue) has revealed that linear measurement error varies by CBCT scanner brand and model. While most evaluated scanners tended to slightly overesti-



**Fig. 1.** Anatomical illustration of the distance between the cemento-enamel junction (CEJ) and the posterior superior alveolar artery (PSAA).

mate the accepted value, this was not universally true.<sup>13</sup> Image quality, spatial resolution, and diagnostic performance for tasks such as visualizing root canals and detecting fractures are influenced by acquisition parameters, including field of view, voxel size, and the number of basis projections (arc of rotation).<sup>14,15</sup> In contrast, scan mode parameters such as peak tube potential, current, and scan time appear less impactful.<sup>14,15</sup> The aim of this retrospective analysis was to determine the impact of CBCT scanner type, field of view, voxel size, sex, and age on the detection of the PSAA and the measurement of the CEJ-PSAA distance at maxillary posterior tooth positions. Additionally, this study describes an assessment of the distance from the PSAA to the CEJ of posterior teeth, which could provide an additional interoperative aid to assist surgeons in avoiding the PSAA.

No prior studies have assessed the distance between the CEJ and the PSAA using CBCT imaging; therefore, this study was designed to address that gap. The objectives were to determine the CEJ-PSAA distance and to assess which factors may influence the identification of the PSAA on CBCT images.

## Materials and Methods

This protocol was reviewed and approved by the Human Research Protections Office (HRPO) at the Dwight David Eisenhower Army Medical Center, Fort Eisenhower, Georgia, United States (protocol # 21-14068). It was conducted in accordance with the Declaration of Helsinki of 1975, as revised in 2013. Participating patients provided both written and oral informed consent for all treatments. Information was recorded in a manner that ensured the identities of human participants could not be directly ascertained or inferred through linked identifiers. Thus, the investigators did not contact the participants. Accordingly, the HRPO classified this protocol as secondary research for which consent is not required (category 4), as per 32 CFR 219.101 (b).

To be included in the analysis, a diagnostic CBCT volume had to be available from 1 of the 2 CBCT scanner systems at the Department of Periodontics, Army Postgraduate Dental School, Fort Eisenhower, Georgia. The scan needed to include some or all of the maxillary posterior teeth or tooth positions (left, right, or both) as well as the maxillary sinus, extending at least 20 mm superior to the sinus floor. Nondiagnostic scans were excluded. The CBCT scanners were designated as scanner 1 (3D Accuitomo 170; J. Morita Corp., Osaka, Japan) and scanner 2 (CS 9300; Carestream, Rochester, NY, USA). The acquisition parameters, such as

**Table 1.** Characteristics of the study sample and summary of descriptive statistics

		Number	Percentage
Age (years)	36.5 ± 12.9 (range, 18 to 94)		
Sex	Female	61	24
	Male	193	76
CBCT volumes	254		
Scanner	Scanner 1	128	50.4
	Scanner 2	126	49.6
Field of view	40 mm × 40 mm	111	43.7
	50 mm × 50 mm	24	9.4
	60 mm × 60 mm	33	13
	80 mm × 50 mm	15	5.9
	80 mm × 80 mm	30	11.8
	100 mm × 50 mm	6	2.4
	100 mm × 100 mm	27	10.6
	120 mm × 50 mm	1	0.4
Voxel size	120 mm × 100 mm	6	2.4
	160 mm × 100 mm	1	0.4
	0.05 to 0.08 mm <sup>3</sup>	142	55.9
	0.125 to 0.160 mm <sup>3</sup>	103	40.6
PSAA detection within scan	0.250 to 0.300 mm <sup>3</sup>	9	3.5
	Detected	21	8.3
	Not detected	233	91.7
Distance from cementoenamel junction to PSAA by tooth position (mm)			
	Scanner 1	Scanner 2	Overall
Second molar	17.0 ± 4.0	17.3 ± 3.5	17.1 ± 3.7
First molar	21.8 ± 4.1	16.9 ± 4.3	19.6 ± 4.8
Second premolar	19.5 ± 4.7	18.5 ± 4.1	18.9 ± 4.4
First premolar	19.9 ± 4.9	18.4 ± 4.3	19.3 ± 4.7

CBCT: cone-beam computed tomography, PSAA: posterior superior alveolar artery

field of view and voxel size, are detailed in Table 1. The peak tube potential varied from 79 kV to 120 kV (mean, 104.1 ± 15.7 kV), the current ranged from 4 mA to 8 mA (mean, 6.9 ± 1.4 mA), and the scan time was between 10.0 and 30.8 seconds (mean, 23.7 ± 7.1 seconds).

For each CBCT volume that met the inclusion criteria, a single examiner evaluated the region between PM1 and M2 to determine the detectability of the PSAA. The examiner reviewed custom cross-sectional slices that were oriented orthogonally to the maxillary posterior teeth or alveolar ridge. After optimizing the brightness and contrast, the examiner scrolled through the cross-sectional slices from the posterior to the anterior end twice, examining them at various magnification levels up to 200%. If the artery was not visible in this orientation, parasagittal and axial views

were also employed to facilitate identification. In addition to evaluating detectability, the examiner categorized the PSAA as either “readily apparent” or “difficult to identify”. An artery was only considered “detected” if it was traceable across multiple consecutive cross-sectional slices. This analysis included all CBCT volumes, even those from edentulous patients. Data on patient age, sex, the CBCT scanner used (scanner 1 or scanner 2), isotropic voxel size, and field of view were also documented.

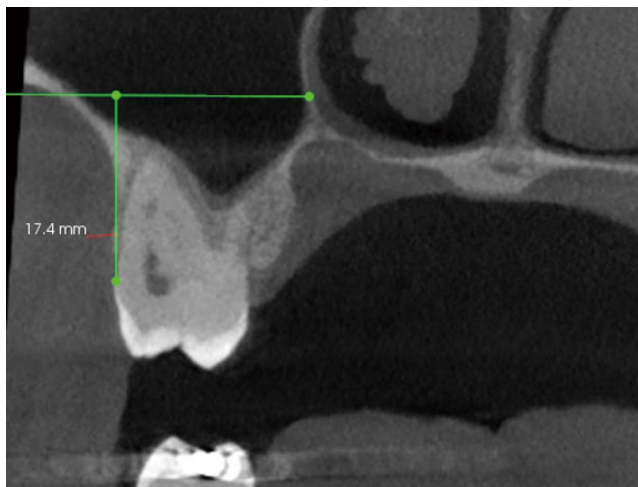
Vertical measurements were taken from the apical position of the CEJ to the inferior border of the PSAA at each posterior tooth position. The sites were examined using cross-sectional coronal slices that were oriented orthogonal to the maxillary posterior teeth (Fig. 2). For each site, the cross-sectional slice that captured the most apical point of the CEJ was selected for measurement. The inferior border of the PSAA was marked with a horizontal line. Measurements were recorded from the apical point of the CEJ to the horizontal reference line of the artery, representing a vertical distance parallel to the long axis of the teeth. This procedure was performed for each posterior tooth-bearing site within the CBCT volume. Edentulous sites were excluded.

Descriptive and inferential statistical analyses were conducted for all qualitative and quantitative variables using SPSS Statistics for Windows, version 28 (IBM Corp., Armonk, NY, USA). *P*-values of less than 0.05 were considered to indicate statistical significance. The dependent variables of interest included the detection of the PSAA at any

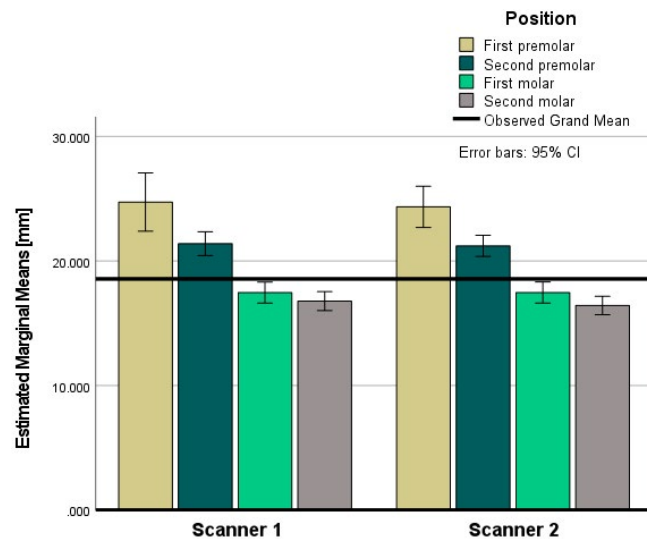
location within the PM1-M2 region (a binary variable) and the CEJ-PSAA distance recorded at each tooth position (a ratio variable). The independent variables were tooth position (PM1, PM2, M1, and M2), the type of CBCT scanner used, CBCT acquisition parameters (field of view and isotropic voxel size), sex, and age. A binomial logistic regression analysis was conducted to evaluate the impact of the independent variables on PSAA detection, and a multiple linear regression analysis was performed to assess their influence on the CEJ-PSAA distance. The examiner recorded duplicate measurements on every fifth CBCT scan, and the intra-class correlation coefficient (ICC) was calculated to assess intra-examiner reliability.

### Results

The characteristics of the study sample, along with descriptive statistics for the independent and dependent variables, are summarized in Table 1. The analysis included a total of 515 dentate maxillary posterior tooth positions from 254 CBCT volumes. Each scan incorporated a 360° arc of rotation. The peak tube potential ranged from 79 kV to 120 kV (mean,  $104.1 \pm 15.7$  kV), the current varied from 4 mA to 8 mA (mean,  $6.9 \pm 1.4$  mA), and the scan time ranged from 10.0 to 30.8 seconds (mean,  $23.7 \pm 7.1$  seconds). The PSAA was identified on 233 (91.7%) of the CBCT volumes, while it was not detected on 21 (8.3%) volumes. Of the 233 detected vessels, 99 (42%) were graded as “readily apparent,” while 134 (58%) were deemed “difficult to identify.” The grand mean CEJ-PSAA distance was  $18.6 \pm 4.6$  mm (Fig. 3). The intraclass correlation coefficient was calculated



**Fig. 2.** Cross-sectional measurement from the cemento-enamel junction to the posterior superior alveolar artery. For each posterior tooth site, the cross-section containing the most apical level of the cemento-enamel junction was selected. Within this cross-section, the artery was identified and marked with a horizontal reference line. The distance was then measured from the most apical point of the cemento-enamel junction to the reference mark.



**Fig. 3.** Estimated marginal means of the distance from the cemento-enamel junction to the intraosseous branch.

to be 0.991, indicating intra-rater excellent reliability.

A logistic regression analysis was conducted to explore whether age, sex, scanner type, field of view, or voxel size predicted the detection of the PSAA within the M2-PM1 region of the CBCT volume. Hierarchical models were constructed by adding 1 variable at a time to eliminate factors that did not significantly impact PSAA detection. The fit of the models was assessed using omnibus tests of model coefficients. However, none of the models tested reached statistical significance ( $P > 0.05$ ), indicating that no factor evaluated in this study was a significant predictor of PSAA detection.

A multiple linear regression analysis was conducted to assess the impact of various independent variables on the CEJ-PSAA distance. The potential predictors included tooth position, sex, CBCT scanner type, and isotropic voxel size. Field of view was eliminated from the model due to collinearity with voxel size (tolerance = 0.19). The criterion variable in this analysis was the CEJ-PSAA distance. The results indicated that the linear combination of predictor variables was significantly related to CEJ-PSAA distance ( $F[5,509] = 5.6, P < 0.05$ ). In this sample, this linear combination accounted for approximately 5% of the variance in this distance. Two variables displayed significant associations with the CEJ-PSAA distance: tooth position ( $b = -0.67$ ; 95% CI:  $-0.994$  to  $-0.347$ ;  $P < 0.001$ ) and scanner type ( $b = -1.3$ ; 95% CI:  $-2.071$  to  $-0.499$ ;  $P = 0.001$ ). For each successive tooth position in the posterior direction, from the first premolar to the second molar, the estimated mean CEJ-PSAA distance decreased by 0.67 mm. Additionally, relative to CBCT scanner type 1, type 2 was associated with a 1.3-mm decrease in the estimated mean CEJ-PSAA distance.

By performing a stepwise linear regression with tooth position entered in the first block and all other predictor variables in the second block, tooth position alone was found to account for 3% of the variance in the CEJ-PSAA distance. The inclusion of the other variables contributed an additional 2%. Of the 2 statistically significant factors, tooth position was a marginally stronger predictor of CEJ-PSAA distance, although the overall model explained only a small percentage of the variance. The estimated marginal means of the CEJ-PSAA distance are presented in Table 1.

## Discussion

This investigation was conducted to determine the effects of specific patient- and scan-related factors on the detection of the PSAA using CBCT and to measure the distance from

the CEJ to the PSAA at maxillary posterior tooth positions. Multiple authors have described the diameter, location, and course of the PSAA.<sup>4-12</sup> However, no consensus has been reached on the position of this artery, as it has been indexed to various intraoral landmarks, and studies have reported differing estimates. The variability in reported PSAA locations can likely be attributed to the use of different anatomic reference points, heterogeneity in study samples, and the application of diverse measurement protocols. In this study, the CEJs of the maxillary posterior teeth were selected as reference points due to their reliable intraoperative visibility, temporospatial stability, and high detectability using CBCT. However, a clear drawback of this reference point is its lack of applicability to cases in which all maxillary posterior teeth are absent. Among the various methods for assessing the PSAA, the protocol employed in this study – CBCT evaluation – seems to be the most clinically relevant, given the widespread availability and use of this imaging technology. To the knowledge of these authors, no previous investigations have employed a CBCT measurement protocol that indexes the PSAA position to the CEJ.

In this investigation, the PSAA was undetectable on only 8.3% of scans. Studies of the human skull suggest that the PSAA is present in virtually every individual,<sup>4-6</sup> although the vessel diameter may be small in some patients. Despite the presumed presence of the PSAA, radiological detection of the intraosseous branch using CBCT has varied, with identification rates ranging from 64% to 82% within each volume. Lower rates have been observed when considering specific sites.<sup>11,12</sup> These values still represent a considerable improvement over PSAA detection on conventional CT, which can have a rate as low as 44%.<sup>10</sup> The high detectability of the PSAA observed in this study may be partially attributable to advancements in scanner technology and viewing software. The devices used in this investigation, scanner 1 and scanner 2, were installed in 2012 and 2021, respectively. The latest generation of CBCT scanners may conceivably provide superior performance compared to earlier models. Additionally, many of the volumes analyzed were captured for endodontic treatment, which typically requires a comparatively small field of view and high resolution. This may have further contributed to the relatively high rate of PSAA identification in this study.

None of the independent variables defined in this study exerted a statistically significant effect on PSAA detection. For certain clinical indications, such as root canal visualization and fracture detection, specific scanner models and CBCT acquisition parameters have been associated with superior performance.<sup>14,15</sup> Under the described conditions,

scanner type, field of view, and voxel size had no significant influence on PSAA detection in this sample. Therefore, efforts to increase resolution with the intent to improve identification of the PSAA are not justified according to the findings of this study.

In the present investigation, 193 of the 254 analyzed volumes originated from male patients, a distribution that reflects the demographics of a military-based patient population. Efforts to minimize this imbalance would have compromised the randomized design of the study. Notably, sex was not found to significantly influence either the detection of the PSAA or the CEJ-PSAA distance.

The mean positions of the PSAA calculated in this study align with the results of previous research, with several prior reports presenting similar or higher estimates. Solar et al. reported an average distance of 19 mm from the PSAA to the alveolar crest, which is close to the grand mean distance from the CEJ to the PSAA in the present study.<sup>4</sup> However, in a healthy periodontium, the CEJ is typically 2 to 3 millimeters coronal to the alveolar crest,<sup>16-18</sup> and alveolar bone loss at a dentate site may occur due to periodontitis, other pathologies, trauma, or developmental factors.<sup>19</sup> Thus, the average PSAA position reported in this paper seems to fall several millimeters inferior to the position estimated by Solar et al.,<sup>4</sup> aligning with the mean values reported by Kqiku et al.<sup>6</sup> Hur et al.<sup>5</sup> identified the PSAA in relation to the same anatomical landmark as the present study, and the CEJ-PSAA measurements obtained with scanner 2 mirrored the trends they observed: greater mean distances in the premolar regions compared to the molar regions, with the smallest distance at the M1 position. In contrast, the CEJ-PSAA measurements taken with scanner 1 were greatest at the M1 position (Table 1), which is inconsistent with the findings of previous studies.<sup>5-8</sup> This discrepancy may be due to sample variability. Notably, in the present study sample, the M1 position had the fewest observations. Interestingly, when considering a model that includes both scanner type and tooth position, the estimated marginal means of the CEJ-PSAA distance more closely resemble the anticipated pattern.

At all tooth positions, Hur et al.<sup>5</sup> reported mean CEJ-PSAA values that exceeded those observed in the present study. In contrast, Rysz et al.<sup>10</sup> employed CEJ reference points and a conventional CT measurement protocol, reporting mean CEJ-PSAA values resembling those found here. Similarly, when considering differences in anatomical references, Kang et al.,<sup>11</sup> Mardinger et al.,<sup>8</sup> and Elian et al.<sup>9</sup> reported PSAA positions that were comparable to the estimates presented in this report. In the case of edentulous,

highly atrophic alveolar ridges, the clinical situation regarding PSAA position is distinct. The alveolar ridge volume decreases substantially after tooth extraction. In such cases, comparatively short distances have therefore been recorded between the PSAA and the alveolar crest or sinus floor. It is challenging to contextualize the findings of these reports with those of the present study.<sup>7-9</sup>

Two significant predictors of the CEJ-PSAA distance were identified in this study: scanner type and tooth position. The influence of tooth position on this measurement is not unexpected, corroborating findings from multiple previous reports.<sup>5,6,10</sup> Moreover, the observed decrease in CEJ-PSAA distance from the premolar to the molar positions, typically reaching its minimum at the first molar, also aligns with earlier research.<sup>5-8</sup> One study noted both the linear and the less common U-shaped distribution patterns of the PSAA.<sup>5</sup> Variability in linear measurements based on scanner type has also been documented.<sup>13</sup> In a performance test of linear measurements using 8 CBCT scanners, the device labeled “scanner 1” in the present study exhibited the third lowest mean absolute measurement error ( $0.14 \pm 0.07$ ), while scanner 2 displayed the third highest ( $0.23 \pm 0.18$ ). This discrepancy may stem from advancements in scanner technology between the installation of scanner 1 in 2012 and that of scanner 2 in 2021, as well as differences in the viewing software associated with each device.

In this investigation, 515 tooth positions within 254 CBCT volumes were evaluated to assess the impact of patient- and scan-related factors on the detection of the PSAA and the CEJ-PSAA distance. The frequency of PSAA detection surpassed previously reported figures, possibly due to advancements in scanner technology and viewing software. None of the explanatory variables examined, including voxel size, significantly influenced the detection of the PSAA. Therefore, increasing spatial resolution specifically for PSAA detection does not appear to be justified. Although 2 statistically significant predictors of the CEJ-PSAA distance were identified, the linear regression model used explained only 5% of the variance in this distance, casting doubt on the clinical relevance of these findings. Nevertheless, the study did confirm that in dentate patients, a CBCT measurement protocol that incorporates the CEJ as a reference point can estimate the position of the PSAA with a level of accuracy comparable to that achieved through direct measurement, conventional CT, or CBCT using an alveolar bone reference point.

Estimations of the CEJ-PSAA distance using CBCT appear comparable to direct recordings in human cadaver studies and measurements obtained on conventional CT volumes.



The type of CBCT scanner may exert a minor influence on this parameter. None of the assessed independent variables significantly affected the detection of PSAA. The present study did not find evidence to support increasing the CBCT resolution to improve detection of the PSAA.

**Conflicts of Interest:** None

### Acknowledgments

The views expressed in this manuscript are those of the authors and do not necessarily reflect the official policy of the Department of Defense, the Department of the Army, the US Army Medical Department, or the Uniformed Services University of the Health Sciences.

### References

1. Pjetursson BE, Tan WC, Zwahlen M, Lang NP. A systematic review of the success of sinus floor elevation and survival of implants inserted in combination with sinus floor elevation. *J Clin Periodontol* 2008; 35(8 Suppl): 216-40.
2. Zijdeveld SA, van den Bergh JP, Schulten EA, ten Bruggenkate CM. Anatomical and surgical findings and complications in 100 consecutive maxillary sinus floor elevation procedures. *J Oral Maxillofac Surg* 2008; 66: 1426-38.
3. Danesh-Sani SA, Loomer PM, Wallace SS. A comprehensive clinical review of maxillary sinus floor elevation: anatomy, techniques, biomaterials and complications. *British J Oral Maxillofac Surg* 2016; 54: 724-30.
4. Solar P, Geyerhofer U, Traxler H, Windisch A, Ulm C, Watzek G. Blood supply to the maxillary sinus relevant to sinus floor elevation procedures. *Clin Oral Implants Res* 1999; 10: 34-44.
5. Hur MS, Kim JK, Hu KS, Bae HE, Park HS, Kim HJ. Clinical implications of the topography and distribution of the posterior superior alveolar artery. *J Craniofac Surg* 2009; 20: 551-4.
6. Kqiku L, Biblekaj R, Weiglein AH, Kqiku X, Städtler P. Arterial blood architecture of the maxillary sinus in dentate specimens. *Croat Med J* 2013; 54: 180-4.
7. Rosano G, Taschieri S, Gaudy JF, Weinstein T, Del Fabbro M. Maxillary sinus vascular anatomy and its relation to sinus lift surgery. *Clin Oral Implants Res* 2011; 22: 711-5.
8. Mardinger O, Abba M, Hirshberg A, Schwartz-Arad D. Prevalence, diameter and course of the maxillary intraosseous vascular canal with relation to sinus augmentation procedure: a radiographic study. *Int J Oral Maxillofac Surg* 2007; 36: 735-8.
9. Elian N, Wallace S, Cho SC, Jalbout ZN, Froum S. Distribution of the maxillary artery as it relates to sinus floor augmentation. *Int J Oral Maxillofac Implants* 2005; 20: 784-7.
10. Rysz M, Ciszek B, Rogowska M, Krajewski R. Arteries of the anterior wall of the maxilla in sinus lift surgery. *Int J Oral Maxillofac Surg* 2014; 43: 1127-30.
11. Kang SJ, Shin SI, Herr Y, Kwon YH, Kim GT, Chung JH. Anatomical structures in the maxillary sinus related to lateral sinus elevation: a cone beam computed tomographic analysis. *Clin Oral Implants Res* 2013; 24 Suppl A100: 75-81.
12. Apostolakis D, Bissoon AK. Radiographic evaluation of the superior alveolar canal: measurements of its diameter and of its position in relation to the maxillary sinus floor: a cone beam computerized tomography study. *Clin Oral Implants Res* 2014; 25: 553-9.
13. Kosalagood P, Silkosessak OC, Pittayapat P, Pisarnurakit P, Pauwels R, Jacobs R. Linear measurement accuracy of eight cone-beam computed tomography scanners. *Clin Implant Dent Relat Res* 2015; 17: 1217-27.
14. Hassan BA, Payam J, Juyanda B, van der Stelt P, Wesselink PR. Influence of scan setting selections on root canal visibility with cone beam CT. *Dentomaxillofac Radiol* 2012; 41: 645-8.
15. Hassan B, Metska ME, Ozok AR, van der Stelt P, Wesselink PR. Comparison of five cone beam computed tomography systems for the detection of vertical root fractures. *J Endod* 2010; 36: 126-9.
16. Gargiulo AW, Wentz FM, Orbon B. Dimensions and relations of the dentogingival junction in humans. *J Periodontol* 1961; 32: 261-7.
17. Vacek JS, Gher ME, Assad DA, Richardson AC, Giambarrresi LI. The dimensions of the human dentogingival junction. *Int J Periodontics Restorative Dent* 1994; 14: 154-65.
18. Hausmann E, Allen K, Clerehugh V. What alveolar crest level on a bite-wing radiograph represents bone loss? *J Periodontol* 1991; 62: 570-2.
19. Hämmerle CH, Tarnow D. The etiology of hard- and soft-tissue deficiencies at dental implants: a narrative review. *J Periodontol* 2018; 89 Suppl 1: S291-303.