



Safety of Administering Intravenous CT Contrast Agents Repeatedly or Using Both CT and MRI Contrast Agents on the Same Day: An Animal Study

Heejin Bae*, Hyewon Oh*, Ga Bin Park, Yong Eun Chung

Department of Radiology, Severance Hospital, Yonsei University College of Medicine, Seoul, Republic of Korea

Objective: To investigate molecular and functional consequences of additional exposures to iodine- or gadolinium-based contrast agents within 24 hours from the initial intravenous administration of iodine-based contrast agents through an animal study.

Materials and Methods: Fifty-six Sprague–Dawley male rats were equally divided into eight groups: negative control, positive control (PC) with single-dose administration of CT contrast agent, and additional administration of either CT or MR contrast agents 2, 4, or 24 hours from initial CT contrast agent injection. A 12 $\mu\text{L/g}$ of iodinated contrast agent or a 0.47 $\mu\text{L/g}$ of gadolinium-based contrast agent were injected into the tail vein. Serum levels of blood urea nitrogen, creatinine, cystatin C (Cys C), and malondialdehyde (MDA) were measured. mRNA and protein levels of kidney injury molecule-1 (KIM-1) and neutrophil gelatinase-associated lipocalin (NGAL) were evaluated.

Results: Levels of serum creatinine (SCr) were significantly higher in repeated CT contrast agent injection groups than in PC (0.21 ± 0.02 mg/dL for PC; 0.40 ± 0.02 , 0.34 ± 0.03 , and 0.41 ± 0.10 mg/dL for 2-, 4-, and 24-hour interval groups, respectively; $P < 0.001$). There was no significant difference in the average Cys C and MDA levels between PC and repeated CT contrast agent injection groups (Cys C, $P = 0.256\text{--}0.362$; MDA, $P > 0.99$). Additional doses of MR contrast agent did not make significant changes compared to PC in SCr ($P > 0.99$), Cys C ($P = 0.262$), and MDA ($P = 0.139\text{--}0.771$) levels. mRNA and protein levels of KIM-1 and NGAL were not significantly different among additional CT or MR contrast agent groups ($P > 0.05$).

Conclusion: A sufficient time interval, probably more than 24 hours, between repeated contrast-enhanced CT examinations may be necessary to avoid deterioration in renal function. However, conducting contrast-enhanced MRI on the same day as contrast-enhanced CT may not induce clinically significant kidney injury.

Keywords: Acute kidney injury; Contrast agent; Magnetic resonance imaging; Computed tomography

INTRODUCTION

Contrast agents are routinely used to enhance the performance of various imaging modalities for diagnostic

Received: July 27, 2023 **Revised:** December 16, 2023

Accepted: December 21, 2023

*These authors contributed equally to this work.

Corresponding author: Yong Eun Chung, MD, PhD, Department of Radiology, Severance Hospital, Yonsei University College of Medicine, 50-1 Yonsei-ro, Seodaemun-gu, Seoul 03722, Republic of Korea

• E-mail: yelv@yuhs.ac

This is an Open Access article distributed under the terms of the Creative Commons Attribution Non-Commercial License (<https://creativecommons.org/licenses/by-nc/4.0>) which permits unrestricted non-commercial use, distribution, and reproduction in any medium, provided the original work is properly cited.

and interventional procedures in daily clinical practice. However, iodine-based CT contrast agents are nephrotoxic medications that can cause acute kidney injury (AKI) [1,2]. As the third most common cause of hospital-acquired AKI, accounting for 10%–12% of cases, post-contrast AKI (PC-AKI) is generally defined as an absolute increase in serum creatinine (SCr) of ≥ 0.3 mg/dL or a relative elevation of SCr by $\geq 50\%$ from baseline within 48–72 hours from the injection of contrast agent in the absence of other causative factors of AKI [3–6]. Previous studies have shown that PC-AKI is associated with a prolonged hospital stay, increased hospital-acquired complications, and increased morbidity and mortality in both inpatient and outpatient settings [7–10].

Various patient- and procedure-related risk factors,

including pre-existing renal insufficiency, diabetes mellitus, and large doses of contrast agents, are related to PC-AKI [6]. Although repeated exposure to contrast agents within a short period is one of the well-established risk factors for PC-AKI, repeat contrast-enhanced CT examinations or contrast-enhanced MRI following contrast-enhanced CT examinations within 48–72 hours is occasionally performed in outpatient settings as well as in emergencies for both diagnostic and therapeutic purposes [6,11-13]. Considering these clinical situations where repeated exposure to contrast agents is inevitable, several guidelines have suggested the minimum interval between two contrast-enhanced examinations. The European Society of Urogenital Radiology (ESUR) guidelines recommend a 4-hour interval between administrations of iodine-based CT and gadolinium-based MR contrast agents for patients with normal or moderately reduced renal function (glomerular filtration rate [GFR] > 30 mL/min/1.73 m²) [3]. For patients with severely reduced renal function, a 7-day interval between injections of iodine-based and gadolinium-based contrast agents is recommended [3]. The rationale for this recommendation is that 75% of injected iodine- and gadolinium-based contrast agents are excreted after 4 hours [3]. On the other hand, the American College of Radiology Committee on Drugs and Contrast Media does not recommend withholding

a repeat contrast agent administration for more than 24 hours from the prior injection, nor do they suggest a specific time interval between repeated contrast-enhanced CT examinations because the supporting evidence is inadequate to decide on specific guidelines [4]. As shown in these guidelines, the evidence to support a particular time interval between repeated exposures to iodine- and gadolinium-based contrast agents is insufficient.

Therefore, the purpose of this study was to investigate the molecular and functional consequences of additional injections of iodine- or gadolinium-based contrast agents within 24 hours from the initial administration of iodine-based contrast agents, through an animal study.

MATERIALS AND METHODS

Animal Experiments

This animal study was approved by the Institutional Animal Care and Use Committee (IACUC No. 2019-0283) and was conducted in accordance with the ARRIVE guidelines and all other relevant guidelines and regulations. A total of 56 Sprague–Dawley male rats weighing 200–220 g were used in this study. The rats were housed in an animal laboratory and maintained in a sterile 12-hour light and 12-hour dark experimental animal environment with 50%–

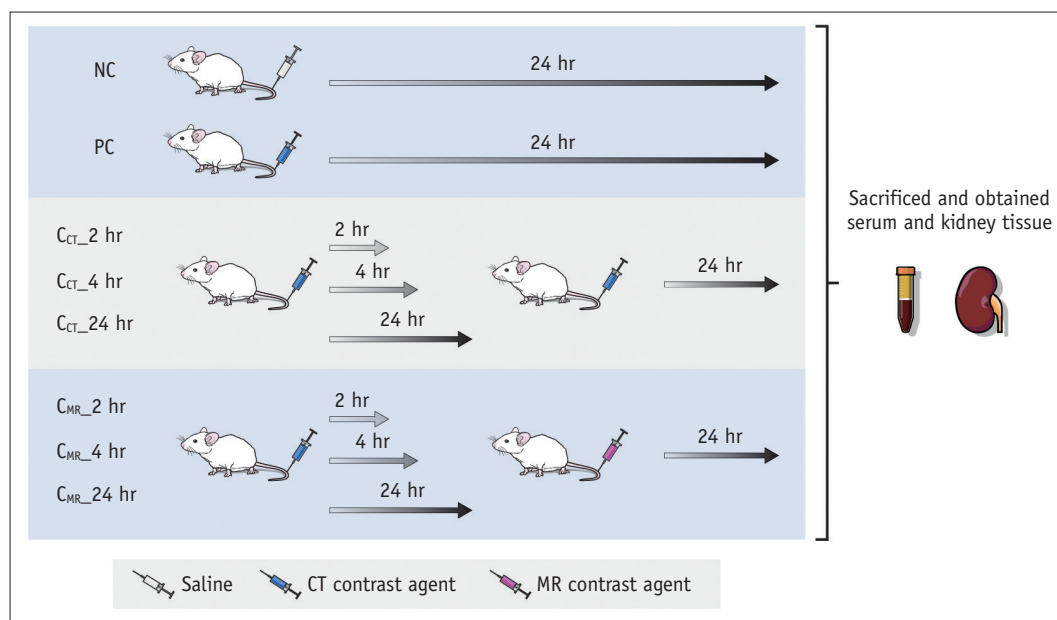


Fig. 1. Illustration of the experimental procedure. The rats were divided into eight groups. The NC and PC groups were given saline and a single dose of CT contrast agent, respectively. Time intervals between the injections of contrast agents were 2, 4, and 24 hours (referred to as C_{CT}_2 hr, C_{CT}_4 hr, and C_{CT}_24 hr for repeated administrations of CT contrast agents and referred to as C_{MR}_2 hr, C_{MR}_4 hr, and C_{MR}_24 hr for additional administration of MR contrast agent after the single-dose of CT contrast agent). NC = negative control, PC = positive control

100% humidity at 22°C ± 2°C before the experiments. The experimental procedure is illustrated in Figure 1. The rats were equally divided into eight groups: a negative control group with saline injection (the same volume as single dose of CT contrast agent); a positive control group with single-dose administration of CT contrast agent; repeated administration of CT contrast agent with 2, 4, or 24 hours between the injections (referred to as C_{CT_2} hr, C_{CT_4} hr, and C_{CT_24} hr, respectively); and additional administration of MR contrast agent 2, 4, or 24 hours after the single-dose administration of CT contrast agents (referred to as C_{MR_2} hr, C_{MR_4} hr, and C_{MR_24} hr, respectively). We administered a 12 µL/g of iodinated contrast agent (Iopamidol, Pamiray 300; Dongkuk Pharmaceutical, Seoul, Korea) or a 0.47 µL/g of gadolinium-based contrast agent (Gadobutrol, Gadovist; Bayer Healthcare, Berlin, Germany) into the tail vein. After 24 hours from the last administration of contrast agent or saline, rats were sacrificed using inhalation anesthesia with 5% isoflurane in a mixture of 0.7 L/min nitrous oxide and 0.3 L/min oxygen. Serum was drawn, and kidney tissues were resected for analysis.

Serum Collection and Renal Function Assessment

Blood samples were collected without anticoagulants, using a 26-gauge syringe needle through a cardiac puncture into the right atrium. The blood was transferred into a serum-separating tube and centrifuged at 13000 rpm for 20 min at room temperature. The serum was used in an enzyme-linked immunosorbent assay (ELISA) and malondialdehyde (MDA) assay. In addition, the serum levels of creatinine, blood urea nitrogen (BUN), and cystatin C (Cys C) were measured using a Cobas C502 autoanalyzer (Roche, Mannheim, Germany).

Kidney Histopathology

Kidney tissue was fixed with 10% neutral-buffered formalin, embedded in paraffin, and sectioned into 4-µm slices. The paraffin-embedded tissues were deparaffinized by xylene and rehydrated in increasing concentrations of ethanol solutions (70%, 90%, 95%, and 100%). Then, the samples were stained with hematoxylin and eosin (H&E) using the Leica Autostainer (Leica, Wetzlar, Germany). The stained slides were observed under an inverted microscope (IX71, Olympus, Tokyo, Japan).

RNA Extraction and Real-Time PCR

Total RNA was extracted from the kidney tissue using a commercial kit according to the manufacturer's instructions

(K-3140, Bioneer Corporation, Daejeon, Korea). To obtain cDNA, 1 µg of the total RNA was reverse transcribed using amifiRivert cDNA synthesis (GenDEPOT, Baker, TX, USA) according to the manufacturer's instructions. The mRNA levels of kidney injury molecule-1 (KIM-1) and neutrophil gelatinase-associated lipocalin (NGAL) were assessed with the SYBR-Green reagent (GenDEPOT) using the ABI7500 real-time polymerase chain reaction (PCR) system (Applied Biosystem, Foster City, CA, USA) and normalized to β-actin. Gene expression was quantified using β-actin as the internal loading control. The relative mRNA expression of target genes was calculated based on the 2^{-ΔΔCt} method. To reduce intrinsic errors in real-time PCR, such as pipetting errors, the experiments were conducted with duplicated samples. The primer sequences are shown in Table 1.

Enzyme-Linked Immunosorbent Assay

Rat serum KIM-1 and NGAL levels were analyzed using the Rat KIM-1 (ab223858, Abcam, Cambridge, MA, USA) and Rat NGAL ELISA kits (ab207958, Abcam), respectively, according to the manufacturer's instructions. The absorbance levels of the concentration were analyzed at 450 nm using a microplate reader (Molecular Devices, Sunnyvale, CA, USA).

Oxidative Stress Quantification using MDA

Oxidative stress was determined by measuring the formation of MDA, a product of membrane lipid peroxidation, using 2-thiobarbituric acid-reactive substances. MDA concentration was measured as MDA equivalents using rat serum and with a commercial kit (Cat #10009055, Cayman Chemical, Ann Arbor, MI, USA) according to the manufacturer's instructions.

Statistical Analysis

One-way analysis of variance was used to evaluate and compare the levels of kidney function and kidney injury markers among the negative control, positive control, and experimental groups. The results were represented as the mean ± standard deviation. For multiple comparisons, *P*-values

Table 1. Primer sequence for quantitative real-time polymerase chain reaction for the in vivo experiments

Gene	Forward sequence (5'-3')	Reverse sequence (5'-3')
β-actin	tggcaccagcacaatgaa	ctaagtcatagtccgctagaagca
Kim-1	aacgcagcgattgtgatcc	gtacactcaccatgtaacc
NGAL	gatgaactgaaggagcgattc	tcggtgggaacagagaaaac

Kim-1 = kidney injury molecule-1, NGAL = neutrophil gelatinase-associated lipocalin

were adjusted using the Bonferroni correction. All statistical analyses were performed using GraphPad Prism 9.3.0 software (GraphPad, San Diego, CA, USA). A *P*-value less than 0.05 was considered statistically significant.

RESULTS

Positive Control

Compared to the negative control with saline injection (Scr, 0.16 ± 0.02 mg/dL; BUN, 9.43 ± 0.98 mg/dL; Cys C, 0.40 mg/L; MDA, 0.77 ± 0.47 μ M), the positive control with a single dose of CT contrast agent did not show a

significantly altered kidney function (Scr, 0.21 ± 0.02 mg/dL; BUN, 9.86 ± 1.22 mg/dL) and kidney injury markers (Cys C, 0.43 ± 0.05 mg/L; MDA, 1.80 ± 0.74 μ M) (Supplementary Tables 1, 2, Fig. 2). Similarly, mRNA and the protein levels of KIM-1 and NGAL were not significantly different between the negative and positive control groups (Supplementary Tables 1, 2, Fig. 3).

Repetitive Exposure to CT Contrast Agents

Additional doses of CT contrast agent resulted in significant increases in BUN and Scr levels ($C_{CT_2\ hr}$: 14.0 ± 2.45 mg/dL and 0.40 ± 0.02 mg/dL, respectively; $C_{CT_4\ hr}$:

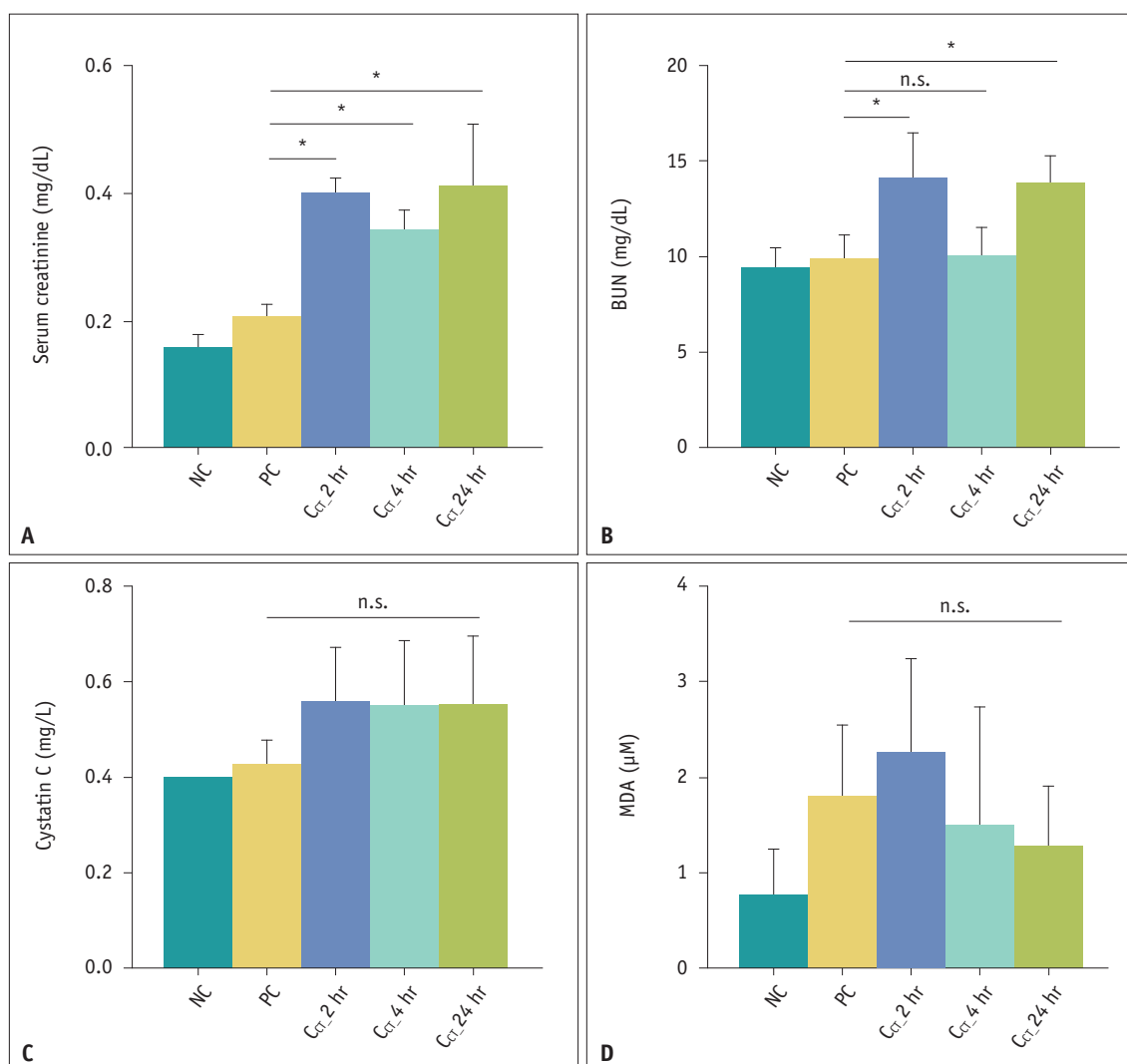


Fig. 2. Renal function and oxidative stress markers after repeated CT contrast agent administration. **A-D:** Comparison of serum levels of creatinine (**A**), BUN (**B**), cystatin C (**C**), and MDA (**D**). Results are presented as the mean \pm standard deviation. The repeated administration of CT contrast agent resulted in significant increases in serum creatinine and BUN levels, except for the BUN level in $C_{CT_4\ hr}$. Cystatin C and MDA levels showed no significant difference between the PC and additional contrast exposure groups. Statistical significance (PC vs. $C_{CT_2, 4, \text{ and } 24\ hr}$). **P* < 0.001. BUN = blood urea nitrogen, MDA = malondialdehyde, $C_{CT_2, 4, \text{ and } 24\ hr}$ = an additional dose of CT contrast agent within 2, 4, or 24 hours after the single-dose administration of CT contrast agent, PC = positive control, NC = negative control, n.s. = no significance

10.0 ± 1.41 mg/dL and 0.34 ± 0.03 mg/dL, respectively; C_{CT}_24 hr: 13.9 ± 1.35 mg/dL and 0.41 ± 0.10 mg/dL, respectively; *P*-values [vs. positive control], > 0.99 for BUN level of C_{CT}_4 hr; < 0.001 for other cases; Fig. 2, Supplementary Table 1), except for the BUN level in C_{CT}_4 hr. In contrast to the SCr and BUN, the concentrations of kidney injury markers were not significantly different in all experimental CT contrast agent groups compared to those of the positive control group (Figs. 2, 3, Supplementary Table 1). There were also no significant histologic changes on H&E staining (Supplementary Fig. 1).

Additional Exposure to MR Contrast Agent after CT Contrast Agent

The average values of SCr and BUN with an additional dose of MR contrast agent after a single dose of CT contrast agent were not significantly different from those after one dose of CT contrast agent (*P* > 0.05) (Fig. 4, Supplementary Table 2). Similarly, Cys C and MDA levels and both mRNA and protein levels of KIM-1 and NGAL were not significantly altered in the additional MR contrast agent injection groups (*P* > 0.05) (Figs. 4, 5, Supplementary Table 2).

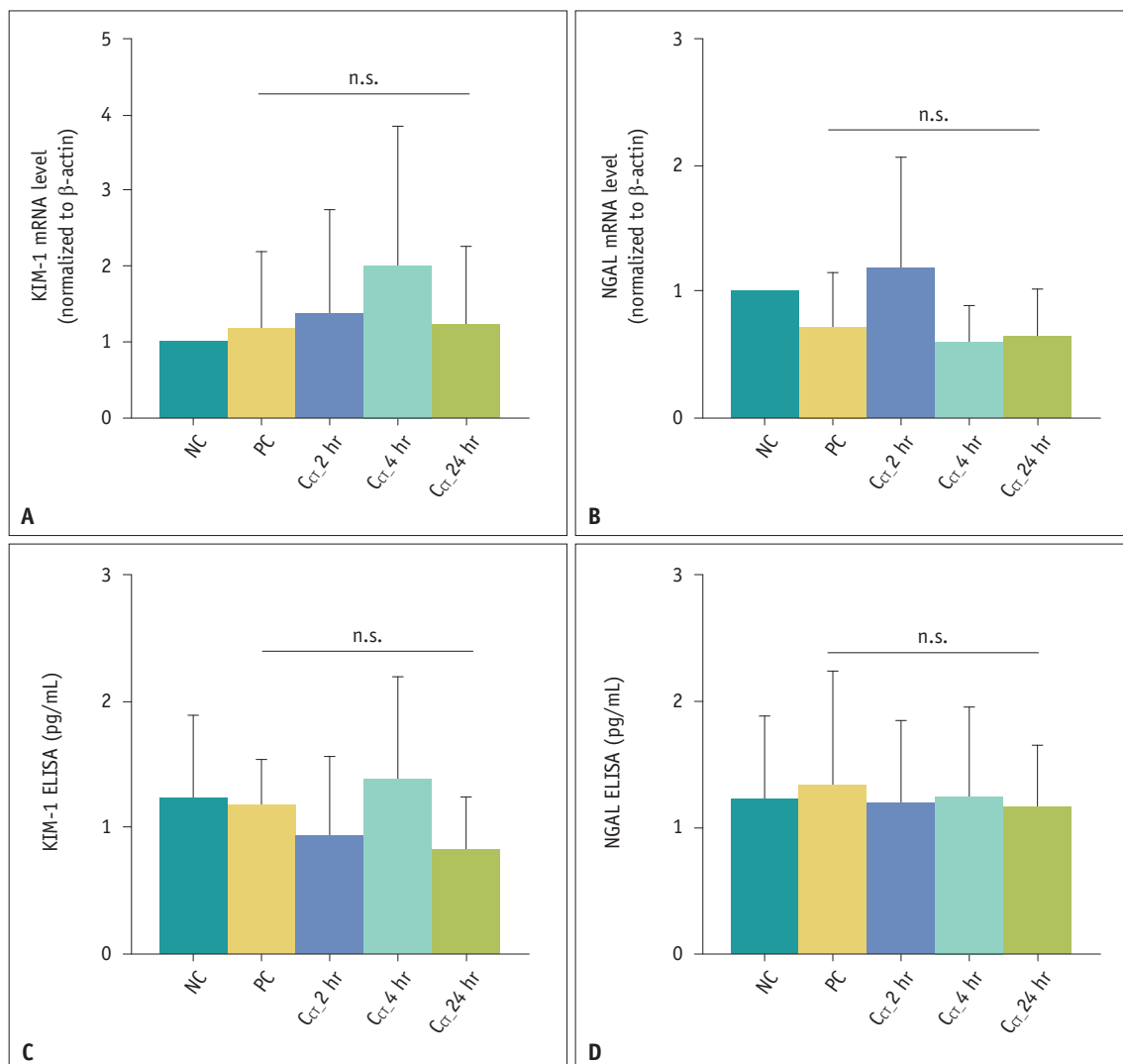


Fig. 3. Renal injury markers after repeated CT contrast agent administration. **A-D:** Real-time polymerase chain reaction was used to measure the mRNA expression of KIM-1 and NGAL (**A, B**). An ELISA was used to quantify protein levels of KIM-1 and NGAL (**C, D**). Regardless of time intervals, the repeated exposure to the CT contrast agent did not affect both mRNA and protein levels of KIM-1 and NGAL. Results are presented as the mean ± standard deviation. KIM-1 = kidney injury molecule-1, NGAL = neutrophil gelatinase-associated lipocalin, ELISA = enzyme-linked immunosorbent assay, NC = negative control, PC = positive control, C_{CT}_2, 4, and 24 hr = an additional dose of CT contrast agent within 2, 4, or 24 hours after the single-dose administration of CT contrast agent, n.s. = no significance

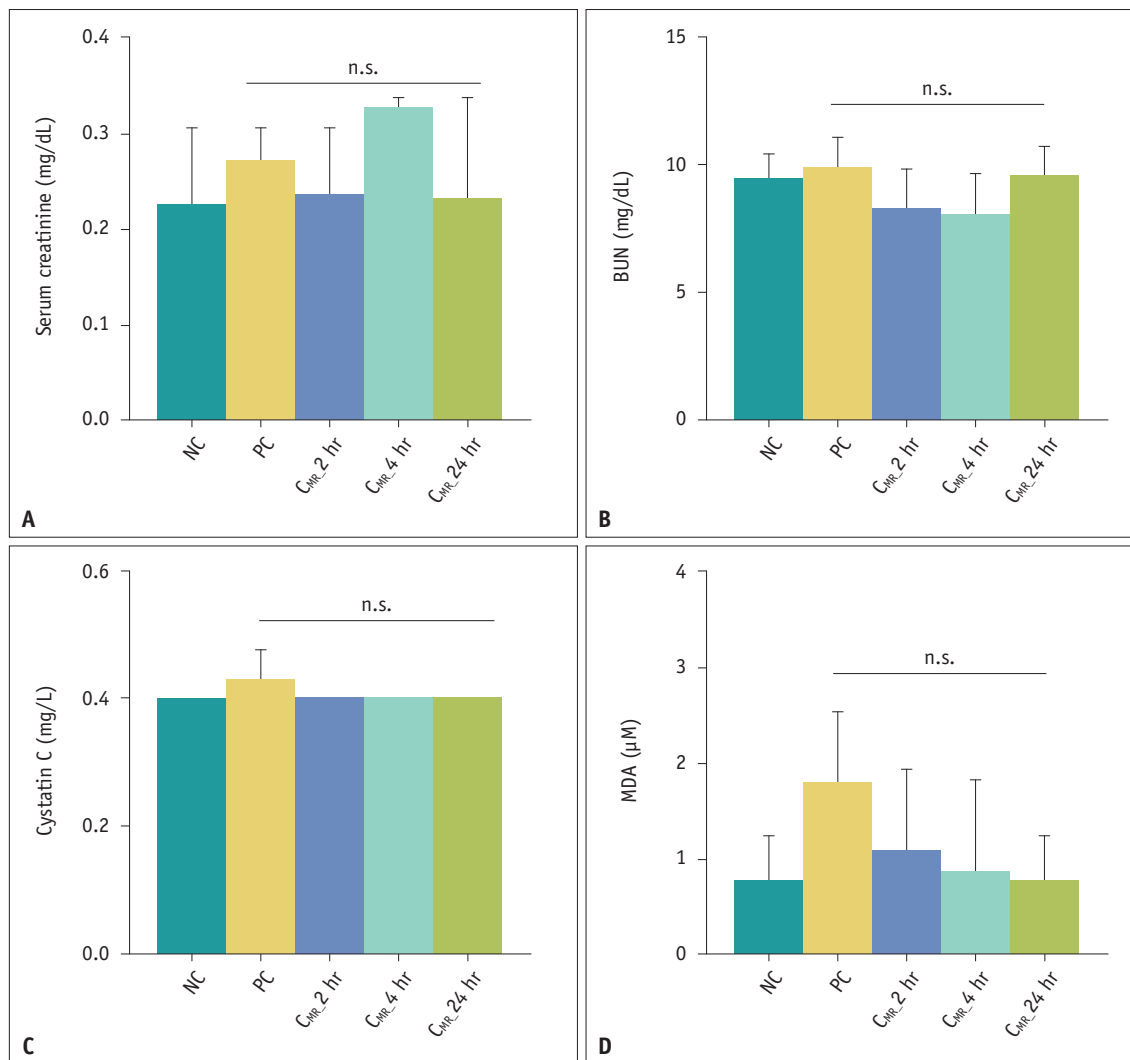


Fig. 4. Renal function and oxidative stress markers after the additional administration of MR contrast agents following the single-dose administration of CT contrast agents. **A-D:** Serum creatinine (**A**), BUN (**B**), cystatin C (**C**), and MDA (**D**) levels were not significantly different between the PC and contrast exposure groups. Results are presented as the mean ± standard deviation. BUN = blood urea nitrogen, MDA = malondialdehyde, PC = positive control, NC = negative control, C_{MR}_2, 4, and 24 hr = an additional dose of MR contrast agent within 2, 4, or 24 hours after the single-dose administration of CT contrast agent, n.s. = no significance

DISCUSSION

Despite the widespread use of imaging modalities, evidence to establish the optimal time interval between multiple exposures to iodine- and gadolinium-based contrast agents is still scarce. This study found that the administration of an MR contrast agent within 24 hours after the injection of a CT contrast agent did not significantly affect renal function and renal injury markers in rats. However, the repeated administration of a CT contrast agent within short time periods significantly increased the SCr levels, although the levels of other renal injury markers, including Cys C, KIM-1, and NGAL, were

not significantly different between rats with a single and repeated administration of a CT contrast agent.

The half-lives of iodine- and gadolinium-based contrast agents differ according to the types of contrast agent, injected dose, and patient's renal function, but the elimination half-lives of both CT and MR contrast agents are usually 1–2 hours [14–17]. Intravenously injected CT contrast agents are eliminated exclusively through glomerular filtration, and in the case of healthy individuals, approximately 83% of the contrast dose is detected in urine within 3 hours of its administration [17]. Based on this pharmacokinetics, the ESUR guidelines recommend an interval of at least 4 hours between administrations of iodine-based and gadolinium-

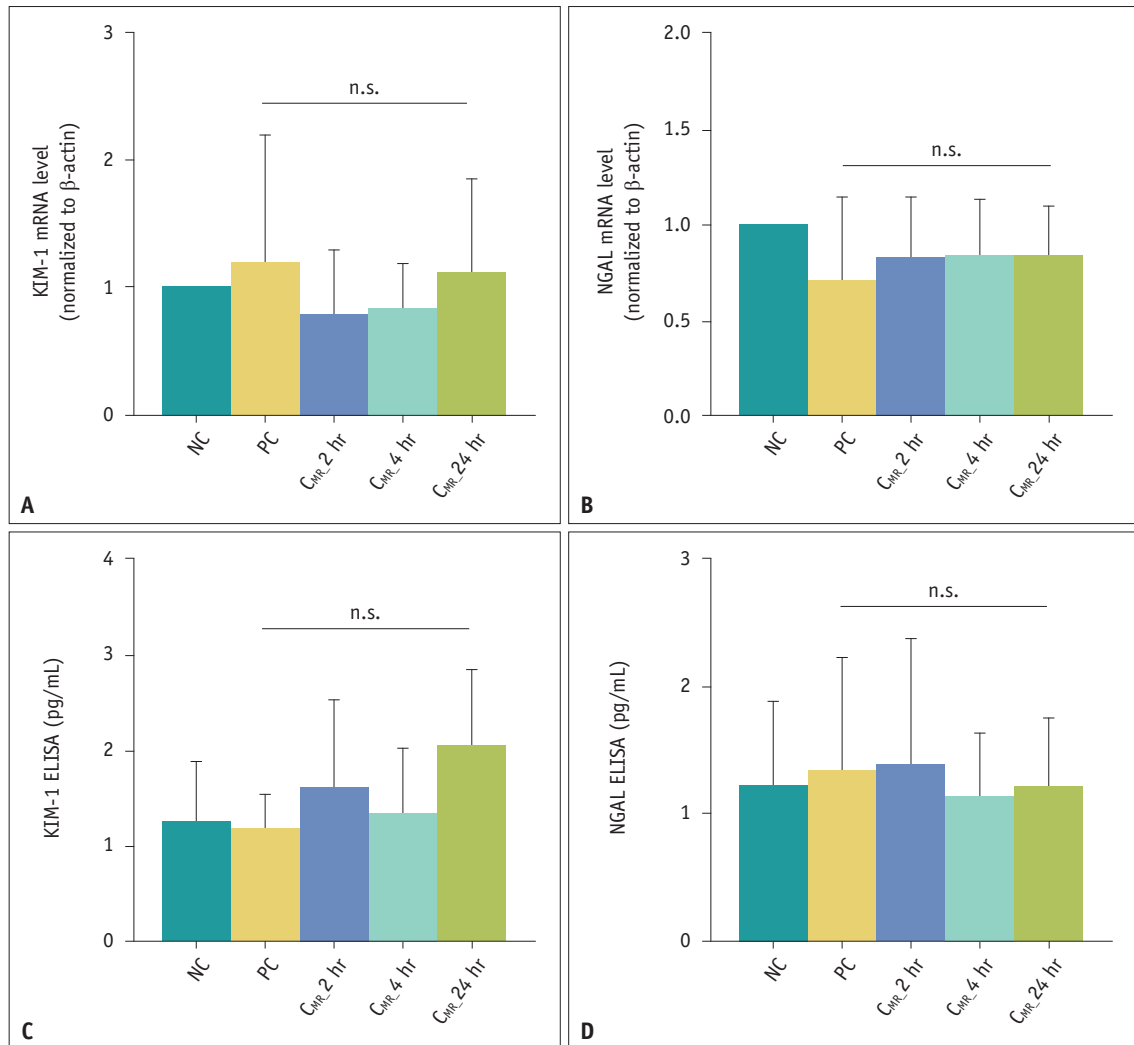


Fig. 5. Renal injury markers after the additional administration of MR contrast agents following the single-dose administration of CT contrast agents. **A-D:** The mRNA expression levels of KIM-1 and NGAL were measured using the real-time polymerase chain reaction (**A, B**), and the protein levels of KIM-1 and NGAL were quantified using the ELISA (**C, D**). Additional injection of MR contrast agent did not significantly affect both mRNA and protein levels of KIM-1 and NGAL. Results are presented as the mean ± standard deviation. KIM-1 = kidney injury molecule-1, NGAL = neutrophil gelatinase-associated lipocalin, ELISA = enzyme-linked immunosorbent assay, NC = negative control, PC = positive control, C_{MR} 2, 4, and 24 hr = an additional dose of MR contrast agent within 2, 4, or 24 hours after the single-dose administration of CT contrast agent, n.s. = no significance

based contrast agents to reduce potential nephrotoxicity in patients with normal or moderately reduced renal function (GFR > 30 mL/min/1.73 m²) [3]. However, our results on the additional MR contrast agent injections after the CT contrast agent administration showed that renal function (as indicated by SCr and BUN levels) was not affected. In addition, renal injury markers did not increase even with a 2-hour interval between the injections. These findings may support performing contrast-enhanced CT and MRI on the same day without limitations on the time interval between them.

For repeated administration of iodine-based contrast agents on the same day, the ESUR also recommends

the same interval of at least 4 hours between two CT examinations in patients with normal or moderately reduced renal function [3]. The current study found significantly increased SCr levels after administration of the second CT contrast agent up to 24 hours within the first administration. Hence, it would likely be better to maintain the interval between contrast-enhanced CT examinations as long as possible. If a repeated contrast-enhanced CT examination within a short period is inevitable, such as in an emergency, other preventive methods, such as hydration, should be considered to prevent PC-AKI.

In addition to SCr, Cys C, KIM-1, and NGAL are recently

developed indicators of renal function that can be used for early detection of PC-AKI, and they have shown good predictive value [18-21]. In our study, additional doses of CT contrast agent within short time intervals increased SCr in rats, whereas there were no significant differences in KIM-1 and NGAL levels throughout the different time intervals. This discrepancy may be because increased SCr represents a loss of kidney function, while increased expressions of KIM-1 and NGAL suggest kidney injury [22-24]. When the recent definition of AKI is applied, small changes in renal function (i.e., decreased GFR) without tissue injury can be diagnosed as AKI [23,24]. The decrease in renal function without tissue injury after two administrations of CT contrast agent with a short time interval might be because the animals used in this study did not have chronic renal disease or risk factors for kidney disease. Another possible explanation for the discrepancy might be that the rats were sacrificed, and their serum and renal tissues were obtained 24 hours after the last dose of CT contrast agent. SCr changes in patients with PC-AKI are usually observed 24–48 hours after the contrast exposure, while significant elevations in NGAL and serum Cys C are observed after 2 and 8 hours, respectively [5,25]. The levels of Cys C, KIM-1, and NGAL in this study remained unchanged, and this could be because, given the minimal renal tissue injury, they increased early and had already returned to baseline when the serum samples were obtained. Regarding BUN levels, significant increases were observed after the additional doses of CT contrast agent, excluding the BUN level in C_{CT} 4 hr. This variation in study results may be due to the limited sample size. Unlike repeated exposure to CT contrast agents, additional dose of MR contrast agent after the administration of CT contrast agent did not affect SCr or the other renal injury markers.

There are limitations to this study. First, the number of rats in each group was small. Second, direct translation of our study results to human subjects and clinical situations may be premature because of an inherent limitation of almost every animal study: rat models may not perfectly reflect human responses. Despite these limitations, our study provides instrumental evidence to discuss and re-define the time intervals between repeated contrast-enhanced examinations. Third, based on routinely adopted experimental protocols, we sacrificed the rats 24 hours after the last administration of a contrast agent. However, since the diagnostic criteria of PC-AKI is an increase in SCr within 48–72 hours from the injection of contrast

agents, future studies with a time interval of 48 or 72 hours between contrast agent injection and serum and renal tissue acquisitions are necessary to investigate the discrepancy between levels of SCr and other renal injury markers. Furthermore, the Korean Clinical Practice Guidelines for adverse reactions to intravenous iodinated and MRI-gadolinium contrast agents [26] recommend withholding MR contrast agent administration in patients with severely reduced renal function ($GFR < 30 \text{ mL/min/1.73 m}^2$). However, in this study, we did not analyze risk factors for AKI or pre-existing renal dysfunction and conducted experiments with male rats with normal renal function. Therefore, further studies using animals with renal dysfunction or risk factors for AKI are necessary to generalize our study results. Additionally, even though the change in SCr is usually observed later than the incidence of AKI [27], the assessment of SCr before conducting contrast-enhanced MRI on the same day as contrast-enhanced CT may be necessary to prevent PC-AKI. As such, future studies are needed to investigate the practicality of SCr evaluation within the short interval between multiple exposures to iodine- and gadolinium-based contrast agents.

In conclusion, performing contrast-enhanced MRI on the same day as contrast-enhanced CT may not induce clinically significant deterioration of renal function. However, repeated contrast-enhanced CT examinations within a short time period may result in significant deterioration of renal function, and thus, a sufficient time interval, probably more than 24 hours, may be needed.

Supplement

The Supplement is available with this article at <https://doi.org/10.3348/kjr.2023.0712>.

Availability of Data and Material

The datasets generated or analyzed during the study are included in this published article and its supplement.

Conflicts of Interest

The authors have no potential conflicts of interest to disclose.

Author Contributions

Conceptualization: Yong Eun Chung. Data curation: Heejin Bae, Hyewon Oh, Ga Bin Park. Formal analysis: Heejin Bae, Hyewon Oh, Ga Bin Park. Funding acquisition: Heejin Bae, Yong Eun Chung. Investigation: Heejin Bae, Hyewon Oh.

Methodology: Yong Eun Chung. Project administration: Yong Eun Chung. Resources: Hyewon Oh, Ga Bin Park. Supervision: Yong Eun Chung. Validation: Heejin Bae, Hyewon Oh. Visualization: Heejin Bae, Hyewon Oh. Writing—original draft: Heejin Bae, Hyewon Oh, Yong Eun Chung. Writing—review & editing: Heejin Bae, Hyewon Oh, Yong Eun Chung.

ORCID IDs

Heejin Bae

<https://orcid.org/0000-0002-1227-8646>

Hyewon Oh

<https://orcid.org/0000-0003-4985-8000>

Ga Bin Park

<https://orcid.org/0009-0002-0155-9263>

Yong Eun Chung

<https://orcid.org/0000-0003-0811-9578>

Funding Statement

This work was supported by the faculty research grant from Yonsei University College of Medicine (grant number: 6-2021-0122).

REFERENCES

- Hasebroock KM, Serkova NJ. Toxicity of MRI and CT contrast agents. *Expert Opin Drug Metab Toxicol* 2009;5:403-416
- Wichmann JL, Katzberg RW, Litwin SE, Zwerner PL, De Cecco CN, Vogl TJ, et al. Contrast-induced nephropathy. *Circulation* 2015;132:1931-1936
- European Society of Urogenital Radiology. ESUR guidelines on contrast agents 10.0 [accessed on May 25, 2022]. Available at: https://www.esur.org/wp-content/uploads/2022/03/ESUR-Guidelines-10_0-Final-Version.pdf
- American College of Radiology. ACR manual on contrast media 2022 [accessed on May 25, 2022]. Available at: https://www.acr.org/-/media/ACR/files/clinical-resources/contrast_media.pdf
- Mohammed NM, Mahfouz A, Achkar K, Rafie IM, Hajar R. Contrast-induced nephropathy. *Heart Views* 2013;14:106-116
- Tao SM, Wichmann JL, Schoepf UJ, Fuller SR, Lu GM, Zhang LJ. Contrast-induced nephropathy in CT: incidence, risk factors and strategies for prevention. *Eur Radiol* 2016;26:3310-3318
- Mitchell AM, Kline JA, Jones AE, Tumlin JA. Major adverse events one year after acute kidney injury after contrast-enhanced computed tomography. *Ann Emerg Med* 2015;66:267-274.e4
- Rudnick M, Feldman H. Contrast-induced nephropathy: what are the true clinical consequences? *Clin J Am Soc Nephrol* 2008;3:263-272
- Mitchell AM, Jones AE, Tumlin JA, Kline JA. Incidence of contrast-induced nephropathy after contrast-enhanced computed tomography in the outpatient setting. *Clin J Am Soc Nephrol* 2010;5:4-9
- Park JH, Shin HJ, Choi JY, Lim JS, Park MS, Kim MJ, et al. Is there association between statin usage and contrast-associated acute kidney injury after intravenous administration of iodine-based contrast media in enhanced computed tomography? *Eur Radiol* 2020;30:5261-5271
- van der Molen AJ, Reimer P, Dekkers IA, Bongartz G, Bellin MF, Bertolotto M, et al. Post-contrast acute kidney injury – Part 1: definition, clinical features, incidence, role of contrast medium and risk factors: recommendations for updated ESUR Contrast Medium Safety Committee guidelines. *Eur Radiol* 2018;28:2845-2855
- Abujudeh HH, Gee MS, Kaewlai R. In emergency situations, should serum creatinine be checked in all patients before performing second contrast CT examinations within 24 hours? *J Am Coll Radiol* 2009;6:268-273
- Trivedi H, Foley WD. Contrast-induced nephropathy after a second contrast exposure. *Ren Fail* 2010;32:796-801
- Geenen RW, Kingma HJ, van der Molen AJ. Contrast-induced nephropathy: pharmacology, pathophysiology and prevention. *Insights Imaging* 2013;4:811-820
- Bellin MF. MR contrast agents, the old and the new. *Eur J Radiol* 2006;60:314-323
- Perazella MA. Current status of gadolinium toxicity in patients with kidney disease. *Clin J Am Soc Nephrol* 2009;4:461-469
- Currie GM. Pharmacology, part 5: CT and MRI contrast media. *J Nucl Med Technol* 2019;47:189-202
- Akdeniz D, Celik HT, Kazanci F, Yilmaz H, Yalcin S, Bilgic MA, et al. Is kidney injury molecule 1 a valuable tool for the early diagnosis of contrast-induced nephropathy? *J Investig Med* 2015;63:930-934
- Wang ZY, Wang YL, Wei J, Jin L, Wang ZC. Role of serum cystatin C in the prediction of contrast-induced nephropathy after intra-arterial interventions. *Chin Med J (Engl)* 2020;133:408-414
- Quintavalle C, Anselmi CV, De Micco F, Roscigno G, Visconti G, Golia B, et al. Neutrophil gelatinase-associated lipocalin and contrast-induced acute kidney injury. *Circ Cardiovasc Interv* 2015;8:e002673
- Wacker-Gußmann A, Bühren K, Schultheiss C, Braun SL, Page S, Saugel B, et al. Prediction of contrast-induced nephropathy in patients with serum creatinine levels in the upper normal range by cystatin C: a prospective study in 374 patients. *AJR Am J Roentgenol* 2014;202:452-458
- Murty MS, Sharma UK, Pandey VB, Kankare SB. Serum cystatin C as a marker of renal function in detection of early acute kidney injury. *Indian J Nephrol* 2013;23:180-183
- Kellum JA, Romagnani P, Ashuntantang G, Ronco C, Zarbock A, Anders HJ. Acute kidney injury. *Nat Rev Dis Primers* 2021;7:52
- Ronco C, Bellomo R, Kellum JA. Acute kidney injury. *Lancet* 2019;394:1949-1964

25. Oh H, Choi A, Seo N, Lim JS, You JS, Chung YE. Protective effect of glycyrrhizin, a direct HMGB1 inhibitor, on post-contrast acute kidney injury. *Sci Rep* 2021;11:15625
26. Oh SW, Park SY, Yong HS, Choi YH, Cha MJ, Kim TB, et al. Korean clinical practice guidelines for adverse reactions to intravenous iodinate and MRI-gadolinium contrast agents: revised clinical consensus and recommendations (3rd edition, 2022). *J Korean Soc Radiol* 2022;83:254-264
27. Fähring M, Seeliger E, Patzak A, Persson PB. Understanding and preventing contrast-induced acute kidney injury. *Nat Rev Nephrol* 2017;13:169-180