

The branching patterns and termination points of the facial artery: a cadaveric anatomical study

Vu Hoang Nguyen¹, Lin Cheng-Kuan², Tuan Anh Nguyen³, Trang Huu Ngoc Thao Cai³

¹Department of Anatomy, University of Medicine and Pharmacy, Ho Chi Minh City, Vietnam

²Department of Environmental Health, Harvard T.H. Chan School of Public Health, Boston, MA, USA

³Department of Plastic and Cosmetic Surgery, University of Medicine and Pharmacy, Ho Chi Minh City, Vietnam

Background: The facial artery is an important blood vessel responsible for supplying the anterior face. Understanding the branching patterns of the facial artery plays a crucial role in various medical specialties such as plastic surgery, dermatology, and oncology. This knowledge contributes to improving the success rate of facial reconstruction and aesthetic procedures. However, debate continues regarding the classification of facial artery branching patterns in the existing literature.

Methods: We conducted a comprehensive anatomical study, in which we dissected 102 facial arteries from 52 embalmed and formaldehyde-fixed Vietnamese cadavers at the Anatomy Department, University of Medicine and Pharmacy, Ho Chi Minh City, Vietnam.

Results: Our investigation revealed eight distinct termination points and identified 35 combinations of branching patterns, including seven arterial branching patterns. These termination points included the inferior labial artery, superior labial artery, inferior alar artery, lateral nasal artery, angular artery typical, angular artery running along the lower border of the orbicularis oculi muscle, forehead branch, duplex, and short course (hypoplastic). Notably, the branching patterns of the facial artery displayed marked asymmetry between the left and right sides within the same cadaver.

Conclusion: The considerable variation observed in the branching pattern and termination points of the facial artery makes it challenging to establish a definitive classification system for this vessel. Therefore, it is imperative to develop an anatomical map summarizing the major measurements and geometric features of the facial artery. Surgeons and medical professionals involved in facial surgery and procedures must consider the detailed anatomy and relative positioning of the facial artery to minimize the risk of unexpected complications.

Abbreviations: AA, angular artery; hLMA, horizontal labiomental artery; IAA, inferior alar artery; ILA, inferior labial artery; LNA, lateral nasal artery; OOc, orbicularis oculi muscle; SLA, superior labial artery

Keywords: Arteries / Cosmetic techniques / Dermal fillers / Face / Methods / Nose / Plastic surgery procedures / Surgical flaps

INTRODUCTION

The facial artery, which originates from the external carotid ar-

tery, plays a critical role in supplying the anterior face with the majority of its blood supply. It starts at the border of the lip, crosses the jaw, and ascends between the nostrils and the cheek, ultimately reaching the submandibular gland [1]. Although the facial artery has been the subject of numerous studies, there is still ongoing debate in the literature about its classification, branching structure, and termination points. Various authors have proposed classifications for the branching patterns of the facial artery across the face, but a consensus has yet to be established [2-5].

Extensive anatomical investigations of dissected cadavers have provided valuable insights into the facial artery [2-14]. Previous

Correspondence: Trang Huu Ngoc Thao Cai
Department of Plastic and Cosmetic Surgery, University of Medicine and Pharmacy, 217 Hong Bang Street, Ward 11, District 5, Ho Chi Minh City 1700, Vietnam
E-mail: thaotrang@ump.edu.vn

How to cite this article:
Nguyen VH, Cheng-Kuan L, Nguyen TA, Cai THNT. The branching patterns and termination points of the facial artery: a cadaveric anatomical study. Arch Craniofac Surg 2024;25(2):77-84.
https://doi.org/10.7181/acfs.2024.00038

Received January 22, 2024 / Revised February 21, 2024 / Accepted April 19, 2024

research has identified the angular, superior, and inferior labial arteries, as well as the lateral nasal arteries (LNAs) or alar arteries, named for the anatomical regions they supply. However, the complexity of the branching patterns and the termination point of the facial artery has been obscured by the use of different terminologies in various studies.

Several studies have attempted to categorize the facial artery based on its distribution. Pinar et al. [15], Loukas et al. [10], and Koziej et al. [7] identified five distinct types of facial artery distribution, while Yang et al. [16], Dickson et al. [2], and Niemann et al. [12] reported six types. Furukawa et al. [4] described four types. The identification of the ultimate branch of the facial artery is still a subject of debate in the field. In this study, we used the terminology from Terminologia Anatomica (2020), abbreviated as TA98, for the well-known tributaries of the facial artery: the inferior labial artery (ILA; TA2 code: A12.2.05.025), the superior labial artery (SLA; TA2 code: A12.2.05.026), and the lateral nasal branch (TA2 code: A12.2.05.028). Although the branch that supplies the ala of the nose is not listed in TA2, it is commonly referred to as the inferior alar branch.

Recent anatomical investigations have shed light on the branching patterns of the ILA. Two distinct patterns have been observed. The first pattern follows the vermilion border of the lower lip and emerges from the facial artery at the cheilion (mouth corner). The second pattern, referred to as the horizontal labiomental artery (hLMA), descends along the labiomental crease and passes beneath the cheilion. Al-Hoqail and Meguid [1] and Kawai et al. [17] have noted that the submental artery can adopt the first pattern, giving rise to the vertical labiomental arteries, or it can divide into multiple vertical branches of the hLMA and anastomose with the ILA. The terminal tributary of the facial artery that enters the angular region is known as the angular artery (AA; TA98 code: A12.2.05.029). The AA can take two courses. The typical course runs along the side of the nose, while the AA-OOc runs along the lower border of the orbicularis oculi muscle (OOc). Although the facial artery usually follows the first pattern, there are instances where it follows an atypical path along the lower border of the OOc, referred to as the zygomatic branch [15], infraorbital trunk [8], dominant lateral branch [4], or de-toured branch [8]. The objective of this study was to conduct a comprehensive and detailed analysis of the branching structure and the termination points of the facial artery throughout the face.

METHODS

Specimen collection and preparation

This cross-sectional study was conducted in the Anatomy De-

partment of the University of Medicine and Pharmacy at Ho Chi Minh City, Vietnam, from March to December 2021. A total of 52 adult Vietnamese cadavers, which had been embalmed and fixed with formaldehyde, were selected for the dissection of the facial artery. The cadavers were sourced from various individuals who had donated their bodies for medical education and research purposes.

Dissection procedures

A team of experienced anatomists and medical professionals conducted the dissections. Each cadaver underwent a thorough examination before dissection to ensure there were no craniofacial anomalies or pathologies that might compromise the integrity of the facial arteries. The dissection protocol adhered to the standardized anatomical guidelines detailed in *Cunningham's Manual of Practical Anatomy* [18]. The dissections took place under controlled laboratory conditions, with the team using appropriate personal protective equipment and surgical instruments.

To access the facial arteries, a midline incision was made along the neck and face. The skin, platysma, and superficial fascia covering the carotid triangle on both sides were meticulously reflected laterally. After reflecting the deep cervical fascia, the boundaries of the sternocleidomastoid muscles and the superior belly of the omohyoid were identified. Careful dissection techniques were employed to avoid any damage to the surrounding structures.

Next, the submandibular gland was mobilized by delineating the boundaries of the posterior bellies of the digastric and stylohyoid muscles. Upon opening the carotid sheath within the carotid triangle, the external carotid artery and its branches were identified. The external carotid artery in the neck features three primary branches, with the facial artery being the third. This approach improved visualization and access to the carotid sheath, enabling the clear identification of the external carotid artery and its branches. The facial artery, as the third branch of the external carotid artery in the neck, was carefully traced and dissected.

Throughout the dissection process, a $\times 2.5$ magnification loupe was utilized to enhance precision and accuracy. The branching patterns and termination points of the facial artery within the face were meticulously observed and documented. Dissections were performed on a total of 102 hemifaces, obtained from 52 cadavers.

Data collection and analysis

Detailed notes were taken and anatomical drawings were made during the dissection process to document the observed branching patterns and termination points of the facial artery. The data collected were then organized and analyzed to identify common

patterns and variations. Statistical analyses, including frequency distributions and descriptive statistics, were used to summarize the findings. The results were presented in tables and accompanied by anatomical illustrations to offer a comprehensive visual representation of the branching patterns and termination points of the facial artery.

Quality control measures

To ensure the accuracy and reliability of our findings, we implemented quality control measures throughout the dissection process. The dissection team engaged in regular discussions and consultations to address any discrepancies or uncertainties encountered. Additionally, cross-validation of observed patterns

and measurements was performed by multiple experienced anatomists to enhance the validity of the data.

RESULTS

The study included 52 adult Vietnamese cadavers, with an average age at death of 74.31 years, ranging from 32 to 100 years. Among these cadavers, 17 were female and 35 were male. The researchers dissected a total of 102 facial arteries from the cadavers. Of the 52 cadavers, 50 were used to obtain the 102 facial arteries, with an equal number of 51 arteries dissected from both the left and right sides. Additionally, one artery from each side was included despite tissue injury. The majority of the facial arteries, 95%, originated directly from the external carotid artery. In contrast, 6% arose from the linguofacial trunk, and 1% from the thyrolingual trunk.

The 102 evaluated facial arteries exhibited a range of branches by the following frequencies: one branch was observed in eight cases (7.84%), two branches in 13 cases (11.75%), three branches in 28 cases (27.45%), four branches in 33 cases (32.35%), five branches in 18 cases (17.65%), six branches in one case (0.98%).

The facial artery has eight types of branches (ILA, SLA, inferior alar artery [IAA], LNA, AA typical, AA-OOc, forehead branch, and duplex) in 35 combinations (Table 1). Importantly, the branching patterns and termination sites were found to be asymmetrical between the left and right sides. Additionally, these facial arteries provided arterial blood supply to the respective opposing sides of the face.

Among eight types of branches, the SLA was the most preva-

Table 1. Combinations of branching patterns of 102 FAs in our study

FA type	Combinations of branching patterns	No.
Inferior labial artery type	ILA	5
Superior labial type	ILA, SLA	3
	SLA	2
Alar type	ILA, SLA, IAA	5
	SL, IA	2
Nasal type	LN	1
	IL, SL, LN	9
	IL, SL, IA, LN	17
	SL, LN	2
Angular type: At	SL, IA, LN	4
	IL, LN, At	1
	IL, IA, LN, At	1
	IL, At	1
	IL, SL, LN, At	4
	IL, SL, IA, LN, At	8
	IL, SL, IA, At	2
IL, SL, At	1	
Angular type: AA-OOc	SL, IA, LN, At	3
	IL, AA-OOc	1
	IL, SL, IA, LN, AA-OOc	2
	IL, SL, IA, AA-OOc	1
	IL, SL, AA-OOc	3
	SL, IA, LN, AA-OOc	2
	SL, AA-OOc	1
Angular type: forehead branch	IL, SL, LNA, F	1
	SL, F	1
Duplex type	IL, IOT	1
	IL, LN, IOT	1
	IL, SL, IOT	3
	IL, SL, LN, IOT	1
	IL, SL, IA, LN, IOT	8
	ILA, SLA, IA, LN, A, IOT	1
	SL, IOT	1
	SL, IA, IOT	1
	SL, IA, LN, IOT	1
Hypoplastic type	FA short course	1

FA, facial artery; IL, inferior labial; ILA, IL artery; SL, superior labial; SLA, SL artery; IA, inferior alar; IAA, IA artery; LN, lateral nasal; LNA, LN artery; At, angular artery typical; AA, angular artery; AA-OOc, AA along the lower border of the orbicularis oculi muscle; F, forehead branch; IOT, infraorbital trunk.

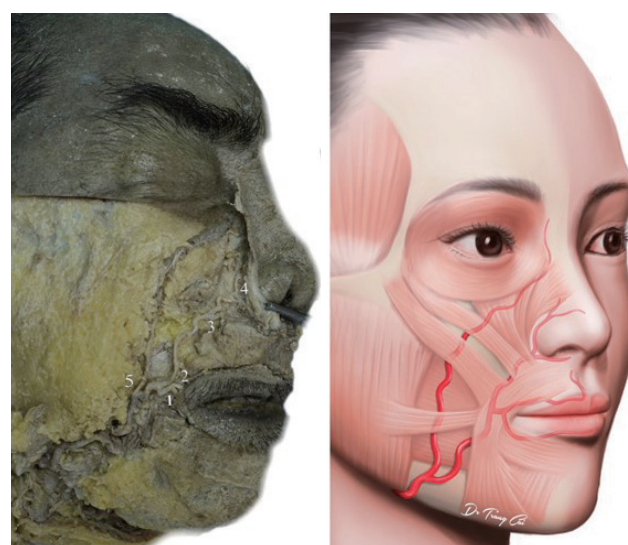


Fig. 1. Facial artery, duplex type. (1) The inferior labial artery (ILA), typical ILA. (2) The superior labial artery. (3) The inferior alar artery (IAA), IAA from facial artery. (4) The lateral nasal artery. (5) The infraorbital trunk.

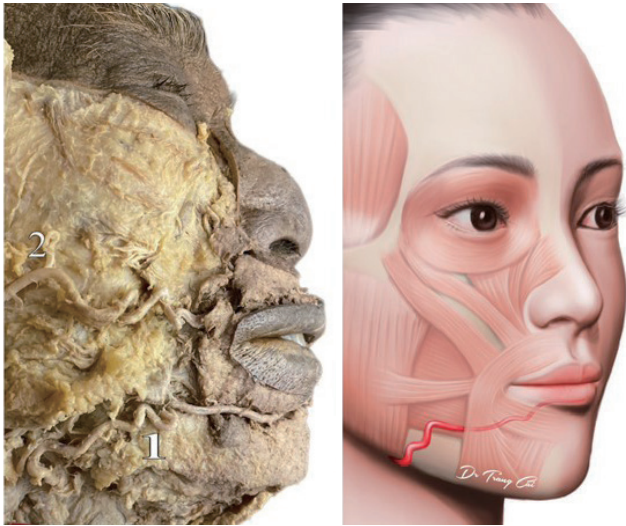


Fig. 2. Facial artery, inferior labial type. (1) The inferior labial artery (ILA) horizontal labiomenal artery (hLMA) or ILA with a hLMA pattern. (2) The transverse facial artery.

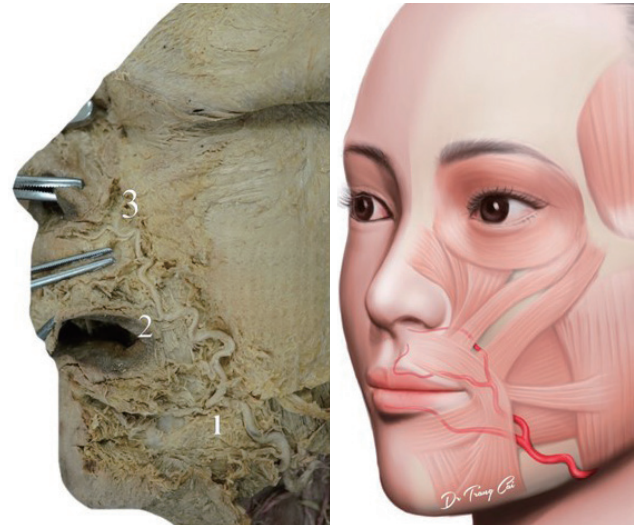


Fig. 4. Facial artery, alar type. (1) The inferior labial artery (ILA) horizontal labiomenal artery (hLMA) or ILA with a hLMA pattern. (2) The superior labial artery. (3) The inferior alar artery (IAA), IAA from facial artery.

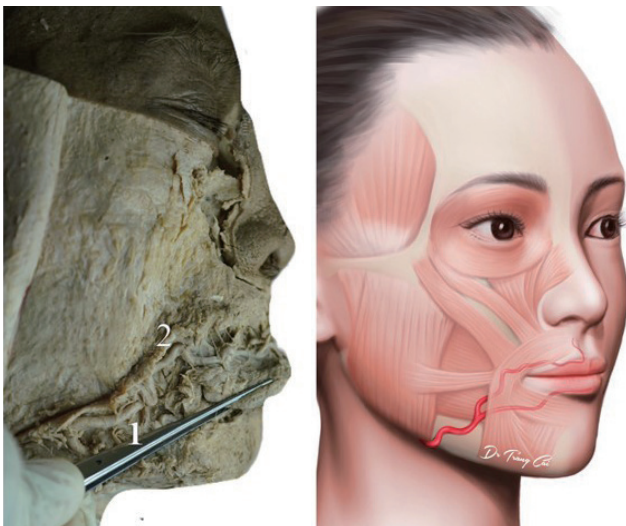


Fig. 3. Facial artery, superior labial type. (1) The inferior labial artery (ILA) horizontal labiomenal artery (hLMA) or ILA with a hLMA pattern. (2) The superior labial artery.

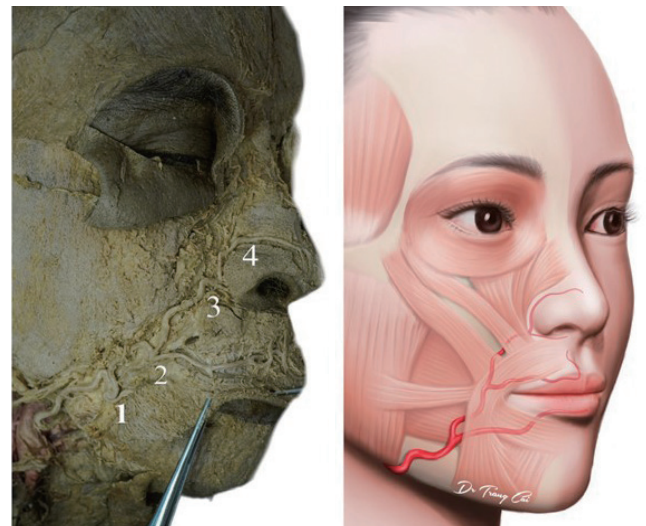


Fig. 5. Facial artery, nasal type. (1) The inferior labial artery (ILA) horizontal labiomenal artery (hLMA) or ILA with a hLMA pattern. (2) The superior labial artery. (3) The inferior alar artery (IAA), IAA from facial artery. (4) The lateral nasal artery.

lent branch, accounting for 89 specimens (87.25%), followed by the ILA 80 specimens (78.43%), LNA 67 specimens (64.71%), 59 specimens IAA (57.84%), AA typical 22 specimens (21.57%), AA-OOc 10 specimens (9.80%), forehead branch two specimens (1.96%), and duplex 18 specimens (17.65%). In one specimen (0.98%), the facial artery exhibited a brief course in the inferior labial area. On the other hand, one specimen had AA and duplex together (Table 1).

Of the 80 ILAs observed, nine displayed the first typical ILA pattern (Fig. 1), while 71 displayed the second pattern known as hLMA or ILA with a hLMA pattern (Figs. 2-7).

Furthermore, out of 59 IAAs from facial artery (Figs. 1, 4, 5, 8), there were 13 IAAs not a branch of the facial artery. These IAAs originated from the SLA in six cases (Fig. 7), the contralateral SLA in four cases, the contralateral LNA in two cases, and the infraorbital artery in one case.

Figs. 1-9 show the branching patterns of 102 facial arteries according to their terminations. Eight distinct termination points are ILA, SLA, IAA, LNA, AA, forehead branch, duplex and under the inferior labial area (hypoplastic type). The results showed that the facial artery terminated as ILA in five cases (4.90%) in

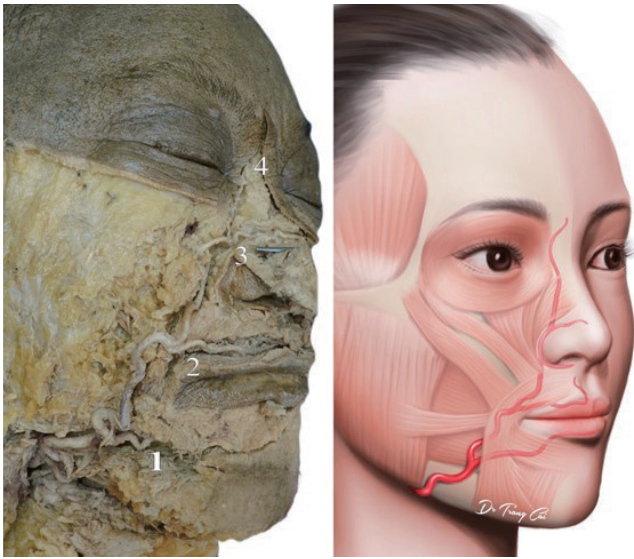


Fig. 6. Facial artery, angular typical type. (1) The inferior labial artery (ILA) horizontal labiomental artery (hLMA) or ILA with a hLMA pattern. (2) The superior labial artery. (3) The lateral nasal artery. (4) The angular artery typical type.

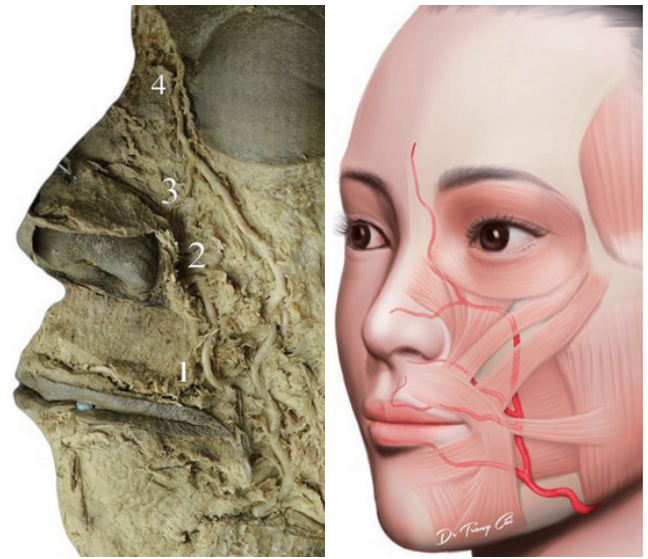


Fig. 8. Facial artery, angular AA-OOc type. (1) The superior labial artery. (2) The inferior alar artery (IAA), IAA from facial artery. (3) The lateral nasal artery. (4) The angular artery along the lower border of the orbicularis oculi muscle type (AA-OOc type).

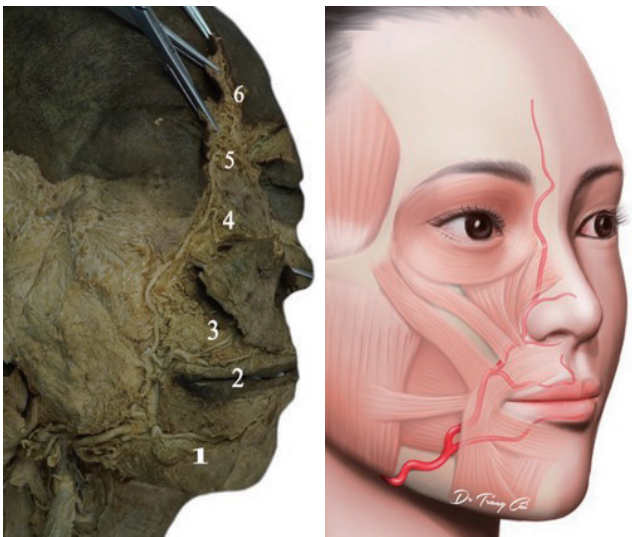


Fig. 7. Facial artery, angular type with forehead branch. (1) The inferior labial artery (ILA) horizontal labiomental artery (hLMA) or ILA with a hLMA pattern. (2) The superior labial artery (SLA). (3) The inferior alar artery (IAA), IAA from SLA. (4) The lateral nasal artery. (5) The angular artery. (6) Forehead branch.

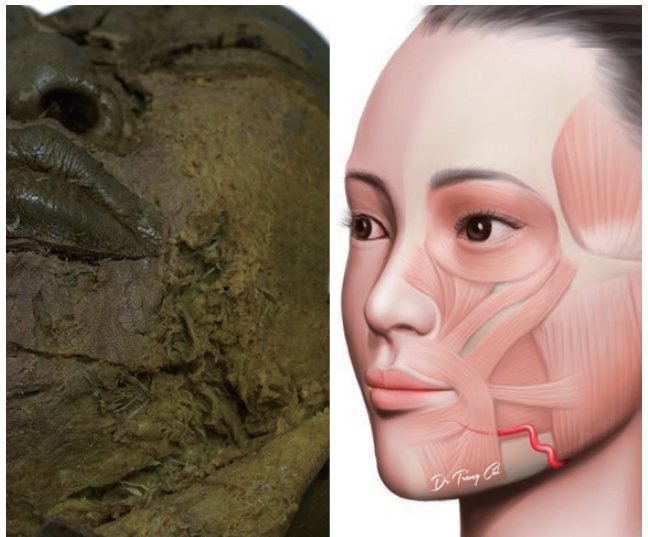


Fig. 9. Facial artery, hypoplastic type.

Fig. 2, as SLA in five cases (4.90%) in Fig. 3, as IAA in seven cases (6.86%) in Fig. 4, as LNA in 33 cases (32.35%) in Fig. 5, as AA in 31 cases (30.39%) in Figs. 6 and 8, as forehead branch in two cases (1.96%) in Fig. 7. Notably, in the duplex of 18 cases (17.65%) in Fig. 1, a prominent lateral angular branch traveled down the nasojugal groove, along the lower border of the OOc before terminating at the nasion. The duplex facial artery type exhibited nine combination patterns (Table 1). In one instance, the facial

artery terminated under the inferior labial area after a brief course (Fig. 9).

Furthermore, 48 out of 102 cases (47.05%) had an ophthalmic artery with a dorsal nasal artery. Among these cases, there were three instances of the ILA type, two instances of the SLA type, 37 instances of the nasal angular type, and eight instances of the duplex type. Additionally, in three out of five cases, the transverse facial artery (Fig. 2), which is a kind of ILA, supplied blood to the lip and nose. In the case of the hypoplastic facial artery, the contralateral facial artery supplied the full remaining course.

DISCUSSION

The findings of our study lead to several significant conclusions. First, we have identified eight distinct termination points on the superior/distal aspect of the facial artery. Second, Table 1 provides a comprehensive overview of the 35 different branching patterns observed in the facial artery. Third, it is important to note the asymmetrical characteristics between the left and right sides of the face. Fourth, in rare cases, the facial artery may cross the midline to supply arterial blood to the opposite side of the face. Additionally, our study reveals discrepancies between our findings and those from previous studies regarding the branching patterns and termination points of the facial arteries. These differences raise questions about the reliability and utility of existing categorization schemes.

In our investigation, we observed a range of 1 to 6 visualized branches in the assessed frontal arteries, with the percentages of occurrence ranging from 0.98% for one branch to 31.37% for four branches. When compared with other studies, there are noticeable variations in the number of branches identified. For instance, Koziej [7] utilized computed tomographic angiography to analyze 255 facial arteries and found the following distribu-

tion: 35 cases (13.7%) had one branch, eight cases (3.1%) had five branches, 45 cases (17.6%) had four branches, 88 cases (34.5%) had three branches, 72 cases (28.2%) had two branches, and seven cases (2.7%) exhibited the hypoplastic type. An anatomical cadaver study of Kulkarni and Geetha [19] reported different branch counts: six branches in two cases, seven branches in 18 cases, eight branches in 43 cases, nine branches in 36 cases, and 10 branches in one case. These discrepancies underscore the necessity for additional research to achieve a consistent understanding of the branching patterns of the facial artery.

The reported prevalence of certain branch of FA, such as the AA, SLA, and ILA, also varies across studies [6,8] from 32.5% to 73.5% for the AA, from 77.5% to 98.0% for the SLA, and from 57.5% to 100% for the ILA. Our study yielded prevalence rates of 33.33%, 87.25%, and 78.43% for these arteries, respectively.

Recent anatomical investigations have shed light on the branching patterns of the ILA. Two distinct patterns have been observed [8]. The first pattern follows the vermilion border of the lower lip and emerges from the facial artery at the cheilion (mouth corner). The second pattern, referred to as the hLMA, descends along the labiomental crease and passes beneath the cheilion. Kawai et al. [17] and Al-Hoqail and Abdel Meguid [1]

Table 2. Summary of facial artery branching patterns

Author (year)	No.	ILA	SLA	IAA	LNA	AA/F	D	H
Our study (2023)	102 (52 cadavers)	5 (4.9)	5 (4.9)	7 (6.9)	33 (32.4)	33 (32.4) ^{a)}	18 (17.7)	1 (1.0)
Koziej et al. (2022) [6]	2,119 (meta-analysis)	15.6	15.6	5.9	69.8		1.7	0.8
Wang et al. (2022) [20]	300 (150 CTA cases)	70 (23.3)		163 (54.3)		49 (16.3)	18 (6.0)	-
Tansatit et al. (2021) [21]	62 (31 cadavers)	-	3 (4.8)	-	5 (8.1)	-	-	-
Hong et al. (2020) [22]	284 (198 CTA cases)	18 (6.3)	24 (8.5)	-	138 (48.6)	90 (31.7) ^{b)}	-	-
Niemann et al. (2019) [12]	39 (20 cadavers)	1 (2.6)	1 (2.6)	-	25 (64.1)	7 (18.0)	-	1 (2.6)
Koziej et al. (2019) [7]	255 (131 CTA cases)	63 (24.7)	63 (24.7)	80 (31.4)	102 (40.0)		4 (1.6)	6 (2.3)
Vasudha et al. (2018) [23]	50 (25 cadavers)	-	15 (30.0)	-	6 (12.0)	28 (56.0)	-	1 (2.0)
Piisl et al. (2016) [14]	60 (30 CTA cadavers)	11 (18.3)		-	16 (26.7)	25 (41.7)	8 (13.3)	-
Lee et al. (2018) [8]	60 (36 cadavers)	4 (6.7)		9 (15.0)	-	47 (78.3)	-	-
Dickson et al. (2013) [2]	40 (21 cadavers)	-	17 (42.5)	3 (7.5)	-	20 (50.0)	-	-
Furukawa et al. (2013) [4]	187 (94 CTA cases)	-	64 (34.2)	74 (39.6)	45 (24.1)		4 (2.1)	-
Kulkarni et al. (2013) [19]	100 (50 cadavers)	-	20 (20.0)	-	44 (44.0)	36 (36.0)	-	-
Lohn et al. (2011) [9]	201 (112 cadavers)	6 (3.0)	20 (10.0)	35 (17.0)	96 (48.0)	40 (20.0)	-	4 (2.0)
Loukas et al. (2006) [10]	284 (142 cadavers)		24 (8.5)	-	110 (38.7)	135 (47.5)	11 (3.9)	4 (1.4)
Pinar et al. (2005) [15]	50 (25 cadavers)	1 (2.0)	2 (4.0)	6 (12.0)	30 (60.0)	11 (22.0)	-	-
Koh et al. (2003) [24]	91 (47 cadavers)	5 (5.5)	6 (6.6)	3 (3.3)	40 (44.0)	26 (28.5)	11 (12.1)	-
Gardetto et al. (2002) [5]	44 (22 cadavers)	-	2 (4.5)	6 (13.5)	-	34 (77.4)	2 (4.5)	-
Dupoirieux et al. (1999) [3]	20 (10 cadavers)	-	7 (35.0)	-	9 (45.0)	4 (20.0)	-	-
Niranjan (1988) [13]	50 (25 cadavers)	-	2 (4.0)	1 (2.0)	-	42 (84.0)	5 (10.0)	-
Mitz et al. (1973) [11]	100 (50 cadavers)	8 (8.0)	10 (10.0)	-	-	78 (78.0)	4 (4.0)	-

Values are presented as number (%) or %.

ILA, inferior labial artery; SLA, superior labial artery; IAA, inferior alar artery; LNA, lateral nasal artery; AA, angular artery; F, forehead branch; D, duplex type; H, hypoplastic type.

^{a)}AA (31, 30.4%)/F (2, 2.0%); ^{b)}AA (56, 19.7%)/F (34, 12.0%).

have noted that the submental artery can adopt the first pattern, giving rise to the vertical labiomental arteries, or it can divide into multiple vertical branches of the hLMA and anastomose with the ILA. The use of different terminologies and classifications by researchers may contribute to these discrepancies. Furthermore, there is no consensus on which branch of the facial artery should be considered as the ultimate termination point. While the AA is commonly regarded as the final branch, it can also arise from the ophthalmic or infraorbital arteries.

Regarding the termination vessels, studies have reported varying prevalence rates for different types, such as from 0% to 80% for an IAA, 0% to 15% for a LNA or AA, 0% to 95.16% for a duplex artery, and 0% to 8.33% for a hypoplastic facial [6-8]. In our study, out of 102 assessed facial arteries, the termination was AA/F in 33 cases (32.35%), LNA in 33 cases (32.35%), IAA in seven cases, SLA in five cases, and ILA in five cases. Furthermore, we observed nine combination patterns with a duplex artery in 18 facial arteries (17.65%). These findings provide the most recent information about facial artery termination. In our study, the traditional definition of the AA as the facial artery's terminal tributary only had a success rate of 32.35%. Therefore, our results suggest that the LNA and AA are the primary terminations of the facial artery, which is consistent with findings from other studies (Table 2). The termination point of the facial artery exhibited remarkable consistency in its characteristics, suggesting its potential utility in categorizing the branching pattern of the facial arteries. In our investigation, we have identified seven distinct types as follows: (1) angular type: facial artery terminates at the AA or forehead branch; (2) nasal type: facial artery terminates at the LNA; (3) alar type: facial artery terminates at the IAA; (4) superior labial type: facial artery terminates at the SLA; (5) inferior labial type: facial artery terminates at the ILA; (6) duplex type: facial artery terminates as a duplex artery with the infraorbital trunk; and (7) hypoplastic type: hypoplastic facial artery.

In conclusion, eight termination points of the facial artery were observed, with 35 different branching patterns that showed asymmetries between the left and right sides. The usual description of the AA as the facial artery's terminal tributary was accurate in only 32.35% of cases. The duplex type was found in 18 facial arteries (17.65%). Differences according to the branching pattern and termination points of the facial artery should be considered to reduce complications during while performing head and neck surgery, facial plastic surgery, and facial aesthetic procedures.

NOTES

Conflict of interest

No potential conflict of interest relevant to this article was re-

ported.

Funding

This study was supported by the University of Medicine and Pharmacy, Ho Chi Minh City, Vietnam.

Ethical approval

This study was approved by the University of Medicine and Pharmacy at Ho Chi Minh City 2 (No. IRB-VN01002/IRB00010293/FWA00023448).

ORCID

Vu Hoang Nguyen <https://orcid.org/0009-0003-5957-5677>
Lin Cheng-Kuan <https://orcid.org/0000-0002-3124-9402>
Tuan Anh Nguyen <https://orcid.org/0009-0006-5709-808X>
Trang Huu Ngoc Thao Cai <https://orcid.org/0009-0008-7661-0629>

Author contributions

Conceptualization; Data curation; Formal analysis; Methodology; Project administration: Vu Hoang Nguyen, Trang Huu Ngoc Thao Cai, Tuan Anh Nguyen, Lin Cheng-Kuan. Visualization: Vu Hoang Nguyen, Trang Huu Ngoc Thao Cai. Writing - original draft: Trang Huu Ngoc Thao Cai. Writing - review & editing: Trang Huu Ngoc Thao Cai, Vu Hoang Nguyen, Tuan Anh Nguyen, Lin Cheng-Kuan. Investigation: Vu Hoang Nguyen, Trang Huu Ngoc Thao Cai, Tuan Anh Nguyen, Lin Cheng-Kuan. Resources: Vu Hoang Nguyen, Trang Huu Ngoc Thao Cai. Software: Trang Huu Ngoc Thao Cai, Lin Cheng-Kuan. Supervision; Validation: Vu Hoang Nguyen, Trang Huu Ngoc Thao Cai, Tuan Anh Nguyen, Lin Cheng-Kuan.

REFERENCES

1. Al-Hoqail RA, Abdel Meguid EM. An anatomical and analytical study of the modiolus: enlightening its relevance to plastic surgery. *Aesthetic Plast Surg* 2009;33:147-52.
2. Dickson G, Clark SK, George D, Mackenzie F, Mann NA, Wright K, et al. The variability of the facial artery in its branching pattern and termination point and its relevance in craniofacial surgery. *Eur J Plast Surg* 2014;37:1-8.
3. Dupoirieux L, Plane L, Gard C, Penneau M. Anatomical basis and results of the facial artery musculomucosal flap for oral reconstruction. *Br J Oral Maxillofac Surg* 1999;37:25-8.
4. Furukawa M, Mathes DW, Anzai Y. Evaluation of the facial artery on computed tomographic angiography using 64-slice multidetector computed tomography: implications for facial reconstruction in plastic surgery. *Plast Reconstr Surg* 2013;131:

- 526-35.
5. Gardetto A, Dabernig J, Rainer C, Piegger J, Piza-Katzer H, Fritsch H. Does a superficial musculoaponeurotic system exist in the face and neck? An anatomical study by the tissue plastination technique. *Plast Reconstr Surg* 2003;111:664-75.
 6. Koziej M, Bonczar M, Ostrowski P, Piatek-Koziej K, Bonczar T, Pasternak A, et al. Termination points of the facial artery: a meta-analysis. *Clin Anat* 2022;35:469-76.
 7. Koziej M, Trybus M, Holda M, Polak J, Wnuk J, Brzegowy P, et al. Anatomical map of the facial artery for facial reconstruction and aesthetic procedures. *Aesthet Surg J* 2019;39:1151-62.
 8. Lee HJ, Won SY, O J, Hu KS, Mun SY, Yang HM, et al. The facial artery: a comprehensive anatomical review. *Clin Anat* 2018;31:99-108.
 9. Lohn JW, Penn JW, Norton J, Butler PE. The course and variation of the facial artery and vein: implications for facial transplantation and facial surgery. *Ann Plast Surg* 2011;67:184-8.
 10. Loukas M, Hullett J, Louis RG Jr, Kapos T, Knight J, Nagy R, et al. A detailed observation of variations of the facial artery, with emphasis on the superior labial artery. *Surg Radiol Anat* 2006;28:316-24.
 11. Mitz V, Ricbourg B, Lassau JP. Facial branches of the facial artery in adults: typology, variations and respective cutaneous areas. *Ann Chir Plast* 1973;18:339-50.
 12. Niemann K, Lazarus L, Rennie C. An anatomical study of the facial artery. *Int J Morphol* 2019;37:1310-5.
 13. Niranjana NS. An anatomical study of the facial artery. *Ann Plast Surg* 1988;21:14-22.
 14. Pilsl U, Anderhuber F, Neugebauer S. The facial artery: the main blood vessel for the anterior face? *Dermatol Surg* 2016;42:203-8.
 15. Pinar YA, Bilge O, Govsa F. Anatomic study of the blood supply of perioral region. *Clin Anat* 2005;18:330-9.
 16. Yang HM, Lee JG, Hu KS, Gil YC, Choi YJ, Lee HK, et al. New anatomical insights on the course and branching patterns of the facial artery: clinical implications of injectable treatments to the nasolabial fold and nasojugal groove. *Plast Reconstr Surg* 2014;133:1077-82.
 17. Kawai K, Imanishi N, Nakajima H, Aiso S, Kakibuchi M, Hosokawa K. Arterial anatomy of the lower lip. *Scand J Plast Reconstr Surg Hand Surg* 2004;38:135-9.
 18. Koshi R. Cunningham's manual of practical anatomy. Vol 3: head and neck. Oxford University Press; 2018.
 19. Kulkarni AS, Geetha KN. Variations in branching pattern of facial artery: an anatomical study in 50 Indian adult cadavers. *J Anat* 2013;113:130-4.
 20. Wang D, Xiong S, Zeng N, Wu Y. Facial arterial variations in asians: a study on computed tomographic angiography. *Aesthet Surg J* 2022;42:527-34.
 21. Tansatit T, Jitaree B, Uruwan S, Rungsawang C. Anatomical study of the dorsal nasal artery to prevent visual complications during dorsal nasal augmentation. *Plast Reconstr Surg Glob Open* 2021;9:e3924.
 22. Hong SJ, Park SE, Jo JW, Jeong DS, Choi DS, Won JH, et al. Variant facial artery anatomy revisited: conventional angiography performed in 284 cases. *Medicine (Baltimore)* 2020;99:e21048.
 23. Vasudha TK, Divya Shanthi D, Sadashivana G. A study on course and variations of facial artery on the face. *Int J Anat Res* 2018;6:4928-32.
 24. Koh KS, Kim HJ, Oh CS, Chung IH. Branching patterns and symmetry of the course of the facial artery in Koreans. *Int J Oral Maxillofac Surg* 2003;32:414-8.