

Utility of intraoral scanner imaging for dental plaque detection

Chihiro Yoshiga¹, Kazuya Doi^{1,*}, Hiroshi Oue¹, Reiko Kobatake¹, Maiko Kawagoe², Hanako Umehara¹, Kazuhiro Tsuga¹

¹Department of Advanced Prosthodontics, Graduate School of Biomedical and Health Sciences, Hiroshima University, Hiroshima, Japan

²Department of Clinical Practice and Support, Dental Section, Hiroshima University Hospital, Hiroshima, Japan

ABSTRACT

Purpose: Oral hygiene, maintained through plaque control, helps prevent periodontal disease and dental caries. This study was conducted to examine the accuracy of plaque detection with an intraoral scanner (IOS) compared to images captured with an optical camera.

Materials and Methods: To examine the effect of color tone, artificial tooth resin samples were stained red, blue, and green, after which images were acquired with a digital single-lens reflex (DSLR) camera and an IOS device. Stained surface ratios were then determined and compared. Additionally, the deviation rate of the IOS relative to the DSLR camera was computed for each color. In the clinical study, following plaque staining with red disclosing solution, the staining was captured by the DSLR and IOS devices, and the stained area on each image was measured.

Results: The stained surface ratios did not differ significantly between DSLR and IOS images for any color group. Additionally, the deviation rate did not vary significantly across colors. In the clinical test, the stained plaque appeared slightly lighter in color, and the delineation of the stained areas less distinct, on the IOS compared to the DSLR images. However, the stained surface ratio was significantly higher in the IOS than in the DSLR group.

Conclusion: When employing IOS with dental plaque staining, the impact of color was minimal, suggesting that the traditional red stain remains suitable for plaque detection. IOS images appeared relatively blurred and enlarged relative to the true state of the teeth, due to inferior sharpness compared to camera images. (*Imaging Sci Dent* 2024; 54: 43-8)

KEY WORDS: Dental Plaque; Diagnosis, Oral; Oral Hygiene

Introduction

Oral hygiene, maintained through plaque control, is crucial for preventing periodontal disease and dental caries.¹⁻³ Consequently, it is essential to effectively control plaque, both by instructing patients regarding oral hygiene and by providing precise assessment of plaque adhesion areas.^{3,4} Traditionally, the O'Leary plaque control record (PCR) has been used to evaluate oral hygiene in clinical settings.⁵ While straightforward and useful, this method cannot visually capture the oral status during evaluation, with

associated drawbacks including issues with reproducibility and challenges in collaborative assessment.

In contrast, the oral hygiene status can be documented and archived through the capture of intraoral photographs using a camera. However, while images obtained with an optical camera can offer an indirect evaluation of oral hygiene, this method is time-intensive and burdensome for patients. Conversely, in recent years, digital dentistry has made remarkable progress. Intraoral scanners (IOSs) are capable of capturing digital color images of the dentition and are utilized in the creation of crown prostheses via computer-aided design/computer-aided manufacturing.⁶⁻⁸ The digital color images obtained with an IOS can be manipulated on a monitor, with features including rotation and magnification; this enables observation of the dentition from angles that are otherwise not accessible.^{9,10} Efforts have been made to apply IOS technology in the evaluation of oral hygiene.¹¹⁻¹³ In par-

Received August 18, 2023; Revised October 1, 2023; Accepted October 11, 2023
Published online January 4, 2024

*Correspondence to : Dr. Kazuya Doi

Department of Advanced Prosthodontics, Hiroshima University Graduate School of Biomedical and Health Sciences, 1-2-3, Kasumi, Minami-ku, Hiroshima 734-8553, Japan
Tel) 81-82-257-5677, E-mail) kazuya17@hiroshima-u.ac.jp

Copyright © 2024 by Korean Academy of Oral and Maxillofacial Radiology

This is an Open Access article distributed under the terms of the Creative Commons Attribution Non-Commercial License (<http://creativecommons.org/licenses/by-nc/3.0>) which permits unrestricted non-commercial use, distribution, and reproduction in any medium, provided the original work is properly cited.

Imaging Science in Dentistry · pISSN 2233-7822 eISSN 2233-7830

ticular, an IOS can be used to rapidly record the oral status, potentially addressing the challenges associated with the technical demands of intraoral photography.

In a prior study, these authors reported that an IOS system was capable of detecting sites of plaque adhesion.¹⁰ Furthermore, Giese-Kraft et al.¹⁴ used an intraoral camera and an IOS to document the oral status following plaque staining, revealing that the areas with stained plaque could be visualized similarly with both technologies.

Three-dimensional (3D) intraoral imaging serves as an appropriate instrument for whole-mouth planimetry, enabling the identification and monitoring of dental plaque. However, the disclosure of plaque on intraoral scans is subject to error, among other problems. With an IOS, the oral condition is captured as a digital image, which facilitates the manipulation of the image through rotation, enlargement, and digital processing for the accurate detection of dental plaque. By displaying the areas with adherent plaque as a digital image on a monitor, one can evaluate the oral hygiene status while also encouraging patient motivation.

As such, IOS may emerge as a novel method for assessing oral hygiene by detecting areas of plaque. The presence of dental plaque is typically revealed through the application of a staining agent. Traditionally, most plaque-disclosing solutions have included a red dye. However, few studies have been conducted on the accuracy with which plaque deposits are captured on IOS images, including the influence of color tone.

In this study, the impact of dye color on IOS imaging was explored. Additionally, the accuracy of detection in clinical practice was compared between IOS images and photographs captured with an optical camera.

Materials and Methods

Study design and participants

This study was an interventional, single-arm, open (that is, without masking), uncontrolled, single-assignment investigation. Approval was granted by the Hiroshima University Hospital Certified Review Board (CRB6180006). The study was conducted as a specific clinical research project (jRCTs 062220068) in accordance with the Good Clinical Practice guidelines of the International Conference on Harmonization. The clinical portion took place at the Department of Dentistry, Hiroshima University Hospital, Japan, from January 2023 to July 2023.

The study included 20 patients who received oral hygiene prophylaxis (7 men and 13 women, ranging in age from 25

to 85 years). Each participant received information about the study and provided signed informed consent to undergo oral hygiene procedures utilizing the IOS.

Regarding the inclusion criteria, participants were limited to those who: 1) were at least 18 years old, 2) provided written informed consent, 3) had periodontal disease and/or peri-implantitis, 4) had been receiving regular oral hygiene treatment from a dentist or hygienist for a period exceeding 6 months, 5) displayed a PCR exceeding 20%, and 6) possessed the cognitive ability to understand and accurately respond to a questionnaire.

The exclusion criteria were as follows: 1) patients with a pacemaker or an implantable cardioverter defibrillator, 2) edentulous individuals, 3) patients with 4 missing molars and premolars, 4) those with disorders affecting mouth opening or the temporomandibular joint, and 5) those deemed unsuitable for the study by the principal investigator or co-investigators.

Examination of color variations

As a preliminary experiment prior to the clinical study, these authors examined the impacts of color on images captured with an IOS device. A model of the mandible (D18D-500A; Nissin Dental Products Inc., Kyoto, Japan), equipped with synthetic hard resin teeth (A20A; Nissin Dental Products Inc.), was utilized. The artificial first molars were marked with water-based ink in red, blue, and green (McKee WYTS5-R, BL, and G; Zebra Co. Ltd., Tokyo, Japan). Following application of the ink, the buccal surfaces of

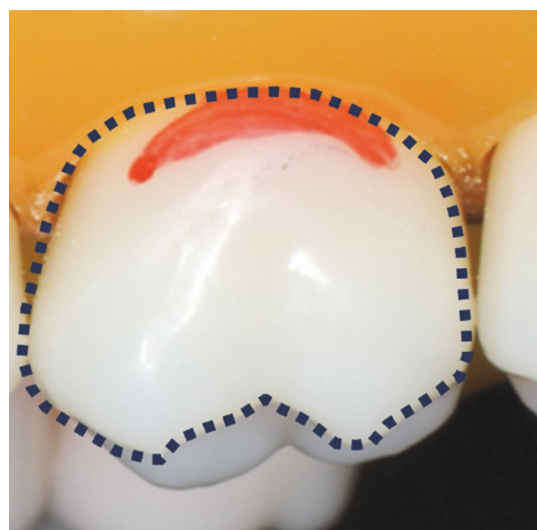


Fig. 1. Method used to measure the stained surface ratio. To calculate this ratio, the stained area (indicated in red) was divided by the crown area (outlined with a black dotted line).

the artificial teeth were imaged using a digital single-lens reflex (DSLR) camera (EOS 60D; Canon, Tokyo, Japan) (flash: Macro Ring Lite MR-14EXII, Canon; lens: EF 50 mm F2.5 compact macro lens, Canon), as well as with an IOS (TRIOS 3 Basic; 3 Shape, Copenhagen, Denmark).

The images of stained teeth were digitized, and the area of tooth surface staining was quantified using ImageJ (National Institutes of Health, Bethesda, MD, USA) ($N = 5$). The stained surface ratio was determined for each image by dividing the stained area by the area of the crown (Fig. 1). The deviation rates for the DSLR camera and IOS images were assessed as absolute values for each color as follows: $[(\text{stained surface ratio for the IOS}/\text{stained surface ratio for the DSLR camera}) - 1] \times 100 (\%)$. Differences between camera and IOS images were examined for the red, blue, and green groups. The deviation rates within each group were analyzed using 1-way analysis of variance, with the significance level set at 5% (Prism v7; GraphPad Software, La Jolla, CA, USA).

Clinical study

Plaque adhesion was assessed using dental plaque staining. A cotton ball soaked in a red plaque-disclosing gel (Prospec; GC Corporation, Tokyo, Japan) was used to apply the solution to the tooth surface. Subsequently, the patient's mouth was rinsed with water, and the buccal side of the stained molar was imaged using IOS. After rinsing, photographs of the same areas were captured with a camera ($N =$

20). The ratios of the stained tooth surface in both the IOS and camera images were quantified using the methodology established in the preliminary experiment. Differences between groups were assessed with the Wilcoxon matched-pairs signed-rank test, with P -values of less than 0.05 considered to indicate statistical significance.

Results

Areas stained red, blue, and green were identified on the photographs acquired with the camera, as well as the IOS images (Fig. 2).

The stained surface ratios of the IOS images tended to exceed those of the DSLR camera images for the red and blue stains. Nevertheless, no significant differences were observed for any color group ($P > 0.05$ for red, blue, and green). When comparing the rates of deviation, no significant differences were found across these colors ($P > 0.05$) (Table 1).

Dental plaque staining was also examined on the IOS and camera images (Figs. 3A and B). On the IOS images, the color of the stained areas appeared slightly lighter than on the images acquired with the camera. Additionally, the edges of the stained areas in the DSLR camera images appeared sharp. In contrast, the IOS images displayed comparatively blurred outlines (Figs. 3C and D).

The stained surface ratio was significantly higher for the IOS than for the camera images ($P < 0.05$) (Fig. 4).

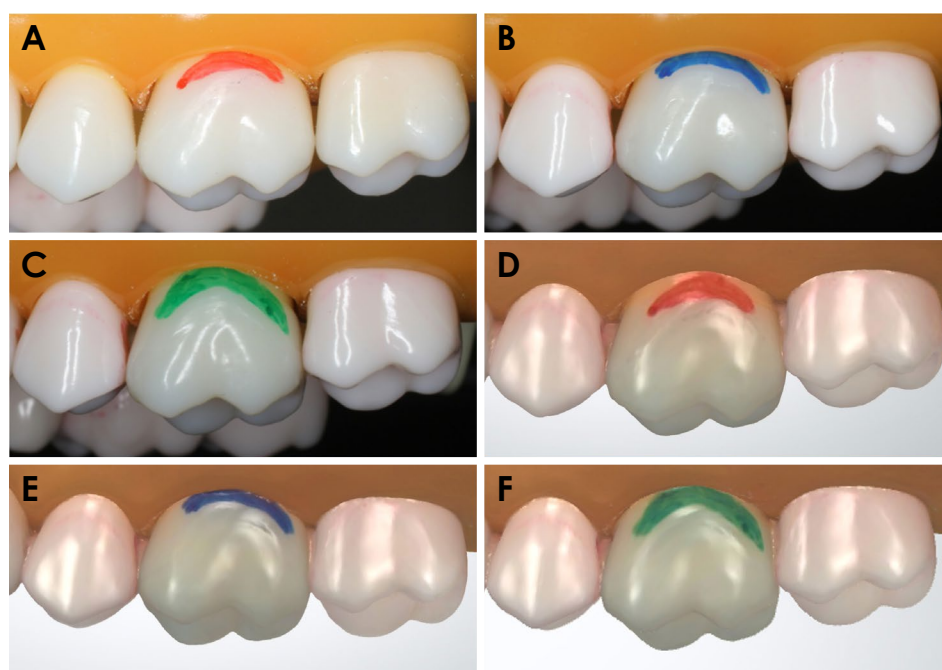


Fig. 2. Images captured using a digital single-lens reflex (DSLR) camera and an intraoral scanner (IOS), depicting red, blue, and green markings. A. DSLR camera image of a red marking. B. DSLR camera image of a blue marking. C. DSLR camera image of a green marking. D. IOS image of a red marking. E. IOS image of a blue marking. F. IOS image of a green marking.

Table 1. Surface staining and deviation rates for red, blue, and green markings, captured by a digital single-lens reflex (DSLR) camera and an intraoral scanner (unit: %)

Sample	DSLR camera	Intraoral scanner	Deviation rate
Red-1	21.63	22.72	5.04
Red-2	12.46	12.75	2.34
Red-3	15.39	16.15	4.97
Red-4	8.85	10.11	14.19
Red-5	11.89	12.55	5.54
Blue-1	8.56	8.73	1.96
Blue-2	10.92	11.66	6.78
Blue-3	12.65	13.25	4.74
Blue-4	21.99	22.56	2.60
Blue-5	17.04	17.27	1.38
Green-1	10.31	11.15	8.13
Green-2	6.45	6.63	2.83
Green-3	11.28	11.05	2.09
Green-4	15.12	15.05	0.49
Green-5	22.86	22.38	2.09

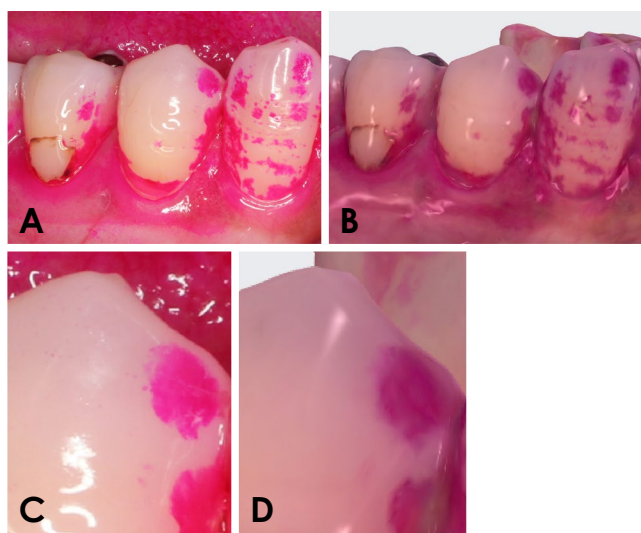


Fig. 3. Images captured following dental plaque disclosure, using a digital single-lens reflex (DSLR) camera and an intraoral scanner (IOS). A. DSLR camera image. B. IOS image. C. Magnified view of the DSLR camera image. D. Magnified view of the IOS image.

Discussion

This study involved examining the color tones of plaque-disclosing agents, as visualized by IOS. To the knowledge of these authors, this is the first study to examine the color representation and dental plaque staining visualization of IOS imaging. Identifying sites of plaque adhesion and providing oral hygiene guidance, whether in the oral cavity

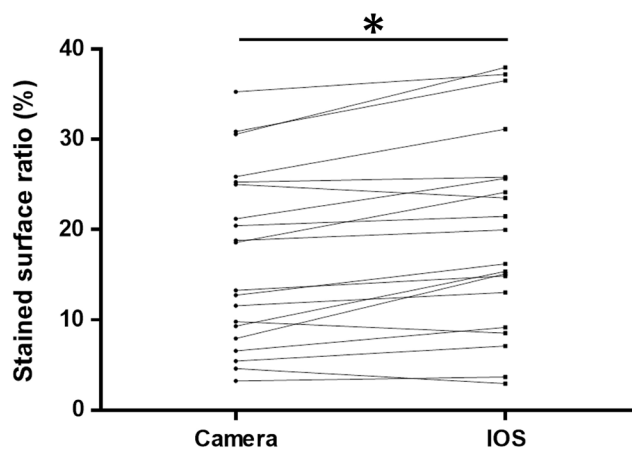


Fig. 4. The stained surface ratio was significantly higher on intraoral scanner (IOS) images than on photographs captured with a digital single-lens reflex camera ($P < 0.05$).

or on a jaw model, is crucial for maintaining optimal oral health. The evaluation of oral hygiene necessitates: 1) superior objective assessment, 2) quantification, 3) simple and accurate measurement and documentation, 4) high reproducibility, and 5) assessments that are easily understood by both practitioners and patients. While documenting oral hygiene status with an optical camera can offer an indirect assessment of oral hygiene, the process is time-consuming, requires assistance, and is burdensome for the patient. Consequently, this procedure places repeated demands on both the practitioner and the patient if executed at every clinical visit.

IOS devices can capture 3D images of intraoral conditions. This technique can be performed by a single surgeon, representing a rapid process that minimizes patient burden. Recent studies have explored the use of IOS for oral hygiene assessment.^{10,14,15} For instance, Jung et al.¹⁵ conducted a planimetric analysis of disclosed plaque areas using both an IOS device and a camera. Due to the convex nature of tooth surfaces, a single image from an intraoral camera may not fully represent the central portion of the tooth. In contrast, IOS imaging can capture the entire tooth surface in 1 image; in the present study, this likely contributed to the slightly higher observed plaque coverage in IOS scans compared to camera images. In a previous investigation, the present authors examined the utility of IOS in PCR measurements. After applying a plaque-staining agent and visualizing the dentition with IOS, the images clearly showed the stained dental plaque.¹⁰ These scans were particularly useful for visualizing plaque in hard-to-see areas, such as the lingual and distal aspects of the tooth surface. This research suggests that images recorded using IOS equipment can

reflect plaque disclosure. Dental plaque staining solutions are typically red in color.¹⁶ However, the use of this color for plaque detection with IOS has not been validated. In this preliminary study, red, blue, and green colors were used for staining. Again, red is commonly used in clinical settings, while blue and green were chosen for comparison. In the chromaticity diagram, which depicts the color spectrum from the lightest whites to the most vivid colors, the color triangle is defined by the presence of the 3 primary colors at its vertices.¹⁷ This triangle represents the broad range of colors that can be produced by mixing the primary colors. Red, which is composed of green and blue within this color triangle, is also employed in additive color mixing to create a variety of colors, including the RGB (red, green, and blue) colors used in the image sensors of digital cameras. In the present study, no significant difference was found in the deviation rate across these colors. These findings suggest that the use of a red dental plaque staining solution is acceptable for identifying stained plaque areas using IOS.

Preliminary studies revealed no significant differences in measurements between the DSLR and IOS images, although the IOS measurements were non-significantly higher for the red and blue stains. In the clinical results, the stained regions depicted on IOS images exhibited larger relative areas than those captured by the camera. The IOS system benefits from digital processing capabilities, including magnification and rotation, which likely contribute to its tendency to yield higher values for the ratio of stained surfaces compared to conventional measurement methods.

Meseli et al.¹⁸ examined the relationship between scores determined using the FluoreCam method and the dental plaque index obtained following the application of a plaque staining agent. The findings indicated that plaque scores obtained through the FluoreCam approach exceeded those recorded after plaque staining in a clinical setting. In the present study, visual and IOS image recordings of the PCR measurements were compared, with higher readings observed for the IOS images. This discrepancy may stem from the ability to view IOS images on a monitor, which enables enhanced magnification and rotation to ultimately facilitate a more detailed plaque inspection. Consequently, higher PCR scores are obtained. The clinical data regarding the plaque deposition area ratio indicated that the IOS images produced higher values. Under the present measurement conditions, both camera and IOS images were captured at the same level of magnification. Consequently, the potential effects of rotation and magnification, which are advantages of IOS, were not considered.

The IOS device used in this study was equipped with a

complementary metal oxide semiconductor reading sensor, which enabled full-color scanning. Consequently, differences in color tone appeared to exert minimal impact on the findings.

One contributing factor is that camera images are captured at a resolution of 1980 × 1080 pixels, whereas IOS devices operate at a lower reading resolution of 1280 × 870 pixels due to equipment performance limitations. Consequently, when IOS images are enlarged, the contours appear blurred relative to camera images, and the measured area seems larger. The deviation value is appropriate for evaluations such as confirming plaque attachment areas and conducting PCR measurements. The benefits of image processing, including rotation and magnification, underscore the potential utility of IOS in assessing oral hygiene status. Nonetheless, for the development and implementation of new indices, such as the area ratio of stained plaque and the volume ratio of plaque accumulation, IOS images would require a resolution on par with that of a DSLR camera.

The use of IOS images in the assessment of oral hygiene is potentially useful. However, these images tended to appear blurred and enlarged relative to the true condition of the teeth, due to their reduced sharpness relative to camera images.²⁻⁵

Conflicts of Interest: None

References

1. Costalonga M, Herzberg MC. The oral microbiome and the immunobiology of periodontal disease and caries. *Immunol Lett* 2014; 162: 22-38.
2. Larsen T, Fiehn NE. Dental biofilm infections - an update. *APMIS* 2017; 125: 376-84.
3. Tonetti MS, Eickholz P, Loos BG, Papananou P, van der Velden U, Armitage G, et al. Principles in prevention of periodontal diseases: consensus report of group 1 of the 11th European Work-shop on Periodontology on effective prevention of periodontal and peri-implant diseases. *J Clin Periodontol* 2015; 42 Suppl 16: S5-11.
4. Needleman I, Nibali L, Di Iorio A. Professional mechanical plaque removal for prevention of periodontal diseases in adults - systematic review update. *J Clin Periodontol* 2015; 42: S12-35.
5. O'Leary TJ, Drake RB, Naylor JE. The plaque control record. *J Periodontol* 1972; 43: 38.
6. Fine DH. Chemical agents to prevent and regulate plaque development. *Periodontol* 2000 1995; 8: 87-107.
7. Mangano F, Gandolfi A, Luongo G, Logozzo S. Intraoral scanners in dentistry: a review of the current literature. *BMC Oral Health* 2017; 17: 149.
8. Siqueira R, Galli M, Chen Z, Mendonça G, Meirelles L, Wang HL, et al. Intraoral scanning reduces procedure time and improves patient comfort in fixed prosthodontics and implant denti-

- stry: a systematic review. *Clin Oral Investig* 2021; 25: 6517-31.
9. Patzelt SB, Emmanouilidi A, Stampf S, Strub JR, Att W. Accuracy of full-arch scans using intraoral scanners. *Clin Oral Investig* 2014; 18: 1687-94.
 10. Doi K, Yoshiga C, Kobatake R, Kawagoe M, Wakamatsu K, Tsuga K. Use of an intraoral scanner to evaluate oral health. *J Oral Sci* 2021; 63: 292-4.
 11. Christofoli BR, Silva NC, Oliveira JA, Fernandes MI, Haas AN. Predictors of dental plaque and gingivitis in patients receiving integrated dental treatment - a longitudinal retrospective study. *Clin Oral Investig* 2019; 23: 651-9.
 12. Daly S, Seong J, Parkinson C, Newcombe R, Claydon N, West N. A randomised controlled trial evaluating the impact of oral health advice on gingival health using intra oral images combined with a gingivitis specific toothpaste *J Dent* 2023; 131: 104472.
 13. Steinmeier S, Wiedemeier D, Hämmerle CHF, Mühlemann S. Accuracy of remote diagnoses using intraoral scans captured in approximate true color: a pilot and validation study in teledentistry. *BMC Oral Health* 2020; 20: 266.
 14. Giese-Kraft K, Jung K, Schlueter N, Vach K, Ganss C. Detecting and monitoring dental plaque levels with digital 2D and 3D imaging techniques. *PLoS One* 2022; 17: e0263722.
 15. Jung K, Giese-Kraft K, Fischer M, Schulze K, Schlueter N, Ganss C. Visualization of dental plaque with a 3D-intraoral-scanner - a tool for whole mouth planimetry. *PLoS One* 2022; 17: e0276686.
 16. Datta D, Kumar SG, Narayanan MB, Selvamary AL, Sujatha A. Disclosing solutions used in dentistry. *World J Pharm Res* 2017; 6: 1648-56.
 17. Hunt RW. *The reproduction of colour*. 6th ed. Chichester: John Wiley & Sons; 2004.
 18. Meseli S, Ekenel S, Korkut B, Aksu B, Tagtekin D, Yanikoglu F. Clinical assessment of various imaging systems for dental plaque scoring after the use of 3 different toothpastes. *Imaging Sci Dent* 2023; 53: 209-16.