

# Assessment of radiographic left atrial dimension and C-reactive protein in dogs with myxomatous mitral valve disease

Jihee Hong<sup>1,2</sup>, Han-Joon Lee<sup>2</sup>, Dong-Kwan Lee<sup>2</sup>, Kun-Ho Song<sup>2\*</sup>

<sup>1</sup>TOPCARE Animal Medical Center, Goyang 10500, Korea

<sup>2</sup>Department of Veterinary Internal Medicine, College of Veterinary Medicine, Chungnam National University, Daejeon 34134, Korea

Received January 4, 2024

Revised March 14, 2024

Accepted March 17, 2024

Corresponding author:

Kun-Ho Song

E-mail: [songkh@cnu.ac.kr](mailto:songkh@cnu.ac.kr)

<https://orcid.org/0000-0001-8478-2035>

Radiographic left atrial dimension (RLAD) is a valuable metric for assessing left atrial enlargement in dogs. While there have been studies on the use of RLAD and the increase in C-reactive protein (CRP) levels based on heart disease stages, there has been no prior research on the correlation between RLAD and CRP. In this study, the objective was to investigate the relationship between the rise in RLAD as myxomatous mitral valve disease (MMVD) stages advance and the increase in CRP levels with MMVD stage progression. In this study, a total of 30 small-breed dogs were included as subjects. These dogs were diagnosed with MMVD at the American College of Veterinary Internal Medicine (ACVIM) stage B1 or B2, or stage C, based on a comprehensive assessment including physical examination, thoracic radiography, and echocardiography. Measurements of VHS and RLAD were compared to assess any significant differences. There were significant differences in RLAD between dogs with MMVD ACVIM stage B1 and those with stage C. The monocytes and CRP levels showed significant differences between ACVIM stage B1, B2 and ACVIM C. Additionally, a significant correlation was observed between the RLAD and VHS measurements. This underscores the notable association between MMVD stage advancement and elevated monocyte and CRP levels. The RLAD scores exhibited a significant difference among dogs with ACVIM stages B1, B2, and C, and significant variations were also observed in monocyte and CRP levels. These results suggest that monocyte and CRP levels may be a valuable diagnostic indicator for heart disease in dogs during the diagnostic evaluation.

**Key Words:** Radiographic left atrial dimension, Radiography, Monocyte, CRP, Dogs

## INTRODUCTION

Myxomatous mitral valve disease (MMVD) stands as one of the most prevalent chronic acquired heart conditions found in small dogs (Fox, 2012). It is characterized by a gradual myxomatous degeneration of the mitral valve apparatus, leading to the subsequent dilation of the left atrium (LA) and left ventricle (LV) (Buchanan et al, 1995). The consequent rise in LA pressure results in elevated pulmonary capillary pressure, initiating pulmonary edema and congestion (Ettinger et al, 2017). The diagnosis and treatment of MMVD follow the consensus guidelines established by the American College of Vet-

erinary Internal Medicine (ACVIM) (Keene et al, 2019).

Enlargement of the LA is among the earliest and most crucial indicators of disease severity, and the assessment of LA size should be performed prior to the onset of clinical signs of congestive heart failure (CHF) (Lam et al, 2021). Utilizing echocardiography to measure indices like the left atrial to aortic ratio (LA:Ao) and the left ventricular end-diastolic diameter normalized for body weight (LVIDDn) represents the gold standard approach, offering a direct and precise assessment of congestive heart failure (CHF) condition in dogs (Sánchez Salguero et al, 2018; Keene et al, 2019; Lam et al, 2021). However, measuring indices with echocardiography of-



ten requires a skilled examiner and may be difficult to perform due to the patient's condition, time, and cost constraints.

Thus, thoracic radiography, known for its sensitivity in detecting left atrial enlargement, can be considered as an alternative approach for assessing MMVD (Kittleston et al, 2003; Ettinger et al, 2017). It offers insights into overall cardiac size and the presence of pulmonary congestion or edema. (Ettinger et al, 2017). Various radiographic methods exist for evaluating left atrial size in dogs, including vertebral heart size (VHS), vertebral left atrial size (VLAS), and radiographic left atrial dimension (RLAD) (Lam et al, 2021).

RLAD builds upon the measurements of VHS by incorporating a third line that intersects the vertical and horizontal axes of VHS at a 45-degree angle towards the caudal aspect, extending to the dorsal edge of the left atrial bulge (Sánchez Salguero et al, 2018). When RLAD is employed with a cutoff value of 1.8 vertebrae, it demonstrates a sensitivity of 93.5% and specificity of 96.8% in subjects with an LA:Ao ratio of  $\geq 1.6$  (Sánchez Salguero et al, 2018). In a separate study, RLAD measurements of  $\geq 1.8$  vertebrae exhibited a sensitivity of 90.2% and specificity of 79.3% (Lam et al, 2021). Furthermore, RLAD demonstrated excellent repeatability and reproducibility with low intra-observer variability (Lam et al, 2021).

The serum C-reactive protein concentrations increased in dogs with congestive heart failure due to myxomatous mitral valve disease (Reimann et al, 2016). In veterinary medicine, C-reactive protein (CRP), an acute-phase protein synthesized by the liver, serves as an inflammation marker (Domanjko Petrič et al, 2018; Hwang et al, 2021). Elevated CRP concentrations result from the increased expression of myocardial cytokines in both the atria and ventricles of dogs experiencing heart failure caused by various cardiac diseases, including MMVD (Hwang et al, 2021). The association between CRP and VLAS had not been previously investigated. However, our findings revealed a robust positive correlation between VLAS and CRP, indicating a significant

rise in CRP levels as VLAS values increased (Hwang et al, 2021).

Previous studies have explored the correlation between VLAS and CRP in dogs with MMVD, but the relationship between RLAD and CRP has not yet been investigated (Domanjko Petrič et al, 2018; Hwang et al, 2021). We observed a strong positive correlation between RLAD and CRP, with CRP levels significantly increasing as RLAD values increased. Therefore, incorporating CRP testing alongside RLAD assessment when evaluating cardiac status can contribute to a more precise assessment of the prognosis and condition of MMVD patients.

## MATERIALS AND METHODS

### Animals

The medical records of small breed dogs treated at the TOPCARE Animal Medical Center in Goyang-si from 2020 to 2023 were reviewed, selecting dogs diagnosed with myxomatous mitral valve disease as candidates for this study. Patients were diagnosed with MMVD and classified into stages according to the ACVIM consensus guidelines through physical examination, cardiac auscultation, thoracic radiography, and echocardiography. The study focused on patients with MMVD ACVIM stages B1, B2, and C, totaling 30 dogs. Stage B1 was defined as asymptomatic patients with mitral regurgitation due to MMVD, not meeting the criteria for stage B2 due to a less severe presentation (Keene et al, 2019). The criteria for stage B2 included a cardiac murmur intensity of 3 out of 6 or greater, an LA:Ao ratio of 1.6 or higher in echocardiography's right-sided short-axis view during early diastole, and a VHS exceeding 10.5 (Keene et al, 2019). The patients who showed clinical signs associated with congestive heart failure were put into stage C group. Patients with congenital heart conditions or other medical issues such as other inflammatory disorders unrelated to MMVD were excluded from the study.

### Blood analysis

Blood samples obtained from the dogs and complete blood count was measured using the ProCyte Dx (IDEXX, Seoul, Korea). CRP was measured from obtained serums of the dogs using the IDEXX Catalyst One (IDEXX, Seoul, Korea).

### Thoracic radiography

Thoracic radiography was employed to measure VHS and RLAD. These measurements were obtained using a digital caliper in the right lateral inspiratory view, following established methods (Buchanan et al, 1995; Malcolm et al, 2018; Vezzosi et al, 2020). VHS and RLAD measurements were extracted from the same radiographic images (Sánchez Salguero et al, 2018).

The measurement of VHS began by drawing a line along the long axis of the heart, connecting the ventral border of the left mainstem bronchus to the farthest ventral contour of the cardiac apex (Buchanan et al, 1995). Additionally, the short axis of the heart, taken at the widest point of the cardiac silhouette and perpendicular to the long axis, was also measured (Buchanan et al, 1995). Both the long-axis and short-axis measurements were then converted to vertebrae units, beginning at the cranial edge of the fourth thoracic vertebra, and the total number of vertebrae intersecting these two measurements was counted and summed (Buchanan et al, 1995). To measure RLAD, a line that equally di-

vided the 90-degree angle formed by the VHS L and S axes was drawn and extended to the dorsal edge of the left atrium (Sánchez Salguero et al, 2018). The length of this line was subsequently standardized to vertebrae units, commencing from the edge of the fourth thoracic vertebra (Sánchez Salguero et al, 2018). Using a digital protractor computer program, the angle between this line and the VHS L and S axes was confirmed to be 45 degrees (Sánchez Salguero et al, 2018).

### Statistical analysis

Statistical analysis was performed using a commercial software program (IBM SPSS Statistics 24.0, SPSS Inc., Chicago, IL, USA). A Kolmogorov-Smirnov test was conducted to determine the normality of the data.

A one-way ANOVA and Kruskal-Wallis test was performed to analyze the difference in the results from the three groups, with correction for post hoc analysis. Pearson's correlation coefficient was used to examine the relationship between variables. A *P* value <0.05 was considered statistically significant.

## RESULTS

A total of 30 small-breed dogs were included in this study. The clinical data for age, sex, and body weight were summarized in Table 1. The dogs were divided into 3 groups according to the MMVD ACVIM guidelines as follows: 10 dogs in stage B1; 10 dogs in stage B2; and 10

**Table 1.** Parameters of radiography, CBC, and CRP in MMVD dogs

		B1 <sup>a</sup>	B2 <sup>b</sup>	C <sup>c</sup>	<i>P</i>	
CBC	WBC	10.42±3.88	10.31±3.45	14.42±6.53	0.114	
	Neutrophil	7.24±3.52	7.09±3.08	9.85±4.02	0.168	
	Lymphocyte	2.18±0.74	1.98±0.68	2.72±2.90	0.630	
	Monocyte	0.73±0.47	0.75±0.53	1.53±1.07*	0.035	α,β<γ
	Eosinophil	0.26±0.17	0.55±0.52	0.29±0.23	0.126	
	Basophil	0.01±0.01	0.04±0.05	0.02±0.02	0.155	
CRP	6.68±8.51	5.55±9.16	27.94±23.67**	0.004	α,β<γ	
VHS	10.28±1.20	10.79±0.95	11.82±1.06*	0.011	α<γ	
RLAD	1.52±0.31	1.86±0.26	2.27±0.47**	0.000	α<γ	

\**P*<0.05, \*\**P*<0.01.

dogs in stage C. There was no significance in age and sex across the stages. According to the Kolmogorov-Smirnov test, normality was observed for WBC, neutrophils, lymphocytes, monocytes, eosinophils, CRP, VHS, and RLAD. Therefore, parametric tests were applied. However, for basophils, a non-parametric test was employed due to non-normality.

In monocytes, CRP, VHS, and RLAD, statistically significant differences were observed. Monocytes exhib-

ited higher values in Group C compared to B1 and B2. Notably, monocyte and CRP levels showed a significant increase in stage C compared to stages B1 and B2 ( $P=0.004$ ). Additionally, the VHS was significantly higher in C compared to stage B1 ( $P=0.011$ ), and the RLAD was significantly higher in stage C compared to stage B1 ( $P=0.000$ ). These findings highlight the potential of CRP as a diagnostic marker for MMVD progression, along with radiographic changes in VHS and RLAD ( $P<0.05$  between B1 and C) (Fig. 1).

The examination of the relationship between CRP, VHS, and RLAD revealed a significant positive correlation between VHS and RLAD with a correlation coefficient of 0.708 ( $P<0.01$ ) (Table 2). This indicates that as VHS increases, RLAD also tends to increase. However, no statistically significant correlation was observed between CRP and either VHS or RLAD (Fig. 2~4).

## DISCUSSION

The objective of this study was to investigate the correlation between RLAD changes and CBC alterations in small-breed dogs and to explore the relationship between RLAD and CRP levels. In South Korea, heart disease is commonly diagnosed in small-breed dogs aged 11 years and older (Fox, 2012). Among various diagnostic methods for heart disease, many rely on radiographic measurements, such as VHS and RLAD (Buchanan et al, 1995; Keene et al, 2019) This prompted curiosity about the potential utility of CRP as a hematological diagnostic method (Reimann et al, 2016; Domanjko Petrič et al, 2018; Hwang et al, 2021). Building on previous research that explored the correlation between MMVD stages and CRP, this study was conducted to investigate

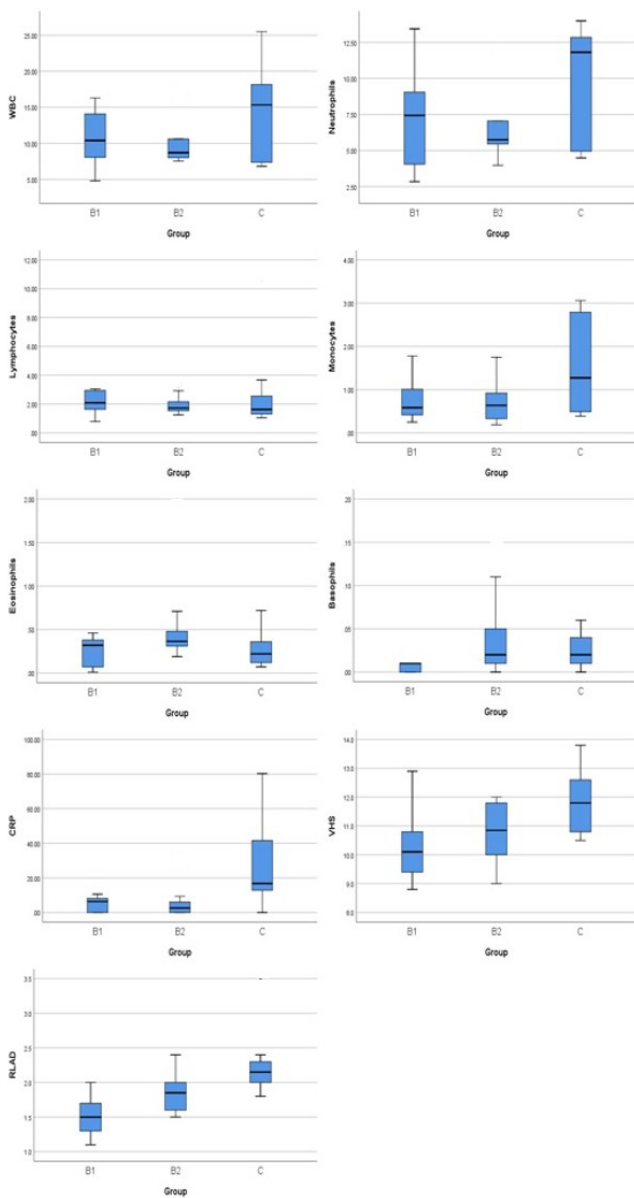


Fig. 1. Graphs of parameters of radiography, CBC, and CRP in MMVD dogs.

Table 2. Correlation coefficient values between indices

	CRP	VHS	RLAD
CRP	1		
VHS	0.347	1	
RLAD	0.242	0.708**	1

\*\* $P<0.01$ .

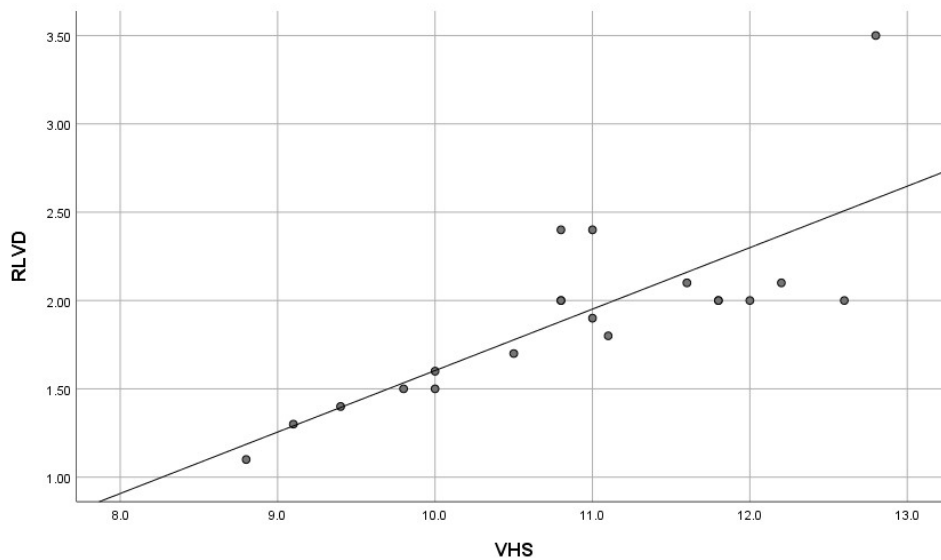


Fig. 2. Correlation between CRP and VHS in MMVD dogs (Correlation coefficient 0.347,  $P>0.05$ ).

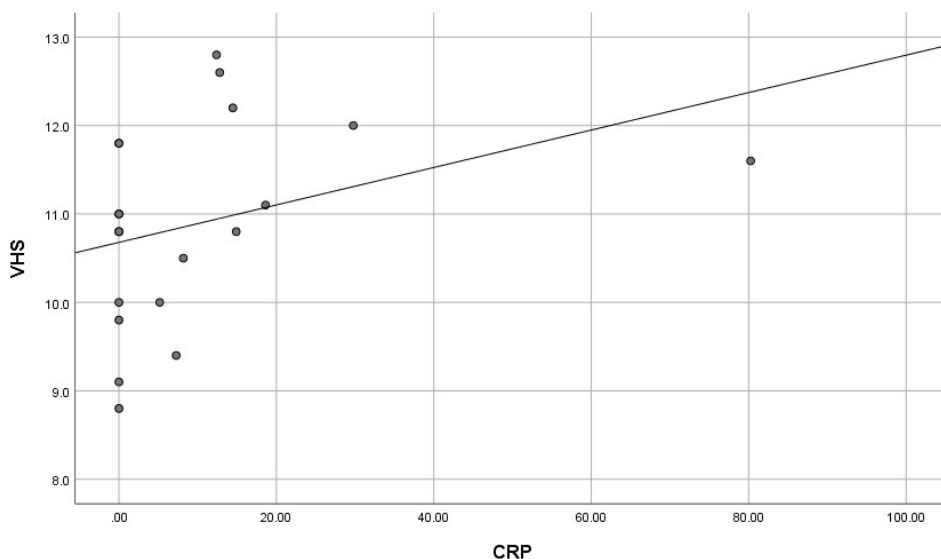
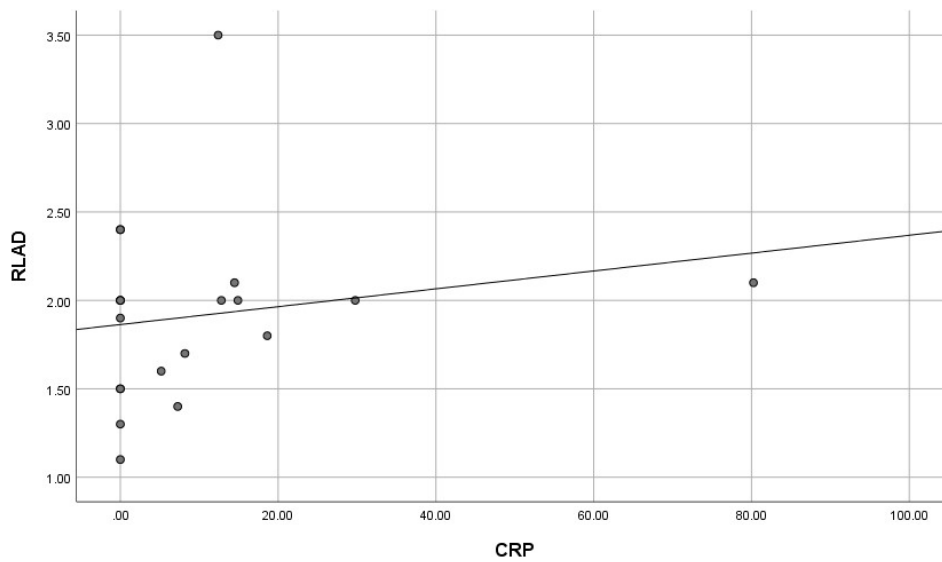


Fig. 3. Correlation between CRP and RLAD in MMVD dogs (Correlation coefficient 0.242,  $P>0.05$ ).

the correlation between RLAD and CRP (Hwang et al, 2021).

Previous studies have confirmed that RLAD measurement values showed a strong correlation compared to VHS measurement values, and they were not associated with white CBC and CRP measurement values according to ACVIM stages (Sánchez Salguero et al, 2018). This is in line with the results of this study, indicating a correlation between an increase in white blood cell counts, elevated CRP, and an increase in RLAD measurement values according to ACVIM stages in small breed dogs with MMVD in South Korea.

In a study by Domanjko Petrič et al (Domanjko Petrič et al, 2018), the CBC results showed a significant increase in WBC, neutrophils, and CRP in ISACHC III depending on the ISACHC stage. In this study, WBC and neutrophil showed no significant differences among ACVIM stages. The results show that only monocytes are significantly elevated in ACVIM stage C. Monocytes are known to increase systemic inflammation-modulating cytokine production along with lymphocytes (Domanjko Petrič et al, 2018). This result could be due to an inflammatory process from a CHF condition; however, further studies on specific pathophysiology of monocyte



**Fig. 4.** Correlation between VHS and RLAD in MMVD dogs (Correlation coefficient 0.708,  $P < 0.01$ ).

increase in MMVD progression are needed.

It was confirmed that RLAD measurements exhibited a higher capability than VHS in determining MMVD stages. Consequently, RLAD was utilized as a reference point to investigate changes in CRP levels and white blood cell counts. Among the numerous patients, the exclusion of individuals was made with underlying conditions and inflammatory diseases that could affect CRP levels. Furthermore, animals presenting with congestive heart failure significantly impacting CRP levels were also excluded from the study cohort. Additionally, this study was unable to include a group of healthy dogs, as the majority of owners of healthy small-breed dogs were unwilling to undergo echocardiography. As a result, we were unable to assess the reproducibility of each measured value separately.

Regarding the increase in CRP from the advanced stage of heart disease, in a study by Hwang et al. (Hwang et al, 2021), an increase in CRP is observed by the advancement of heart diseases stages as defined by ACVIM. As the ACVIM stage increases, the VLAS level increases, and as the VLAS level increases, an increase in CRP is observed. In this paper, it was confirmed that CRP increased as the ACVIM stage increased.

Regarding the increase in VHS from the advanced stage of heart disease, in a study by Lee et al. (Lee et al, 2022) as the ACVIM stage increases, VHS increases. This

paper shows that when VHS is high, CRP also increases. Based on this, it can be judged that as the ACVIM stage increases, VHS increases and CRP also increases.

Regarding the increase in RLAD from the advanced stage of heart disease, in a study by Lee et al. (Lee et al, 2022) RLAD increases as the ACVIM stage increases. In this paper, the increase in RLAD is judged to be significant to the increase in VHS.

Also, in the study by Lee et al. (Lee et al, 2022) it can be confirmed that VHS and RLAD increase as the ACVIM stage increases, and the same results were confirmed in this paper.

## CONCLUSION

This study was conducted to compare the differences in RLAD, CBC, and CRP among dogs diagnosed with MMVD at ACVIM stages B1, B2, and C, and to investigate the correlation between RLAD and CRP. Monocytes and CRP of ACVIM stage C were significantly higher than those of ACVIM stage B1 and B2. These results suggest that monocyte and CRP levels may be a valuable diagnostic indicator for heart disease in dogs during the diagnostic evaluation. However, further studies are needed to clarify the pathophysiology related to increased monocytes and CRP in ACVIM stage C.

## CONFLICT OF INTEREST

No potential conflict of interest relevant to this article was reported.

## ORCID

Jihee Hong, <https://orcid.org/0009-0005-1159-3715>  
 Han-Joon Lee, <https://orcid.org/0000-0001-9340-4095>  
 Dong-Kwan Lee, <https://orcid.org/0000-0001-9120-3863>  
 Kun-Ho Song, <https://orcid.org/0000-0001-8478-2035>

## REFERENCES

- Buchanan JW, Bücheler J. 1995. Vertebral scale system to measure heart size in radiographs. *J Am Vet Med Assoc* 206: 194-199.
- Domanjko Petrič A, Lukman T, Verk B, Nemec Svete A. 2018. Systemic inflammation in dogs with advanced-stage heart failure. *Acta Vet Scand* 60: 20.
- Ettinger SJ, Feldman EC, Cote E. pp. 1252-1264. *Textbook of veterinary internal medicine*. 8th ed. Elsevier. St. Louis, Missouri.
- Fox PR. 2012. Pathology of myxomatous mitral valve disease in the dog. *J Vet Cardiol* 14: 103-126.
- Hwang SH, Song KH. 2021. Assessment of vertebral left atrial size and C-reactive protein in dogs with myxomatous mitral valve disease. *J Vet Clin* 38.1: 16-20.
- Keene BW, Atkins CE, Bonagura JD, Fox PR, Häggström J, Fuentes VL, Oyama MA, Rush JE, Stepien R, Uechi M. 2019. ACVIM consensus guidelines for the diagnosis and treatment of myxomatous mitral valve disease in dogs. *J Vet Intern Med* 33: 1127-1140.
- Kittleson MD, Brown WA. 2003. Regurgitant fraction measured by using the proximal isovelocity surface area method in dogs with chronic myxomatous mitral valve disease. *J Vet Intern Med* 17: 84-88.
- Lam C, Gavaghan BJ, Meyers FE. 2021. Radiographic quantification of left atrial size in dogs with myxomatous mitral valve disease. *J Vet Intern Med* 35: 747-754.
- Lee SI, Lee HJ, Song JH, Song KH. 2022. Assessment of radiographic left atrial dimension in Maltese dogs with ACVIM stage B myxomatous mitral valve disease. *J Vet Clin* 39: 287-293.
- Malcolm EL, Visser LC, Phillips KL, Johnson LR. 2018. Diagnostic value of vertebral left atrial size as determined from thoracic radiographs for assessment of left atrial size in dogs with myxomatous mitral valve disease. *J Am Vet Med Assoc* 253: 1038-1045.
- Reimann MJ, Ljingsvall I, Hillström A, Møller JE, Hagman R, Falk T, et al. 2016. Increased serum C-reactive protein concentrations in dogs with congestive heart failure due to myxomatous mitral valve disease. *Vet J* 209: 113-118.
- Sánchez Salguero X, Prandi D, Llabrés-Díaz F, Manzanilla EG, Bussadori C. 2018. A radiographic measurement of left atrial size in dogs. *Ir Vet J* 71: 25.
- Vezzosi T, Puccinelli C, Tognetti R, Pelligra T, Citi S. 2020. Radiographic vertebral left atrial size: A reference interval study in healthy adult dogs. *Vet Radiol Ultrasound* 61: 507-511.