



Comparison of the effects of two different styles of orally prescribing prednisolone on postoperative sequelae of surgical extraction of an impacted mandibular third molar: a single-blind randomized study

Mohammed Mousa H. Bakri¹, Faisal Hussain Alabdali², Rashed Hussain Mahzari², Thamer Jabril Rajhi²,
 Norah Mohammed Gohal², Rehab Abdu Sufyani², Asma Ali Hezam¹, Ahtesham Ahmed Qurishi¹,
 Hamed Mousa Bakri³, Fareedi Mukram Ali¹

¹Division of Oral and Maxillofacial Surgery, Department of Oral and Maxillofacial Surgery and Diagnostic Sciences, College of Dentistry, Jazan University, Jazan, ²Private Clinic, Jazan, ³Department of Periodontology and Implant Dentistry, Jazan Specialized Dental Center, Jazan, Saudi Arabia

Abstract (J Korean Assoc Oral Maxillofac Surg 2024;50:27-34)

Objectives: Surgical intervention for removal of an impacted third molar can lead to significant pain and swelling. Corticosteroids show promise for mitigating postoperative sequelae across various surgical contexts. The use of corticosteroids following minor oral surgery, though controversial, has already been proven effective. However, little research has explored peroral prescription of corticosteroids despite its convenience for outpatients and for non-surgeons like implantologists and periodontists and others who don't have access to needle injections. The aim of this study was to address a void in the literature by comparing the effects of two styles of preoral administration of prednisolone after surgical removal of the mandibular third molar and to determine which style minimizes postoperative sequelae.

Materials and Methods: A randomized, split-mouth clinical study was conducted to investigate the efficacy of two different styles of preoral prednisolone in mitigating postoperative sequelae following surgical extraction of impacted mandibular third molars. Fifteen participants were enrolled in the study. Random selection was used to determine the prescription style for the right and left mandibular arch. Group A included those who received a single dose of prednisolone 25 mg, while group B received prednisolone 5 mg postoperatively for a period of three days (5 mg three times/day on the first postoperative day, 5 mg twice/day on the second postoperative day; 5 mg once/day on the third postoperative day).

Results: There was a significant difference in the distance between the corner of the mouth and tragus, which decreased with the time interval with respect to group B when compared to group A.

Conclusion: The present study showed that a three-day tapered dose of prednisolone postoperatively was more effective in reducing post-extraction sequelae than a single-dose regimen.

Key words: Prednisolone, Mandibular third molar, Impaction surgery, Tapered dosage

[paper submitted 2023. 11. 24 / revised 1st 2024. 2. 3, 2nd 2024. 2. 12 / accepted 2024. 2. 14]

I. Introduction

Impacted mandibular third molars, a prevalent condition affecting up to 35% of the population, often necessitate sur-

gical extraction. In the United States alone, this procedure accounts for over 2 million extractions annually^{1,2}. However, the aftermath of such interventions can include substantial postoperative sequelae, including pain, swelling, trismus, and infection. Among these, pain is the most pervasive, and is often severe, lingering for several days. Swelling can hinder essential functions such as eating and speaking, while trismus, characterized by limited jaw movement, can impede oral hygiene practices. Although rare, infection is a grave concern following third molar extraction^{3,4}.

Prednisolone, a corticosteroid known for its anti-inflammatory and immunosuppressive properties, has exhibited promise in mitigating postoperative sequelae across various

Mohammed Mousa H. Bakri

Division of Oral and Maxillofacial Surgery, Department of Oral and Maxillofacial Surgery and Diagnostic Sciences, College of Dentistry, Jazan University, Jazan 82816, Saudi Arabia

TEL: +966-569918432

E-mail: mmb644@nyu.edu

ORCID: <https://orcid.org/0000-0002-5775-2938>

© This is an open-access article distributed under the terms of the Creative Commons Attribution Non-Commercial License (<http://creativecommons.org/licenses/by-nc/4.0/>), which permits unrestricted non-commercial use, distribution, and reproduction in any medium, provided the original work is properly cited.

Copyright © 2024 The Korean Association of Oral and Maxillofacial Surgeons.

surgical contexts, including third molar extraction^{2,3}. While the precise mechanism remains unclear, prednisolone likely dampens the inflammatory response after surgery, which could diminish pain, swelling, and trismus. Furthermore, prednisolone's immune-suppressive properties could potentially aid in preventing postoperative infections^{3,5}.

Numerous investigations have explored the utility of prednisolone for alleviating postoperative sequelae after third molar extraction, with a spectrum of different outcomes. Some studies emphasized the effectiveness of prednisolone in this context; Bierne and Holland's study in 1993 demonstrated that patients administered prednisolone experienced significantly reduced pain and swelling compared to their counterparts¹. Similarly, Jepsen and Andreasen in 1991 observed decreased pain and trismus in prednisolone-treated patients⁴.

However, other studies failed to establish significant benefits of prednisolone administration. Ozok and Uslu in 2007 found no discernible disparities in pain or swelling between prednisolone-treated and untreated patients⁶. Similarly, Yilmaz and Ozturk in 2004 reported no substantial differences in pain, swelling, or trismus⁷.

Several factors potentially influence the efficacy of prednisolone in ameliorating postoperative sequelae after third molar extraction: the dosage of prednisolone, the duration of treatment, and the timing of administration^{3,7-9}. Optimal dosage remains controversial, with conflicting findings regarding higher doses over lower doses. Similarly, there is no consensus on the ideal treatment duration, with studies demonstrating the efficacy of both shorter and longer treatment courses^{8,9}. Additionally, the time context of prednisolone administration is noteworthy, with studies supporting its preoperative and postoperative use^{3,8,9}. This study aims to compare two prescribing styles of prednisolone and determine which one leads to fewer postoperative complications.

II. Materials and Methods

1. Study design

A randomized split-mouth clinical study was conducted to investigate the efficacy of prednisolone in mitigating postoperative sequelae following surgical extraction of impacted mandibular third molars. The study was employed at Jazan University College of Dentistry clinics from January to June 2023 and used a within-subject design, with each participant serving as their own control by comparing two different treatment approaches within the same individual.

All methods for this study were carried out in compliance with the Declaration of Helsinki. The study adhered to ethical guidelines and obtained appropriate ethical approval from the Institutional Review Board (IRB) and the Standing Committee for Scientific Research - Jazan University (HAPO-10-Z-001) with reference No. REC-44/07/505. All research data is in the possession of the corresponding author. Informed consent was obtained from each participant before participation in the study, and their confidentiality and anonymity were strictly ensured.

Sample size was calculated based on a previously published study by Al-Shamiri et al.⁴. A sample-size calculator (<https://stats.oarc.ucla.edu/other/gpower/>) was utilized. Finally, 15 participants were enrolled in the study: eight females and seven males. Inclusion criteria included age between 18 to 30 years, good health status, and the presence of impacted mandibular third molars necessitating surgical extraction (right and left side) with complete root formation.

All of the impacted cases were Class II, Position B on Pell and Gregory classification of impacted mandibular third molars⁴. This study's surgical procedures included bone removal. The researcher (M.M.H.B.) used the envelope system to decide whether to initially operate on the left or right side. The surgical extraction procedure was performed unilaterally, with a minimum of 21 days before surgical extraction on the opposite side.

The study excluded all possible participants who had a history of thromboembolic or cardiovascular events, hypertension, gastrointestinal tract ulcers, diabetes, glaucoma, active bacterial, fungal, or viral infections, or psychosis. Furthermore, those who were taking anti-inflammatory medications and women who were pregnant or lactating were also excluded from the study. All patients underwent radiographic (periapical and panorex view) and clinical examinations performed by a single examiner.

Participants were selected through a rigorous screening process from among patients who visited the College of Dentistry, Jazan University, to ensure homogeneity in the study population. Randomization was performed via computer-generated sequence to allocate participants into group A (single dose) or group B (tapered dose), ensuring an even distribution of participants between the groups.

2. Procedure

A single qualified oral and maxillofacial surgeon who was blinded to group enrollment and who had a postgraduate de-

gree and four years of experience in the specialty (M.M.H.B.) performed surgery for every patient who participated in the trial. Anesthesia was achieved locally using a mepivacaine 2%/epinephrine 1:100,000 (Septodont) to block the inferior alveolar, lingual, and buccal nerves.

Three-sided mucoperiosteal flaps were reflected, buccal bone guttering was carried out under irrigation with sterile isotonic saline, and tooth division was performed with a low-speed handpiece and appropriately sized round surgical burs as necessary; the third molar was subsequently removed, after which the flap was repositioned and sutured with 3/0 black silk. Every patient was given the standard postoperative instructions and analgesics (ibuprofen 400 mg three times a day for 3 days).

3. Intervention

Participants in group A received a single dose of prednisolone 25 mg, while those in group B received prednisolone 5 mg postoperatively for three days (5 mg three times/day on the first postoperative day, 5 mg twice/day on the second postoperative day; 5 mg once/day on the third postoperative day). The intervention was administered in a single-blind fashion, where the researchers who collected the data were blinded to treatment allocation.

4. Data collection

Preoperative and postoperative parameters were assessed to quantify the impact of prednisolone on postoperative sequelae. Parameters included maximum mouth opening, facial swelling (from the corner of the mouth to the tragus and the canthus to the mandibular angle), and pain intensity using a visual analog scale (VAS). Measurements were taken at various times: preoperative, immediately postoperative, and on the first day, third day, and seventh day following the surgical procedure. Each participant's data were systematically recorded in Microsoft Excel 2010 (Microsoft), ensuring accurate and organized data management.

5. Data analysis

Analysis of the collected data utilized the IBM SPSS Statistics software (ver. 22; IBM). Descriptive statistics, including measures such as mean and standard deviation, were calculated for the quantitative variables. A significance level of 0.05 was established ($P < 0.05$) as the threshold for determin-

ing statistical significance. Prior to analysis, the normality of the data was assessed using the Shapiro–Wilk test to ensure the assumptions of the statistical tests were met. Unpaired *t*-tests were employed to compare numerical measurements between the two groups. This statistical test was chosen to discern any significant differences concerning the parameters under investigation between group A (single dose) and group B (tapered dose). The pain intensity between the two groups was analyzed using the chi-square test.

III. Results

1. Comparison of mouth opening between group A (single dose) and group B (tapered dose)

No statistically significant difference in mouth opening was observed at baseline. However, postoperatively on the first day, third day, and seventh day, participants in group B (tapered dosage) showed significantly more mouth opening than group A. (Table 1, Fig. 1)

2. Comparison of facial swelling (in mm) between group A (single dose) and group B (tapered dose) based on COM–TRG (corner of the mouth to the tragus)

A statistically significant difference in the decrease in distance between the corner of the mouth and tragus with time was observed between group B and group A. (Table 2, Fig. 2)

3. Comparison of canthus–M angle (in mm) between group A (single dose) and group B (tapered dose)

A statistically significant difference was observed between group B and group A in canthus and mandibular angle decrease over time. (Table 3, Fig. 3)

4. Comparison of pain VAS scores between group A (single dose) and group B (tapered dose) in relation to pain parameter

No Statistically significant difference was observed in pain parameters with all the time intervals when comparing the pain VAS scores between group A and group B. (Table 4, Fig. 4)

Table 1. Comparison between Group A (single dose) and Group B (tapering dose) in relation to mouth opening

	Mouth opening (mm)		Unpaired <i>t</i> -test	<i>P</i> -value
	Group A	Group B		
Preoperative	47.5±6.1	46.8±4.9	0.981	0.372
Immediate postoperative	41.62±5.91	44.91±5.1	-3.981	0.049*
Day 1	28.81±3.97	33.64±5.91	-5.915	0.021*
Day 3	34.81±5.43	41.88±5.93	-8.221	0.002*
Day 7	39.03±4.91	44.09±2.87	-5.587	0.043*

**P*<0.05.

Values are presented as mean±standard deviation.

Mohammed Mousa H. Bakri et al: Comparison of the effects of two different styles of orally prescribing prednisolone on postoperative sequelae of surgical extraction of an impacted mandibular third molar: a single-blind randomized study. J Korean Assoc Oral Maxillofac Surg 2024

Table 2. Comparison of COM-TRG parameter, i.e., between Group A (single dose) and Group B (tapering dose) in relation to facial swelling

	COM-TRG measurement (mm)		Unpaired <i>t</i> -test	<i>P</i> -value
	Group A	Group B		
Preoperative	110.1±16.8	110.25±14.91	0.731	0.582
Immediate postoperative	112.6±9.31	112.1±13.4	1.234	0.261
Day 1	123.7±7.92	117.9±11.22	4.096	0.031*
Day 3	126.9±11.2	122.0±10.4	6.778	0.016*
Day 7	113.4±12.9	111.5±12.5	5.081	0.048*

**P*<0.05.

(COM-TRG: corner of the mouth to the tragus)

Values are presented as mean±standard deviation.

Mohammed Mousa H. Bakri et al: Comparison of the effects of two different styles of orally prescribing prednisolone on postoperative sequelae of surgical extraction of an impacted mandibular third molar: a single-blind randomized study. J Korean Assoc Oral Maxillofac Surg 2024

IV. Discussion

The surgical removal of an impacted third molar can lead to considerable pain and swelling for the patient. Employing proper surgical techniques and handling tissues delicately can help minimize these symptoms. When tissue damage occurs, the body responds with inflammation, its defense mechanism against cell injury^{4,9,10}. This involves the release of substances like histamine, bradykinin, and serotonin. Histamine induces local blood vessel dilation, increasing blood flow to the damaged region. Additionally, the permeability of venous capillaries and venules increases. While this inflammatory process is necessary for healing, excessive inflammation often results in unnecessary pain, swelling, and trismus^{11,12}.

Glucocorticosteroids, a group of steroids secreted by the adrenal cortex, possess anti-inflammatory properties. These steroids, particularly corticosteroids, play a crucial role in suppressing inflammation. They interfere with processes such

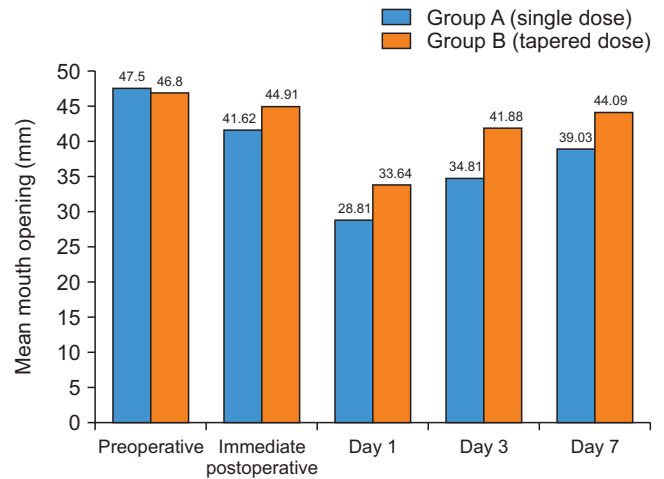


Fig. 1. Bar graph representing comparison of mean mouth opening among the groups.

Mohammed Mousa H. Bakri et al: Comparison of the effects of two different styles of orally prescribing prednisolone on postoperative sequelae of surgical extraction of an impacted mandibular third molar: a single-blind randomized study. J Korean Assoc Oral Maxillofac Surg 2024

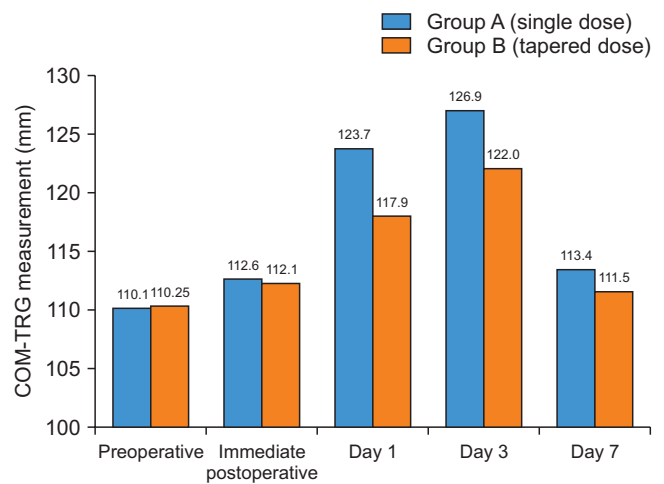


Fig. 2. COM-TRG comparison among the groups preoperatively and postoperatively. (COM-TRG: corner of the mouth to the tragus)

Mohammed Mousa H. Bakri et al: Comparison of the effects of two different styles of orally prescribing prednisolone on postoperative sequelae of surgical extraction of an impacted mandibular third molar: a single-blind randomized study. J Korean Assoc Oral Maxillofac Surg 2024

as capillary dilation, edema formation, fibrin deposition, migration of white blood cells, and phagocytosis. Higher doses of adrenal glucocorticoids are used as anti-inflammatory agents^{13,14}. Several mechanisms have been proposed for their anti-inflammatory activity, including stabilizing lysosomes, inhibiting the migration of certain white blood cells, reversing increased capillary permeability, and suppressing the function of fibroblasts. Prednisone and its active form, prednisolone, are significantly more potent (five to six times)

Table 3. Comparison of Canthus-M angle parameter, i.e., between Group A (single dose) and Group B (tapering dose) in relation to facial swelling

	Canthus-M angle (mm)		Unpaired <i>t</i> -test	<i>P</i> -value
	Group A	Group B		
Preoperative	98.2±8.91	99.3±6.91	0.511	0.582
Immediate postoperative	103.7±6.9	102.8±5.6	0.276	0.761
Day 1	109.3±12.9	108.8±10.2	1.312	0.103
Day 3	105.7±11.2	102.8±9.62	6.778	0.016*
Day 7	101.2±6.43	100.6±9.21	2.217	0.134

**P*<0.05.

(Canthus-M: medial canthus)

Values are presented as mean±standard deviation.

Mohammed Mousa H. Bakri et al: Comparison of the effects of two different styles of orally prescribing prednisolone on postoperative sequelae of surgical extraction of an impacted mandibular third molar: a single-blind randomized study. *J Korean Assoc Oral Maxillofac Surg* 2024

Table 4. Comparison of pain vas score parameter between Group A (single dose) and Group B (tapering dose) in relation to pain parameter (n=15)

	Presence of pain		χ^2 test	<i>P</i> -value
	Group A	Group B		
Preoperative	0 (0)	0 (0)	0.0	>0.999
Immediate postoperative	1 (6.7)	2 (13.3)	0.871	0.513
Day 1	4 (26.7)	4 (26.7)	0.0	>0.999
Day 3	3 (20.0)	1 (6.7)	1.731	0.092
Day 7	0 (0)	0 (0)	0.001	0.134

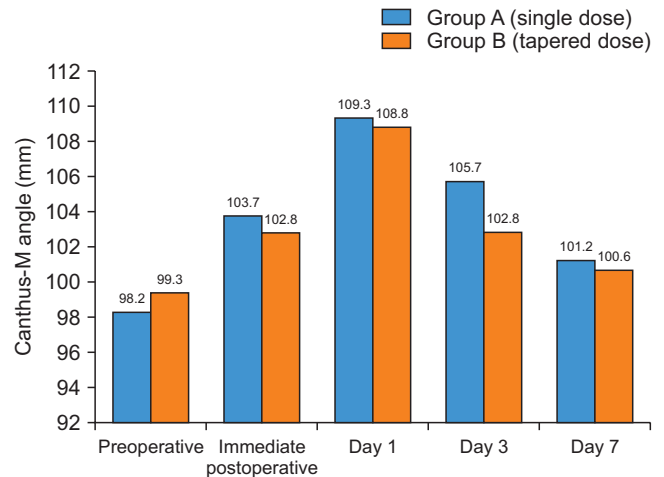
Values are presented as number (%).

Mohammed Mousa H. Bakri et al: Comparison of the effects of two different styles of orally prescribing prednisolone on postoperative sequelae of surgical extraction of an impacted mandibular third molar: a single-blind randomized study. *J Korean Assoc Oral Maxillofac Surg* 2024

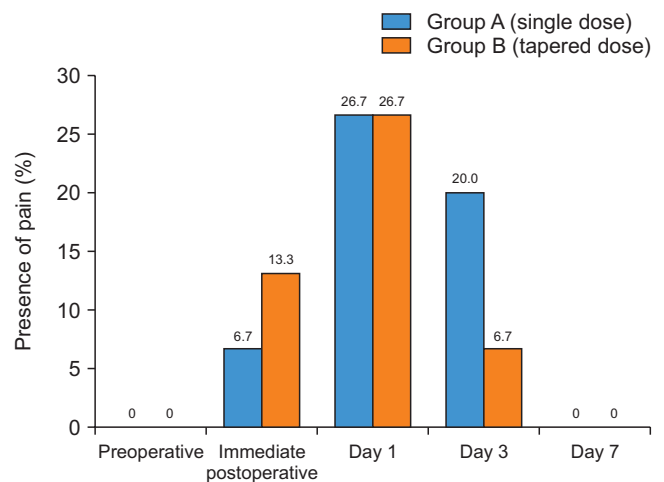
than hydrocortisone naturally produced by the body. Clinical improvement with these drugs can be observed as early as 3 hours after administration, and their peak effectiveness is reached within 6 to 12 hours¹⁵⁻¹⁷.

Steroids have typically been administered either before or around the time of surgery to enhance outcomes¹⁷⁻²⁰. The use of corticosteroid treatment might not be necessary for all cases of wisdom tooth extraction; it should only be considered for situations involving technical challenges, which can be determined by factors such as the level of impaction of the molar, the need to remove bone tissue, and the patient's age and sex.

Given that steroids come with a range of systemic side effects, it is important to avoid their unreasonable use. These medications can trigger adverse reactions, which is evident from their impact on endocrine functions, as well as their effects on behavior and vision^{18,19}. The heightened likelihood of conditions like hypertension, chronic infections, osteoporosis, and compromised glucose tolerance associ-

**Fig. 3.** Bar graph representing canthus-M angle among the group. (Canthus-M: medial canthus)

Mohammed Mousa H. Bakri et al: Comparison of the effects of two different styles of orally prescribing prednisolone on postoperative sequelae of surgical extraction of an impacted mandibular third molar: a single-blind randomized study. *J Korean Assoc Oral Maxillofac Surg* 2024

**Fig. 4.** Bar graph describing pain among the groups.

Mohammed Mousa H. Bakri et al: Comparison of the effects of two different styles of orally prescribing prednisolone on postoperative sequelae of surgical extraction of an impacted mandibular third molar: a single-blind randomized study. *J Korean Assoc Oral Maxillofac Surg* 2024

ated with high doses of corticosteroids must be carefully considered¹⁹⁻²¹.

Methylprednisolone is five times more potent than hydrocortisone without exhibiting mineralocorticoid action²²⁻²⁴. Al-Khateeb et al.²⁵ conducted a randomized study comparing dexamethasone and methylprednisolone, and concluded that the methylprednisolone group experienced greater reductions in pain and trismus²⁴. Several other studies have also indicated that methylprednisolone significantly reduces swelling and pain after third molar extraction, solidifying its position as the preferred steroid for this

procedure^{25,26}.

Different studies have suggested various modes of steroid administration. Intravenous administration provides immediate blood levels, although the sustainability of effects from high-dose IV is limited. Inadequate duration of use can result in rebound swelling, necessitating further short-duration steroid formulations^{27,28}. Intramuscular administration offers prolonged anti-inflammatory effects but increases the risk of adrenal suppression. Percutaneous routes rely on operator expertise and equipment availability, and can cause patient discomfort. Conversely, oral dosing is convenient and widely appealing. Glucocorticosteroids are rapidly and almost entirely absorbed through oral administration, matching the effectiveness of parenteral methods²⁹. Postoperative dosing has also shown efficacy^{1,29}. Thus, the present study opted for oral administration and postoperative dosing.

Methylprednisolone has an intermediate half-life of 18-30 hours²³. Oral administration of glucocorticosteroids necessitates repeated dosing to maintain adequate blood levels immediately after surgery. Corticosteroid therapy needs to extend for a minimum of three days, as swelling in steroid-treated patients often peaks on the third day post-surgery²⁸. However, prior investigations had low dosing schedules and short observation periods^{1,6,26}. Effective corticosteroid doses generally fall within the range of 80 to 625 mg hydrocortisone-equivalent anti-inflammatory dosage, translating to 16-125 mg methylprednisolone^{30,31}. Furthermore, it has been confirmed that methylprednisolone dosages of 40 mg or less do not result in adverse systemic effects³²⁻³⁵. Thus, in the present study, 5 mg of prednisolone was administered every 8 hours immediately postoperative, then tapered over the following two days. This dosage was effective for minimizing facial swelling postoperatively compared with a single-dose regimen, and no side effects were observed following steroid administration. However, these findings should be confirmed with a larger sample size.

With the small sample size of this study, it is difficult to generalize our findings. However, the sample size was calculated and was within the measured limits to support the results. Postoperative complications after the impaction of mandibular and maxillary third molars remain an important factor for maxillofacial surgeons to consider for improving the quality of life of patient during the healing phase³⁵. Oral and maxillofacial surgeons should be well versed in the management of these complications to make postoperative recovery comfortable. In this study tapered oral prednisolone was more effective than a single dose for treating patients

postoperatively. Moreover, the literature suggests that oral administration of this drug is effective, safe, painless, non-invasive, and cost-effective³⁵.

V. Conclusion

It can be concluded from the present study that a 3-day tapered regimen of prednisolone given postoperatively was more effective for reducing post-extraction sequelae than a single-dose regimen.

ORCID

Mohammed Mousa H. Bakri, <https://orcid.org/0000-0002-5775-2938>

Faisal Hussain Alabdali, <https://orcid.org/0009-0005-5532-0671>

Rashed Hussain Mahzari, <https://orcid.org/0000-0002-2301-4494>

Thamer Jabril Rajhi, <https://orcid.org/0009-0008-2023-4628>

Norah Mohammed Gohal, <https://orcid.org/0009-0002-3313-0146>

Rehab Abdu Sufyani, <https://orcid.org/0009-0002-2510-8301>

Asma Ali Hezam, <https://orcid.org/0009-0005-0549-3611>
Ahtesham Ahmed Qurishi, <https://orcid.org/0000-0002-6943-7169>

Hamed Mousa Bakri, <https://orcid.org/0009-0000-9253-4701>

Fareedi Mukram Ali, <https://orcid.org/0000-0002-6315-8273>

Authors' Contributions

M.M.H.B., H.M.B., and F.H.A. participated in data collection and wrote the manuscript. R.H.M., T.J.R., N.M.G., and A.A.Q. participated in the study design and performed the statistical analysis. R.A.S., F.M.A., and A.A.H. participated in the study design and coordination and helped to draft the manuscript. All authors read and approved the final manuscript.

Funding

No funding to declare.

Ethics Approval and Consent to Participate

The study obtained appropriate ethical approval from the Institutional Review Board (IRB) and the Standing Committee for Scientific Research - Jazan University (HAPO-10-Z-001) with reference No. REC-44/07/505. Informed consent was obtained from each participant before participation in the study.

Conflict of Interest

No potential conflict of interest relevant to this article was reported.

References

- Montgomery MT, Hogg JP, Roberts DL, Redding SW. The use of glucocorticosteroids to lessen the inflammatory sequelae following third molar surgery. *J Oral Maxillofac Surg* 1990;48:179-87. [https://doi.org/10.1016/s0278-2391\(10\)80207-1](https://doi.org/10.1016/s0278-2391(10)80207-1)
- Micó-Llorens JM, Satorres-Nieto M, Gargallo-Albiol J, Arnabat-Domínguez J, Berini-Aytés L, Gay-Escoda C. Efficacy of methylprednisolone in controlling complications after impacted lower third molar surgical extraction. *Eur J Clin Pharmacol* 2006;62:693-8. <https://doi.org/10.1007/s00228-006-0164-5>
- Herrera-Briones FJ, Prados Sánchez E, Reyes Botella C, Vallecillo Capilla M. Update on the use of corticosteroids in third molar surgery: systematic review of the literature. *Oral Surg Oral Med Oral Pathol Oral Radiol* 2013;116:e342-51. <https://doi.org/10.1016/j.oooo.2012.02.027>
- Al-Shamiri HM, Shawky M, Hassanein N. Comparative assessment of preoperative versus postoperative dexamethasone on postoperative complications following lower third molar surgical extraction. *Int J Dent* 2017;2017:1350375. <https://doi.org/10.1155/2017/1350375>
- Chugh A, Singh S, Mittal Y, Chugh V. Submucosal injection of dexamethasone and methylprednisolone for the control of postoperative sequelae after third molar surgery: randomized controlled trial. *Int J Oral Maxillofac Surg* 2018;47:228-33. <https://doi.org/10.1016/j.ijom.2017.07.009>
- Chaudhary PD, Rastogi S, Gupta P, Niranjanaprasad Indra B, Thomas R, Choudhury R. Pre-emptive effect of dexamethasone injection and consumption on post-operative swelling, pain, and trismus after third molar surgery. A prospective, double blind and randomized study. *J Oral Biol Craniofac Res* 2015;5:21-7. <https://doi.org/10.1016/j.jobcr.2015.02.001>
- Graziani F, D'Aiuto F, Arduino PG, Tonelli M, Gabriele M. Perioperative dexamethasone reduces post-surgical sequelae of wisdom tooth removal. A split-mouth randomized double-masked clinical trial. *Int J Oral Maxillofac Surg* 2006;35:241-6. <https://doi.org/10.1016/j.ijom.2005.07.010>
- Agrawal A, Chandel S, Singh N, Tiwari AK, Singh AK, Singh G. The efficacy of intralesional dexamethasone versus intravenous dexamethasone in surgery for impacted third molars: a randomized controlled trial. *Natl J Maxillofac Surg* 2020;11:94-7. https://doi.org/10.4103/njms.njms_46_17
- Suleiman IK, James O, Olasoji HO. Effect of dexamethasone, ketoprofen and cold compress on postoperative sequelae in mandibular third molar surgery: a randomized clinical trial. *Adv Oral Maxillofac Surg* 2022;5:100211. <https://doi.org/10.1016/j.adoms.2021.100211>
- Warraich R, Faisal M, Rana M, Shaheen A, Gellrich NC, Rana M. Evaluation of postoperative discomfort following third molar surgery using submucosal dexamethasone - a randomized observer blind prospective study. *Oral Surg Oral Med Oral Pathol Oral Radiol* 2013;116:16-22. <https://doi.org/10.1016/j.oooo.2012.12.007>
- Claman HN. Glucocorticosteroids II: the clinical responses. *Hosp Pract (Off Ed)* 1983;18:143-6, 149-51. <https://doi.org/10.1080/21548331.1983.11702592>
- Axelrod L. Glucocorticoid therapy. *Medicine (Baltimore)* 1976;55:39-65. <https://doi.org/10.1097/00005792-197601000-00003>
- Gilman AG, Rall TW, Nies AS, Taylor P. Goodman and Gilman's the pharmacological basis of therapeutics. 8th ed. McGraw-Hill; 1990:1436.
- Flower RJ, Blackwell GJ. Anti-inflammatory steroids induce biosynthesis of a phospholipase A2 inhibitor which prevents prostaglandin generation. *Nature* 1979;278:456-9. <https://doi.org/10.1038/278456a0>
- Hargreaves KM, Schmidt EA, Mueller GP, Dionne RA. Dexamethasone alters plasma levels of beta-endorphin and postoperative pain. *Clin Pharmacol Ther* 1987;42:601-7. <https://doi.org/10.1038/clpt.1987.206>
- Appelt GD, Appelt JM. Therapeutic pharmacology. Lea & Febiger; 1988:318-20.
- Bosker G. Pharmatecture: minimizing medications to maximize results. 2nd ed. Facts and Comparisons; 1999:125-7, 200, 226.
- UStün Y, Erdogan O, Esen E, Karsli ED. Comparison of the effects of 2 doses of methylprednisolone on pain, swelling, and trismus after third molar surgery. *Oral Surg Oral Med Oral Pathol Oral Radiol Endod* 2003;96:535-9. <https://doi.org/10.1016/s1079210403004645>
- Hyrkäs T. Effect of preoperative single doses of diclofenac and methylprednisolone on wound healing. *Scand J Plast Reconstr Surg Hand Surg* 1994;28:275-8. <https://doi.org/10.3109/02844319409022011>
- Hyrkäs T, Ylipaavalniemi P, Oikarinen VI, Paakkari I. A comparison of diclofenac with and without single-dose intravenous steroid to prevent postoperative pain after third molar removal. *J Oral Maxillofac Surg* 1993;51:634-6. [https://doi.org/10.1016/s0278-2391\(10\)80261-7](https://doi.org/10.1016/s0278-2391(10)80261-7)
- Bamgbose BO, Akinwande JA, Adeyemo WL, Ladeinde AL, Arotiba GT, Ogunlewe MO. Effects of co-administered dexamethasone and diclofenac potassium on pain, swelling and trismus following third molar surgery. *Head Face Med* 2005;1:11. <https://doi.org/10.1186/1746-160x-1-11>
- Allikmets L, Nurmand L. Farmakoloogia. Õpik üliõpilastele ja käsiraamat arstidele ning proviisoritele. University of Tartu; 2000:472-7. Estonian.
- Esen E, Taşar F, Akhan O. Determination of the anti-inflammatory effects of methylprednisolone on the sequelae of third molar surgery. *J Oral Maxillofac Surg* 1999;57:1201-6; discussion 1206-8. [https://doi.org/10.1016/s0278-2391\(99\)90486-x](https://doi.org/10.1016/s0278-2391(99)90486-x)
- Schimmer BP, Parker KL. Adrenocortical steroids and their synthetic analogs. In: Goodman LS, Hardman JG, Limbird LE, Gilman AG, eds. Goodman and Gilman's the pharmacological basis of therapeutics. 10th ed. McGraw-Hill; 2001:1587.
- Al-Khateeb TL, Marouf HA, Mahmmud MA. Clinical evaluation of dexamethasone vs. methylprednisolone for reducing postoperative inflammatory sequelae following third molar surgery. *Saudi Dent J* 1996;8:13.
- Holland CS. The influence of methylprednisolone on post-operative swelling following oral surgery. *Br J Oral Maxillofac Surg* 1987;25:293-9. [https://doi.org/10.1016/0266-4356\(87\)90068-4](https://doi.org/10.1016/0266-4356(87)90068-4)
- Beirne OR, Hollander B. The effect of methylprednisolone on pain, trismus, and swelling after removal of third molars. *Oral Surg Oral Med Oral Pathol* 1986;61:134-8. <https://doi.org/10.1016/0030->

- 4220(86)90173-8
28. Neupert EA 3rd, Lee JW, Philput CB, Gordon JR. Evaluation of dexamethasone for reduction of postsurgical sequelae of third molar removal. *J Oral Maxillofac Surg* 1992;50:1177-82; discussion 1182-3. [https://doi.org/10.1016/0278-2391\(92\)90149-t](https://doi.org/10.1016/0278-2391(92)90149-t)
 29. Milles M, Desjardins PJ. Reduction of postoperative facial swelling by low-dose methylprednisolone: an experimental study. *J Oral Maxillofac Surg* 1993;51:987-91. [https://doi.org/10.1016/s0278-2391\(10\)80041-2](https://doi.org/10.1016/s0278-2391(10)80041-2)
 30. Skjelbred P, Løkken P. Reduction of pain and swelling by a corticosteroid injected 3 hours after surgery. *Eur J Clin Pharmacol* 1982;23:141-6. <https://doi.org/10.1007/bf00545968>
 31. Selvido DI, Bhattarai BP, Niyomtham N, Riddhabhaya A, Vongsawan K, Pairuchvej V, et al. Review of dexamethasone administration for management of complications in postoperative third molar surgery. *J Korean Assoc Oral Maxillofac Surg* 2021;47:341-50. <https://doi.org/10.5125/jkaoms.2021.47.5.341>
 32. Linenberg WB. The clinical evaluation of dexamethasone in oral surgery. *Oral Surg Oral Med Oral Pathol* 1965;20:6-28. [https://doi.org/10.1016/0030-4220\(65\)90259-8](https://doi.org/10.1016/0030-4220(65)90259-8)
 33. Caci F, Gluck GM. Double-blind study of prednisolone and papase as inhibitors of complications after oral surgery. *J Am Dent Assoc* 1976;93:325-7. <https://doi.org/10.14219/jada.archive.1976.0484>
 34. Campbell WI, Kendrick RW. Postoperative dental pain--a comparative study of anti-inflammatory and analgesic agents. *Ulster Med J* 1991;60:39-43.
 35. Osunde OD, Adebola RA, Omeje UK. Management of inflammatory complications in third molar surgery: a review of the literature. *Afr Health Sci* 2011;11:530-7.

How to cite this article: Bakri MMH, Alabdali FH, Mahzari RH, Rajhi TJ, Gohal NM, Sufyani RA, et al. Comparison of the effects of two different styles of orally prescribing prednisolone on postoperative sequelae of surgical extraction of an impacted mandibular third molar: a single-blind randomized study. *J Korean Assoc Oral Maxillofac Surg* 2024;50:27-34. <https://doi.org/10.5125/jkaoms.2024.50.1.27>