



# Chyle leak after head and neck surgeries: a comprehensive review of diagnosis and management strategies

Aparna Ganesan<sup>1</sup>, Nehal C. Singh<sup>2</sup>, Naren P. Khatri<sup>3</sup>, Charanjeet Singh Madaan<sup>4</sup>, Savreek Kaur<sup>4</sup>, Amanjot Kaur<sup>5</sup>

<sup>1</sup>Department of Oral Oncology, Kidwai Memorial Institute of Oncology, Bengaluru, <sup>2</sup>Department of Anaesthesiology & Intensive Care, Postgraduate Institute of Medical Education and Research (PGIMER), Chandigarh, <sup>3</sup>Department of Orthopedics, Zydus Sitapur Hospital, Ahmedabad, India, <sup>4</sup>Schulich School of Medicine and Dentistry, Western University, London, ON, Canada, <sup>5</sup>Department of Oral and Maxillofacial Surgery, All India Institute of Medical Sciences, Jammu, India

**Abstract** (J Korean Assoc Oral Maxillofac Surg 2024;50:3-12)

Chyle leaks are uncommon complications after head and neck surgeries. Although uncommon, such a complication is noteworthy mention due to its perplexing diagnosis and management strategies. This scoping review aims to highlight and emphasize the diagnosis and management options proposed in the literature. A comprehensive search was performed in PubMed, Google Scholar, Cochrane Library, and Scopus databases and identified 617 articles that were reduced to 40 studies and reports after applying the eligibility criteria. Although numerous treatment options ranging from simple, conservative measures to invasive surgical procedures have been mentioned for low-output, high-output, and massive leaks, there is no concrete evidence on the best method. Thus, a combination of management options must be customized by case for optimum results.

**Key words:** Chyle, Thoracic duct, Neck dissection, Octreotide

[paper submitted 2023. 6. 11 / revised 2023. 8. 26 / accepted 2023. 9. 3]

## I. Introduction

Chyle leaks (CLs) are rare yet significant complications of head and neck surgeries, with a reported incidence of 1%-8%<sup>1</sup>. They may present as milky white fluid collection in the drain, which may suddenly increase on starting enteral feeding or as localized fluctuant collections in the neck wound with overlying skin erythema. Chyle extravasation can result in metabolic disturbances, electrolyte imbalances, infection, delayed wound healing, skin necrosis, and chylothorax, if persistent<sup>2</sup>. Prompt identification, followed by management of the leak, are essential to ensure optimal outcomes after surgery.

Extensive knowledge of the embryology and anatomy of the thoracic duct remains mandatory for the operating sur-

geon to avoid intraoperative mishaps. Lymphatic vessels develop by the end of the 6th week of intrauterine life from stem cells<sup>3</sup>. Multiple lymphatic clefts arise and eventually fuse to form a plexus. Subsequently, selective atrophy of these plexuses gives rise to a single duct that drains lymphatic fluid from the right lower half and entire left half of the body below the clavicle. This duct enters at the level of T12-L2, from the cisterna chyli, and ascends cranially between the aorta and azygos vein, entering the thorax through the aortic hiatus. The intrathoracic course commences within the posterior mediastinum where, at the level of T7, it takes an oblique course behind the esophagus. At T5-T6 levels, the duct crosses the midline to the left and courses behind the aorta to approximately 2-3 cm above the clavicle, ultimately terminating into the confluence of the left internal jugular and subclavian veins in the superior mediastinum. The lower two-thirds and upper one-third of the thoracic duct spring from the embryonic right thoracic duct and left duct, respectively<sup>3</sup>. (Fig. 1)

The right lymphatic duct with a short 2 cm course is located anterior to the scalenus anterior muscle and is formed by the confluence of the right jugular, subclavian, and bronchomediastinal trunks. It empties at the junction of the right in-

---

### Amanjot Kaur

Department of Oral and Maxillofacial Surgery, All India Institute of Medical Sciences, Vijaypur, Jammu 184120, India

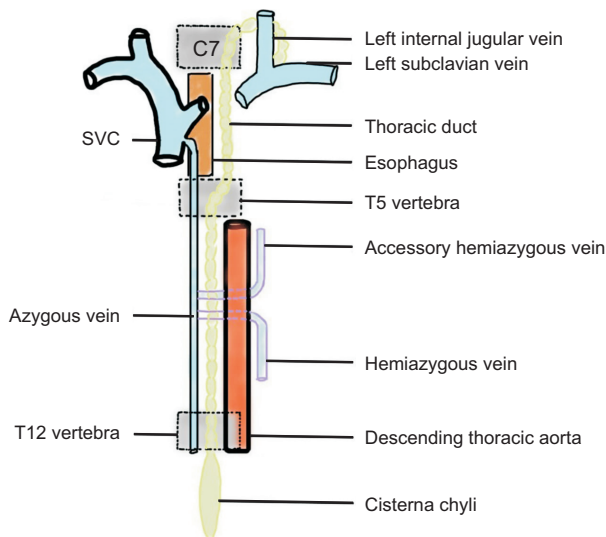
TEL: +91-9988515692

E-mail: amanjotkaur1992@yahoo.com

ORCID: <https://orcid.org/0000-0001-5560-0140>

© This is an open-access article distributed under the terms of the Creative Commons Attribution Non-Commercial License (<http://creativecommons.org/licenses/by-nc/4.0/>), which permits unrestricted non-commercial use, distribution, and reproduction in any medium, provided the original work is properly cited.

Copyright © 2024 The Korean Association of Oral and Maxillofacial Surgeons.



**Fig. 1.** Anatomy of thoracic duct. (SVC: superior vena cava)  
 Apama Ganesan et al: Chyle leak after head and neck surgeries: a comprehensive review of diagnosis and management strategies. J Korean Assoc Oral Maxillofac Surg 2024

ternal jugular and subclavian veins into the systemic venous system, draining lymphatic fluid from the right thorax, right upper limb, and right half of the head and neck<sup>3</sup>.

The thoracic duct contains about 5-20 bicuspid valves with morphological variations. These valves are located more closely in the cephalic portion of the duct to handle higher pressures, preventing backflow. One centimeter proximal to the lymphovenous junction, ostial-type valves are found and prevent retrograde blood flow into the lymphatic system during episodes of elevated venous pressure, such as coughing or sneezing<sup>3</sup>.

Variations in the normal anatomy of the thoracic duct have been extensively described with established classification systems. A few noteworthy variations include multiple channels in the intrathoracic course (40%), failure to cross the midline at T5-T6 with lymphovenous connection on the right side (6%), emptying into the subclavian vein (18%) or jugulo-venous bulb (32%), or multiple terminating points (24%). According to Kinnaert<sup>4</sup>, the incidence of a single thoracic duct is 13%. Sixty-six percent of thoracic ducts presented as multiple channels terminating as a short common duct, and 21% comprised multiple channels ending separately<sup>4,6</sup>.

Several treatment and prevention strategies for CL have been proposed. Nevertheless, there is lack of consensus or guidelines regarding the timing of intervention and type of intervention, whether conservative, pharmacotherapy, or surgical. The present comprehensive review describes the various management strategies proposed for CL after neck dissection.

## II. Methodology

### 1. Protocol and registration

The authors framed the methodology and defined the eligibility criteria before commencement of this review, and the study protocol follows the PRISMA (Preferred Reporting Items for Systematic Reviews and Meta-Analyses) guidelines.

### 2. Literature search

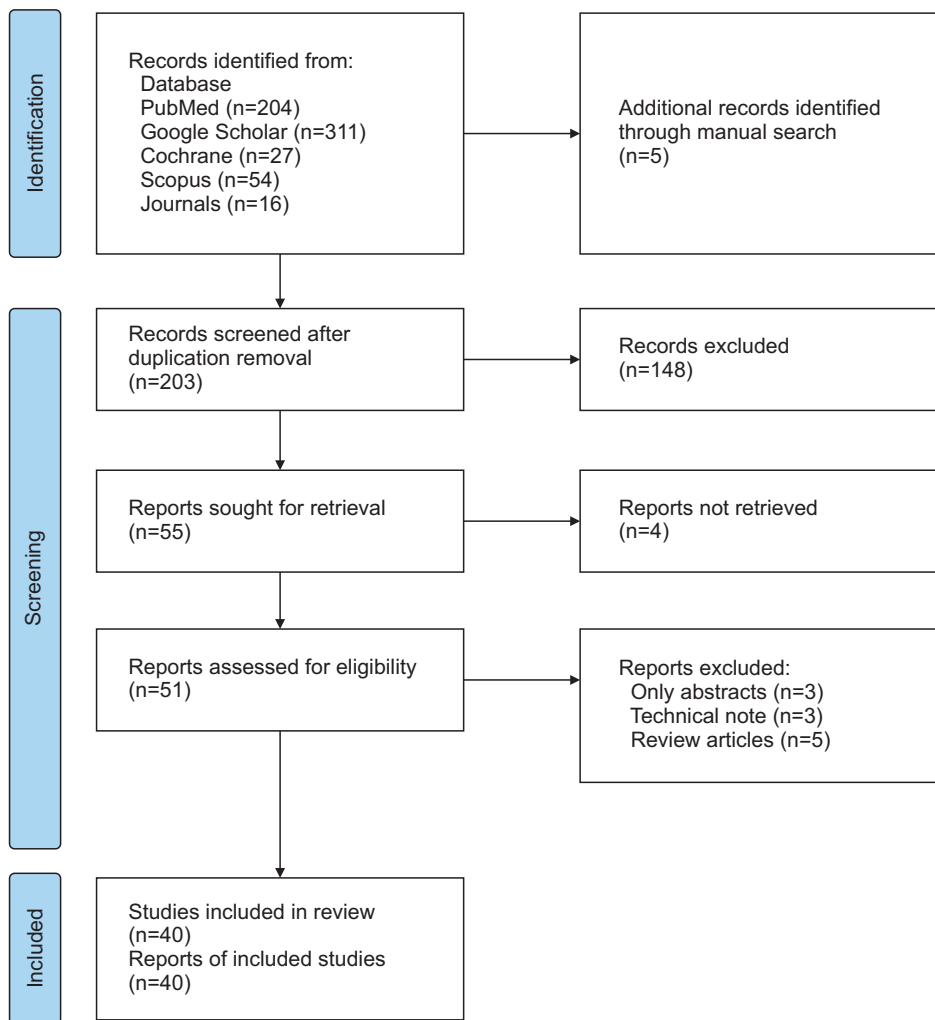
Two authors (A.K. and A.G.) independently searched various databases (PubMed, Google Scholar, Cochrane Library, and Scopus) using the keywords “chyle leak,” “cancer,” “head and neck,” and “surgery.” Further, databases of oral and maxillofacial surgery journals like *International Journal of Oral and Maxillofacial Surgery*, *Journal of Oral and Maxillofacial Surgery*, *British Journal of Oral and Maxillofacial Surgery*, *Journal of Cranio-Maxillofacial Surgery*, and *Journal of Maxillofacial and Oral Surgery* were reviewed for suitable articles. References from the studies identified above were additionally scrutinized to find eligible studies. All English language articles in the databases up to 28th February 2023 were included.

### 3. Eligibility criteria

All English language retrospective studies, prospective studies, case reports, or case series focusing on CL after head and neck surgeries were included. However, cadaveric or animal studies, editorials, letters, commentaries, and other CL studies not pertaining to head and neck surgery were excluded.

### 4. Study selection and data extraction

Two reviewers (A.K. and A.G.) independently selected studies and extracted data; areas of disagreements were mutually discussed and resolved. The following data were extracted: authors’ name, type of study, year of study, number of patients, type of surgery, diagnosis, timing of treatment, and type of treatment (conservative, medical with drugs, surgical only, surgical with drugs).



**Fig. 2.** The PRISMA (Preferred Reporting Items for Systematic Reviews and Meta-Analyses) flow diagram. *Apama Ganesan et al: Chyle leak after head and neck surgeries: a comprehensive review of diagnosis and management strategies. J Korean Assoc Oral Maxillofac Surg 2024*

### III. Results

Six hundred twelve articles were identified by review of the literature and databases, and five additional articles were identified by manual search. After removal of duplicates, 203 articles were screened by title, abstract, and language. Fifty-one reports were retrieved and assessed for eligibility. Finally, 40 articles were shortlisted and included in this review<sup>7-46</sup>. (Fig. 2)

#### 1. Characteristics of individual studies

In the 40 studies, 139 patients were reported to have CL after head and neck surgeries (26 left neck dissections, 4 right neck dissections, 19 bilateral neck dissections, 85 neck dissections with side unspecified, and 6 patients who underwent other procedures of the neck such as lobectomy, thyroidectomy, or parathyroidectomy)<sup>7-46</sup>. (Table 1, Supplementary Table 1)

#### 2. Characteristics of leak and diagnosis

CLs ranged from low volume (100 mL/day) to massive volume (4,000 mL/day) based on drain output. Twenty-one studies confirmed CL by clinical judgment, whereas 14 studies utilized the criterion of triglyceride level >100 mg/dL (or greater than serum levels). Six studies did not specify the parameters they based their diagnoses of a CL on.

#### 3. Treatment strategies

Somatostatin was assessed for its efficacy in reducing CL in seven studies. Mean dosage was subcutaneous (SC) 100 µg every eight hours. Coşkun and Yildirim<sup>7</sup> and Priego Jiménez et al.<sup>8</sup> used higher intravenous once-daily doses of 6 mg and 3 mg, respectively. The duration of treatment ranged from 5-24 days with most of the leaks being controlled within 10 days; only one case reported by Valentine et al.<sup>9</sup> required treatment for longer than 10 days (24 days).

**Table 1.** Characteristics of individual studies included in this review

Study	No. of patients	Type of surgery	Characteristics of leak	Diagnosis	Treatment drug and dose	Duration of treatment	Treatment start to cessation of leak	Additional measures
de Gier et al. <sup>20</sup> (1996)	11	3 MRND, 7 RND, 1 PLND	190-4,300 mL/day	Clinical	Surgical intervention – PMMC flap+fibrin glue	-	9-30 days	Diet modification, suction drainage
Roh and Park <sup>17</sup> (2008)	4	MRND (2 cases) MRND+CND (1 case) RND (1 case)	10-50 mL/day	NA	OK-432 0.1-0.2 mg	0.2 mg×1 (2 cases) 0.2 mg×2 (1 case) 0.1 mg×1 (1 case)	2 wk to 2 mo	Pressure dressing
Cheng et al. <sup>22</sup> (2014)	2	Supraclavicular teratoma excision Left total neck dissection	Case 1: >1 L of blood-tinged chyle on surgical exploration Case 2: >300 mL/day	Clinical	Case 1: TissuePatch sealant Case 2: TissuePatch sealant	Case 1: NA Case 2: NA	Cessation confirmed intraoperatively by Valsalva maneuver	Case 1: Sternomastoid muscle+tetracycline powder for recurrence of leak Case 2: Recovery uneventful
Ahn et al. <sup>39</sup> (2015)	2	Left MRND (1)	NA	NA	SC injection of somatostatin	11 days	11 days	Suction drainage+pressure dressing
Sisliu et al. <sup>41</sup> (2014)	3	Thyroidectomy+right MRND (1) Thyroidectomy+left MRND (1) Thyroidectomy+bilateral MRND (1)	250 mL/day (n=1) 1,200 mL/day (n=1) 1,500 mL/day (n=1) >500 mL/day (n=4) <500 mL/day (n=15)	Clinical	100 µg Q8-Q12 hr SC somatostatin injection of 100 µg TID	7.5 days	6.5 days	Dietary modifications, suction drainage, surgical exploration (2)
Jain et al. <sup>44</sup> (2015)	19	RND (1) Left neck dissection		Clinical	SC injection octreotide 100 mcg TID	Low output for 5 days High output for 7 days 9.4 days	Low output for 2-4 days High output for 5 days 5.5 days	Suction drainage, dietary modifications, pressure dressing Bed rest Dietary modifications, suction drainage
Swanson et al. <sup>28</sup> (2015)	12	Left MRND (3) Right MRND (1) Thyroidectomy+bilateral MRND (3) Thyroidectomy (4)	445.5 mL	Biochemical	SC injection octreotide 100 µg TID			
Chakedis et al. <sup>26</sup> (2018)	6	Parathyroidectomy (1) Left lateral neck dissection	None; performed preoperatively to identify thoracic duct	NA	1-2 mL of indocyanine green dye 2.5 mg/mL	Single dose	NA	NA
Moussa et al. <sup>25</sup> (2020)	6	Thyroidectomy	250-1,200 mL/day	Clinical	Intranodal lymphangiography+transabdominal thoracic duct embolization	NA	3-5 days	None
Nandy et al. <sup>13</sup> (2022)	52	Right or left neck dissection	<500 mL/day (low output) >500 mL/day (high output)	Clinical	SC injection of octreotide 100 µg TID	14 days	14 days	Suction drainage, pressure dressing, dietary modification, bed rest
Al-Lami et al. <sup>23</sup> (2022)	8	Bilateral ND (I-IV) (7) Left ND (I-IV) (1)	Low output <200 mL/day (n=1) Intermediate output (500-1,000 mL/day) (n=1) High output (>1,000 mL/day) (n=6)	Clinical	Orlistat and octreotide VATS after 7 days of medical management VATS after 2-9 days of medical management	22 days	1 day	Diet modification, negative pressure
Gupta et al. <sup>46</sup> (2022)	16	MRND (9) SND (7)	<500 mL/day (n=10) >500 mL/day (n=6)	Clinical (13) Biochemical (3)	SC injection of octreotide 100 µg TID	3-10 days	5-12 days	Suction drain

MRND: modified radical neck dissection, RND: radical neck dissection, PLND: posterolateral neck dissection, PMMC: pectoralis major myocutaneous flap, CND: central neck dissection, NA: not available, SC: subcutaneous, TID: three times a day, VATS: video-assisted thoracoscopic surgery, ND: neck dissection, SND: selective neck dissection.  
 Aparna Ganesan et al. Chyle leak after head and neck surgeries: a comprehensive review of diagnosis and management strategies. J Korean Assoc Oral Maxillofac Surg 2024

The use of 100 µg SC octreotide every 8 hours (TID; three times a day) was reported in 19 studies. As an exception, Meyer et al.<sup>29</sup> administered 50 µg SC TID. Touska et al.<sup>10</sup> and Sri Kumar et al.<sup>11</sup> administered 200 µg SC TID in their studies. The duration of treatment ranged from 2-22 days, with an average of 8.9 days. Most of the leaks were reported to have ceased within 4-10 days, with 3 cases requiring additional invasive strategies due to failed treatment with octreotide<sup>12-14</sup>.

The use of etilefrine was first reported by Mathis et al.<sup>15</sup> who administered this drug at a dose of 120 mg/day at a flow rate of 5 mg/hr for eight days. Somatostatin was concurrently administered SC at a dose of 300 g/day, which then was increased to 1,500 g/day. They reported successful stoppage of the leak, although the individual efficacies of the drugs could not be assessed<sup>15</sup>. Srinivasan et al.<sup>16</sup> injected a single dose of 100 mg doxycycline intralesionally, whereas Roh and Park<sup>17</sup> injected 0.1-0.2 mg of OK-432 intralesionally in four cases. There was a successful resolution of leaks in both reports; however, there was no mention of the characteristics of the leaks. Kim et al.<sup>18</sup> applied viscous albumin extract as a sclerosant for 23 days and reported resolution of the leak.

Kadota et al.<sup>19</sup> reported successful resolution of CL with -50 mmHg negative pressure wound therapy (NPWT) along with intravenous somatostatin analog administration for six days.

Two reports<sup>20,21</sup> have described successful invasive surgical procedures using local muscle flaps (pectoralis major or scalene muscle) along with fibrin glue, surgical, tetracycline powder, or free fat grafts. Cheng et al.<sup>22</sup> used TissuePatch sealant to obliterate defects after surgical re-exploration and then resorted to use of a sternomastoid muscle flap and tetracycline powder when the leak recurred.

Minimally invasive thoracic duct ligation by video-assisted thoracoscopic surgery (VATS) or embolization was reported in 3 studies<sup>23-25</sup>. All studies confirmed cessation of the leak in 24 hours after thoracoscopic ligation and 3-5 days after embolization.

The use of adjuncts such as pressure dressings, suction drainage, and dietary modifications in the form of low-fat or fat-free medium-chain triglyceride (MCT) diet or total parenteral nutrition (TPN) were reported in all 40 studies<sup>47</sup>.

#### IV. Discussion

This review aimed to provide a comprehensive overview of the various management strategies for CL after head and neck surgeries.

Risk factors for CL include presence of metastatic nodes at

the internal jugular vein and subclavian junction, prior irradiation, low body mass index, younger age, and low prognostic nutritional index<sup>48</sup>.

The diagnosis of a CL is often subjective, and the diagnostic criteria usually vary. Preoperative identification by use of 500 mL of milk ingestion orally 6 hours before esophagectomy aids in visualization of the thoracic duct intraoperatively<sup>49</sup>. In addition, surgical identification of CL can be aided by indocyanine green dye and near-infrared imaging<sup>26</sup>. Yet another method to detect CL intraoperatively, according to Cernea et al.<sup>50</sup>, is to observe for leaks on the left of the level IV region following 20-30 seconds of abdominal compression. Placing the patient in the Trendelenburg position or raising the intrathoracic pressure utilizing a Valsalva maneuver with the anesthesiologist's assistance can aid in better visualization and isolation of the site of injury. Extravasation of turbid, milky white fluid in the surgical field should alert the surgeon to the presence of a CL.

Vokes et al.<sup>51</sup> reported propofol lipemia mimicking CL in a patient undergoing neck dissection. Such an observation should always be brought to the notice of the anesthesiologist to effectively manage any effects of propofol infusion syndrome such as bradycardia, metabolic acidosis, and myoglobinuria.

##### 1. Recognition of a postoperative CL

A sudden increase in the volume of the drain tube collection, especially after resuming enteral feeds, should alert the surgeon to a CL. In addition, a milky white or creamy fluid in the drain tube should raise suspicion of a CL.

Biochemical assessment of CL should be used to confirm the diagnosis. Specific gravity >1.01, pH >7.5, triglyceride level >100 mg/dL or greater than serum concentration, and cholesterol to triglyceride ratio <1 are all indicative of CL. In addition, the protein content of chyle is approximately half that of plasma, and the leukocyte number in chyle ranges from 400 to 6,800 (cells/mm<sup>3</sup>)<sup>2,47</sup>. Note that chylomicron levels cannot be used as a definitive indicator due to their unpredictable occurrence in the wound bed due to fat breakdown. Nevertheless, some studies have relied on chylomicron level for diagnosis of chylothorax<sup>52</sup>.

There are inconsistencies in the literature regarding what quantity of drainage amounts to a high- or a low-output leak. In general, any leak greater than 1 L/day is considered a high-output leak and necessitates surgical intervention. Massive leaks (>4 L/day) require urgent invasive procedures. How-



ever, protracted low-output leaks persisting for more than 14 days may also necessitate surgery<sup>47</sup>.

## 2. Conservative treatment modalities

Pressure dressings and serial aspirations, although performed routinely, have been widely criticized due to difficulty in application and degradation of the already compromised skin flap vascularity by the chyloma and intense inflammatory reaction. A novel but simple maneuver described by Xiang et al.<sup>53</sup> involves 24-hour application of moderate finger pressure in the supraclavicular fossa, directed infero-medially between the two heads of the sternocleidomastoid (SCM) muscle.

## 3. Role of nutrition

The major goals of nutritional management include decreasing the production of chyle, replenishing fluids and electrolytes, and preventing malnutrition. The length of nutritional therapy reported in the literature varies from 1 to 24 weeks<sup>54</sup>.

Fat-free or low-fat diets supplemented with MCT, linoleic and linolenic acids, and TPN are some of the proposed nutritional treatment options. The rationale is that dietary fat restriction may help decrease chyle flow, which would theoretically encourage the healing process. In conjunction with MCT supplementation, dietary fat restriction may limit lymphatic drainage into the portal venous circulation. A high-energy, high-protein diet with fluids and electrolytes is necessary owing to the metabolic demands of the body in the anabolic phase of healing<sup>54</sup>. Molena et al.<sup>55</sup> in their meta-analysis assessed the effectiveness of octreotide vs. dietary modification in the form of TPN but were unable to determine the efficacy of TPN as it was concurrently used with other treatment modalities. Smith et al.<sup>56</sup> in their recent systematic review highlighted the important role of an MCT diet in managing leaks of less than 1,000 mL/day along with other conservative measures.

## 4. Negative pressure wound therapy

NPWT has been used to resolve CLs using devices that apply continuous or intermittent sub-atmospheric pressure to the wound bed, diminishing the dead space and hastening the granulation process. Furthermore, they improve tissue oxygenation by minimizing inflammatory mediators. The first

use of such devices in CL was by Kadota et al.<sup>19</sup> in 2012, who applied 50 mm continuous negative pressure to eliminate CL. Dorneden et al.<sup>57</sup> used 125 mmHg pressure NPWT in three patients to stop CL and reported success. Similarly, Pines et al.<sup>27</sup> reported successful resolution of CL with 75 mmHg negative pressure after failed treatment with diet modification, somatostatin, and surgical re-exploration. The use of high (600 mmHg)- and low (125 mmHg)-pressure NPWT in 21 patients was compared by Wu et al.<sup>58</sup>, who observed that those treated with higher negative pressures had a shorter hospital stay. The foremost disadvantage of NPWT is the risk of bleeding from erosion of major vessels. Thus, there is a lacuna in the existing literature regarding the validity of NPWT, duration of use, and optimal amount of negative pressure to apply to the wound bed.

## 5. Octreotide

Ulibarri was the first to use somatostatin to treat chylous leaks in 1990. Since then, somatostatin and its analogue octreotide have been used to treat chylous fistulae of varying etiologies. How somatostatin and octreotide stop CLs, however, is poorly understood. The initial proposed mechanism was constriction of lymphatic vessels<sup>59</sup>. More precisely, activation of somatostatin receptors modifies splanchnic arteriolar resistance and gastrointestinal (GI) blood flow to reduce chyle flow. Swanson et al.<sup>28</sup> hypothesized that somatostatin acts on hepatic and pancreatic lipases, reducing chyle flow. Although somatostatin has been widely used in the past, octreotide is preferred due its ease of administration via the SC route compared to the need for continuous intravenous infusion of the somatostatin<sup>60</sup>. At present, there is no consensus regarding the dosage and duration of administration of octreotide. While most studies have reported using 100 µg every 8 hours (TID), variations include 200 µg TID<sup>61</sup>, 50 µg BID (twice a day)<sup>28</sup>, or 500 µg TID<sup>29</sup>. The average duration of administration is 2-14 days, with most of the leaks resolving within 2-11 days. Adverse effects range from trivial reactions such as GI disturbances, flatulence, dyspepsia, and glycemic dysregulation to life threatening conditions such as anaphylactic shock, pulmonary embolism, or severe GI bleed<sup>60</sup>. Magoo et al.<sup>60</sup> in their meta-analysis found octreotide to be safe and efficacious for the treatment of CL. Molena et al.<sup>55</sup> in their meta-analysis detailed the superiority of octreotide in spontaneous chylous fistula resolution compared to dietary modification.

## 6. Orlistat

Orlistat is a pancreatic lipase inhibitor that interferes with duodenal lipid breakdown, consequently reducing lipid absorption in the intestine. Through this mechanism, it drastically reduces chyle flow and subsequently hastens the healing process and fistula closure. Orlistat has been used at 120 mg administered TID 30 minutes before enteral feeding and is usually continued for up to one week after resolution of fistula and drain removal<sup>62</sup>. No major adverse reactions apart from steatorrhea and fecal urgency have been recorded. Nevertheless, there are no current supporting clinical trials or scientific literature to support its use.

## 7. Etilefrine

Etilefrine is an alpha-adrenergic sympathomimetic drug that induces smooth muscle contraction. It was postulated that it could induce contraction of the thoracic duct to curb CL. Mathis et al.<sup>15</sup> administered etilefrine at 120 mg/day intravenously at a flow rate of 5 mg/day with continuous cardiac monitoring. However, the sympathomimetic actions of the drug including hypertension, ventricular arrhythmias, headache, and acute urinary retention are worrisome. The application of this drug is limited to digestive and thoracic surgeries, and the risk-benefit ratio must be evaluated judiciously prior to administration. Etilefrine has not been widely used to treat CL after head and neck surgeries due to its serious adverse reactions.

## 8. Sclerotherapy

Use of sclerosing agents is well-accepted in the scenario of vascular malformations, and they have gained popularity in the management of CL. They obliterate vascular and lymphatic channels by causing endothelial damage, resulting in fibrosis<sup>63</sup>. Tetracycline has been injected as a sclerosant into a supraclavicular wound to stop CL. Srinivasan et al.<sup>16</sup> reported successful resolution of CL and minimal morbidity by injection of a single dose of doxycycline into the wound bed. Roh and Park<sup>17</sup> applied 0.1-0.2 mg OK-432 to CL wound beds and recommend its use in addition to pressure dressings in select cases. Sclerosants, however, are not widely used for the treatment of CL.

High output leaks and persistent leaks for more than 14 days mandate active interventions through minimally invasive surgeries, interventional radiology, or re-exploration<sup>47</sup>.

Lymphangiography of the site of leak, with or without percutaneous thoracic duct embolization, is safe and effective for the management of CL. Lymphangiography can aid in the identification of the source of the leak and help determine if control measures are effective. However, technical difficulties such as cannulation of cisterna chyli are probable. The low complication rate, satisfactory success rate, and feasibility of lymphangiography even after a failed attempt make it a suitable option prior to surgical intervention<sup>64</sup>.

Thoracoscopic ligation of the thoracic duct complex has been endorsed as an effective treatment modality. In the prone-position, three-port thoracoscopy was used to identify and clip the thoracic duct complex above the diaphragm<sup>65</sup>. Practical challenges are the risk of lung injury and the need for skilled hands. However, this is considered a safe, effective and feasible therapeutic option with minimal morbidity<sup>66</sup>.

Tissue sealants such as N-2-butyl cyanoacrylate have been used during embolization or during direct surgical exposure. These chemical substances polymerize by exothermic reaction and harden on contact with body fluids. Blythe et al.<sup>67</sup> and Cheng et al.<sup>22</sup> reported successful preoperative and postoperative use of these sealants in CL management.

A novel strategy developed by Ding et al.<sup>30</sup> involves compression using a Foley catheter. The balloon of the catheter was positioned between the internal jugular vein and sternal head of the SCM muscle and inflated with 10 mL normal saline. A gradual reduction in drain output was observed within 7 days. However, this method carries the potential risk of damage to the internal jugular vein.

## 9. Surgery

The last and ultimate resort to treat CL is surgical re-exploration yielding direct access to the injury site. The complexity of surgical access and the procedure is amplified by the inflammatory response to the extravasated chyle and the dehydrated state of the patient. Every attempt should be made to identify the duct and the site of the leak, after which the duct should be sewed with a non-absorbable suture. An adjunctive modality such as a muscle flap or tissue glue should be combined with ductal ligation. Options for muscle flaps include SCM- or omohyoid-based muscle flaps. The clavicular head of the SCM is separated from its site of origin, positioned on the wound bed, and secured to the surrounding soft tissues. In radical neck dissection, if the SCM has been sacrificed, the levator scapulae muscle can serve the same purpose<sup>68</sup>. Similarly, the omohyoid muscle can be used by severing its hyoid

attachment. Zhang et al.<sup>69</sup> used an omohyoid-based flap to cover the level IV region and reinforced this flap with non-absorbable sutures to the surrounding soft tissues.

Chang and colleagues have endorsed the use of a pectoralis major myocutaneous flap for intractable CL. The proximity of this bulky muscle to the lower neck makes it ideal for defect closure as it forms an effective barrier and seals off the leak<sup>68</sup>.

## 10. Radiotherapy

De Felice et al.<sup>70</sup> proposed using radiation therapy to treat CL. These authors found that low-dose radiation <1 Gy per fraction, with a total dose of up to 15 Gy, was successful at resolving lymphatic fistulae and lymphorrhoea. Radiotherapy can be used in the management of CL after head and neck surgeries. Low-dose irradiation modifies the inflammatory cascade and its effects by downregulating inflammatory cytokines. At present, however, there are no reported trials of radiation therapy to treat CL.

Dunlap and colleagues analyzed predictors of postoperative CL taking into consideration pathology, surgical technique, and type of surgery. Endocrine pathologies, use of a harmonic scalpel, and papillary thyroid carcinoma were significantly associated with higher CL rates than non-endocrine pathologies, monopolar cautery, and squamous cell carcinoma, respectively. However, there was no significant difference in the rate of CL with respect to level IV nodal yield, prophylactic or therapeutic dissection, level VI dissection, or prior history of irradiation<sup>48</sup>.

## V. Conclusion

We reviewed the intricacies of the current management strategies available for CL by review of the medical literature. CL is a rare complication following head and neck surgeries that results in local and systemic morbidity. This necessitates its timely diagnosis and treatment. Established interventions range from conservative measures to invasive surgical modalities, depending on the duration of the leak and the amount of chyle that is leaking. Hence, the combination of treatment options should be tailored to the individual patient's presentation.

## ORCID

Aparna Ganesan, <https://orcid.org/0000-0002-4249-2651>

Nehal C. Singh, <https://orcid.org/0000-0003-0514-1569>  
Naren P. Khatri, <https://orcid.org/0000-0001-5140-971X>  
Charanjeet Singh Madaan, <https://orcid.org/0000-0003-2648-662X>  
Savreek Kaur, <https://orcid.org/0000-0001-6876-2456>  
Amanjot Kaur, <https://orcid.org/0000-0001-5560-0140>

## Authors' Contributions

A.K. participated in conception of idea, study design, wrote manuscript. A.G. participated in data collection and wrote the manuscript. N.C.S. and N.P.K. participated in figures/tables and coordination. S.K. and C.S.M. participated in final approval of manuscript.

## Funding

No funding to declare.

## Supplementary Materials

Supplementary data is available at <http://www.jkaoms.org>

## Conflict of Interest

No potential conflict of interest relevant to this article was reported.

## References

1. Baker A, Tassone P, Dooley LM, Galloway TI, Zitsch RP 3rd. Postoperative chyle leak rate following neck dissection for squamous cell carcinoma versus papillary thyroid cancer. *Laryngoscope* 2023;133:2959-64. <https://doi.org/10.1002/lary.30627>
2. Brennan PA, Blythe JN, Herd MK, Habib A, Anand R. The contemporary management of chyle leak following cervical thoracic duct damage. *Br J Oral Maxillofac Surg* 2012;50:197-201. <https://doi.org/10.1016/j.bjoms.2011.02.001>
3. Phang K, Bowman M, Phillips A, Windsor J. Review of thoracic duct anatomical variations and clinical implications. *Clin Anat* 2014;27:637-44. <https://doi.org/10.1002/ca.22337>
4. Kinnaert P. Anatomical variations of the cervical portion of the thoracic duct in man. *J Anat* 1973;115(Pt 1):45-52.
5. Gottlieb MI, Greenfield J. Variations in the terminal portion of the human thoracic duct. *AMA Arch Surg* 1956;73:955-9. <https://doi.org/10.1001/archsurg.1956.01280060055012>
6. Seeger M, Bewig B, Günther R, Schafmayer C, Vollnberg B, Rubin D, et al. Terminal part of thoracic duct: high-resolution US imaging. *Radiology* 2009;252:897-904. <https://doi.org/10.1148/radiol.2531082036>
7. Coşkun A, Yıldırım M. Somatostatin in medical management of chyle fistula after neck dissection for papillary thyroid carcinoma. *Am J Otolaryngol* 2010;31:395-6. <https://doi.org/10.1016/j.amjoto.2009.05.002>



8. Priego Jiménez P, Collado Guirao MV, Rojo Blanco R, Grajal Marino R, Rodríguez Velasco G, García Villanueva A. Chyle fistula in right cervical area after thyroid surgery. *Clin Transl Oncol* 2008;10:593-6. <https://doi.org/10.1007/s12094-008-0257-4>
9. Valentine CN, Barresi R, Prinz RA. Somatostatin analog treatment of a cervical thoracic duct fistula. *Head Neck* 2002;24:810-3. <https://doi.org/10.1002/hed.10103>
10. Touska P, Constantinides VA, Palazzo FF. A rare complication: lymphocele following a re-operative right thyroid lobectomy for multinodular goitre. *BMJ Case Rep* 2012;2012:bcr0220125747. <https://doi.org/10.1136/bcr.2012.5747>
11. Srikumar S, Newton JR, Westin TA. Bilateral chylothorax following left-sided radical neck dissection. *J Laryngol Otol* 2006;120:705-7. <https://doi.org/10.1017/s0022215106001344>
12. Deshmukh R, Kulkarni P, Bhutekar U, Kala A, Richhariya S, Tawari H. Management of chyle leak in right side neck dissection: a rare case and review of literature (a case report). *Pan Afr Med J* 2021;40:209. <https://doi.org/10.11604/pamj.2021.40.209.30496>
13. Nandy K, Jayaprakash D, Rai S, Kumar A, Puj K, Tripathi U. Management of chyle leak after head and neck surgery; our meritorious experience in 52 cases and review of literature. *Indian J Otolaryngol Head Neck Surg* 2022;74(Suppl 3):5978-83. <https://doi.org/10.1007/s12070-021-02648-z>
14. Tenny BC, Madjarov J, Shipe T. Surgical intervention in a complicated persistent chyle leak. *Int J Surg Case Rep* 2018;42:7-9. <https://doi.org/10.1016/j.ijscr.2017.11.031>
15. Mathis C, Hamitouche S, Barberot JP, Lindas P. Refractory lymphorrhoea of the neck treated with etilefrine. *Eur Ann Otorhinolaryngol Head Neck Dis* 2021;138:383-6.
16. Srinivasan D, Green J, Pandya H, Brown A. Management of chyle leak with tetracycline sclerotherapy. *Br J Oral Maxillofac Surg* 2007;45:E7. <https://doi.org/10.1016/j.bjoms.2007.07.124>
17. Roh JL, Park CI. OK-432 sclerotherapy of cervical chylous lymphocele after neck dissection. *Laryngoscope* 2008;118:999-1002. <https://doi.org/10.1097/mlg.0b013e31816b657b>
18. Kim CW, Kim JS, Lee AH, Kim YS. Viscum album extract (Helixor-M) treatment for thoracic duct injury after modified radical neck dissection: a case report. *Gland Surg* 2021;10:832-6. <https://doi.org/10.21037/gs-20-629>
19. Kadota H, Kakiuchi Y, Yoshida T. Management of chylous fistula after neck dissection using negative-pressure wound therapy: a preliminary report. *Laryngoscope* 2012;122:997-9. <https://doi.org/10.1002/lary.23216>
20. de Gier HH, Balm AJ, Bruning PF, Gregor RT, Hilgers FJ. Systematic approach to the treatment of chylous leakage after neck dissection. *Head Neck* 1996;18:347-51. [https://doi.org/10.1002/\(sici\)1097-0347\(199607/08\)18:4%3C347::aid-hed6%3E3.0.co;2-y](https://doi.org/10.1002/(sici)1097-0347(199607/08)18:4%3C347::aid-hed6%3E3.0.co;2-y)
21. Rollon A, Salazar C, Mayorga F, Marin R, Infante P. Severe cervical chyle fistula after radical neck dissection. *Int J Oral Maxillofac Surg* 1996;25:363-5. [https://doi.org/10.1016/s0901-5027\(06\)80031-7](https://doi.org/10.1016/s0901-5027(06)80031-7)
22. Cheng L, Lau CK, Parker G. Use of TissuePatch<sup>®</sup> sealant film in the management of chyle leak in major neck surgery. *Br J Oral Maxillofac Surg* 2014;52:87-9. <https://doi.org/10.1016/j.bjoms.2013.09.007>
23. Al-lami A, Shamil E, Nixon I, Jeannon JP, Bille A, Harrison-Phipps K, et al. Improving the management of cervical chyle leak following neck dissection: a case series of management algorithm; 10 years clinical experience with video assisted thoracoscopy and thoracic duct ligation. *Clin Otolaryngol* 2022. <https://doi.org/10.22541/au.165033182.24678248/v1> [Epub ahead of print]
24. Ilcyszyn A, Ridha H, Durrani AJ. Management of chyle leak post neck dissection: a case report and literature review. *J Plast Reconstr Aesthet Surg* 2011;64:e223-30. <https://doi.org/10.1016/j.jbjs.2010.12.018>
25. Moussa AM, Maybody M, Gonzalez-Aguirre AJ, Buicko JL, Shaha AR, Santos E. Thoracic duct embolization in post-neck dissection chylous leakage: a case series of six patients and review of the literature. *Cardiovasc Intervent Radiol* 2020;43:931-7. <https://doi.org/10.1007/s00270-020-02475-9>
26. Chakedis J, Shirley LA, Terando AM, Skoracki R, Phay JE. Identification of the thoracic duct using indocyanine green during cervical lymphadenectomy. *Ann Surg Oncol* 2018;25:3711-7. <https://doi.org/10.1245/s10434-018-6690-4>
27. Pines G, Malka Yosef L, Lazar LO, Bar I, Schindel D. Negative-pressure vacuum therapy for high-output chyle leak following neck dissection. *Innovations (Phila)* 2020;15:481-3. <https://doi.org/10.1177/1556984520935535>
28. Swanson MS, Hudson RL, Bhandari N, Sinha UK, Maceri DR, Kokot N. Use of octreotide for the management of chyle fistula following neck dissection. *JAMA Otolaryngol Head Neck Surg* 2015;141:723-7. <https://doi.org/10.1001/jamaoto.2015.1176>
29. Meyer CD, McLeod IK, Gallagher DJ. Conservative management of an intraoperative chyle leak: a case report and literature review. *Mil Med* 2016;181:e1180-4. <https://doi.org/10.7205/milmed-d-15-00240>
30. Ding Z, Chen M, Pang R, Sheng R, Zhao X, Nie C. Case report: balloon compression for cervical chyle leakage post neck dissection. *Front Surg* 2022;9:1019425. <https://doi.org/10.3389/fsurg.2022.1019425>
31. Ulibarri JI, Sanz Y, Fuentes C, Mancha A, Aramendia M, Sánchez S. Reduction of lymphorrhagia from ruptured thoracic duct by somatostatin. *Lancet* 1990;336:258. [https://doi.org/10.1016/0140-6736\(90\)91793-a](https://doi.org/10.1016/0140-6736(90)91793-a)
32. Al-Sebeih K, Sadeghi N, Al-Dhahri S. Bilateral chylothorax following neck dissection: a new method of treatment. *Ann Otol Rhinol Laryngol* 2001;110:381-4. <https://doi.org/10.1177/000348940111000416>
33. Nyquist GG, Hagr A, Sobol SE, Hier MP, Black MJ. Octreotide in the medical management of chyle fistula. *Otolaryngol Head Neck Surg* 2003;128:910-1. <https://doi.org/10.1016/s0194-59980300464-9>
34. Suver DW, Perkins JA, Manning SC. Somatostatin treatment of massive lymphorrhoea following excision of a lymphatic malformation. *Int J Pediatr Otorhinolaryngol* 2004;68:845-50. <https://doi.org/10.1016/j.ijporl.2004.01.017>
35. Harlak A, Karahatay S, Onguru O, Menten O, Gerek M, Tufan T. Chyle fistula after neck dissection for an unusual breast cancer recurrence. *Breast Care (Basel)* 2008;3:274-6. <https://doi.org/10.1159/000144491>
36. Khurana H, Mishra S, Jain R, Goyal GN, Bhatnagar S. Management of postoperative chylothorax in a patient with carcinoma of thyroid and lymphadenopathy--a case report. *Middle East J Anaesthesiol* 2009;20:121-3.
37. Mikhail Ael D, Pascual JF, Gil JL. [Chylous fistula as a complication of thyroidectomy without lymphadenectomy]. *Cir Esp* 2009;86:261-2. Spanish. <https://doi.org/10.1016/j.ciresp.2008.10.011>
38. Rodier JF, Volkmar PP, Bodin F, Frigo S, Ciftci S, Dahlet C. Thoracic duct fistula after thyroid cancer surgery: towards a new treatment? *Case Rep Oncol* 2011;4:255-9. <https://doi.org/10.1159/000328801>
39. Ahn D, Sohn JH, Jeong JY. Chyle fistula after neck dissection: an 8-year, single-center, prospective study of incidence, clinical features, and treatment. *Ann Surg Oncol* 2015;22 Suppl 3:S1000-6. <https://doi.org/10.1245/s10434-015-4822-7>
40. Ogi K, Manabe Y, Kimura Y, Fujieda S. A case of successful octreotide treatment for chylous leakage after neck dissection. *Pract Oto Rhino Laryngol* 2013;106:469-73. <https://doi.org/10.5631/jibirin.106.469>
41. Süslü N, Sözeri B, Hoşal AŞ, Demircin M. The role of somatostatin treatment in the management of chylous fistula after neck dissection. *Turk Arch Otolaryngol* 2014;52:39-42. <https://doi.org/10.5152/tao.2014.242>

42. Rammal A, Zawawi F, Varshney R, Hier MP, Payne RJ, Mlynarek AM. Chyle leak: a rare complication post-hemithyroidectomy. case report and review of literature. *Otolaryngol Pol* 2014;68:204-7. <https://doi.org/10.1016/j.otpol.2014.03.003>
43. Prabhu S, Thomas S. Octreotide for conservative management of intractable high output post operative chylous fistula: a case report. *J Maxillofac Oral Surg* 2015;14(Suppl 1):21-4. <https://doi.org/10.1007/s12663-011-0269-y>
44. Jain A, Singh SN, Singhal P, Sharma MP, Grover M. A prospective study on the role of octreotide in management of chyle fistula neck. *Laryngoscope* 2015;125:1624-7. <https://doi.org/10.1002/lary.25171>
45. Pan H, Jin P, Cao J, Yang Y. Neck swelling 19 days after thyroidectomy: a case report of a rare chyle leak patient. *Ear Nose Throat J* 2022. <https://doi.org/10.1177/01455613221121495> [Epub ahead of print]
46. Gupta V, Dwivedi G, Chugh R, Sahu PK, Gupta DK, Basu A, et al. Role of octreotide in conservative management of chyle leak post neck dissection in cases of head neck cancer: a retrospective analysis. *Indian J Otolaryngol Head Neck Surg* 2022;74(Suppl 3):6078-86. <https://doi.org/10.1007/s12070-021-02746-y>
47. Delaney SW, Shi H, Shokrani A, Sinha UK. Management of chyle leak after head and neck surgery: review of current treatment strategies. *Int J Otolaryngol* 2017;2017:8362874. <https://doi.org/10.1155/2017/8362874>
48. Dunlap Q, Bridges M, Nelson K, King D, Stack BC Jr, Vural E, et al. Predictors for postoperative chyle leak following neck dissection, a technique-based comparison. *Otolaryngol Head Neck Surg* 2021;165:667-72. <https://doi.org/10.1177/0194599821993815>
49. Shen Y, Feng M, Khan MA, Wang H, Tan L, Wang Q. A simple method minimizes chylothorax after minimally invasive esophagectomy. *J Am Coll Surg* 2014;218:108-12. <https://doi.org/10.1016/j.jamcollsurg.2013.09.014>
50. Cernea CR, Hojaij FC, De Carlucci D Jr, Tavares MR, Araújo-Filho VJ, Silva-Filho GB, et al. Abdominal compression: a new intraoperative maneuver to detect chyle fistulas during left neck dissections that include level IV. *Head Neck* 2012;34:1570-3. <https://doi.org/10.1002/hed.21956>
51. Vokes DE, Linskey ME, Armstrong WB. Propofol lipemia mimicking chyle leak during neck dissection. *Head Neck* 2006;28:1147-9. <https://doi.org/10.1002/hed.20472>
52. Rodgers GK, Johnson JT, Petruzzelli GJ, Warty VS, Wagner RL. Lipid and volume analysis of neck drainage in patients undergoing neck dissection. *Am J Otolaryngol* 1992;13:306-9. [https://doi.org/10.1016/0196-0709\(92\)90053-v](https://doi.org/10.1016/0196-0709(92)90053-v)
53. Xiang D, Liu Z, Yang T, Bai B, Zhang J, Wang C, et al. Finger-pressing: a simple and efficient way to stop chyle leak post neck dissection. *Endocrine* 2020;67:374-8. <https://doi.org/10.1007/s12020-019-02119-0>
54. McCray S, Parrish CR. When chyle leaks: nutrition management options. *Pract Gastroenterol* 2004;28:60-76.
55. Molena E, King E, Davies-Husband C. Octreotide versus oral dietary modification for the treatment of chylous fistula following neck dissection: a systematic review and meta-analysis. *Clin Otolaryngol* 2021;46:474-84. <https://doi.org/10.1111/coa.13700>
56. Smith R, Higginson J, Breik O, Praveen P, Parmar S. Nutritional management of chyle leak after head and neck surgery: a systematic review and proposed protocol for management. *Oral Maxillofac Surg* 2023. <https://doi.org/10.1007/s10006-023-01152-8> [Epub ahead of print]
57. Dorneden A, Olson G, Boyd N. Negative pressure wound therapy (Wound VAC) in the treatment of chylous fistula after neck dissection. *Ann Otol Rhinol Laryngol* 2019;128:569-74. <https://doi.org/10.1177/0003489419827037>
58. Wu G, Chang X, Xia Y, Huang W, Koch WM. Prospective randomized trial of high versus low negative pressure suction in management of chyle fistula after neck dissection for metastatic thyroid carcinoma. *Head Neck* 2012;34:1711-5. <https://doi.org/10.1002/hed.21979>
59. Buettiker V, Hug MI, Burger R, Baenziger O. Somatostatin: a new therapeutic option for the treatment of chylothorax. *Intensive Care Med* 2001;27:1083-6. <https://doi.org/10.1007/s001340100959>
60. Mago S, Bhate K, Santhosh Kumar SN, Kakodkar P, Gajul M, Mastud S. Effect of octreotide in stopping post surgical chyle leak in neck dissection-a systematic review. *J Oral Biol Craniofac Res* 2022;12:737-41. <https://doi.org/10.1016/j.jobcr.2022.08.018>
61. Chan JY, Wong EW, Ng SK, van Hasselt CA, Vlantis AC. Conservative management of postoperative chylous fistula with octreotide and peripheral total parenteral nutrition. *Ear Nose Throat J* 2017;96:264-7. <https://doi.org/10.1177/014556131709600720>
62. Belloso A, Saravanan K, de Carpentier J. The community management of chylous fistula using a pancreatic lipase inhibitor (orlistat). *Laryngoscope* 2006;116:1934-5. <https://doi.org/10.1097/01.mlg.0000236846.45777.39>
63. Ganesan A, Hegde AI, Ghosh TS, Chaudhry K. Venolymphatic malformation of tongue: a prompt life saving intervention. *BMJ Case Rep* 2022;15:e252437. <https://doi.org/10.1136/bcr-2022-252437>
64. Ushinsky A, Guevara CJ, Kim SK. Intranodal lymphangiography with thoracic duct embolization for the treatment of chyle leaks after head and neck cancer surgery. *Head Neck* 2021;43:1823-9. <https://doi.org/10.1002/hed.26646>
65. Ahmed U, Davakis S, Syllaios A, Sdralis E, Lorenzi B, Mastoraki A, et al. Prone position thoracoscopic management of neck chyle leak following major head and neck surgery. A case series. *Ann Ital Chir* 2020;91:265-72.
66. Wilkerson PM, Haque A, Pitkin L, Soon Y. Thoracoscopic ligation of the thoracic duct complex in the treatment for high-volume chyle leak following modified radical neck dissection: safe, feasible, but underutilised. *Clin Otolaryngol* 2014;39:73-4. <https://doi.org/10.1111/coa.12210>
67. Blythe JN, Habib A, Gulati A, Brennan PA. Use of N-butyl-2-cyanoacrylate tissue glue in thoracic duct injury during neck dissection surgery. *Br J Oral Maxillofac Surg* 2011;49:486-7. <https://doi.org/10.1016/j.bjoms.2010.10.012>
68. Chang GH, Lee CY, Tsai YT, Fang CC, Fang KH, Tsai MS, et al. Strategic approach to massive chylous leakage after neck dissection. *Healthcare (Basel)* 2021;9:379. <https://doi.org/10.3390/healthcare9040379>
69. Zhang ML, Guo LM, Li PC, Zhang JK, Guo CX. An effective method to reduce lymphatic drainage post-lateral cervical lymph node dissection of differentiated thyroid cancer: a retrospective analysis. *World J Surg Oncol* 2022;20:294. <https://doi.org/10.1186/s12957-022-02759-z>
70. De Felice F, Musio D, Musella A, Tombolini M, Tombolini V. Chyle leak following neck dissection: could radiotherapy be considered a management option? *J Craniofac Surg* 2016;27:e115-8. <https://doi.org/10.1097/scs.0000000000002329>

**How to cite this article:** Ganesan A, Singh NC, Khatri NP, Madaan CS, Kaur S, Kaur A. Chyle leak after head and neck surgeries: a comprehensive review of diagnosis and management strategies. *J Korean Assoc Oral Maxillofac Surg* 2024;50:3-12. <https://doi.org/10.5125/jkaoms.2024.50.1.3>