

Bowel Perforation Treated with Acupuncture and *Gami-Gamchogungang-tang*: A Case Report

Hyun-sik Seo¹, Jun-yeol Kim¹, Han-eum Ju¹, Young-min Jo¹, Hye-ri Bae², Jung-hyo Cho¹

¹East-West Cancer Center, Daejeon Korean Medicine Hospital of Daejeon University

²Dept. of Hepatology & Hematology, Graduated School of Korean Medicine, Daejeon University

Bowel Perforation Treated with Acupuncture and *Gami-Gamchogungang-tang*: A Case Report

Hyun-sik Seo¹, Jun-yeol Kim¹, Han-eum Ju¹, Young-min Jo¹, Hye-ri Bae², Jung-hyo Cho¹

¹East-West Cancer Center, Daejeon Korean Medicine Hospital of Daejeon University

²Dept. of Hepatology & Hematology, Graduated School of Korean Medicine, Daejeon University

ABSTRACT

Objective: This case report details the successful management of bowel perforation through traditional Korean medicine. Often, emergency surgery is required due to potential complications, such as peritonitis. In this case, the patient had previously undergone a total colectomy, making surgical treatment complicated.

Methods: The patient revealed persistent abdominal pain and over 20 instances of diarrhea per day. During the course of treatment, which included two hospitalizations and one outpatient visit, acupuncture treatment and herbal medicine were administered. Throughout the treatment period, the intensity of abdominal pain and the frequency of diarrhea gradually decreased.

Results: At the end of treatment, a follow-up abdominal computed tomography (CT) scan showed no evidence of perforation. Additionally, blood tests revealed no abnormalities in liver or kidney function, confirming the safety of the treatments.

Key words: acupuncture, herb medicine, perforation, conservative treatment

1. Introduction

Bowel perforation is the formation of a hole in the wall of the gastrointestinal tract¹. Bowel perforation is a disease that requires emergency treatment

because substances in the gastrointestinal tract and intestinal bacteria can penetrate the abdominal cavity and lead to peritonitis². The reason for the perforation in the intestine is that diseases such as colon obstruction, gastrointestinal cancer, gastric ulcer, and inflammatory bowel disease worsen, and it can also occur directly due to trauma such as a colonoscopy or cut by a knife³.

The main symptoms of bowel perforation are abdominal pain and tenderness. In case of perforation in the stomach or small intestine, the patient

· 투고일: 2023.08.30, 심사일: 2023.09.22, 게재확정일: 2023.09.26
· Corresponding author: Jung-hyo Cho East-West Cancer Center,
Daejeon Oriental Hospital of Daejeon University, 75, Daedeok-daero 176 beon-gil,
Seo-gu, Daejeon, Republic of Korea
TEL: +82-42-470-9132 FAX: +82-42-470-9008
E-mail: choajoa@dju.kr

complains of sudden abdominal pain. In addition, when perforation occurs in the large intestine, abdominal pain may appear gradually. Symptoms other than abdominal pain include chills, fever, nausea, and vomiting⁴.

In general, emergency surgery is required for Bowel perforation. Therefore, sepsis can be prevented by suturing the hole using exploratory laparotomy and treating peritonitis by removing foreign substances that have flowed into the abdominal cavity¹.

Therefore, in the treatment of patients with Bowel perforation, the key goal is to prevent complications by fast fusion of the perforations.

In this case, the author reports the improvement of the bowel perforation around ileo-anal anastomosis patient after the treatment with Korean traditional medicine due to the difficulty of surgical treatment caused by total colectomy.

II. Case

For the study of this case, the patient signed consent form and IRB (Institutional Review Board) review exemption (DJDSKH-22-E-21) was approved by Daejeon Korean Medicine Hospital of Dae-Jeon University IRB.

1. Diagnosis and Patient symptoms

In March, 2022, a 42 year old male, visited the D University Korean Medicine Hospital for treating

bowel perforation and received two inpatient treatments and one outpatient treatment for 76 days (Fig. 1). The patient had never been receiving any treatment since being diagnosed with perforation at a General Hospital in February, 2022. The perforation was discovered during regular follow ups for total colectomy which was done because of colon polyposis in 2012. The reason for the perforation was untraceable, and it was discovered around ileo-anal anastomosis and pre-sacral space without transudate.

He heard from the his attending physician that it had difficulty to perform additional operation sealing perforation off since total colectomy had already been performed. As performing a perforation surgery would be difficult, his primary physician suggested administering oral medication and monitoring him. Besides, the patient himself showed reluctance to operation. So, there were no additional alternatives. He was eager to receive Korean medicine treatment with a full understanding of the potential complications, such as peritonitis, and we started treatment.

A since several days before his first admission, he complained of a abdominal pain with a cramping and bloating and diarrhea worsened and was unable to carry out everyday life.

His blood pressure was 126/83 mmHg, pulse 79 times/min, respiratory rate 20 times/min, and body temperature 36.1 °C (Fig. 1).

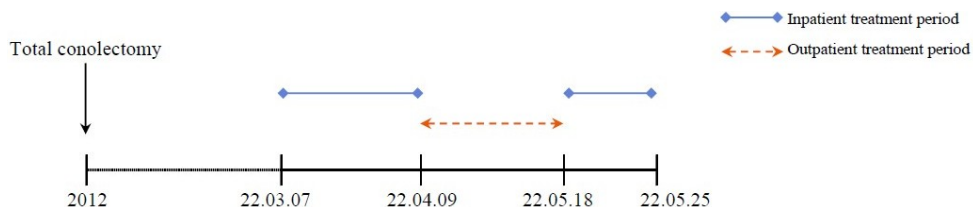


Fig. 1. Treatment periods.

2. Treatment and progress

Manual acupuncture treatment was performed twice a day during inpatient treatment period, and 3-4 times per week during outpatient treatment period based on the Korean medicine theory. Acupuncture treatment was used by stainless steel needles in a thickness of 0.20 mm and a length of 15 mm (Dongbang Medical, Republic of Korea). The acupoints used were: LU07 (列缺, Lieque), KI06 (照海, Zhaohai), ST36 (足三里, Zusanli), LI02 (二間, Erjian), LI03 (三間, Sanjian), LI04 (合谷, Hegu), ST34 (梁丘, Liangqiu). 70 cc of *Gami-Gamchogungang-tang* (*Jiawei-Gancaoganjiang-tang*) was given to drink three times a day after meals. Normally, the patient was allowed to consume a soft diet, but when severe abdominal pain occurred, fasting was initiated, and total parenteral nutrition was carried out. His usual treatment of Ibuprofen Arginine 368.9 mg tid, Loperamide hydrochloride 2 mg tid were given to him until until the 20th day of treatment (Table 1).

The treatment was assessed by comparing degree of abdominal pain, checking the frequency of diarrhea, biochemical tests, abdominal computed tomography (CT) and abdominal X-ray. Numerical rating scale was used as method to objectify symptom severity. Abdominal pain improved from NRS 5 on the first day of treatment to NRS1-2 on the last day of first inpatient treatment period. During outpatient treatment, the intensity of abdominal pain remained unchanged. At first day of second inpatient treatment day, the patient complained of abdominal pain on NRS 7, and it improved with NRS 1 on the last day of treatment. He had diarrhea 20 times per day on the first day

of inpatient treatment, March 7th, 2022. The frequency of diarrhea on March 31st, 2022 was 15 times per day. On May 21st, 2022 at the end of the treatment, the number of diarrhea decreased to 13 times per day (Fig. 2, 3).

Biochemical tests results were mostly normal, but there were abnormality in CRP (C-reactive protein). Results showed a CRP of 1.07 on March 8th, 2022, and 3.2 on May 19th, 2022. At the ends of the each inpatient treatment period, CRP levels were back to normal showed a CRP of 0.08 on March 28th, 2022, 0.45 on May 24 th, 2022 (Table 2).

Abdomen CT showed branching patterned fistulas with inflammatory infiltration around ileo anal anastomosis and pre sacral space on February 16 th, 2022, and no specific findings related to fistulas on May 21st, 2022 (Fig. 4). On abdominal x-ray taken on March 23rd, 2022, multiple air fluid levels in midabdomen were observed, and it was presumed to be a distal small obstruction. But, there were no significant abnormal gas pattern on abdominal x-ray taken on April 8th, 2022 (Fig. 5).

To tests for toxicity and side effects, Aspartate aminotransferase (AST), alanine aminotransferase (ALT), alkaline phosphatase (ALP) and Gamma-glutamyl transferase (GGT), typical liver function biochemical test, remained within normal range. Also, blood urea nitrogen (BUN) and creatinine, representing kidney function biochemical test, were no abnormal during treatments period. In order to assess the possibility of disease exacerbation, vital signs were checked in addition to blood tests, and there were no significant changes in body temperature or blood pressure. And, there were no unusual symptoms that the patient revealed.

Table 1. Prescription of *Gami-Gamchogungang-tang* (Jiawei-Gancaoganjiang-tang)

<i>Gami-Gamchogungang-tang</i> (Jiawei-Gancaoganjiang-tang)	
Herbal name	Dosage (g/day)
Zingiber officinale Roscoe (乾薑)	8
Glycyrrhiza uralensis Fischer (甘草)	4
Cervi Pantotrichum Cornu (鹿茸)	8
Total dosage (g/day)	20

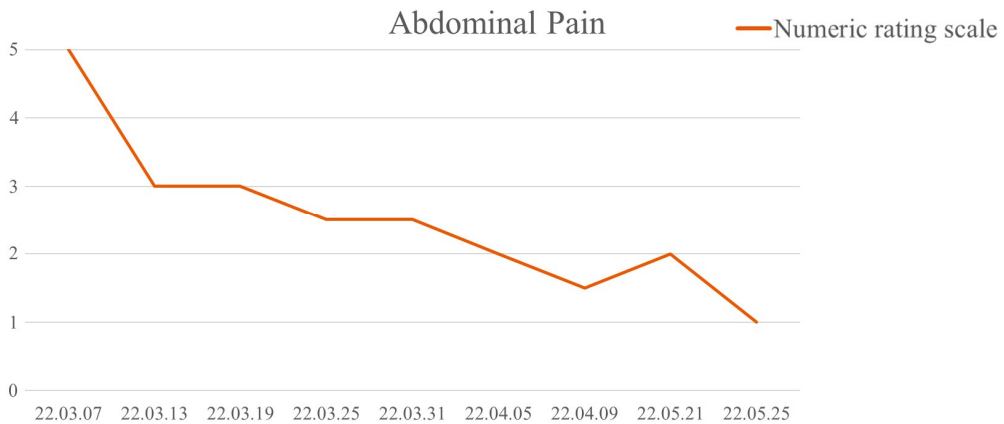


Fig. 2. Changes of numeric rating scale (NRS) on abdominal pain.

NRS of Abdominal pain decreased from 5 to 1.

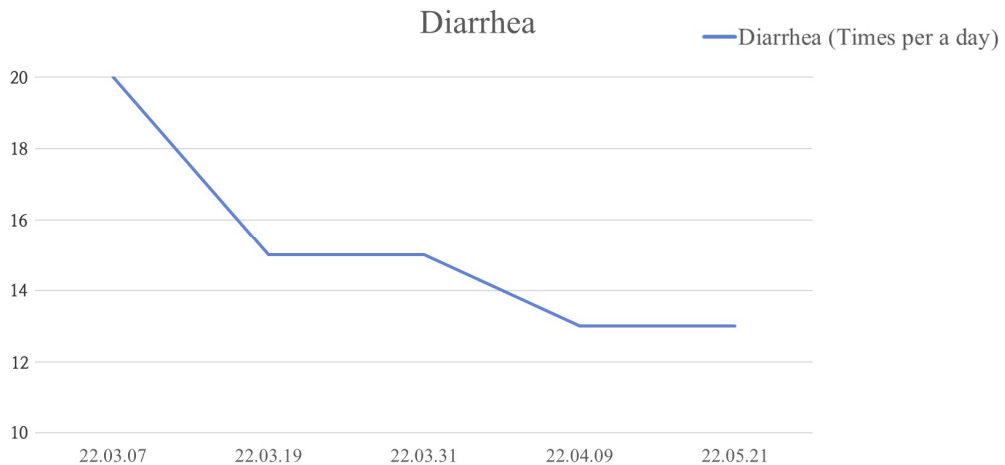


Fig. 3. Changes in the frequency of diarrhea.

The number of diarrhea decreased from 20 times to 13 times per a day.

Table 2. Laboratory Findings

	Normal range	22.03.08	22.03.28	22.05.19	22.05.24
AST (U/l)	0~40	16	12	12	10
ALT (U/l)	0~40	11	8	5	7
ALP (U/l)	40~129	71	104	72	83
GGT (U/l)	0~60	14	14	11	17
BUN (mg/dl)	6~20	15.5	15.4	20.6 ↑	8.6
Creatinine (mg/dl)	0.5~1.2	0.72	0.67	0.8	0.72
CRP (mg/dl)	0~0.5	1.07 ↑	0.08	3.2 ↑	0.45
WBC (10 ³ /μl)	4.5~11	4.7	4.4 ↓	3.5 ↓	4.7

AST : aspartate aminotransferase, ALT : alanine aminotransferase, ALP : alkaline phosphatase, GGT : gamma-glutamyl transferase, BUN : blood urea nitrogen, CRP : c-reactive protein, WBC : white blood cell

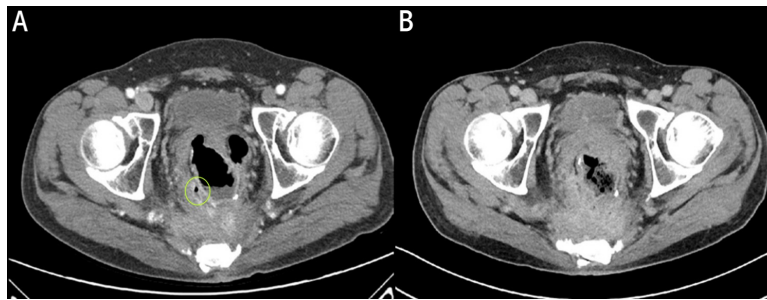


Fig. 4. Comparison of abdominal computed tomography.

A : Air containing, amorphous, branching patterned fistulas with inflammatory infiltration around ileo-anal anastomosis and pre-sacral space suggesting seal off perforation with fistula formation (22.02.16).
 B : No Specific Findings Related with Fistula in the Abdomen Cavity (22.05.21).

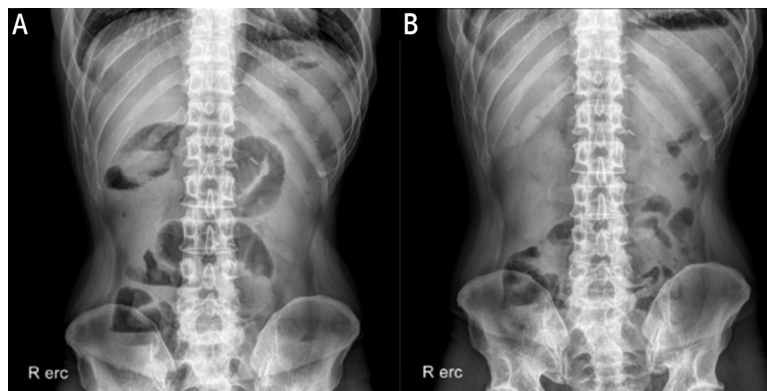


Fig. 5. Comparison of abdominal x-ray (erect).

A : Multiple air fluid levels in midabdomen; distal small bowel obstruction (22.03.23).
 B : No significant abnormal gas pattern, no definite noted ileus sign (22.04.08).

III. Discussion

Statistically, it is reported that acute abdominal pain accounts for about 40% of all emergency surgeries performed in hospitals. Also, most cases correspond to secondary symptoms caused by fistula or Bowel perforation¹. Intestinal perforation is a disease that requires emergency treatment because it can develop into peritonitis due to the penetration of substances in the gastrointestinal tract and intestinal bacteria into the abdominal cavity.

Bowel perforation treatment requires not only emergency surgery but also antibiotics and nutrition. The most important therapy for the treatment of Bowel perforation is by far source control. Source control is usually achieved by surgery. Surgery is performed to control the degree of damage, and the ultimate goal is to remove, clean, and regenerate the damaged intestine^{5,6}. Therefore, source control is direct. It must be made to re-function the functional anatomy through the removal of inflammation, removal of contaminants in the abdominal cavity, and drainage of abscesses⁵. Antibiotics have become a standard treatment technique for treating the perforation of the gastrointestinal tract. Antibiotics are selected according to the site of the perforation⁷. Antimicrobial therapy is commonly used as an adjuvant treatment to prevent secondary peritonitis caused by perforation. Secondary peritonitis causes local inflammation and may cause complications such as bacteremia and sepsis^{5,7}.

In Korean medicine, Bowel perforation belongs to the classification of 腸癰 (a localized pyogenic inflammation of the intestine) and 腹痛 (abdominal pain). We report this case because of the lack of

studies previously reported on oriental medicine alone for the treatment of intestinal perforation. In this case, the patient came to our hospital to treat abdominal pain and perforation that occurred after follow ups for total colectomy for polyps of the colon. In this case, the patient started treatment at the hospital from March, 2022 with bowel perforation confirmed in February, 2022. Korean medicine treatment consisted of acupuncture treatment and herbal medicine treatment.

During the acupuncture treatment for perforation, the acupoints was performed as follows. LU07 (列缺, Lieque), KI06 (照海, Zhaohai). These acupoints were used not only for chest and abdominal pain but also obstetrics and gynecological diseases and digestive system diseases⁸. The combination of these two acupoints is used in common intestinal disorders. In addition, LI02 (二間, Erjian) has the effect of removing inflammation of the large intestine meridian⁹. ST36 (足三里, Zusanli) is the a acupoint of the stomach meridian and has the effect of treating inflammation of the intestine¹⁰. LI04 (合谷, Hegu) is the source of the blood of the large intestine meridian among the twelve meridians, and it is used for digestive system symptoms such as diarrhea and indigestion¹¹.

The patient received *Gami-Gamchogungang-tang* as a basic prescription for Korean medicine treatment. *Gamchogungang-tang*, which has effects for treating external and interal Yin pattern, is recorded in a traditional Chinese medical text Shang Han Lun (On Cold Damage). When using the traditional Chinese medicine diagnostic tool, pulse diagnosis and tongue diagnosis, the pulse was tense and the tongue color was pale-rose, which indicate coldness. When we pressed on the abdomen, there was a feeling of abdominal distension, no rebound tenderness

appeared, and the tender points were not consistent, with the pain moving around. Besides, he generally felt the abdominal pain like squeezing and cramping. Based on symptoms and these diagnostic tools, we diagnosed it as interior cold pattern, and we prescribed *Gami-Gamchogungang-tang* as the treatment for it. Cervi Pantotrichum Cornu, well known Yang-invigorating agent, was added to *Gamchogungang-tang* for the purpose of regaining and resuscitating energy (回陽, huiyang)¹². It has been reported that *Leejung-tang*, derived composition with *Gami-Gamchogungang-tang*, is used to treat abdominal pain, and it has an anti-inflammatory function by affecting the production of cytokine secretion in the macrophages^{13,14}.

During the outpatient treatment period, the treatment for perforation was continued through acupuncture and herbal medicine. In the case of hospitalization, both cases were abdominal pain caused by idiopathy, and abdomen X-ray showed ileus. At the time of hospitalization, in addition to the acupoints adopted at the time of perforation, two acupoints were collected from LI03 (三間, Sanjian) and ST34 (梁丘, Liangqiu) to solve the symptoms of indigestion. LI03 (三間, Sanjian) is a acupoint of the large intestine meridian, which is effective in treating rumbling sound in the stomach and diarrhea⁹. ST34 (梁丘, Liangqiu) is stomach meridian's cleft point and is effective in treating abdominal bloating and diarrhea¹⁵. Herbal medicine treatment was maintained as it was for the treatment of perforation.

Abdominal pain that the patient complained of from the first visit was NRS 5. It was intermittent with a squeezing, primarily manifesting around the umbilical and right lumbar regions among the nine regions of abdominal area. NRS score decreased to

NRS 1-2 on last day of first inpatient treatment period, and there were no complaints of aggravated abdominal pain due to perforation during outpatient treatment from April 9th, 2022 to May 18th, 2022. At this time, there were no additional injections or western medicine prescribed for treating fistula. NRS 1 level was maintained even at the end of treatment. Also, the frequency of diarrhea decreased from 20 to 13 times per day during treatment. The increase in abdominal pain and inflammatory markers during the early stages of the second hospitalization is presumed to be due to the less proactive treatment and inadequate lifestyle management compared to the inpatient period during the outpatient treatment period.

There were no symptoms such as nausea or chills, related to perforation, and there was no persistent fever. In addition, when we periodically conducted physical abdominal examination, no additional instances of rebound tenderness were observed. WBC, which can be confirmed as inflammatory markers, were detected during the treatment period. There was no significant change in the values within the normal range, so there was no possibility of inflammation. On an abdominal CT taken in May 2022, there was no evidence of inflammation, and it was confirmed that the fistula site had disappeared.

In addition, hepatotoxicity and nephrotoxicity due to Korean medicine treatment were not observed in the blood tests performed in this hospital, and side effects such as pruritus and pain caused by acupuncture were also not found.

If the intestinal perforation is left for a long time, it may cause acute abdominal pain or progressive abdominal pain depending on the location of the occurrence. It is also one of the

emergency diseases that require surgery because it can cause complications such as peritonitis. In this case, perforation of the intestine was found during follow-up after total colectomy. With Korean medicine alone, there were no complications or worsening until now, and the patient's symptoms improved without aggravation due to the perforation. In addition, it was found to show improvement in radiology. Since then, there have been no recurrences of the perforation confirmed on the CT scan, and the symptoms related to the perforation have remained improved.

This case corresponds to the treatment report of one patient, and it has limitations in that some digestive symptoms occurred due to the occurrence of ileus during treatment. In addition, it is suggested that further safety assessments, such as imaging studies like CT scans, should have been conducted for intermediate progress monitoring and the detection of complications in addition to blood tests and physical abdominal examination. However, through this case, it can be concluded that oriental herbal treatment alone can prevent complications and effectively treat perforation in patients with intestinal perforation without surgical treatment or antibiotic treatment, and additional case reports and large-scale studies are needed in the future.

References

1. Langel JT, Mulvihill SJ. Gastrointestinal perforation and the acute abdomen. *Medical Clinics of North America* 2008;92(3):599-625.
2. Gupta SK, Gupta R, Singh G, Gupta S. Perforation peritonitis: A two year experience. *Jk Science* 2010;12(3):141-4.
3. Ugwu AU, Kerins N, Malik M. Traumatic small bowel perforation in a case of a perineal hernia. *Journal of Surgical Case Reports* 2018; 2018(12):rjy330.
4. Lyon C, Clark DC. Diagnosis of acute abdominal pain in older patients. *American family physician* 2006;74(9):1537-44.
5. Blot S, De Waele JJ. Critical issues in the clinical management of complicated intra-abdominal infections. *Drugs* 2005;65(12):1611-20.
6. De Graaf JS, Van Goor H, Bleichrodt RP. Primary small bowel anastomosis in generalized peritonitis. *The European Journal of Surgery* 1996;162(1):55-8.
7. Farber MS, Abrams JH. Antibiotics for the acute abdomen. *Surgical Clinics of North America* 1997;77(6):1395-417.
8. Jang JY, Park SY, Hong JA, Jang JI, Kim KS, Kim JH, et al. A Literary Study on Combination of Yeolgeol (LU(7)) and Johae (KI(6)) of Eight Confluent Acupoints. *Korean Journal of Acupuncture* 2006;23(4):27-47.
9. Meridians & Acupoints Compilation Committee of Colleges of Korean Medicine. Details of Meridians & Acupoints[Volume I]; A Guidebook for College Students. 6th ed. Daejeon: JongRyeoNaMu Publishing Co; 2012, p. 56-9, 60-3.
10. Hu S, Du MH, Luo HM, Wang H, Lv Y, Ma L, et al. Electroacupuncture at Zusanli (ST36) prevents intestinal barrier and remote organ dysfunction following gut ischemia through activating the cholinergic anti-inflammatory-dependent mechanism. *Evidence-Based Complementary and Alternative Medicine* 2013;2013:592127.
11. Nam SH, Lee H. Effect of Pre-treatment or Post-treatment of Acupuncture, Low Frequency Electro-acupuncture and High Frequency

- Electro-acupunctre at LI4 on Intestinal Motility in Rats. *Journal of Acupuncture Research* 2008; 25(4):19-29.
12. Huang CC, Chen YM, Kan NW, Chao HL, Ho CS, Hsu MC. Cornu cervi pantotrichum supplementation improves exercise performance and protects against physical fatigue in mice. *Molecules* 2014;19(4):4669-80.
 13. Lee JY, Kim YJ, Park WS. Effects of White Ginseng-Ejung-tand Acupuncture Solution on Nitric Oxide and Hydrogen peroxide Production in LPS-induced Mouse Macrophages. *Korean Journal of Acupuncture* 2011;28(1):61-9.
 14. Park WS. Effects of red ginseng-ejung-tang and white ginseng-ejung-tang water extract on hydrogen peroxide production in RAW 264.7 cells. *Journal of Physiology & Pathology in Korean Medicine* 2011;25(1):78-83.
 15. Li YQ, Zhu B, Rong PJ, Li YH. Effective regularity in modulation on gastric motility induced by different acupoint stimulation. *World Journal of Gastroenterology* 2006;12(47):7642-8.