



Case Report

Stent-assisted coiling of a ruptured basilar artery perforator aneurysm: A case report

Jongwon Cho¹, Sang Hyun Suh², Joonho Chung¹

¹Department of Neurosurgery, Gangnam Severance Hospital, Yonsei University College of Medicine, Seoul, Korea

²Department of Radiology, Gangnam Severance Hospital, Yonsei University College of Medicine, Seoul, Korea

J Cerebrovasc Endovasc Neurosurg.
2023 March;25(1):81-86

Received: 25 March 2022

Revised: 22 May 2022

Accepted: 7 June 2022

Correspondence to

Joonho Chung

Department of Neurosurgery, Gangnam Severance Hospital, Yonsei University College of Medicine, 50-1, Yonsei-ro, Seodaemun-gu, Seoul 03722, Korea

Tel +82-2-2019-3390

Fax +82-2-3461-9229

E-mail ns.joonho.chung@gmail.com

ORCID <https://orcid.org/0000-0003-2745-446X>

Basilar artery (BA) perforator aneurysms are exceedingly rare causes of subarachnoid hemorrhage. Therefore, the natural history and optimal treatment have not been established, and surgical, endovascular, and conservative management have been used. However, there is no consensus on the optimal treatment strategy. Herein, we report the case of a 52-year-old man presenting with a ruptured BA perforator aneurysm. First, we deployed an Enterprise stent from the left P1 segment to the BA because the microcatheter could not enter the aneurysm. Then, we deployed a helical coil on the orifice of the BA perforator. Finally, we deployed another Enterprise stent, sandwiching the helical coil between the two Enterprise stents. The aneurysm was completely obliterated without recurrence on the follow-up angiography. Our technique of sandwiching the small helical coil between two Enterprise stents might help other surgeons by offering another feasible treatment option for ruptured BA perforator aneurysms.

Keywords Basilar artery aneurysm, Endovascular procedure, Stent, Subarachnoid hemorrhage

INTRODUCTION

Basilar artery (BA) perforator aneurysms, first described by Ghogawala et al.,¹²⁾ are an infrequent cause of subarachnoid hemorrhage (SAH). Therefore, the natural history and optimal treatment have not been established, nor do they have clear definitions. Satti et al.¹⁷⁾ classified BA perforator aneurysms into three types based on their anatomical location to standardize angiographic image descriptions. However, differential treatment strategies using these classifications have not been established. Furthermore, surgical, endovascular, and conservative management have been used, but there remains no consensus on the optimal treatment strategy.²⁾ Herein, we describe a case of SAH due to a ruptured BA perforator aneurysm and treated with stent-assisted coil embolization.

This is an Open Access article distributed under the terms of the Creative Commons Attribution Non-Commercial License (<http://creativecommons.org/licenses/by-nc/4.0/>) which permits unrestricted non-commercial use, distribution, and reproduction in any medium, provided the original work is properly cited.

CASE DESCRIPTION

A 52-year-old man with a history of dyslipidemia presented with sudden onset of severe headache and vomiting. On examination, the patient was drowsy and had right hemiparesis with a Hunt–Hess grade of 3. Urgent brain computed tomography (CT) revealed an SAH within the basal, interpeduncular, and perimesencephalic cisterns (Fig. 1A). Initial CT angiography and transfemoral cerebral angiography (TFCA) failed to reveal the SAH

source. However, the three-day follow-up TFCA identified an aneurysm arising from a small perforating branch of the BA with delayed contrast filling (Fig. 1B, C).

We attempted endovascular treatment with administering two antiplatelet agents (aspirin and clopidogrel), each with a 300 mg loading dose. Under general anesthesia, through the right femoral artery, we introduced a 6-Fr guiding catheter into the left vertebral artery. Then, we used an Excelsior SL-10 microcatheter (Stryker Neurovascular, Kalamazoo, MI, USA) to navigate into

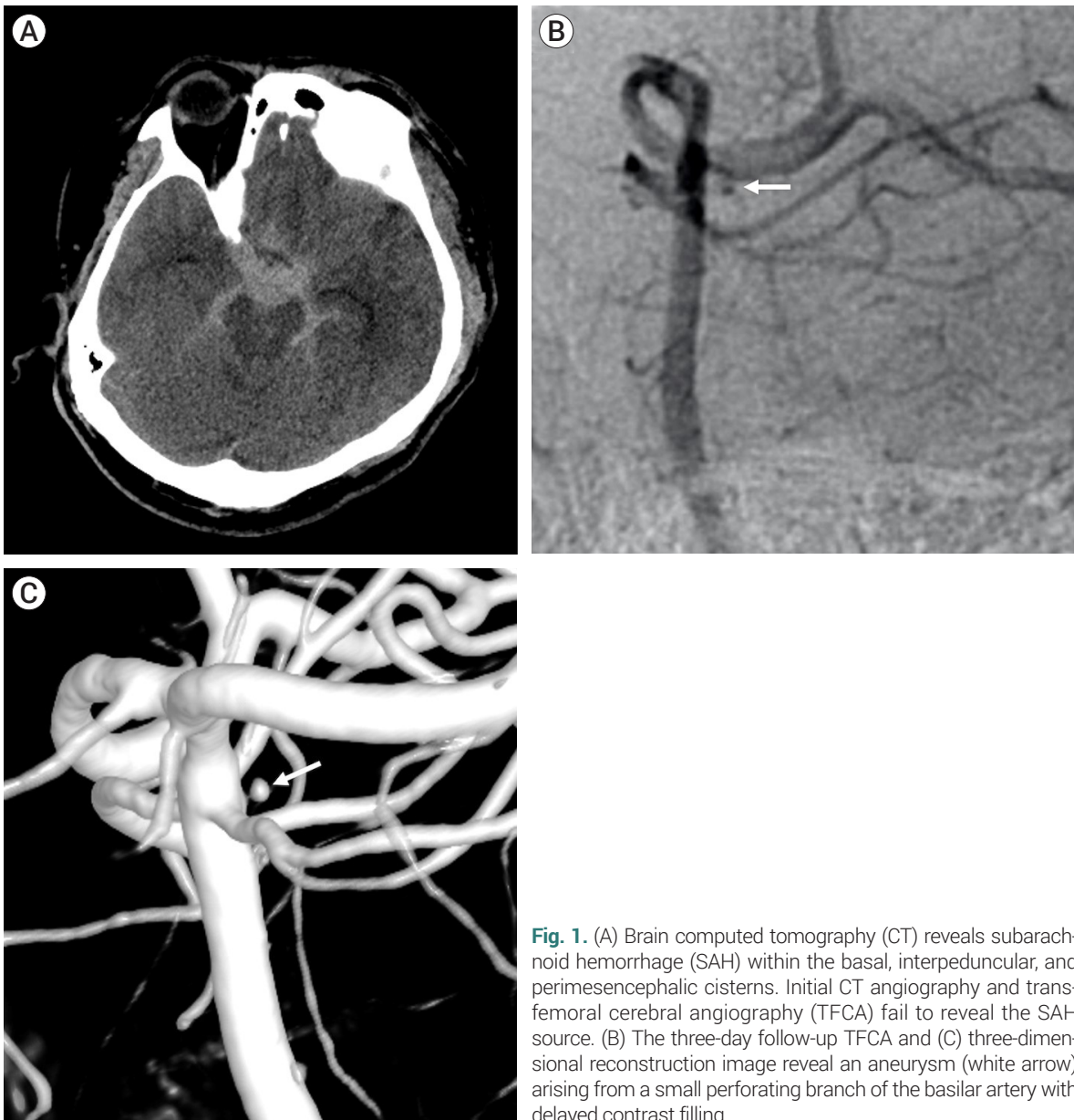


Fig. 1. (A) Brain computed tomography (CT) reveals subarachnoid hemorrhage (SAH) within the basal, interpeduncular, and perimesencephalic cisterns. Initial CT angiography and transfemoral cerebral angiography (TFCA) fail to reveal the SAH source. (B) The three-day follow-up TFCA and (C) three-dimensional reconstruction image reveal an aneurysm (white arrow) arising from a small perforating branch of the basilar artery with delayed contrast filling.

the aneurysm sac, but it failed. Since the microcatheter could not enter the aneurysm, a closed-cell stent (Enterprise; Codman Neurovascular, Miami Lakes, FL, USA) was deployed from the left P1 segment to the BA. Subsequently, we placed a helical coil (Target Helical UltraSoft; Stryker Neurovascular, Fremont, CA, USA) on the orifice of the BA perforating branch where the ruptured aneurysm had arisen. Then, we deployed another Enterprise stent, sandwiching the helical coil between the two Enterprise stents (Fig. 2A, B). The aneurysm disappeared.

Three days after treatment, the patient developed left third cranial nerve palsy, dysarthria, and right-sided hemiparesis. Magnetic resonance diffusion-weighted imaging revealed a recent perforator infarction in the left lower midbrain with multifocal high-signal lesions in the cerebellum (Fig. 2C). Three weeks later, the third cranial nerve palsy completely resolved, and the patient was discharged to home with a modified Rankin Scale score of 2 owing to minimal right hemiparesis. Furthermore, the patient was prescribed 75 mg of clopidogrel and 100 mg of aspirin daily for 3 and 24 months, respectively. Follow-up TFCA were performed 2 weeks, 3 months, and 12 months after treatment. The aneurysm was completely obliterated without recurrence (Fig. 2D, E).

DISCUSSION

In this case, the initial CT angiogram and TFCA did not detect aneurysms inducing SAH. Diagnosing a BA perforator aneurysm is not easy at first, as seen in other published literature.¹⁵⁾ The initial diagnosis failure is likely owing to the small size of the aneurysm and blood flow degradation inside the aneurysm sac with temporary vasospasm and thrombus.¹⁾ These factors demonstrate the importance of timing and high-resolution imaging and emphasize the need for repeated angiography, even if the first try fails to find the SAH cause. We recommend at least a 72-h interval and a repeat angiography within seven days.²⁾

There are various treatment approaches for BA perforator aneurysms, including obliteration with a small

vascular clip,¹²⁾ endovascular coiling,⁷⁾ endovascular reconstruction with a stent,¹⁰⁾¹⁷⁾ Onyx embolization,⁸⁾ and flow diversion.⁵⁾¹⁶⁾ However, the ideal method has not been established owing to the small number of cases. Conservative treatment is another option, and several previous reports have described a high rate of spontaneous resolution without aggressive treatment.²⁾¹³⁾¹⁸⁾ Given the potential risks of surgery and endovascular therapy, conservative management is a viable option for small ruptured BA perforator aneurysms with precise imaging tracking.¹³⁾¹⁶⁾ However, the cerebral aneurysm rebleeding rate is between 11% and 15% when conservatively managed.⁶⁾⁹⁾ Therefore, it seems reasonable to consider neurosurgery or intravascular treatment options. Furthermore, the size of the aneurysm positively correlates with rupture risk, making active treatment preferable over conservative treatment for larger BA perforator aneurysms.

Surgical treatment of directly clipping BA perforators is challenging for all neurosurgeons because of its deep location and surrounding critical structures. During subpial dissection, subarachnoid hematoma makes it difficult to confirm the exact anatomical structures around the lesion, and it is challenging to access the lesion without damaging important vessels or cranial nerves around the BA.⁴⁾ Even after approaching the lesion, standard clip ligation is not suitable because there is often no true neck, and it is not easy to preserve the parent perforating vessels. Endovascular treatment includes coil embolization, stenting, Onyx embolization, and flow diversion. Among actively treated patients, coil embolization is the most commonly used option. However, it often fails because the BA perforating branch cannot be catheterized.¹¹⁾¹⁷⁾ Superselective coil embolization of the aneurysm is ideal. However, this is rarely possible owing to several practical problems. It requires the catheter to enter a small perforating artery branched at a perpendicular angle from the basilar trunk. Moreover, maintaining stability after safely deploying the coil into very small cerebral aneurysms is challenging.³⁾ The brainstem infarction risk is high when BA perforating branches are sacrificed.¹⁸⁾

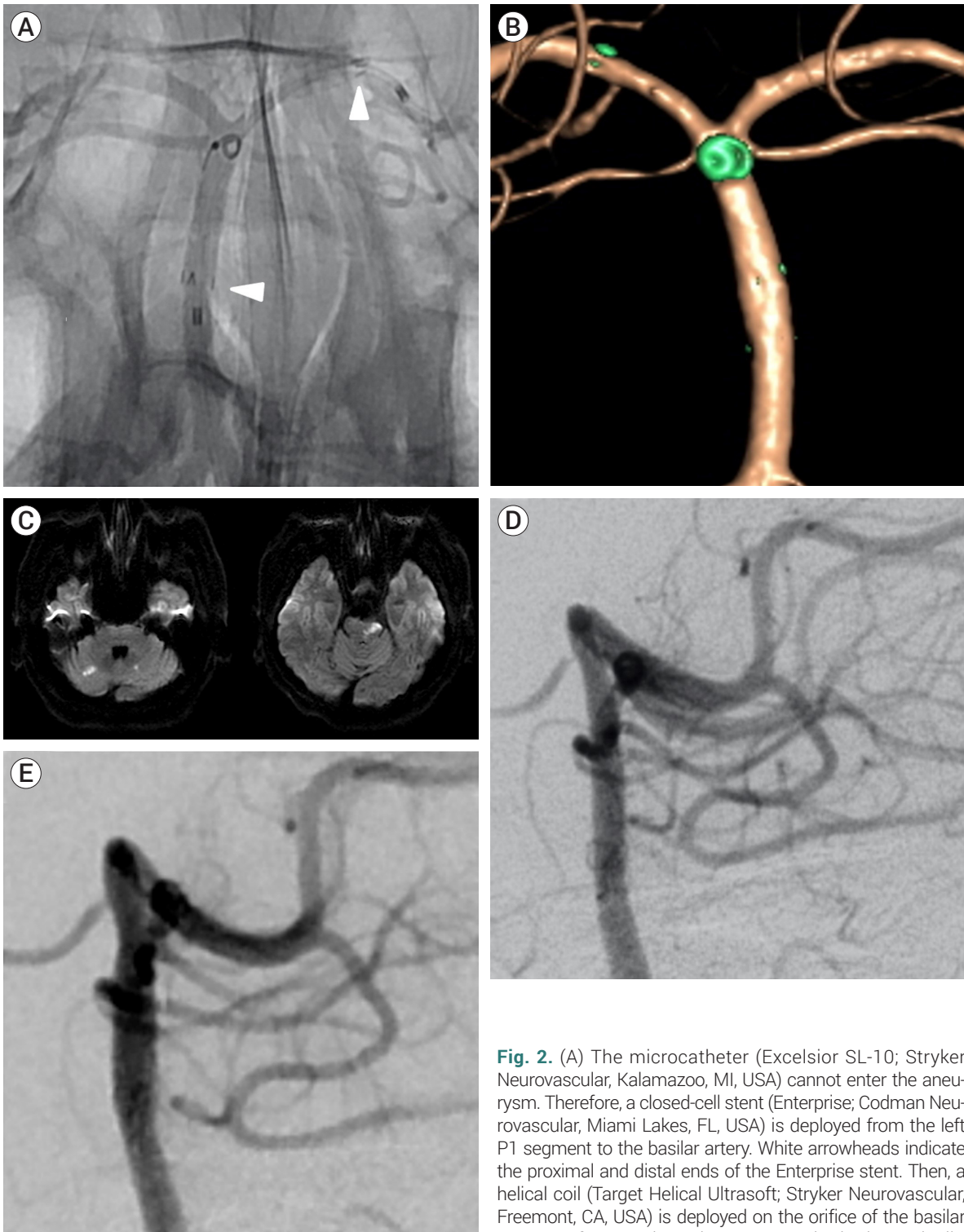


Fig. 2. (A) The microcatheter (Excelsior SL-10; Stryker Neurovascular, Kalamazoo, MI, USA) cannot enter the aneurysm. Therefore, a closed-cell stent (Enterprise; Codman Neurovascular, Miami Lakes, FL, USA) is deployed from the left P1 segment to the basilar artery. White arrowheads indicate the proximal and distal ends of the Enterprise stent. Then, a helical coil (Target Helical Ultrasoft; Stryker Neurovascular, Fremont, CA, USA) is deployed on the orifice of the basilar artery perforator where the aneurysm had arisen. Finally, another Enterprise stent is deployed, sandwiching the helical coil between the two Enterprise stents. (B) The posterior view of a three-dimensional reconstruction image reveals that the coil was placed on the orifice of the perforator, and the aneurysm disappeared. (C) Three days after the treatment, magnetic resonance diffusion-weighted imaging reveals a recent perforator infarction on the left lower midbrain with multifocal high signal lesions in the cerebellum. (D) Follow-up transfemoral cerebral angiography 3 and (E) 12 months after surgery reveal complete obliteration of the aneurysm without recurrence.

Because of this difficulty, some surgeons have promoted aneurysm obliteration by overlapping multiple stents to obtain a flow diversion effect rather than coiling directly into the aneurysm. The stent-in-stent technique aims to cover the BA vessel wall and reduce blood flow into the perforator artery. This action causes thrombosis in the aneurysm while maintaining the patency of the perforator artery. Chalouhi et al. reported the first successful use of the flow diverter technique to treat a ruptured basilar trunk perforator aneurysm.⁵⁾ The flow diverter technique has been demonstrated to be significantly safer and more effective for treating aneurysms with a low risk of symptomatic brainstem infarction and rebleeding compared to the stent-in-stent technique.²⁾¹³⁾

Unlike directly filling the aneurysm sac with coils, the use of the stent-in-stent and flow diverter techniques induces blood clots to occlude the aneurysm. There is also a possibility of rebleeding or increasing the size of the aneurysm before it is obliterated. Thus, treating aneurysms with coils from the beginning might be ideal but is not easy because of several technical challenges. Therefore, our technique of sandwiching the small coil between two Enterprise stents may help other surgeons by offering another feasible treatment option for ruptured BA perforator aneurysms. This technique of sandwiching coil between stents was previously introduced in the treatment for intractable a blood-blister aneurysm. Overlapping stents with a coil sandwich, a stenting-coiling-stenting was placed using a semi-jailing technique, and this technique aimed to reduce porosity by sandwiching the coil near the aneurysm neck.¹⁴⁾

CONCLUSIONS

All the available treatment options for ruptured BA perforator aneurysm have challenges. We present a case of variation on the coiling technique in which a small helical coil is sandwiched between two stents. This may be another feasible treatment option for ruptured BA perforator aneurysms.

Disclosure

The authors report no conflict of interest concerning the materials or methods used in this study or the findings specified in this paper.

REFERENCES

1. Apok V, Tarnaris A, Brydon HL. An unusual aneurysm of a basilar perforating artery presenting with a subarachnoid haemorrhage. *Br J Neurosurg*. 2013 Feb;27(1):105-7.
2. Bhogal P, AlMatter M, Hellstern V, Perez MA, Lehmborg J, Ganslandt O, et al. Basilar artery perforator aneurysms: report of 9 cases and review of the literature. *J Clin Neurosci*. 2019 May;63:122-9.
3. Brinjikji W, Lanzino G, Cloft HJ, Rabinstein A, Kallmes DF. Endovascular treatment of very small (3 mm or smaller) intracranial aneurysms: report of a consecutive series and a meta-analysis. *Stroke*. 2010 Jan;41(1):116-21.
4. Caruso G, Vincentelli F, Giudicelli G, Grisoli F, Xu T, Gouaze A. Perforating branches of the basilar bifurcation. *J Neurosurg*. 1990 Aug;73(2):259-65.
5. Chalouhi N, Jabbour P, Starke RM, Zanaty M, Tjoumakaris S, Rosenwasser RH, et al. Treatment of a basilar trunk perforator aneurysm with the pipeline embolization device: case report. *Neurosurgery*. 2014 Jun;74(6):E697-701; discussion 701.
6. Chau Y, Sachet M, Sedat J. Should we treat aneurysms in perforator arteries from the basilar trunk? Review of 49 cases published in the literature and presentation of three personal cases. *Interv Neuroradiol*. 2018 Feb;24(1):22-8.
7. Chen L, Chen E, Chotai S, Tian X. An endovascular approach to ruptured aneurysms of the circumferential branch of the basilar artery. *J Clin Neurosci*. 2012 Apr;19(4):527-31.
8. Ding D, Starke RM, Jensen ME, Evans AJ, Kassell NF, Liu KC. Perforator aneurysms of the posterior circulation: case series and review of the literature. *J Neurointerv Surg*. 2013 Nov;5(6):546-51.
9. Finitis S, Derelle AL, Tonnelet R, Anxionnat R, Bracard S. Basilar perforator aneurysms: presentation of 4 cases and review of the literature. *World Neurosurg*. 2017 Jan;97:366-73.
10. Fiorella D, Albuquerque FC, Deshmukh VR, Woo HH, Rasmussen PA, Masaryk TJ, et al. Endovascular reconstruction with the Neuroform stent as monotherapy for the treatment of uncoilable intradural pseudoaneurysms. *Neurosurgery*. 2006 Aug;59(2):291-300; discussion 291-300.

11. Forbrig R, Eckert B, Ertl L, Patzig M, Brem C, Vollmar C, et al. Ruptured basilar artery perforator aneurysms--treatment regimen and long-term follow-up in eight cases. *Neuroradiology*. 2016 Mar;58(3):285-91.
12. Ghogawala Z, Shumacher JM, Ogilvy CS. Distal basilar perforator artery aneurysm: case report. *Neurosurgery*. 1996 Aug;39(2):393-6.
13. Granja MF, Monteiro A, Agnoletto GJ, Jamal S, Sauvageau E, Aghaebrahim A, et al. A systematic review of non-trunk basilar perforator aneurysms: is it worth chasing the small fish? *J Neurointerv Surg*. 2020 Apr;12(4):412-6.
14. Maeoka R, Nakagawa I, Ohnishi H, Nakase H. Overlapping stents with coil sandwich for ruptured blood-blister aneurysm in a patient with ipsilateral persistent primitive trigeminal artery: a case report and review of literature. *Asian J Neurosurg*. 2019 Nov;14(4):1236-9.
15. Mathieson CS, Barlow P, Jenkins S, Hanzely Z. An unusual case of spontaneous subarachnoid haemorrhage - a ruptured aneurysm of a basilar perforator artery. *Br J Neurosurg*. 2010 Jun;24(3):291-3.
16. Peschillo S, Caporlingua A, Cannizzaro D, Resta M, Burdi N, Valvassori L, et al. Flow diverter stent treatment for ruptured basilar trunk perforator aneurysms. *J Neurointerv Surg*. 2016 Feb;8(2):190-6.
17. Satti SR, Vance AZ, Fowler D, Farmah AV, Sivapatham T. Basilar artery perforator aneurysms (BAPAs): review of the literature and classification. *J Neurointerv Surg*. 2017 Jul; 9(7):669-73.
18. Shlobin NA, Cantrell DR, Ansari SA, Hurley MC, Shaibani A, Jahromi BS, et al. Conservative management and natural history of ruptured basilar perforator artery aneurysms: two cases and literature review. *World Neurosurg*. 2020 Jun;138:218-22.