

Original Article



The Utility of Contrast Enhanced Ultrasound and Elastography in the Early Detection of Fibro-Stenotic Ileal Strictures in Children with Crohn's Disease

OPEN ACCESS

Received: Nov 12, 2022
Revised: May 25, 2023
Accepted: Jun 13, 2023
Published online: Jul 5, 2023

Correspondence to

Carmen Cuffari





Division of Pediatric Gastroenterology and Nutrition, Children's National Hospital, 111 Michigan Ave. NW, Washington DC 20010, USA.

Email: ccuffari2@cnmc.org

Copyright © 2023 by The Korean Society of Pediatric Gastroenterology, Hepatology and Nutrition

This is an open-access article distributed under the terms of the Creative Commons Attribution Non-Commercial License (<https://creativecommons.org/licenses/by-nc/4.0/>) which permits unrestricted non-commercial use, distribution, and reproduction in any medium, provided the original work is properly cited.

ORCID iDs

Sarah D. Sidhu 
<https://orcid.org/0000-0003-1432-8800>
Shelly Joseph 
<https://orcid.org/0000-0002-5459-2043>
Emily Dunn 
<https://orcid.org/0000-0002-6527-9896>
Carmen Cuffari 
<https://orcid.org/0000-0003-2810-2319>

Funding

Johns Hopkins Institutional Training Grant for Pediatricians, funded by NICHD.

Conflict of Interest

The authors have no financial conflicts of interest.

Sarah D. Sidhu ¹, **Shelly Joseph** ², **Emily Dunn** ³ and **Carmen Cuffari** ⁴

¹Pediatric Gastroenterology, Hepatology and Nutrition of Florida, Tampa General Hospital, Temple Terrace, FL, USA

²Division of Pediatric Gastroenterology, Hepatology, and Nutrition, The Johns Hopkins School of Medicine, Baltimore, MD, USA

³Department of Pediatric Radiology, The Johns Hopkins Hospital, Baltimore, MD, USA

⁴Division of Pediatric Gastroenterology and Nutrition, Children's National Hospital, Washington DC, USA

ABSTRACT

Purpose: Crohn's disease (CD) is a chronic, idiopathic bowel disorder that can progress to partial or complete bowel obstruction. At present, there are no reliable diagnostic tests that can readily distinguish between acute inflammatory, purely fibrotic and mixed inflammatory and fibrotic. Our aim is to study the utility of contrast enhanced ultrasound (CEUS) in combination with shear wave elastography (SWE) to differentiate fibrotic from inflammatory strictures in children with obstructive CD of the terminal ileum.

Methods: Twenty-five (19 male) children between 2016-2021 with CD of the terminal ileum were recruited into the study. Among these patients, 22 had CEUS kinetic measurements of tissue perfusion, including wash-in slope (dB/sec), peak intensity (dB), time to peak intensity (sec), area under the curve (AUC) (dB sec), and SWE. In total, 11 patients required surgery due to bowel obstruction. Histopathologic analysis was performed by a pathologist who was blinded to the CEUS and SWE test results.

Results: Patients that underwent surgical resection had significantly higher mean area under the curve on CEUS compared to patients responsive to medical therapy ($p=0.03$). The AUC also correlated with the degree of hypertrophy and the percent fibrosis of the muscularis propria, as determined by histopathologic grading ($p<0.01$). There was no difference in the mean elastography measurements between these two patient groups.

Conclusion: CEUS is a useful radiological technique that can help identify pediatric patients with medically refractory obstructive fibrotic strictures of the terminal ileum that should be considered for early surgical resection.

Keywords: Ultrasonography; Inflammatory bowel disease; Fibrostenotic; Pediatrics

INTRODUCTION

Crohn's disease (CD) is a chronic, and often relapsing inflammatory bowel disease (IBD) that can affect any portion of the gastrointestinal tract [1]. In pediatrics, CD is estimated to be diagnosed in up to 8.5 per 100,000 children living in North America most frequently affecting the terminal ileum and proximal colon [2]. Children and adolescents with CD may present with either abdominal pain, weight loss and loose stools or with less specific symptoms, including fatigue, decreased oral intake, and growth failure [3]. Medical management is aimed at early diagnosis and aggressive medical therapy to enable mucosal healing and to maintain adequate growth and development [4]. If left untreated, acute inflammation will progress to chronic inflammation with the excessive deposition of collagen and fibronectin within the bowel wall. This attempt by the body to repair the injured tissue results in fibrotic stricture formation, reactive muscular hypertrophy of the muscularis and either partial or complete intestinal obstruction. Failure to identify and surgically treat these fibrotic strictures can lead to intestinal fistulae, intra-abdominal abscess formation, and bowel perforation. While biological therapy has proven efficacy in healing tissue inflammation, fibrotic intestinal strictures can only be managed surgically [5].

Contrast-Enhanced Ultrasound (CEUS) is an imaging modality that utilizes an intravenous microbubble-based contrast agent to amplify the diagnostic scope of ultrasound; and by adding this image enhancement technique, it can also provide a pharmacokinetic measurements of tissue perfusion. CEUS has been utilized throughout Europe with the use of SonoVue® (Bracco Diagnostics Inc.) contrast. In 2016, the United States Food and Drug Administration approved the use of Lumason® (Bracco Diagnostics Inc.) contrast for the CEUS of adult and pediatric liver and bladder under specific dosing and application guidelines that have been previously described [6,7]. Although there have been few reports of severe anaphylactic reactions to Lumason® (Bracco Diagnostics Inc.), most adverse side-effects are described as mild and transient [8-10]. The scope of use for pediatric CEUS continues to expand, as more studies have demonstrated its utility in identifying and monitoring liver lesions, in the diagnosis of blunt abdominal trauma, the monitoring of solid organ transplant grafts, and in the diagnosis of IBD [11,12]. Studies in adult patients with CD have shown that CEUS can be a useful diagnostic tool in delineating inflammatory from fibro-stenotic strictures [13-15]. The application of CEUS in children has been limited to either individual case reports or small case series [16,17].

The primary aim of this prospective study was to investigate the role of CEUS in identifying fibrotic strictures of the terminal ileum in children and adolescents with CD. The study also aims to correlate CEUS kinetics and shear wave elastography (SWE) with histopathologic fibrosis and hypertrophy of the muscular propria in those patients that required surgical resection. We hypothesized that there would be a significant difference in the CEUS kinetic values between inflammatory and fibrotic terminal ileum strictures. Presumably, the inflammatory lesions would show increased CEUS kinetic values due to presumed greater tissue perfusion in the setting of ongoing inflammation, as shown in a previous adult study [15].

MATERIALS AND METHODS

Patients

The study was approved by the Institutional Review Board at The Johns Hopkins University (No. 2016-287). In total, 25 patients with CD that were followed in the Division of Pediatric Gastroenterology IBD Center provided written and informed consent to participate in the study between 2016-2021. The inclusion criteria included: age <22 years, histopathologic diagnosis of CD, and stricturing disease of the terminal ileum diagnosed either at the time of colonoscopy or by Magnetic Resonance enterography (MRE). Among these 25 patients with presumed stricturing disease, 22 (16 males) underwent CEUS with kinetic evaluation of tissue perfusion of the terminal ileum; 10 had isolated distal ileal and 12 ileocolitis diagnosed by colonoscopy and tissue biopsy. Five patients with isolated ileitis had significant narrowing of the terminal ileum with proximal dilation of the distal ileum noted by MRE. Among the 12 patients with ileocolitis diagnosed by both colonoscopy and tissue biopsy, 6 showed proximal dilation of the distal by MRE. In all these patients with MRE criteria for partial distal small bowel obstruction, intubation of the terminal ileum was precluded by narrowing of the ileocecal valve at the time of colonoscopy.

Eleven patients were referred for surgical resection due to clinical symptoms of severe and medically refractory bowel obstruction. A pathologist blinded to the clinical, radiologic, and surgical history performed a validated histopathologic assessment on the resected ileal strictures.

Imaging

After traditional gray-scale ultrasound was performed on the targeted tissue, Lumason[®] was administered intravenously to enhance visualization of the targeted tissue and to allow for the precise determination of blood flow. The microbubbles have a lower acoustic impedance than non-aqueous tissues, creating an ultrasound reflection that provides a visual contrast between blood and the surrounding tissue. In comparison, SWE uses acoustic radiation force to excite a region of interest, and by measuring the speed that which the shear waves travel away from the affected area it provides an indirect measure of tissue elasticity. Fibrotic lesion would be considered to have high elasticity.

CEUS kinetic measurements of the targeted region of interest (ROI) included

Wash-in slope (dB/sec), peak intensity (dB), time to peak intensity (sec), and area under the curve (dB sec) reflecting the dynamic pattern of blood flow at the ROI [15-19]. At our institution, CEUS was performed by experienced radiologists. Per protocol, 0.3 mL/kg of Lumason[®] contrast was injected intravenously and the area of interest at the terminal ileum was identified using Phillips EPIQ ultrasound equipment (Philips Healthcare Ultrasound, Bothell WA) [19]. Study personnel, consisting of pediatric radiologists and gastroenterologists obtained kinetic measurements following completion of the study using Phillips Q-App software installed on the ultrasound equipment. The measurement was performed at an approximate 25 mm ROI, determined subjectively by the radiologist to be the area of greatest bowel wall thickening and enhancement.

Pathology

Eleven of the enrolled patients ultimately required surgical resection due to persistent obstructive symptoms despite optimized medical therapy. Following surgical resection, a single pathologist blinded to the clinical history, radiologic and surgical findings performed histopathologic evaluation. Among these 11 patients, the degree of fibrosis and inflammation was graded in 9,

in addition to standard histopathologic analysis. Two specimens were unavailable for fibrosis scoring. A previously validated histopathologic scoring system was applied at the narrowest portion of the resected ileum, reflecting the most severely affected region. The scoring involves grading of acute inflammation (0–3+), chronic inflammation (0–3+), fibrosis in submucosa and muscularis propria (in semi-quantitative increments of 10%), and the ratio of the thickness of the muscularis mucosa and the muscularis propria at the strictured area to that in the non-diseased portion at the clean surgical margins [20]. The CEUS kinetics of the terminal ileum were then correlated with histopathologic grading of the resected tissue.

Statistical analysis

We compared the CEUS kinetics of those patients who improved with medical management to those who required surgical management of their strictures using a paired sample *t*-test. For the patients who required surgical resection, we also compared the histopathologic scores from the resected ileal strictures to the CEUS kinetics using paired sample *t*-test and Pearson correlation coefficient. A *p*-value of ≤ 0.05 was considered statistically significant.

RESULTS

Twenty-five patients underwent CEUS and SWE with no reported side-effects. Kinetic measurements were not able to be obtained in 3 of the patients studied, and as such, 22 patients with a median (range) Pediatric Crohn's Disease Activity Index (PCDAI) of 45 (30–60) at diagnosis were included in the statistical analysis. The mean age (standard deviation) of the surgically and medically managed patients was 15.2 (3.2) and 15.9 (2.6) years, respectively. Among the 11 patients medically responsive to induction followed maintenance infliximab therapy, CEUS was performed after a median (range) of 16 (8–26) weeks from the time of diagnosis. In this group, the median (range) PCDAI at the time of the CEUS was 15 (10–25). In comparison, among the 11 patients with medically refractory disease that ultimately required surgical resection, the CEUS was performed after a median (range) of 4 (2–12) weeks from the time of diagnosis. In these patients, the median (range) PCDAI at the time the CEUS was performed was 55 (20–60).

Based on each patient's clinical history and exam, medical therapy was maximized whenever possible, including escalation to biologic therapy, as clinically indicated. All patients were closely monitored by their primary pediatric gastroenterologist to determine if clinical improvement occurred with the change in medical therapy. Those patients who demonstrated obstructive symptoms (inability to tolerate PO, severe abdominal pain, or worsening proximal bowel dilation on abdominal imaging) despite presumed optimized medical therapy were referred for surgical intervention at the discretion of their primary gastroenterologist.

Patients who required ileocectomy were found to have significantly elevated mean area under the curve (medical 311.5 dB sec, surgical 762.6 dB sec, $p=0.03$) on CEUS when compared to those patients whose ileal disease responsive to medical therapy (**Table 1**). There was no significant difference found between the time to peak intensity, mean wash-in-slope, peak intensity, or elastography between the two groups.

Histopathologic fibrosis scoring of resected ileocecal specimens are detailed in **Table 2**. Among the 9 resected surgical specimens that underwent fibrosis scoring, all had either high

Table 1. Mean CEUS kinetic values for patients treated medically and surgically

| Kinetic parameter | Medical (n=11) | Surgical (n=11) | p-value |
|------------------------------------|----------------|-----------------|---------|
| Mean wash-in-slope (dB/sec) | 3.2 | 2.3 | 0.72 |
| Mean time to peak intensity (sec) | 28.1 | 35.2 | 0.44 |
| Mean peak intensity (dB) | 11.2 | 18.1 | 0.12 |
| Mean area under the curve (dB sec) | 311.5 | 762.5 | 0.03 |
| Mean elastography (m/s) | 1.23 | 1.26 | 0.80 |

Table 2. Histopathologic scores of resected ileal strictures

| Patient | Acute inflammation (0-3+) | Chronic inflammation (0-3+) | % Fibrosis in submucosa and muscularis propria | Increased thickness of muscularis mucosa in stricture | Increased thickness of muscularis propria in stricture |
|---------|---------------------------|-----------------------------|--|---|--|
| S1 | 3 | 3 | 30% | 10 | 1.5 |
| S2 | 0 | 1 | 60% | 4.3 | 10 |
| S3 | 1 | 3 | 30% | 2 | 3 |
| S4 | 2 | 3 | 20% | 5 | 2 |
| S5 | 3 | 3 | 50% | 2.5 | 3 |
| S6 | 2 | 3 | 10% | 3.5 | 1.3 |
| S7 | 3 | 3 | 50% | 10 | 3 |
| S8 | 3 | 3 | 20% | 17.5 | 1.5 |
| S10 | 3 | 3 | 50% | 10 | 2 |

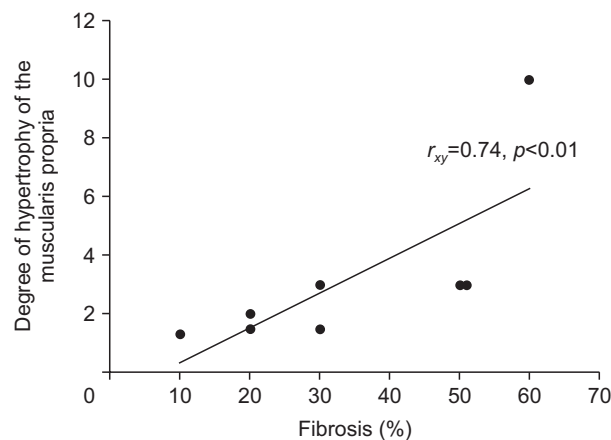


Fig. 1. Degree of hypertrophy of muscularis propria and percent of fibrosis in ileal strictures.

grade acute and/or chronic inflammation. All specimens were also found to have irreversible fibrosis in the submucosa and muscularis propria, ranging from 10–60% of the tissue depth. Among these, 6 specimens were found to have 30% or greater fibrosis in the submucosa and muscularis propria at the most narrowed portion of the stricture. Increasing amounts of fibrosis were found to correlate significantly with increasing thickness of the muscularis propria, reflecting a reactive muscular hypertrophy due to chronic obstruction ($r_{xy}=0.74, p<0.01$) (Fig. 1).

DISCUSSION

This is the first pediatric study to demonstrate the utility of CEUS in identifying those patients with CD and obstructive fibrosing disease of the terminal ileum that would be amenable to early surgical therapy. All of the surgically managed patients were found to have histopathology proven fibrosis and reactive muscular hypertrophy of the muscularis

indicating the presence of high grade obstructive mixed fibrotic and inflammatory stricture of the terminal ileum. The reactive muscular hypertrophy correlated with increased tissue perfusion (AUC). In comparison, patients with medically responsive small bowel disease had less tissue perfusion noted on CEUS, thereby reflecting less inflammation and hypertrophy of the muscularis propria.

The study was not designed to validate CEUS in demonstrating clinical responsiveness to therapy, since only patients with obstructive symptoms were recruited into the study. Our initial hypothesis was that SWE would allow us to best delineate tissue fibrosis refractory to therapy. But in the end, SWE showed no correlation with the degree of fibrosis among those patients that required surgical intervention. Moreover, the increased tissue perfusion as defined by the markedly elevated AUC among those patients with refractory disease that went on to receive surgery proved to be secondary to an hypertrophy of the muscularis propria in response to the significant resistance imposed by the mixed inflammatory and fibrotic obstructive lesions within the terminal ileum.

In pediatric CD, the ileum is the most commonly, and frequently most severely affected region of bowel [1]. Failure to identify and appropriately treat fibrotic strictures in a timely manner leads to CD complications, including fistula and abscess formation. While medical therapy can be used to treat inflammation, most medications, including anti-tumor necrosis factor are unlikely to resolve fibrotic intestinal strictures [20,21]. The early identification and management of patients with CD complicated by fibrotic intestinal stricture holds significant clinical implications, including the need to closely follow patients with obstructive symptoms, and in limiting the use of corticosteroids. Most importantly, these patients should be referred for surgical resection.

Most diagnostic modalities have not been shown to detect the presence of fibrosis in intestinal strictures that have required surgical resection. Although computerized tomography enterography and fluorodeoxyglucosepositron emission tomography identify strictures by demonstrating luminal narrowing with proximal dilation, these studies require significant radiation exposure and are unable to discriminate between acute inflammation and fibrosis within the affected bowel wall [22]. Similarly, magnetic resonance imaging (MRI) including MR enterography and gadolinium-enhanced MRI offer radiation-free, cross-sectional imaging can identify intestinal strictures but cannot delineate between fibrotic and inflammatory strictures [23]. Moreover, these radiological techniques are lengthy and costly exams that often require sedation in pediatric patients. Traditional abdominal ultrasound offers a fast, radiation-free, sedation-free bedside mode of detecting terminal ileum strictures in CD, but again does not provide an assessment of bowel wall fibrosis. CEUS expands the role of traditional ultrasound and allows for enhanced characterization of targeted tissues [18]. It can be extrapolated that the significantly increased measure of AUC in those patients who underwent surgical resection reflected an enhanced level of tissue perfusion within the hypertrophied muscularis in the setting of tissue fibrosis. Indeed, a reactive hypertrophy of the muscularis in the setting of severe obstructive fibro-stenotic disease. Our observations are in contrast to our initial hypothesis that predicted that acute inflammation would result in increased local tissue perfusion and higher CEUS kinetic values, as concluded from a prior adult study [24]. Our study would suggest that through CEUS enhanced tissue perfusion, as quantified by AUC kinetics may be used as a surrogate marker of reactive muscular hypertrophy and fibrosis. The limitations of this study include: a small sample size, and a selection bias, as only those patients presenting with obstructive

symptoms were recruited into the study. Moreover, expertise in performing CEUS is limited to a small number of well-trained personnel.

In conclusion, CEUS is particularly useful in children with CD due to it being a non-invasive, radiation-free, sedation-free radiological exam ideally suited for the pediatric patient population. Our study shows that CEUS is helpful in identifying bowel wall fibrosis that would be amenable to early surgical intervention, especially in patients that are presumed refractory to conventional therapy. Further research is needed in order to validate these study results, and to support the notion of using CEUS as a Point of Care radiological tool that could be used to non-invasively monitor patient responsiveness to medical therapy. The clinical application of CEUS in the evaluation of patients with isolated colonic CD remains to be determined.

REFERENCES

1. Freeman HJ. Natural history and long-term clinical course of Crohn's disease. *World J Gastroenterol* 2014;20:31-6.
[PUBMED](#) | [CROSSREF](#)
2. Cuffari C. Diagnostic Considerations in Pediatric Inflammatory Bowel Disease Management. *Gastroenterol Hepatol (N Y)* 2009;5:775-83.
3. Sauer CG, Kugathasan S. Pediatric inflammatory bowel disease: highlighting pediatric differences in IBD. *Gastroenterol Clin North Am* 2009;38:611-28.
[PUBMED](#) | [CROSSREF](#)
4. Walker WA, Kleinman R. Crohn's disease. In: Kleinman RE, ed. *Walker's Pediatric Gastrointestinal Disease*. 5th ed. BC Decker, 2008:519-39.
5. Rieder F, Zimmermann EM, Remzi FH, Sandborn WJ. Crohn's disease complicated by strictures: a systematic review. *Gut* 2013;62:1072-84.
[PUBMED](#) | [CROSSREF](#)
6. Li J, Mao R, Kurada S, Wang J, Lin S, Chandra J, et al. Pathogenesis of fibrostenosing Crohn's disease. *Transl Res* 2019;209:39-54.
[PUBMED](#) | [CROSSREF](#)
7. Ntoulia A, Anupindi SA, Darge K, Back SJ. Applications of contrast-enhanced ultrasound in the pediatric abdomen. *Abdom Radiol (NY)* 2018;43:948-59.
[PUBMED](#) | [CROSSREF](#)
8. McMahan CJ, Ayres NA, Bezold LI, Lewin MB, Alonzo M, Altman CA, et al. Safety and efficacy of intravenous contrast imaging in pediatric echocardiography. *Pediatr Cardiol* 2005;26:413-7.
[PUBMED](#) | [CROSSREF](#)
9. Piskunowicz M, Kosiak W, Batko T, Piankowski A, Polczyńska K, Adamkiewicz-Drożyńska E. Safety of intravenous application of second-generation ultrasound contrast agent in children: prospective analysis. *Ultrasound Med Biol* 2015;41:1095-9.
[PUBMED](#) | [CROSSREF](#)
10. Darge K, Papadopoulou F, Ntoulia A, et al. Safety of contrast-enhanced ultrasound in children for non-cardiac applications: a review by the Society for Pediatric Radiology (SPR) and the International Contrast Ultrasound Society (ICUS). *Pediatr Radiol* 2013;43:1063-73.
[PUBMED](#) | [CROSSREF](#)
11. Sidhu PS, Cantisani V, Deganello A, Dietrich CF, Duran C, Franke D, et al. Role of contrast-enhanced ultrasound (CEUS) in paediatric practice: an EFSUMB position statement. *Ultraschall Med* 2017;38:33-43.
[PUBMED](#) | [CROSSREF](#)
12. Rafailidis V, Deganello A, Watson T, Sidhu PS, Sellars ME. Enhancing the role of paediatric ultrasound with microbubbles: a review of intravenous applications. *Br J Radiol* 2017;90:20160556.
[PUBMED](#) | [CROSSREF](#)
13. Serafin Z, Bialecki M, Bialecka A, Sconfienza LM, Klopocka M. Contrast-enhanced ultrasound for detection of Crohn's disease activity: systematic review and meta-analysis. *J Crohn's Colitis* 2015;10:354-62.
[PUBMED](#) | [CROSSREF](#)

14. Ripollés T, Rausell N, Paredes JM, Grau E, Martínez MJ, Vizuete J. Effectiveness of contrast-enhanced ultrasound for characterisation of intestinal inflammation in Crohn's disease: A comparison with surgical histopathology analysis. *J Crohn's Colitis* 2013;7:120-8.
[PUBMED](#) | [CROSSREF](#)
15. Medellin A, Merrill C, Wilson SR. Role of contrast-enhanced ultrasound in evaluation of the bowel. *Abdom Radiol (NY)* 2018;43:918-33.
[PUBMED](#) | [CROSSREF](#)
16. Quaia E, Gennari AG, Van Beek EJR. Differentiation of inflammatory from fibrotic ileal strictures among patients with Crohn's disease through analysis of time-intensity curves obtained after microbubble contrast agent injection. *Ultrasound Med Biol* 2017;43:1171-8.
[PUBMED](#) | [CROSSREF](#)
17. Kljucsevsek D, Vidmar D, Urlep D, Dezman R. Dynamic contrast-enhanced ultrasound of the bowel wall with quantitative assessment of Crohn's disease activity in childhood. *Radiol Oncol* 2016;50:347-54.
[PUBMED](#) | [CROSSREF](#)
18. Hwang M, Lyshchik A, Fleischer AC. Molecular sonography with targeted microbubbles: current investigations and potential applications. *Ultrasound Q* 2010;26:75-82.
[PUBMED](#) | [CROSSREF](#)
19. US Food and Drug Administration. Lumason Full Prescribing Information [Internet]. US Food and Drug Administration; 2016 [cited 2016 Dec]. Available from: https://www.accessdata.fda.gov/drugsatfda_docs/label/2021/203684s0091b1.pdf
20. Rieder F, Zimmermann EM, Remzi FH, Sandborn WJ. Crohn's disease complicated by strictures: a systematic review. *Gut* 2013;62:1072-84.
[PUBMED](#) | [CROSSREF](#)
21. Kugathasan S, Denson LA, Walters TD, Kim MO, Marigorta UM, Schirmer M, et al. Prediction of complicated disease course for children newly diagnosed with Crohn's disease: a multicentre inception cohort study. *Lancet* 2017;389:1710-8.
[PUBMED](#) | [CROSSREF](#)
22. Jacene HA, Ginsburg P, Kwon J, Nguyen GC, Montgomery EA, Bayless TM, et al. Prediction of the need for surgical intervention in obstructive Crohn's disease by 18F-FDG PET/CT. *J Nucl Med* 2009;50:1751-9.
[PUBMED](#) | [CROSSREF](#)
23. Darbari A, Sena L, Argani P, Oliva-Hemker JM, Thompson R, Cuffari C. Gadolinium-enhanced magnetic resonance imaging: a useful radiological tool in diagnosing pediatric IBD. *Inflamm Bowel Dis* 2004;10:67-72.
[PUBMED](#) | [CROSSREF](#)
24. Migaleddu V, Scanu AM, Quaia E, Rocca PC, Dore MP, Scanu D, et al. Contrast-enhanced ultrasonographic evaluation of inflammatory activity in Crohn's disease. *Gastroenterology* 2009;137:43-52.
[PUBMED](#) | [CROSSREF](#)