

# Spontaneous recanalization of complete urethral injury treated by suprapubic cystostomy alone after severe pelvic bone fracture in a young male patient in Korea: a case report

Han Kyul Shin, MD<sup>1,3</sup> , Gi Ho Moon, MD<sup>1,2</sup> , Sung Yub Jeong, MD<sup>1,3</sup> , Ho Jun Lee, MD<sup>1,3</sup> 

<sup>1</sup>Department of Trauma Surgery, Armed Forces Trauma Center, Armed Forces Capital Hospital, Seongnam, Korea

<sup>2</sup>Department of Orthopedic Surgery, Armed Forces Capital Hospital, Seongnam, Korea

<sup>3</sup>Department of Surgery, Armed Forces Capital Hospital, Seongnam, Korea

Received: September 28, 2022

Revised: November 7, 2022

Accepted: November 9, 2022

### Correspondence to

Ho Jun Lee, MD

Department of Trauma Surgery, Armed Forces Trauma Center, Armed Forces Capital Hospital, 81 Saemaoul-ro 177 beon-gil, Bundang-gu, Seongnam 13574, Korea

Tel: +82-31-725-5568

Email: hzl224@hanmail.net

Injury to the genitourinary tract is rare, with an incidence of less than 1%. Younger men (mean age, approximately 30 years) are predominantly affected. We introduce an unusual case of a 25-year-old male patient with complete urethral injury combined with a severe open pelvic bone fracture. During the emergency surgery, the primary realignment of the posterior urethra could not be performed due to a large defect. With suprapubic cystostomy alone, follow-up voiding cystourethrography showed spontaneous recanalization of the transected urethra after four months. Suprapubic cystostomy is an efficient treatment option when primary realignment is not possible.

**Keywords:** Urethra; Pelvic bones; Wounds and injuries; Cystostomy; Case reports

## INTRODUCTION

Urethral injury is a consequence of major blunt trauma to the pelvis, with a reported incidence ranging from 1.6% to 25.0% [1,2]. Men are predominantly affected by injury due to a long urethra and attachment to the pubis. These injuries can be catastrophic and incapacitating, causing urethral strictures, erectile dysfunction, and urinary incontinence.

The male urethra can be classified into anterior (bulbous and pendulous) and posterior (prostatic and membranous) parts. Posterior urethral disruption injuries can occur due to severe pelvic blunt injuries, especially avulsion of the puboprostatic liga-

ment and lengthening of the membranous urethra. The treatment of posterior urethral injury involves primary realignment (PR) with a urethral catheter or suprapubic cystostomy (SPC) with delayed repair [3]. A recent systematic review reported that PR appears superior in terms of stricture formation, but there is still debate regarding the proper management of posterior urethral disruption.

In this case report, we review an unusual experience of spontaneous recanalization of complete posterior urethral disruption combined with an open pelvic bone fracture in a young male patient who underwent SPC alone.

CASE REPORT

A 26-year-old male patient was a pedestrian struck by a forklift caught between a car and a wall. The patient was initially transported to a local emergency department, where he was diagnosed with an open pelvic bone fracture and a right distal femur fracture (Fig. 1). Active contrast leakage was not shown on abdomen and pelvis computed tomography scan. A Foley catheter was inserted constrainedly, and 50 mL of fresh blood was drained. Owing to a lack of capacity and unstable systolic blood pressure (<60 mmHg), we decided to transfer the patient to the Armed Forces Trauma Center (Seongnam, Korea). Vital signs on arrival were stable (blood pressure, 123/77 mmHg; pulse rate, 109 beats/min; respiratory rate, 16 breaths/min) and extended focused assessment with sonography for trauma (eFAST) was negative. Therefore, we decided to perform emergency surgery for pelvic exploration and external fixation.

The trauma surgery team surveyed the pelvic cavity during the initial emergency surgery, but no active venous or arterial bleeding was observed. Orthopedic surgeons performed external pelvic fixation and decided not to mount anterior plating on the symphysis pubis due to contaminated wounds and urologic interventions. Urologists had previously explored the bladder and urethra. The bladder was perforated, and the posterior urethra was completely disrupted. In addition, the initial Foley catheter was exposed outside the bladder. PR of the urethra was initially attempted using interlocking urethroplasty; however, this failed because the resected part of the urethra was too extended, and

the view was not clear (Fig. 2). Therefore, emergency surgery was completed with external pelvic fixation, internal fixation of the right femur, bladder repair, and SPC. The urologists planned a delayed repair of the urethral injury for 12 weeks later.

On the 8th day of hospitalization, orthopedic surgeons added an anterior plate to the symphysis pubis. After 3 months, voiding cystourethrography, which was planned pre-urethroplasty, showed spontaneous recanalization of the ruptured posterior urethra (Fig. 3) with no intervention except for SPC. Uroflowmetry showed that Qmax was 18 mL/sec and voided volume was 298 mL. Hence, we changed the plan for urethroplasty to observation. The SPC catheter was removed, and the patient did not com-

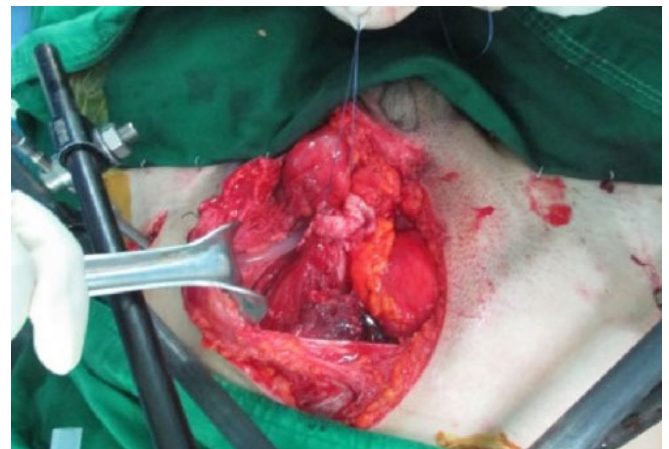


Fig. 2. Intraoperative finding showed that ruptured urethra could not be realigned via retrograde and antegrade Foley catheter insertion.

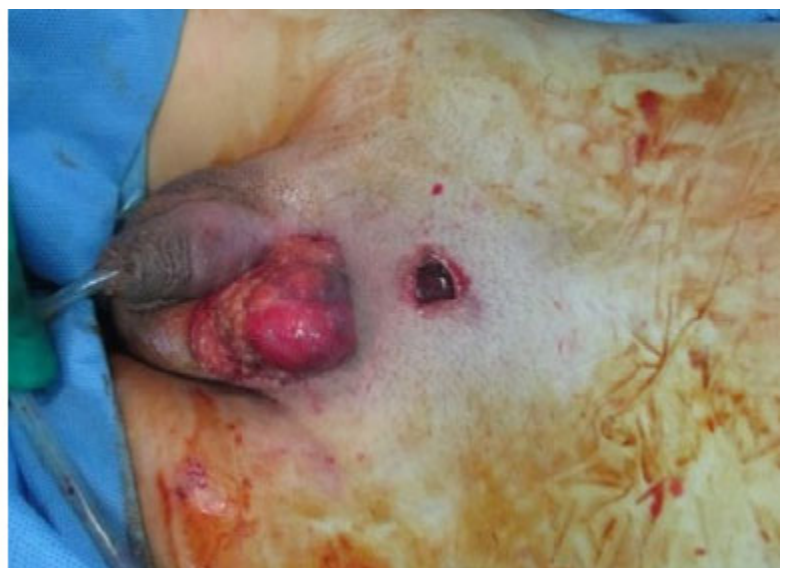
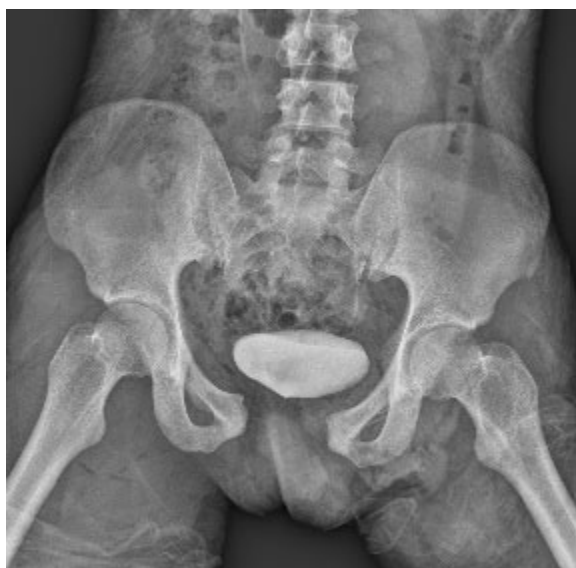
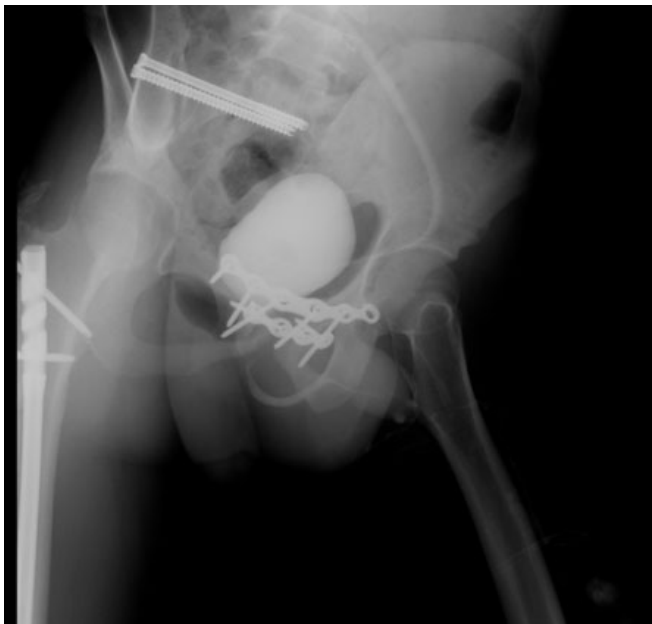Fig. 1. Pictures of initial portable X-ray and wound showed the anterior posterior compression type III open pelvic bone fracture.



**Fig. 3.** After 3 months of suprapubic cystostomy alone, the patient showed complete healing of posterior urethral disruption. There was no evidence of urinary leakage or urethral stricture.

plain of any signs of urinary leakage or urethral stricture. In addition, he reported no erectile dysfunction or urinary incontinence.

Ten months after the initial injury, the patient reported mild residual urination. Follow-up uroflowmetry and residual urine test revealed no specific findings (Qmax, 19.9 mL/sec; voided volume, 473 mL; residual urine, 7 mL). Any medications which might improve urinary symptoms was not administered to the patient during the whole treatment period.

### Ethics statements

The case report was approved by the Institutional Review Board of the Armed Forces Capital Hospital (No. AFCH 2022-09-002-001). Data were collected and analyzed in an ethical manner while protecting the patient's right to privacy. The requirement for informed consent was waived because this was a retrospective study conducted using medical records.

## DISCUSSION

Both anterior and posterior urethral injuries are commonly caused by blunt trauma to the pelvis. However, the posterior urethra is more easily affected by serious pelvic bone fractures, given its deeper location. The key vector for posterior urethral disruption is the upward displacement of the bladder and prostate. An estimated 10% of pelvic fractures are combined with posterior

urethral injuries [4].

The risk of urethral injury is likely correlated with the type of pelvic fracture. Isolated acetabulum, ilium, and sacrum fractures are unlikely to damage the urethra (close to zero) [4]. However, diastasis of the symphysis pubis or inferomedial pubic bone fracture displacement was associated with an approximately 10% increased risk of urethral injury in one study [2]. Other high-risk pelvic bone fracture types involve all four rami of the pubis or both ipsilateral rami combined with high-grade disruption through the sacrum, sacroiliac joint, or ilium.

The standard diagnostic tool for urethral injury is retrograde urethrography. Computed tomography cannot efficiently survey the urethra, especially without delayed-phase scans, which are not routinely performed in trauma settings. Careful insertion of a Foley catheter in a patient with a pelvic bone fracture is a widely known common practice; however, in this case, incorrect, forced placement of the Foley catheter demonstrated the lack of a trauma program in the local emergency department.

The preferred repair for posterior urethral injuries has changed since the 1950s. One of the earliest procedures, described by Badenoch [5], was a “pull-through” operation, a retrograde catheterization through the defect to the bladder, which let the injury heal by scarring. Emerging procedures using the abdominal approach have become mainstream treatments involving delayed repair techniques [6,7]. In 1985, Webster described a complete perineal and stepwise approach to urethral repair. This procedure provides a meaningful success rate of 97% in adults [8]. However, the 2016 male urethral stricture guideline from the American Urological Association (AUA) insisted that definitive urethral reconstruction for pelvic fracture urethral injury should be planned only after major injuries stabilize and patients can be safely positioned for urethroplasty [9]. Thus, there is a need to perform immediate “bridging” treatment.

Despite advances in urethroplasty, the best immediate management for posterior urethral injury in pelvic fractures remains unclear. Currently, two interventions are commonly accepted: PR and SPC. Realignment of the injured urethra using a Foley catheter, open cystostomy, and interlocking sounds have supplanted primary suturing, but this has been associated with an increasing rate of erectile dysfunction and incontinence. Suprapubic cystostomy followed by delayed urethroplasty has become the preferred first-step treatment. The development of flexible urethros-copy has recently attracted renewed interest as an immediate option for early PR [2,4,10–13]. Two recent systematic reviews addressing the priority between PR and SPC have revealed incompatible results. Barrett et al. [10] demonstrated a significantly

lower rate of stricture in PR versus SPC and no differences for other complications (erectile dysfunction and incontinence). Light et al. [14] compared PR versus SPC and early endoscopic realignment versus SPC; they showed no significant differences in stricture, erectile dysfunction, or incontinence across the groups. No randomized controlled trials directly compared the PR group with SPC, and both reviews had limitations in the evidence. Nevertheless, the 2020 Urotrauma Guideline published by the AUA [15] added a new recommendation that clinicians should perform percutaneous or open suprapubic tube placement as the preferred initial management for most pelvic fracture urethral injury cases.

In this case report, we describe a young male patient with complete posterior urethral disruption combined with severe pelvic bone fracture and treated with SPC alone. In the emergency setting, PR could not be performed due to the large defect and damage to the structure of the urethra. Therefore, a delayed urethroplasty was not performed. This is a rare case in which SPC alone was definitive management for a complete posterior urethral injury pelvic bone fracture.

## NOTES

### Conflicts of interest

The authors have no conflicts of interest to declare.

### Funding

None.

### Data sharing statement

Not applicable.

### Author contributions

Conceptualization: all authors; Data curation: all authors; Formal analysis: all authors; Methodology: all authors; Resources: all authors; Supervision: all authors; Validation: all authors; Visualization: all authors; Writing—original draft: HKS; Writing—review & editing: HJL. All authors read and approved the final manuscript.

## REFERENCES

1. Bjurlin MA, Fantus RJ, Mellett MM, Goble SM. Genitourinary injuries in pelvic fracture morbidity and mortality using the National Trauma Data Bank. *J Trauma* 2009;67:1033–9.
2. Koraitim MM. Pelvic fracture urethral injuries: evaluation of various methods of management. *J Urol* 1996;156:1288–91.
3. Myers JB, McAninch JW. Management of posterior urethral disruption injuries. *Nat Clin Pract Urol* 2009;6:154–63.
4. Koraitim MM. Pelvic fracture urethral injuries: the unresolved controversy. *J Urol* 1999;161:1433–41.
5. Badenoch AW. A pull-through operation for impassable traumatic stricture of the urethra. *Br J Urol* 1950;22:404–9.
6. Morehouse DD, Belitsky P, Mackinnon K. Rupture of the posterior urethra. *J Urol* 1972;107:255–8.
7. Waterhouse K, Laungani G, Patil U. The surgical repair of membranous urethral strictures: experience with 105 consecutive cases. *J Urol* 1980;123:500–5.
8. Flynn BJ, Delvecchio FC, Webster GD. Perineal repair of pelvic fracture urethral distraction defects: experience in 120 patients during the last 10 years. *J Urol* 2003;170:1877–80.
9. Wessells H, Angermeier KW, Elliott S, et al. Male urethral stricture: American Urological Association Guideline. *J Urol* 2017;197:182–90.
10. Barrett K, Braga LH, Farrokhyar F, Davies TO. Primary realignment vs suprapubic cystostomy for the management of pelvic fracture-associated urethral injuries: a systematic review and meta-analysis. *Urology* 2014;83:924–9.
11. Mouraviev VB, Coburn M, Santucci RA. The treatment of posterior urethral disruption associated with pelvic fractures: comparative experience of early realignment versus delayed urethroplasty. *J Urol* 2005;173:873–6.
12. Chang PC, Hsu YC, Shee JJ, et al. Early endoscopic primary realignment decreases stricture formation and reduces medical costs in traumatic complete posterior urethral disruption in a 2-year follow-up. *Chang Gung Med J* 2011;34:179–85.
13. Moudouni SM, Patard JJ, Manunta A, Guiraud P, Lobel B, Guille F. Early endoscopic realignment of post-traumatic posterior urethral disruption. *Urology* 2001;57:628–32.
14. Light A, Gupta T, Dadabhoy M, et al. Outcomes following primary realignment versus suprapubic cystostomy with delayed urethroplasty for pelvic fracture-associated posterior urethral injury: a systematic review with meta-analysis. *Curr Urol* 2019;13:113–24.
15. Morey AF, Broghammer JA, Hollowell CM, McKibben MJ, Souter L. Urotrauma Guideline 2020: AUA Guideline. *J Urol* 2021;205:30–5.