



# Unusual insertion of the levator scapulae muscle: a case report

Sang-Hyun Kim, Hyung-Jin Lee

Catholic Institute for Applied Anatomy, Department of Anatomy, College of Medicine, The Catholic University of Korea, Seoul, Korea

**Abstract:** The current case report describes an uncommon insertion of the levator scapulae (LS), which broadly attaches to multiple structures, including the serratus posterior superior, ligamentum nuchae, and the 6th and 7th spinous processes of the cervical vertebrae. The most superior portion of this aponeurosis merged with the ligamentum nuchae at the C7 level. The middle and inferior portions of the head were inserted (or fused) into the tendon of the rhomboid minor as well as the fibers of the serratus posterior superior muscle. Consequently, recognizing this anatomical variation, characterized by an additional slip of the LS attaching to the 7th vertebra and other muscular structures, is crucial not only for anatomists but also for surgeons performing procedures on the posterior neck related to cervical or shoulder pain and cervical dystonia.

**Key words:** Levator scapulae, Unusual insertion, Accessory head, Cervical dystonia

Received April 30, 2023; Accepted May 24, 2023

## Introduction

The levator scapulae (LS) is a strap-like upper back and neck muscle. The LS originates from the transverse processes of the upper four cervical vertebrae or, less commonly upper five cervical vertebrae. It then runs downward posterolaterally and inserts at the superior angle and medial border of the scapula [1-3].

Variations in the anatomical structure of the LS and additional cervical musculature are infrequent occurrences [4]. Previous literature has documented variations in the LS, encompassing its origination from disparate regions of the cervical vertebrae, extensions to the temporal or occipital bones, the rhomboid, serratus anterior, serratus posterior superior, and trapezius muscles. Furthermore, instances of extensions to the clavicle, first and second ribs, and spinous processes

of the thoracic vertebrae have also been reported [1, 4, 5]. We present a case in which the left LS gave rise to an accessory head with broad insertion by way of a flat aponeurotic band to the ligamentum nuchae, the tendon of the rhomboideus major, and the superior aspect of the serratus posterior superior muscle.

## Case Report

This cadaveric study was conducted in compliance with the Act on Dissection and Preservation of Corpses of the Republic of Korea (act number: 14885) and approved by the Institutional Review Board of the College of Medicine, The Catholic University of Korea (Approval No MC23EISE0019). The variation was found during a routine dissection of the posterior cervical and upper back region at the Catholic Institute for Applied Anatomy, College of Medicine of the Catholic University of Korea. The anomaly was discovered in an 84-year-old Asian male. The cadaver showed no evidence of cervicospinal or thoracic procedures or other significant musculoskeletal abnormalities. The skin and subcutaneous tissue were removed during the dissection to reveal the trapezius. Then, the trapezius was isolated from its origin and

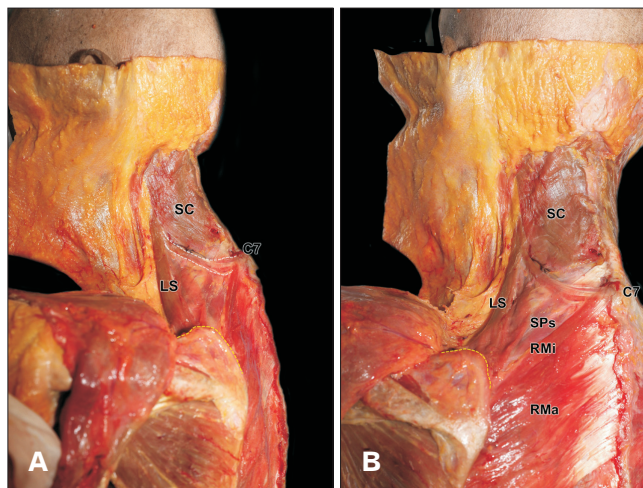
### Corresponding author:

Hyung-Jin Lee

Catholic Institute for Applied Anatomy, Department of Anatomy, College of Medicine, The Catholic University of Korea, Seoul 06591, Korea  
E-mail: leehj221@catholic.ac.kr

Copyright © 2023. Anatomy & Cell Biology

This is an Open Access article distributed under the terms of the Creative Commons Attribution Non-Commercial License (<http://creativecommons.org/licenses/by-nc/4.0/>) which permits unrestricted non-commercial use, distribution, and reproduction in any medium, provided the original work is properly cited.



**Fig. 1.** The left image illustrates the accessory head's attachment to the ligamentum nuchae and the C7, encompassing the RMi and SPs (A). The right image presents a lateral view of the accessory head, outlined by white dashed lines (B). LS, levator scapulae; SPs, serratus posterior superior muscles; RMi, rhomboid minor; SC, splenius capitis muscle; RMa, rhomboid major muscle; C7, 7th cervical vertebra.

reflected laterally to reveal the LS, rhomboid major, minor, and splenius capitis muscles. After arising from the transverse processes of the atlas, axis, and the posterior tubercles of the transverse processes of the third and fourth cervical vertebrae, the belly of the LS divided into two muscle bellies to form two distinct heads. The lateral head, a typical insertion fiber, was inserted into the superior angle and medial border of the scapula (Fig. 1). The medial, or accessory, head, an atypical insertion fiber, was traveled inferomedially, parallel to the fibers of the splenius capitis and cervicis, before widening into a thick aponeurotic band, which inserted broadly upon several structures such as serratus posterior superior, ligamentum nuchae, and 6th and 7th spinous process of the cervical vertebrae.

The most superior portion of this aponeurosis fused with the ligamentum nuchae at the level of C7 (Fig. 1). The middle and inferior portion of the head was inserted (or fused with) into the tendon of the rhomboid minor as well as the fibers of the serratus posterior superior muscle. The aponeurosis of the medial head was tough and required sharp dissection to expose the innervation, which arose deeply from a small branch of the dorsal scapular nerve. No other anomalies or variations of cervical, thoracic, or lumbar musculature were noted.

## Discussion

Numerous researchers have conducted investigations to examine the standard anatomy and variations of the LS. In a study involving 50 cadavers, Mori identified a unique slip originating from the medial edge of the LS, which proceeded medially and downward to insert into the spinous process of the second thoracic vertebra on the dorsal surface of the serratus posterior superior or the thoracolumbar fascia [6]. Macalister also documented several LS variations, encompassing origins from the temporal and occipital bones and potential slips extending to diverse structures in the cervical and upper thoracic regions [7]. Interestingly, none of the aforementioned authors have reported instances where the LS demonstrated a broad insertion through a significant aponeurotic band. This crucial distinction lends clinical relevance to the present study. Considering that thoracolumbar aponeurosis can affect spinal alignment, this substantial aponeurotic component might also increase the likelihood of disrupting the vertebral column's normal curvature and stability [5].

The LS is commonly associated with the etiopathology of neck and shoulder pain [8-10]. Behrsin and Maguire investigated LS activity during shoulder movement using electromyography and radiographic techniques. Their findings suggest that in the presence of pathological changes, the potential stress exerted on the cervical spine by LS contraction may lead to referred pain in the shoulder region [8]. The existence of an unusual variant in our case might enhance the likelihood of causing shoulder pain. Menachem et al. investigated patients experiencing pain at the medial angle of the scapula, known as the "levator scapulae syndrome." They deduced that this condition could be attributed to anatomical variations involving the LS [9]. Garten and Shafer explored the LS's role in the emergence of "cervical syndrome" and pinpointed LS shortening as a contributing factor to trigger point formation [10]. We suggest that LS variations could also be associated with cervical pain; however, due to the postmortem context of this cadaveric discovery, we cannot verify this conjecture in our particular case.

In recent literature, the role of LS in cervical dystonia has been highlighted [11]. The most frequent type of cervical dystonia, muscular torticollis, has traditionally been treated by targeting the ipsilateral splenius capitis, contralateral sternocleidomastoid, and trapezius muscles [11]. In a study by Erro et al. [11], the LS was theorized to be the principal

muscle contributing to torticollis. Consequently, variations in the LS may potentially aggravate torticollis. The research posited that LS variations could explain the lack of treatment responsiveness in medically resistant cases [11]. Variations in the LS might also influence torticollis, and awareness of these variations can support the management of cases resistant to conventional treatments.

In summary, cognizance of this anatomical variation, characterized by an additional slip of the LS attaching to the 7th vertebra and other muscular structures, holds significance not only for anatomists but also for surgeons performing procedures on the posterior neck. Furthermore, this information bears significance for rheumatologists, neurologists, physiatrists, and physical therapists who manage patients presenting with cervical or shoulder pain and cervical dystonia. Reporting anatomical variations is essential due to their potential clinical and anatomical impact in scientific research.

## ORCID

Sang-Hyun Kim: <https://orcid.org/0000-0001-9692-4838>

Hyung-Jin Lee: <https://orcid.org/0000-0002-3082-935X>

## Author Contributions

Conceptualization: SHK. Data acquisition: SHK. Data analysis or interpretation: SHK, HJL. Drafting of the manuscript: SHK, HJL. Critical revision of the manuscript: HJL. Approval of the final version of the manuscript: all authors.

## Conflicts of Interest

No potential conflict of interest relevant to this article was reported.

## Funding

None.

## Acknowledgements

The authors sincerely thank those who donated their bodies to science so that anatomical research could be performed. Results from such research can potentially increase mankind's overall knowledge that can then improve patient care. Therefore, these donors and their families deserve our highest gratitude.

## References

1. Macbeth RA, Martin CP. A note on the levator scapulae muscle in man. *Anat Rec* 1953;115:691-6.
2. Moore KL, Agur AMR, Dalley AF. Clinically oriented anatomy. Lippincott Williams & Wilkins; 2013.
3. Tubbs RS, Shoja MM, Loukas M. Bergman's comprehensive encyclopedia of human anatomic variation. Wiley-Blackwell; 2016.
4. Chotai PN, Loukas M, Tubbs RS. Unusual origin of the levator scapulae muscle from mastoid process. *Surg Radiol Anat* 2015;37:1277-81.
5. Loukas M, Louis RG Jr, Merbs W. A case of atypical insertion of the levator scapulae. *Folia Morphol (Warsz)* 2006;65:232-5.
6. Mori M. Statistics on the musculature of the Japanese. *Okajimas Folia Anat Jpn* 1964;40:195-300.
7. Macalister A. Additional observations on muscular anomalies in human anatomy (third series) with a catalogue of the principal muscular variations hitherto published. Academy; 1872. 134 p.
8. Behrsin JF, Maguire K. Levator scapulae action during shoulder movement: a possible mechanism for shoulder pain of cervical origin. *Aust J Physiother* 1986;32:101-6.
9. Menachem A, Kaplan O, Dekel S. Levator scapulae syndrome: an anatomic-clinical study. *Bull Hosp Jt Dis* 1993;53:21-4.
10. Garten H. The muscle test handbook: functional assessment, myofascial trigger points and meridian relationships. Elsevier; 2013.
11. Erro R, Bhatia KP, Catania S, Shields K, Cordivari C. When the levator scapulae becomes a "rotator capitis": implications for cervical dystonia. *Parkinsonism Relat Disord* 2013;19:705-6.