



# Degenerated lumbricals in the feet of adult human cadavers: case series

Hare Krishna<sup>1</sup>, Rati Tandon<sup>2</sup>, Tony George Jacob<sup>3</sup>

<sup>1</sup>Department of Anatomy, All India Institute of Medical Sciences, Jodhpur, <sup>2</sup>Department of Anatomy, Mahatma Gandhi University of Medical College and Hospital, Jaipur, <sup>3</sup>Department of Anatomy, All India Institute of Medical Sciences, New Delhi, India

**Abstract:** In the foot, the lumbricals flex the metatarsophalangeal joints and extend the interphalangeal joints. The lumbricals are known to be affected in neuropathies. It is not known whether they may degenerate in normal individuals. Here, we report our findings of isolated degenerated lumbricals in seemingly normal feet of two cadavers. We explored lumbricals in 20 male and 8 female cadavers that were 60–80 years of age at the time of death. As part of routine dissection, we exposed the tendons of the flexor digitorum longus and the lumbricals. From the degenerated lumbricals, we took some tissue for paraffin-embedding, sectioning, and staining by hematoxylin and eosin, and Masson's trichrome technique. Of the 224 lumbricals studied, we found four apparently degenerated lumbricals in two male cadavers. In the first, the 2nd and 4th lumbricals in the left foot and the 2nd in the right foot were degenerated. In the second, the right 4th lumbrical was degenerated. Microscopically, the degenerated tissue was made of bundles of collagen. The lumbricals may have degenerated due to compression of their nerve supply. We cannot comment on whether the functionality of the feet were affected by these isolated degeneration of the lumbricals.

**Key words:** Lumbrical muscle, Foot, Degeneration, Lateral plantar nerve

Received November 10, 2022; Revised January 3, 2023; Accepted January 25, 2023

## Introduction


The lumbricals are a group of deep muscles in the hand and foot that on contraction can flex the metacarpophalangeal or metatarsophalangeal joints, and extend the interphalangeal joints [1, 2]. They contribute to the functionality of the hand and the foot. In the foot, the lateral three lumbrical muscles are attached proximally to the adjacent sides of the tendons of the flexor digitorum longus (FDL) and the first lumbrical is attached only to the medial aspect of the first tendon of FDL [1]. They pass anteriorly, on the medial sides

of the metatarsophalangeal joints of each of the lateral four toes, and incline superiorly to be attached to the base of the proximal phalanx and the dorsal digital expansions of the lateral four toes [1, 3].

The lumbricals contain numerous muscle spindles, which are proprioceptors [1, 4]. This proprioceptive information is very important for the coordinated movement between the plantar flexors and extensors, and the control of joint movements while standing, walking, and running [1].

Apart from flexing the metatarsophalangeal joints and extending the interphalangeal joints of the lateral four toes [4], the lumbricals also maintain the extension of the digits at the interphalangeal joints, while the FDL tendons are flexing the toes [5]. Thus, they prevent toes from buckling under while walking and running [5]. They have been reported to help in maintaining the medial longitudinal arch [6-8]. Further, along with the interossei, they play a role in the stabilization of the forefoot during the stance phase, and rearfoot during

### Corresponding author:

Tony George Jacob   
Department of Anatomy, All India Institute of Medical Sciences, New Delhi 110029, India  
E-mail: [tonygeorgejacob@gmail.com](mailto:tonygeorgejacob@gmail.com)

Copyright © 2023. Anatomy & Cell Biology

This is an Open Access article distributed under the terms of the Creative Commons Attribution Non-Commercial License (<http://creativecommons.org/licenses/by-nc/4.0/>) which permits unrestricted non-commercial use, distribution, and reproduction in any medium, provided the original work is properly cited.

the pre-swing phase of gait [6, 9]. The absence or degeneration of lumbricals can result in the extension of the metatarsophalangeal joint and flexion of interphalangeal joints. This can result in clawed toes [6, 10]. In tibial nerve injuries and Charcot-Marie-Tooth disease, which is a hereditary motor-sensory neuropathy, clawing of toes is commonly seen [1]. However, there are very few reports of morphological variations and degeneration of the foot lumbricals. Here, we report our findings of degenerated lumbricals in otherwise normal feet of cadavers.

### Materials and Methods

This was an observational study during routine dissection of cadavers for the teaching of anatomy to undergraduate and postgraduate students in the Department of Anatomy. We studied the lumbricals in 20 male and 8 female cadavers that were 60–80 years of age at the time of death (Table 1) and had been preserved in 10% formalin solution. During the dissection of the sole as per the instructions in the manual dissection, the lumbrical muscles were carefully dissected

out, observed, and isolated [3]. They were then traced to their tendon and we also noted their attachments, course, and the morphological appearance of the lumbricals. Samples were taken from apparently degenerated lumbrical muscles for histopathological examination. Both normal lumbrical muscle and degenerated lumbrical muscle samples were processed for paraffin-embedding, sectioning, and staining [11]. To observe microscopic changes, staining of the sections was done by hematoxylin and eosin, and to confirm degenerating changes Masson's trichrome (MT) staining technique was used [11].

### Results

Of the 224 lumbricals studied, we found four visibly degenerated lumbricals in two male cadavers. In the first cadaver (male, aged 65 years at the time of death), the 2nd and 4th lumbricals in the left foot and 2nd in the right foot (Fig. 1A, B) were degenerated in appearance- pale and fibrous instead of brown. In the second cadaver (male, aged 68 years at the time of death), the right fourth lumbrical was degenerated (Fig. 1C, D).

On light microscopic examination of hematoxylin and eosin stained sections of the normal lumbrical muscle, we observed striated muscle tissue that was arranged in a series of fascicles and the individual muscle fibres had numerous peripheral nuclei (Fig. 2A, B). In the MT stained sections, the muscle fibres appeared to be bright red, the endomysium and perimysium appeared to be green and the peripheral nuclei in the muscle fibres were dark blue in colour (Fig. 3A, B). On examining the degenerated muscle tissue, we observed that it was made of bundles of collagen fibres that were aligned parallel to the skeletal muscle fibres (Fig. 2C, D). On MT-stained sections, the fibrous bundles appeared green (Fig. 3C, D); whereas, some of the fibres that were seen among them stained red.

### Discussion

In the present study, we found four apparently degenerated lumbricals in two male cadavers aged 65 years and 68 years, respectively that on microscopy revealed replacement of striated muscle fibres with collagenous fibrous tissue.

Skeletal muscle atrophy occurs due to various reasons like disuse, aging, starvation, and cachexia in several diseases [12]. It is evident by the replacement of the striated muscle fibres

Table 1. Demographic data of cadavers

No.	Sex	Age (yr)	Right				Left			
			1st L	2nd L	3rd L	4th L	1st L	2nd L	3rd L	4th L
1	M	65	1	Deg	2	2	1	Deg	2	Deg
2	M	68	1	2	2	Deg	1	2	2	2
3	M	67	1	2	2	2	1	2	2	2
4	F	72	1	2	2	2	1	2	2	2
5	F	79	1	2	2	2	1	2	2	2
6	F	78	1	2	2	2	1	2	2	2
7	M	74	1	2	2	2	1	2	2	2
8	M	70	1	2	2	2	1	2	2	2
9	M	75	1	2	2	2	1	2	2	2
10	M	72	1	2	2	2	1	2	2	2
11	M	65	1	2	2	2	1	2	2	2
12	M	71	1	2	2	2	1	2	2	2
13	M	73	1	2	2	2	1	2	2	2
14	F	80	1	2	2	2	1	2	2	2
15	M	78	1	2	2	2	1	2	2	2
16	M	70	1	2	2	2	1	2	2	2
17	F	75	1	2	2	2	1	2	2	2
18	M	79	1	2	2	2	1	2	2	2
19	F	66	1	2	2	2	1	2	2	2
20	M	75	1	2	2	2	1	2	2	2
21	M	76	1	2	2	2	1	2	2	2
22	F	60	1	2	2	2	1	2	2	2
23	M	77	1	2	2	2	1	2	2	2
24	M	80	1	2	2	2	1	2	2	2
25	M	65	1	2	2	2	1	2	2	2
26	F	75	1	2	2	2	1	2	2	2
27	M	75	1	2	2	2	1	2	2	2
28	M	74	1	2	2	2	1	2	2	2

M, male; F, female; L, lumbrical; 1, unipennate; 2, bipennate; Deg, degenerated.

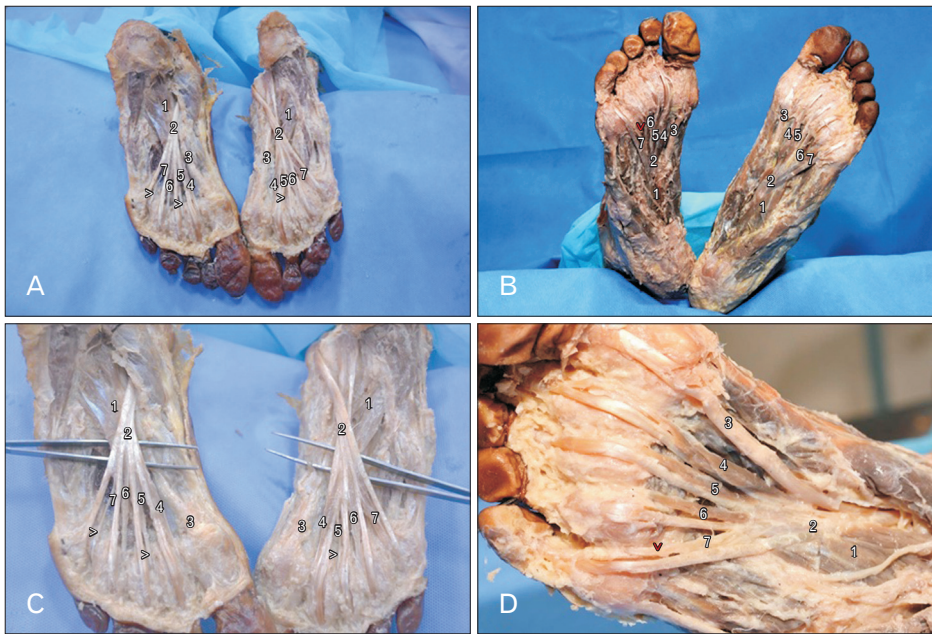


Fig. 1. Photographs of lumbricals of the foot showing: (A) degenerated 2nd and 4th lumbricals in the left and 2nd lumbrical in the right foot; (B) enlarged view of (A) showing degenerated 2nd and 4th lumbricals in the left and 2nd lumbrical in the right foot; (C) the degenerated fourth lumbrical of the right foot and normal lumbricals in the left foot; and (D) enlarged view of the right foot of (C) showing degenerated fourth lumbrical. 1, flexor accessorius; 2, tendon of flexor digitorum longus; 3, tendon of flexor hallucis longus; 4, first lumbrical; 5, second lumbrical; 6, third lumbrical; 7, fourth lumbrical; >, degenerated lumbrical.

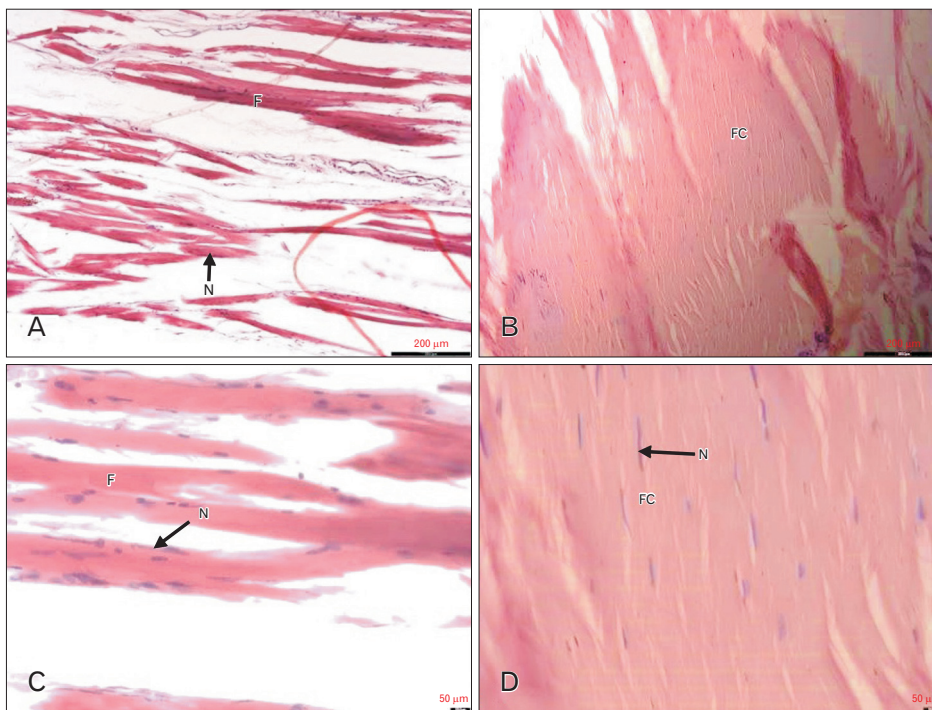
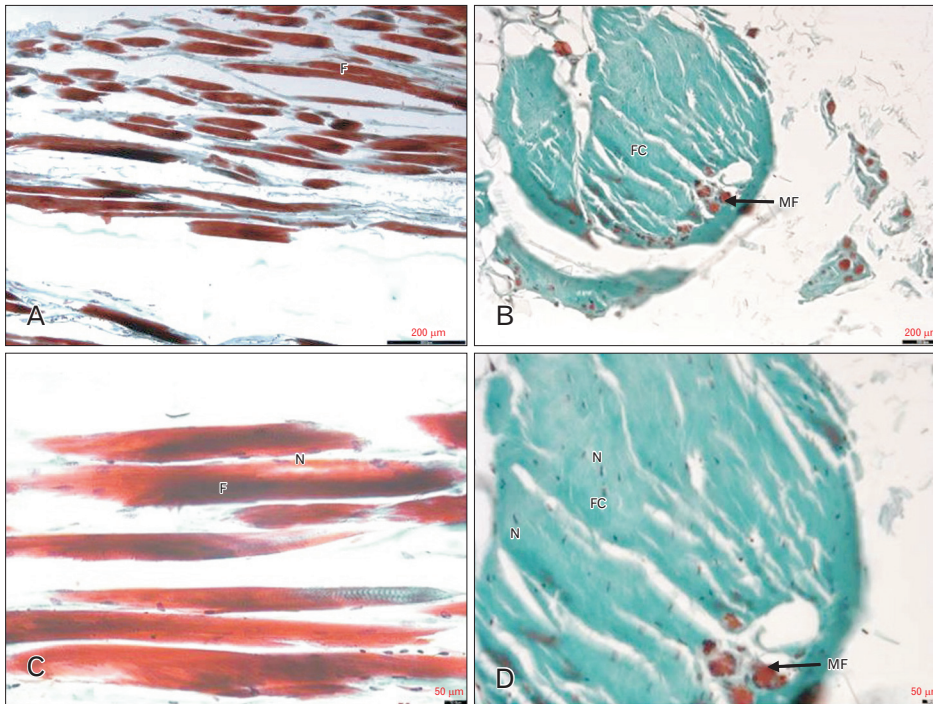


Fig. 2. The photomicrographs of longitudinally sectioned lumbrical muscles, stained with hematoxylin and eosin, showing: (A) normal lumbrical muscle at low power (10 $\times$ ); (B) normal lumbrical muscle at high power (40 $\times$ ); (C) degeneration of lumbrical muscle at low power (10 $\times$ ); and (D) degeneration of lumbrical muscle at high power (40 $\times$ ). Scale bars=200  $\mu$ m (A, C); scale bars=50  $\mu$ m (B, D). F, muscle fascicle; N, nucleus; FC, fascicle of collagen fibers.

by collagen fibres. As we saw in our study, collagen fibres on staining with the Masson's trichrome method take up the colour of the counterstain- neutral green or methylene blue [11]. The degeneration of lumbrical muscles may be due to compression of the branches of the lateral plantar nerve (LPN) that supply the lumbricals. There also could be space-occupying lesion along the course of the LPN- including ganglia,

bone tumours, aneurysm of arteries, and joint abnormalities, or even tenosynovitis, which may cause compression of LPN [1, 13]. The branches of LPN may also be injured due to stress in a hypermobile pronating foot [14].

There are a few reports on the morphological variation of foot lumbricals. Chaney et al. [10], dissected 257 limbs, and all four lumbricals were present in only 54.5% of limbs.



**Fig. 3.** The photomicrographs of longitudinally sectioned lumbrical muscles, stained with Masson's trichrome technique, showing: (A) normal lumbrical muscle at low power (10×); (B) normal lumbrical muscle at high power (40×); (C) degeneration of lumbrical muscle at low power (10×); and (D) degeneration of lumbrical muscle at high power (40×). Scale bars=200 μm (A, C), scale bars=50 μm (B, D). F, muscle fascicle; N, nucleus; FC, fascicle of collagen fibres; MF, muscle fibres.

There were no lumbricals in 3.3% of the feet studied; one lumbrical only in 3.5%, two lumbricals in 12.1% and three in 27.2% [10]. In most of the studies, the third and fourth lumbricals were most often absent in the foot [15]. However, these authors have not reported any neural, bony or joint related anomalies in the feet that they had studied.

In conclusion, degeneration of the lumbricals is a rare phenomenon. However, the detection of a degenerated lumbrical should instigate the surgeon to look for causes of compression of the branches of the LPN that supply the lumbricals in the foot.

## ORCID

Hare Krishna: <https://orcid.org/0000-0002-0683-0377>

Rati Tandon: <https://orcid.org/0000-0002-0018-9793>

Tony George Jacob: <https://orcid.org/0000-0003-1812-4805>

## Author Contributions

Conceptualisation: HK, RT, TGJ. Data acquisition: HK, RT. Data analysis or interpretation: HK, RT, TGJ. Drafting of the manuscript: HK, RT. Critical revision of the manuscript: TGJ. Approval of the final version of the manuscript: all authors.

## Conflicts of Interest

No potential conflict of interest relevant to this article was reported.

## Funding

None.

## Acknowledgements

We thank the relatives of all the persons who donated their precious bodies for educational and research purposes.

## References

1. Standring S. Gray's anatomy: the anatomical basis of clinical practice. 42nd ed. Elsevier; 2021. p. 979, 1458, 1462.
2. Malhotra A, Kulesza R. A case report of an accessory flexor digitorum profundus indicis contributing the first lumbrical. *Anat Cell Biol* 2022;55:390-3.
3. Koshi R. Cunningham's manual of practical anatomy. Volume 1, Upper and lower limbs. 16th ed. Oxford University Press; 2017. p. 248-52.
4. Hur MS, Kim JH, Gil YC, Kim HJ, Lee KS. New insights into the origin of the lumbrical muscles of the foot: tendinous slip of the flexor hallucis longus muscle. *Surg Radiol Anat*

- 2015;37:1161-7.
5. Sinнатamby CS. Last's anatomy: regional and applied. 12th ed. Churchill Livingstone; 2011. p. 163.
  6. Shawn Allen DC, Dabco IFW, Robert Lardner PT. The importance of the lumbricals [Internet]. Dynamic Chiropractic; 2008 Apr 8 [cited 2022 Aug 22]. Available from: <https://www.dynamicchiropractic.com/mpacms/dc/article.php?id=53168>.
  7. Fiolkowski P, Brunt D, Bishop M, Woo R, Horodyski M. Intrinsic pedal musculature support of the medial longitudinal arch: an electromyography study. *J Foot Ankle Surg* 2003;42:327-33.
  8. Okamura K, Kanai S, Oki S, Tanaka S, Hirata N, Sakamura Y, Idemoto N, Wada H, Otsuka A. Does the weakening of intrinsic foot muscles cause the decrease of medial longitudinal arch height? *J Phys Ther Sci* 2017;29:1001-5.
  9. Kalin PJ, Hirsch BE. The origins and function of the interosseous muscles of the foot. *J Anat* 1987;152:83-91.
  10. Chaney DM, Lee MS, Khan MA, Krueger WA, Mandracchia VJ, Yoho RM. Study of ten anatomical variants of the foot and ankle. *J Am Podiatr Med Assoc* 1996;86:532-7.
  11. Drury RAB, Wallington EA. Carleton's histological technique. 5th ed. Oxford University Press; 1980. p. 57-149, 183-5.
  12. Jackman RW, Kandarian SC. The molecular basis of skeletal muscle atrophy. *Am J Physiol Cell Physiol* 2004;287:C834-43.
  13. Peri G. The "critical zones" of entrapment of the nerves of the lower limb. *Surg Radiol Anat* 1991;13:139-43.
  14. Schon LC, Baxter DE. Neuropathies of the foot and ankle in athletes. *Clin Sports Med* 1990;9:489-509.
  15. Bejjani FJ, Jahss MH. Le Double's study of muscle variations of the human body. Part II: muscle variations of the foot. *Foot Ankle* 1986;6:157-76.