



# Surgical Resection of Neurogenic Heterotopic Ossification around Hip Joint in Stroke Patients: A Safety and Outcome Report

Jae-Young Beom, MD, WengKong Low, MD\*, Kyung-Soon Park, MD, PhD,  
Taek-Rim Yoon, MD, PhD, Chan Young Lee, MD, Hyeongmin Song, MD

*Department of Orthopedic Surgery, Chonnam National University Hwasun Hospital,  
Chonnam National University Medical School, Hwasun, Korea  
Orthopaedic and Traumatology Department, Hospital Kuala Lumpur, Kuala Lumpur, Malaysia\**

**Purpose:** Resection remains the most reliable treatment for established heterotopic ossification, despite questions regarding its effectiveness due to the potential for complications. This study evaluated the clinical outcomes and complications of neurogenic heterotopic ossification (NHO) resection in stroke patients' ankylosed hips.

**Materials and Methods:** We retrospectively analyzed nine hip NHO resections performed on seven patients from 2010 to 2018. The pre- and postoperative range of motion of the operated hip were compared. Analysis of postoperative complications, including infection, recurrence, iatrogenic fracture, and neurovascular injury was performed.

**Results:** The mean operative time was  $132.78 \pm 21.08$  minutes, with a mean hemoglobin drop of  $3.06 \pm 0.82$  g/dL within the first postoperative week. The mean duration of postoperative follow-up was  $52.08 \pm 28.72$  months for all patients. Postoperative range of motion showed improvement from preoperative. Flexion and external rotation (mean,  $58.89 \pm 30.60^\circ$  and  $16.67 \pm 18.03^\circ$ , respectively) showed the greatest gain of motion of the operated hip joint. Postoperative infections resolved in two cases through surgical debridement, and one case required conversion to total hip arthroplasty due to instability. There were no recurrences, iatrogenic fractures, or neurovascular injuries.

**Conclusion:** Resection is a beneficial intervention for restoring the functional range of motion of the hip in order to improve the quality of life for patients with NHO and neurological disorders. We recommend performance of a minimal resection to achieve a targeted functional arc of motion in order to minimize the risk of postoperative complications.

**Key Words:** Heterotopic ossification, Hip joint, Stroke, Neurogenic arthropathy

**Submitted:** January 10, 2023 **1st revision:** April 20, 2023

**2nd revision:** May 31, 2023 **3rd revision:** June 14, 2023

**Final acceptance:** June 15, 2023

**Address reprint request to**

**Kyung-Soon Park, MD, PhD**

(<https://orcid.org/0000-0002-5036-1803>)

Department of Orthopaedic Surgery, Chonnam National University  
Hwasun Hospital, Chonnam National University Medical School,  
322 Seoyang-ro, Hwasun-eup, Hwasun 58128, Korea

**TEL:** +82-62-670-9475

**E-mail:** [chiasma@hanmail.net](mailto:chiasma@hanmail.net)

Jae-Young Beom and WengKong Low contributed equally to this study as co-first authors.

This is an Open Access article distributed under the terms of the Creative Commons Attribution Non-Commercial License (<http://creativecommons.org/licenses/by-nc/4.0>) which permits unrestricted non-commercial use, distribution, and reproduction in any medium, provided the original work is properly cited.

## INTRODUCTION

Neurogenic heterotopic ossification (NHO), which is characterized by aberrant formation of ectopic bone in the soft tissue, typically around a joint, occurs in patients who have sustained neurological trauma. NHO includes central nervous system damage, which is most common in cases of traumatic brain or spinal cord injury, with an incidence rate for NHO of 20-30%<sup>1-5</sup>. Atraumatic insults to the central nervous system associated with pathogenesis of NHO include cerebrovascular accident, cerebral anoxia, and brain tumors<sup>2,6-8</sup>. However, occurrence of NHO is rare in stroke patients; Varghese reported an incidence of 0.5-1.2%<sup>9</sup>, however, a recent multicenter cross-sectional study of 17,794 stroke patients conducted in 2019 by Cunha et al.<sup>10</sup> reported that the incidence of clinically and radiologically apparent NHO was 1.3% during a 10-year period. Risk factors for NHO in this patient group include hemorrhagic or hemorrhagic deformable ischemic stroke, severity of early neurological lesions, and spasmodic and cognitive impairment<sup>7,10</sup>.

The hip joint is most commonly affected by NHO<sup>2,11</sup>, followed by NHO in other large joints<sup>12,13</sup>. Patients generally develop fever, pain, swelling, and erythema around the affected joint and, if untreated, these symptoms can progress to an established heterotopic ossification (HO) that can lead to joint stiffness or even ankylosis wherein the stiff or ankylosed hip joint is fixed in a non-functional position, which can impede nursing care, including hygiene care and obtaining a stable sitting posture. In advanced cases, NHO can lead to development of ulcers that can have additional adverse effects on the patients' quality of life.

Despite various surgical complications, including excessive bleeding, infection, recurrence, binary fractures, and neurovascular damage, resection remains the only proven treatment for NHO<sup>5,6,14-17</sup>. Thus there are questions regarding the appropriateness of resection in management of NHO. The aim of this study was to evaluate the clinical outcome and safety of resection of ankylosed hip NHO in stroke patients.

## MATERIALS AND METHODS

### 1. Participants

This study was approved by the Institutional Review Board (IRB) of Chonnam National University Hwasun Hospital (IRB No. CNUHH-2022-232). The written informed con-

sent was waived by the IRB due to the retrospective nature of the study. This retrospective single-center cross-sectional study was conducted in order to examine the clinical outcomes and complications of surgical treatment of NHO performed at Chonnam National University Hwasun Hospital from 2010 to 2018. Patients who underwent resection of NHO that occurred after a cerebrovascular accident were included. Our surgical indications were patients who met both of the following conditions: (1) Patients with difficulty in wheelchair ambulation or perineal hygiene care because of an ankylosed hip due to HO, (2) HO is matured. The diagnosis was based on evidence of simple radiographic appearance following exoskeleton formation. A preoperative computed tomography (CT) scan with three-dimensional (3D) reconstruction was used for comprehensive surgical planning, followed by surgical resection of the exoskeleton.

### 2. Operative Method

All operations were performed by one of the two senior hip surgeons in Chonnam National University Hwasun Hospital. A thorough review of the CT scan was performed by the operating surgeon in order to determine the surgical approach. A Smith-Peterson approach was used in all cases included in this study. The hip joint capsule was preserved as much as possible. Differentiation from normal bone was sometimes impossible due to matured ectopic bone. Therefore, an image intensifier was used to guide the resection, which was halted after the desired functional range of motion had been obtained. Repair of the joint capsule was performed in cases of an unintentional breach. A negative-pressure drain was inserted in all cases to reduce the risk of postoperative hematoma formation. Postoperative monitoring of the hemoglobin level was performed.

For prevention of recurrence, adjuvant radiation therapy was performed within 24 hours after the operation if available. Patients also took etidronate or non-steroidal anti-inflammatory drugs (NSAIDs) medication postoperatively.

### 3. Follow-up

The patients were observed during follow-up, after the first and third months after discharge, and every six months thereafter. The range of motion was recorded during follow-up, and a plain radiograph of the hip was obtained to monitor for recurrence of HO.

#### 4. Evaluation Methods

The following data were extracted from the electronic medical records of each patient: age, sex, side, location of NHO, severity of NHO according to Brooker grading<sup>18)</sup>, previous history of the hip joint on the affected side such as history of other disease or operation, interval from time of neurological insult to time of resection surgery, and operation-related details, including operating surgeon, surgical approach used, duration of operation, and the maximum hemoglobin decrease within the first postoperative week. The pre- and postoperative range of motion of the operated hip were compared for determination of the clinical outcome and all postoperative complications were documented. Statistical analysis was performed using IBM SPSS Statistical software (ver. 25; IBM), and  $P < 0.05$  was considered statistically significant. A comparison of range of motion between the preoperative and postoperative period was performed using a Mann–Whitney test.

#### RESULTS

From 2010 to 2018, nine hip NHO resections were performed in seven patients (all patients were male); four resections were performed on the right hip and five on the left hip. The mean age of patients in our series was  $51.44 \pm 9.42$  years. All nine hip NHOs occurred after a cerebrovascular accident and none of the patients had previous history such as history of other disease or operation for the hip joint on the affected side. The mean duration of follow-up was  $52.08 \pm 28.72$  months. The mean interval from the cerebrovascular accident to NHO surgery was  $36.27 \pm 25.61$  months. According to the Brooker classification for HO, three cases of NHO were graded as Class III and six cases were graded as Class IV<sup>18)</sup>. Regarding the location of the ectopic bone, all NHOs occurred at the anterior aspect of the hip along the iliopsoas muscle, and additional NHO was detected at the lateral aspect of the hip along the gluteus medius in one case. Details regarding the demographic distribution are shown in Table 1.

In the preoperative physical examination, only a limited range of motion of less than  $30^\circ$  in all motions of the hip joint was observed in seven out of nine cases. Ambulation was only possible in one case. Details regarding the preoperative range of motion and ambulation status are shown in Table 2.

CT scan images obtained preoperatively and plain radiographs obtained after sequential excision surgery in a rep-

resentative case are shown in Fig. 1.

The mean operative time for NHO surgery was  $132.78 \pm 21.08$  minutes. The hemoglobin drop in the postoperative period was  $3.06 \pm 0.82$  g/dL in the first week. The amount of preoperative transfusion of packed red cells (PRC) was  $3.89 \pm 2.71$  packs, and one pack of PRC was 320 mL. The amount of heterotopic bone removed intraoperatively was  $225.89 \pm 67.30$  g. To prevent recurrence after the operation, all patients took NSAIDs medication per oral. In addition, radiation therapy was administered in two patients, two patients took etidronate medication per oral, two patients received both, and three patients did not receive either one. Detailed postoperative information is shown in Table 3.

The pre- and postoperative range of motion of the operated hip were compared in order to determine the primary outcome of our study. Details regarding the postoperative range of motion are shown in Table 4. Improvement of the total range of motion to  $153.89 \pm 38.14^\circ$  was observed postoperatively. The range of motion before and after surgery differed significantly, except for abduction range. Flexion and external rotation showed the most significant gains in range of motion, with mean improvements of  $58.89 \pm 30.60^\circ$  and  $16.67 \pm 18.03^\circ$ , respectively. This improved functional range of motion was particularly important for achievement of a stable sitting posture as well as for perineal hygiene care. Results on the improvement in the range of motion are shown in Table 5.

There were two cases of postoperative infection in our cohort. The first patient presented with wound dehiscence and oozing after transfer to the ward in the initial postoperative period. The hematoma was identified based on a CT scan (Fig. 2). The second patient presented with late erythema and swelling during subsequent follow-up, and a CT scan confirmed abscess formation with gas at the NHO resection site. In both cases, resolution of the complications was achieved after surgical debridement with insertion of a negative pressure drain and a short course of systemic antibiotics.

In addition, this cohort included one case of late joint instability and subluxation in a patient with relatively few limitations in the range of hip joint motion who was able to stand up with use of a walker during the preoperative physical examination. Despite the initial improvement in range of motion, the patient complained of slowly progressing pain over the operated hip. Progressive subluxation and osteoarthritic changes of the hip were observed on serial plain radiography during the follow-up. The patient underwent a total hip replacement surgery nine years after the initial NHO surgery, which resulted in resolution of the symptoms. There

**Table 1.** Demographic Distribution of NHO Patients

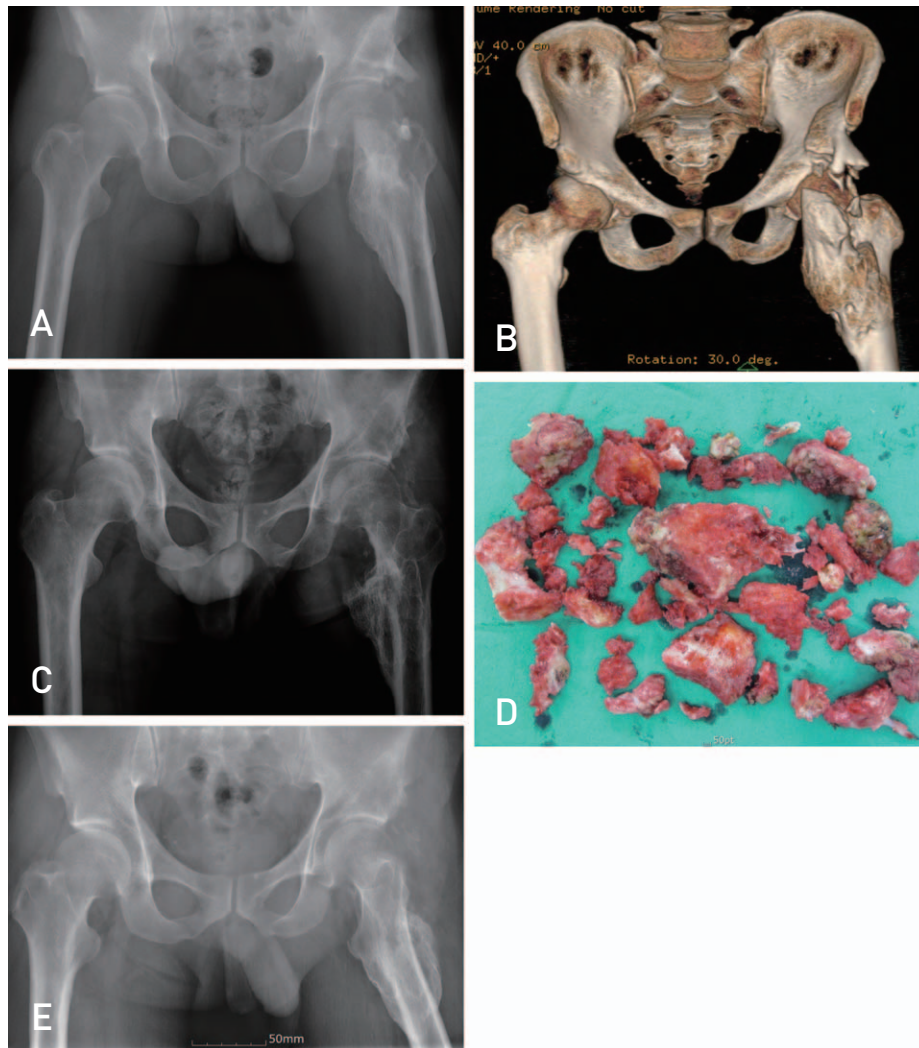
Case No.	Sex	Age (yr)	Side	Cause	PHx of affected side hip joint	Follow-up duration (mo)	Interval to operation (mo)	Brooker classification	HO location	Surgical approach
1	M	47	R	CVA	None	56.30	48.73	IV	Iliopsoas and gluteus medius	Smith-Peterson
2	M	47	L	CVA	None	58.87	46.17	III	Iliopsoas	Smith-Peterson
3	M	61	R	CVA	None	40.23	11.37	IV	Iliopsoas	Smith-Peterson
4	M	61	L	CVA	None	33.33	18.27	IV	Iliopsoas	Smith-Peterson
5	M	42	L	CVA	None	24.60	92.47	III	Iliopsoas	Smith-Peterson
6	M	36	L	CVA	None	122.77	31.97	IV	Iliopsoas	Smith-Peterson
7	M	37	R	CVA	None	52.50	44.87	IV	Iliopsoas	Smith-Peterson
8	M	48	L	CVA	None	39.10	16.27	IV	Iliopsoas	Smith-Peterson
9	M	64	R	CVA	None	41.00	16.33	III	Iliopsoas	Smith-Peterson
Mean		51.44±9.42				52.08±28.72	36.27±25.61			

NHO: neurogenic heterotopic ossification, M: male, R: right, L: left, CVA: cerebrovascular accident, PHx: past history, HO: heterotopic ossification.

**Table 2.** Preoperative ROM and Ambulation Status of NHO Patients

Case No.	Flexion (°)	Extension (°)	Internal rotation (°)	External rotation (°)	Abduction (°)	Adduction (°)	Total ROM (°)	Ambulation status
1	30	-30	-20	20	0	0	0	Wheelchair
2	30	-30	0	0	0	0	0	Wheelchair
3	10	-10	0	0	5	5	10	Bed-ridden
4	0	0	0	0	5	5	10	Bed-ridden
5	70	0	0	10	20	5	105	Ambulation with support
6	20	-20	0	0	0	0	0	Bed-ridden
7	60	-30	10	0	10	0	50	Wheelchair
8	30	-30	-30	30	15	-15	0	Wheelchair
9	30	0	0	40	30	0	105	Wheelchair

ROM: range of motion, NHO: neurogenic heterotopic ossification.



**Fig. 1.** (A, B) Preoperative plain radiograph and computed tomography scan of a stroke patient with left hip neurogenic heterotopic ossification. (C, D) Immediate operation plain radiograph and clinical photo of removed heterotopic ossification. (E) Follow-up plain radiograph taken one year after surgery.

were no cases of recurrence, iatrogenic fracture, or neurovascular injury in our cohort.

## DISCUSSION

Although extensive study has been conducted in recent years, the precise pathophysiology underlying the development of NHO remains unclear<sup>15,19</sup>, despite growing evidence of the induction of HO via the release of osteoconductive factors, produced by a complex interface between local and systemic conditions that includes the autonomous nervous system and inflammatory responses<sup>20,21</sup>. There is still no effective preventive intervention for NHO despite the use of a few widely accepted prophylactic methods, including NSAIDs, such as indomethacin and celecoxib<sup>22</sup>, and radi-

ation therapy<sup>23,24</sup>. There are questions regarding the effectiveness of prophylactic treatments, and there is considerable variation in the dosage and dosing interval used in different centers.

In patients with established NHO, the limitation of the range of motion of the hip joint can have adverse effects on the patient's quality of life, causing many difficulties in daily life. Thus far the only effective treatment is resection or total hip arthroplasty<sup>3,10,14,25</sup>, which, although efficient in recovery of motion in the NHO-involved hip joint, is technically demanding and is associated with a high risk of complications that include excessive bleeding, recurrence, infection, iatrogenic fracture, and neurovascular injuries<sup>17</sup>.

The earliest incidence of infection following NHO resection was reported by Garland and Orwin<sup>16</sup> in 1989, where-

**Table 3.** Intraoperative and Postoperative Information of NHO Patients

Case No.	Operation time (min)	Hemoglobin drop (g/dL)	PRC transfusion (pack)	Resection amount (g)	Postop RT	Postop etidronate	Postop NSAIDs	Complication
1	105	3.3	6	320	Yes	Yes	Yes	None
2	120	2.5	0	190	Yes	Yes	Yes	None
3	165	2.9	8	220	No	Yes	Yes	Infection
4	140	3	7	180	No	No	Yes	None
5	160	3.1	2	170	No	No	Yes	None
6	145	1.5	4	260	Yes	No	Yes	None
7	125	3.4	4	310	Yes	No	Yes	Instability
8	125	4.6	1	263	No	No	Yes	Infection
9	110	3.2	3	120	No	Yes	Yes	None
Mean	132.78±21.08	3.06±0.82	3.89±2.71	225.89±67.30				

NHO: neurogenic heterotopic ossification, PRC: packed red cells, Postop: postoperative, RT: radiation therapy, NSAIDs: non-steroidal anti-inflammatory drugs.

**Table 4.** Postoperative ROM of NHO Patients

Case No.	Flexion (°)	Extension (°)	Internal rotation (°)	External rotation (°)	Abduction (°)	Adduction (°)	Total ROM (°)
1	100	0	10	30	10	20	170
2	110	0	10	30	10	20	180
3	90	0	10	30	30	15	185
4	90	0	5	30	30	15	180
5	120	0	10	40	30	10	315
6	100	0	0	30	20	0	150
7	60	0	10	10	0	5	135
8	90	0	5	10	5	5	115
9	50	0	10	40	30	0	230

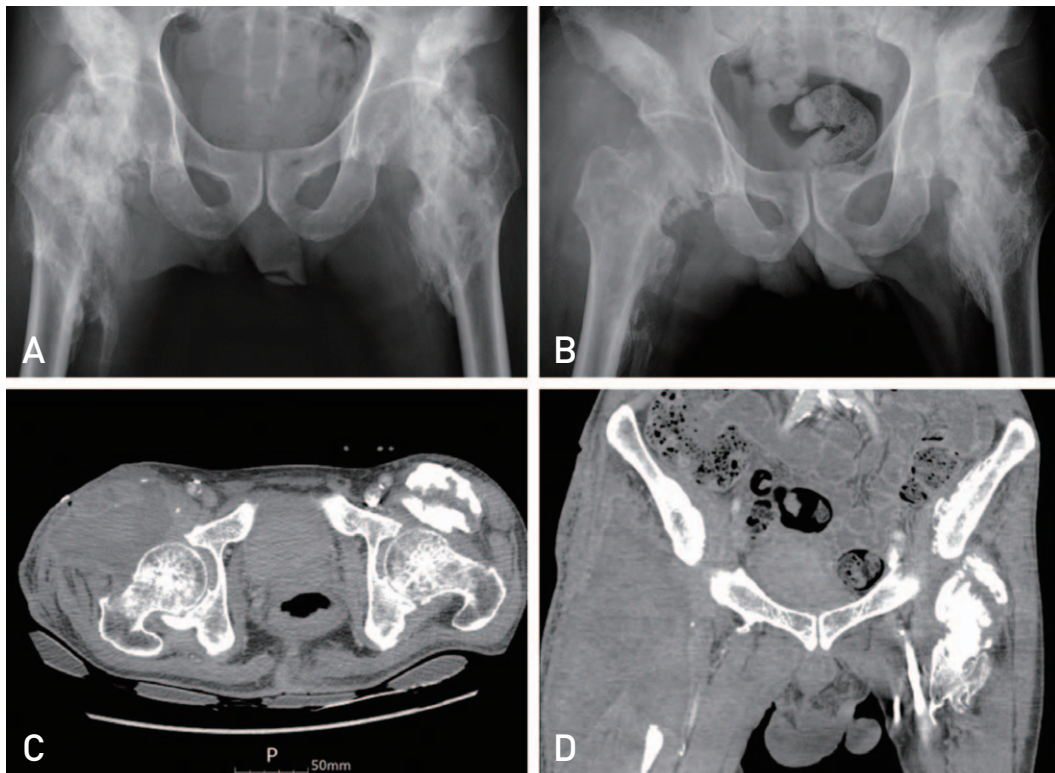
ROM: range of motion, NHO: neurogenic heterotopic ossification.

**Table 5.** Improvement in ROM of NHO Patients

	Preoperative	Postoperative	Improvement	P-value
Flexion (°)	31.11±22.05	90.00±22.36	58.89±30.60	0.000
Extension (°)	-16.67±14.14	0.00±0.00	16.67±14.14	0.014
Internal rotation (°)	-4.44±12.36	7.78±3.63	12.22±12.28	0.004
External rotation (°)	11.11±15.37	27.78±10.93	16.67±18.03	0.024
Abduction (°)	9.44±10.44	18.33±12.25	8.89±13.41	0.136
Adduction (°)	0.00±6.12	10.00±7.91	10.00±8.29	0.019
Total ROM (°)	30.56±43.76	184.44±58.97	153.89±38.14	0.000

The P-values are of inter-group comparisons, with  $P < 0.05$  indicating significance.

ROM: range of motion, NHO: neurogenic heterotopic ossification.



**Fig. 2.** (A) Preoperative plain radiograph of a stroke patient with bilateral hip neurogenic heterotopic ossification. (B) Immediate operation plain radiograph. (C, D) Computed tomography scan performed two weeks after surgery showing hematoma formation.

in superficial or deep infection was detected postoperatively in 79% (19 out of 24) of operated hips. Two studies by Stover et al.<sup>26)</sup> and Meiners et al.<sup>5)</sup> reported postoperative infection rates of 9% and 12% in 42 and 41 hips, respectively. A more recent study by Gatin et al.<sup>4)</sup> in 2017 reported an overall postoperative infection rate of 10%, of which 22% of cases occurred in patients with spinal cord injury and 5% in patients with other causes of NHO. We observed a rate of postoperative infection of 22% in our study group, which is comparable to those reported by other authors.

Postoperative recurrence of HO is a problematic complication for the patients and can be worrisome for the treating surgeon. Garland and Orwin<sup>16)</sup> reported a recurrence rate of 86% in their study conducted in 1989, whereas Almagour et al.<sup>14)</sup> reported a much lower recurrence rate of 5.6% in their more recent study conducted in 2016. This wide range is the result of a lack of consensus on the definition of recurrence<sup>14)</sup>. Waiting for the ectopic bone to mature prior to resection by monitoring the patient's symptoms and the serial plain radiography is the common practice. Alternatively,

bone scintigraphy, a sensitive examination for detecting HO, which is widely accepted as an effective method for determining the maturity of the ectopic bone, can facilitate planning of the excision timing<sup>27,28</sup>). However, according to findings from recent studies, the risk of recurrence is independent of the timing of surgery<sup>6,14,29</sup>). Early performance of an operation is feasible, and surgery should not be unduly delayed while waiting to observe a “cold” lesion on bone scintigraphy. In our series, bone scintigraphy was not performed to determine the maturity of the NHO, and resection was planned and performed as soon as NHO had caused significant functional interference in posture or the nursing process for the patient.

Nevertheless, development of a clear goal for each patient before the surgical removal of NHO is important. The targeted range of motion that should be achieved during the resection surgery should be determined by the operating surgeon. Thorough preoperative planning based on CT scans can guide the surgeon with regard to the target amount of ectopic bone to be removed to obtain the range of motion required for achievement of functional improvement. A complete resection of all ectopic bones, as used in the oncological approach, unnecessarily increases morbidity without additional advantage to the patient and should therefore be avoided<sup>15</sup>). Besides increasing the risk of bleeding, the resulting larger dead space can lead to hematoma formation and increased risk of infection. In addition, there may also be a risk of iatrogenic fracture or joint instability.

One case of late instability following NHO resection that eventually required a total hip replacement was identified in our cohort. We believe that the instability was a result of overzealous removal of ectopic bone, as matured ectopic bone is indistinguishable from the underlying normal bone<sup>3</sup>). Under the guidance of the image intensifier, assessment of the intraoperative range of motion by the operating surgeon is important, and resection should be halted when the desired range of motion has been achieved.

No cases of recurrence, iatrogenic fracture, or neurovascular injury were observed in our study group, which we attribute to use of meticulous surgical technique and conduct of detailed preoperative planning for each patient. It is interesting to note that our cohort includes two stroke patients with bilateral hip NHO. Development of NHO on the non-paretic side was uncommon and was barely discussed in case reports<sup>30</sup>), until a recent study published in 2019, wherein Cunha et al.<sup>10</sup>) reported an incidence of bilateral NHO of 0.2% in 17,794 stroke patients who were included in their study. In our study, to minimize the risk of exces-

sive intraoperative bleeding, resection of bilateral hip NHO was performed in a sequential setting with an interval of 3-6 months.

One limitation of this study is the relatively small sample size, which can be attributed in part to the retrospective study design, as some of the patient data were missing and some patients were lost to follow-up. However, because only a few studies on NHO resection in stroke patients have been reported, we believe that the results of this study provide a framework for designing future studies and will be helpful in determining the policy for treating rare cases of NHO in stroke patients.

## CONCLUSION

In conclusion, NHO resection in stroke patients is a beneficial and effective surgery for recovering functional range of motion of the hip and improving quality of life in patients with neurological disorders. To minimize the potential risk of operative complications, we recommend performance of a minimal resection surgery to achieve the desired functional range of motion over a complete removal of the ectopic bone.

## FUNDING

No funding to declare.

## CONFLICT OF INTEREST

No potential conflict of interest relevant to this article was reported.

## ORCID

Jae-Young Beom (<https://orcid.org/0000-0002-2984-3429>)  
WengKong Low (<https://orcid.org/0000-0002-4149-6722>)  
Kyung-Soon Park (<https://orcid.org/0000-0002-5036-1803>)  
Taek-Rim Yoon (<https://orcid.org/0000-0001-8282-1723>)  
Chan Young Lee (<https://orcid.org/0000-0002-1394-0902>)  
Hyeongmin Song (<https://orcid.org/0000-0003-0817-3646>)

## REFERENCES

1. Shehab D, Elgazzar AH, Collier BD. *Heterotopic ossification*. *J Nucl Med*. 2002;43:346-53.
2. Cipriano CA, Pill SG, Keenan MA. *Heterotopic ossification following traumatic brain injury and spinal cord injury*. *J Am Acad Orthop Surg*. 2009;17:689-97. <https://doi.org/10.5435/00124635-200911000-00003>



3. Brady RD, Shultz SR, McDonald SJ, O'Brien TJ. *Neurological heterotopic ossification: current understanding and future directions*. *Bone*. 2018;109:35-42. <https://doi.org/10.1016/j.bone.2017.05.015>
4. Gatin L, Genêt F, Dinh A, Denormandie P. *Postoperative infections after excision of neurogenic heterotopic ossifications at the hip: risk factors and causative organisms*. *Orthop Traumatol Surg Res*. 2017;103:357-61. <https://doi.org/10.1016/j.otsr.2017.02.001>
5. Meiners T, Abel R, Böhm V, Gerner HJ. *Resection of heterotopic ossification of the hip in spinal cord injured patients*. *Spinal Cord*. 1997;35:443-5. <https://doi.org/10.1038/sj.sc.3100415>
6. Denormandie P, de l'Escalopier N, Gatin L, Grelier A, Genêt F. *Resection of neurogenic heterotopic ossification (NHO) of the hip*. *Orthop Traumatol Surg Res*. 2018;104(1S):S121-7. <https://doi.org/10.1016/j.otsr.2017.04.015>
7. Genêt F, Minooee K, Jourdan C, Ruet A, Denormandie P, Schnitzler A. *Troublesome heterotopic ossification and stroke: features and risk factors. A case control study*. *Brain Inj*. 2015;29:866-71. <https://doi.org/10.3109/02699052.2015.1005133>
8. Hajek VE. *Heterotopic ossification in hemiplegia following stroke*. *Arch Phys Med Rehabil*. 1987;68(5 Pt 1):313-4.
9. Varghese G, Williams K, Desmet A, Redford JB. *Nonarticular complication of heterotopic ossification: a clinical review*. *Arch Phys Med Rehabil*. 1991;72:1009-13. <https://doi.org/10.5555/uri:pii:0003999391901448>
10. Cunha DA, Camargos S, Passos VMA, Mello CM, Vaz LS, Lima LRS. *Heterotopic ossification after stroke: clinical profile and severity of ossification*. *J Stroke Cerebrovasc Dis*. 2019;28:513-20. <https://doi.org/10.1016/j.jstrokecerebrovasdis.2018.10.032>
11. van Kuijk AA, Geurts AC, van Kuppevelt HJ. *Neurogenic heterotopic ossification in spinal cord injury*. *Spinal Cord*. 2002;40:313-26. <https://doi.org/10.1038/sj.sc.3101309>
12. Wharton GW, Morgan TH. *Ankylosis in the paralyzed patient*. *J Bone Joint Surg Am*. 1970;52:105-12.
13. Allard MM, Thomas RL, Nicholas RW Jr. *Myositis ossificans: an unusual presentation in the foot*. *Foot Ankle Int*. 1997;18:39-42. <https://doi.org/10.1177/107110079701800108>
14. Almangour W, Schnitzler A, Salga M, Debaud C, Denormandie P, Genêt F. *Recurrence of heterotopic ossification after removal in patients with traumatic brain injury: a systematic review*. *Ann Phys Rehabil Med*. 2016;59:263-9. <https://doi.org/10.1016/j.rehab.2016.03.009>
15. de l'Escalopier N, Salga M, Gatin L, Genêt F, Denormandie P. *Resection of heterotopic ossification around the hip after trauma*. *EFORT Open Rev*. 2019;4:263-8. <https://doi.org/10.1302/2058-5241.4.180098>
16. Garland DE, Orwin JF. *Resection of heterotopic ossification in patients with spinal cord injuries*. *Clin Orthop Relat Res*. 1989;(242):169-76.
17. Macheras GA, Lepetsos P, Leonidou A, Anastasopoulos PP, Galanakos SP, Tsiroidis E. *Results from the surgical resection of severe heterotopic ossification of the hip: a case series of 26 patients*. *Eur J Orthop Surg Traumatol*. 2017;27:1097-102. <https://doi.org/10.1007/s00590-017-1980-2>
18. Brooker AF, Bowerman JW, Robinson RA, Riley LH Jr. *Ectopic ossification following total hip replacement. Incidence and a method of classification*. *J Bone Joint Surg Am*. 1973;55:1629-32.
19. Genêt F, Kulina I, Vaquette C, et al. *Neurological heterotopic ossification following spinal cord injury is triggered by macrophage-mediated inflammation in muscle*. *J Pathol*. 2015;236:229-40. <https://doi.org/10.1002/path.4519>
20. Bidner SM, Rubins IM, Desjardins JV, Zukor DJ, Goltzman D. *Evidence for a humoral mechanism for enhanced osteogenesis after head injury*. *J Bone Joint Surg Am*. 1990;72:1144-9. <https://doi.org/10.2106/00004623-199072080-00004>
21. Sullivan MP, Torres SJ, Mehta S, Ahn J. *Heterotopic ossification after central nervous system trauma: a current review*. *Bone Joint Res*. 2013;2:51-7. <https://doi.org/10.1302/2046-3758.23.2000152>
22. Baird EO, Kang QK. *Prophylaxis of heterotopic ossification - an updated review*. *J Orthop Surg Res*. 2009;4:12. <https://doi.org/10.1186/1749-799X-4-12>
23. Balboni TA, Gobeze R, Mamon HJ. *Heterotopic ossification: pathophysiology, clinical features, and the role of radiotherapy for prophylaxis*. *Int J Radiat Oncol Biol Phys*. 2006;65:1289-99. <https://doi.org/10.1016/j.ijrobp.2006.03.053>
24. Pellegrini VD Jr, Gregoritch SJ. *Preoperative irradiation for prevention of heterotopic ossification following total hip arthroplasty*. *J Bone Joint Surg Am*. 1996;78:870-81. <https://doi.org/10.2106/00004623-199606000-00010>
25. Genêt F, Jourdan C, Schnitzler A, et al. *Troublesome heterotopic ossification after central nervous system damage: a survey of 570 surgeries*. *PLoS One*. 2011;6:e16632. <https://doi.org/10.1371/journal.pone.0016632>
26. Stover SL, Niemann KM, Tulloss JR. *Experience with surgical resection of heterotopic bone in spinal cord injury patients*. *Clin Orthop Relat Res*. 1991;(263):71-7.
27. Tyler JL, Derbekyan V, Lisbona R. *Early diagnosis of myositis ossificans with Tc-99 m diphosphonate imaging*. *Clin Nucl Med*. 1984;9:256-8. <https://doi.org/10.1097/00003072-198405000-00002>
28. Drane WE. *Myositis ossificans and the three-phase bone scan*. *AJR Am J Roentgenol*. 1984;142:179-80. <https://doi.org/10.2214/ajr.142.1.179>
29. Genêt F, Ruet A, Almangour W, Gatin L, Denormandie P, Schnitzler A. *Beliefs relating to recurrence of heterotopic ossification following excision in patients with spinal cord injury: a review*. *Spinal Cord*. 2015;53:340-4. <https://doi.org/10.1038/sc.2015.20>
30. Kocaağa Z, Bal S, Gurgan A. *Hemiplegia and heterotopic ossification on the non-paretic extremity: a case report*. *J Rehabil Med*. 2007;39:500-2. <https://doi.org/10.2340/16501977-0086>