



A Comparative Study of Bipolar Hemiarthroplasty for Intertrochanteric Fracture: Direct Anterior Approach versus Conventional Posterolateral Approach

Young Yool Chung, MD, Seung-Woo Shim, MD, Min Young Kim, MD, Young-Jae Kim, MD

Department of Orthopedics, Kwangju Christian Hospital, Gwangju, Korea

Purpose: The aim of this study was to compare short-term results from use of the direct anterior approach (DAA) and the conventional posterolateral approach (PLA) in performance of bipolar hemiarthroplasty for treatment of femoral intertrochanteric fractures in elderly patients.

Materials and Methods: A retrospective review of 100 patients with intertrochanteric fractures who underwent bipolar hemiarthroplasty was conducted. The PLA was used in 50 cases from 2016 to 2019; since that time we have used the DAA in 50 cases from 2019 to 2021. Measurements of mean operative time, blood loss, hospitalization period, and ambulation status, greater trochanter (GT) migration and stem subsidence were performed. And the incidence of complications was examined.

Results: Operative time was 73.60 ± 14.56 minutes in the PLA group and 79.80 ± 8.89 minutes in the DAA group ($P < 0.05$). However, after experiencing 20 cases using DAA, there was no statistically difference in operative time between two groups ($P = 0.331$). Blood loss was 380.76 ± 180.67 mL in the PLA group and 318.14 ± 138.51 mL in the DAA group ($P < 0.05$). The hospitalization was 23.76 ± 11.89 days in the PLA group and 21.45 ± 4.18 days in the DAA group ($P = 0.207$). In both groups, there were no progressive GT migration, intraoperative fractures or dislocations, although there was one case of infection in the PLA group.

Conclusion: Although use of the DAA in performance of bipolar hemiarthroplasty required slightly more time in the beginning compared with the PLA, the DAA may well be an alternative, safe surgical technique as a muscle preserving procedure in elderly patients with intertrochanteric fractures.

Key Words: Direct anterior approach, Hemiarthroplasty, Intertrochanteric fracture

INTRODUCTION

Femoral intertrochanteric fractures are commonly seen

in the elderly population after ground level falls. The patients usually have osteoporosis with some chronic underlying disease, making management of these injuries difficult.

Submitted: March 27, 2023 1st revision: May 29, 2023
2nd revision: June 5, 2023 Final acceptance: June 7, 2023

Address reprint request to

Seung-Woo Shim, MD

(<https://orcid.org/0000-0001-6974-7151>)

Department of Orthopedics, Kwangju Christian Hospital, 37
Yangrim-ro, Nam-gu, Gwangju 61661, Korea

TEL: +82-62-650-5064

E-mail: message2u@naver.com

This is an Open Access article distributed under the terms of the Creative Commons Attribution Non-Commercial License (<http://creativecommons.org/licenses/by-nc/4.0>) which permits unrestricted non-commercial use, distribution, and reproduction in any medium, provided the original work is properly cited.

Osteosynthesis is the preferred treatment of choice for intertrochanteric fractures; however, a high failure rate was reported after osteosynthesis¹⁻³. Compared to osteosynthesis, arthroplasty could be helpful in management of elderly patients in terms of early recovery, faster rehabilitation, and better functional outcomes³⁻⁶. Early mobilization is of vital importance in patients' recovery after hip surgery: Krenk et al.^{7,8} reported that use of 'fast-track arthroplasty' resulted in decreased postoperative delirium and cognitive disorder.

The posterolateral approach (PLA) is the most commonly used surgical approach in performance of hip arthroplasty⁹. However, several studies have reported on the potential for development of soft tissue damage and complications when using the PLA. The direct anterior approach (DAA) for performance of hip arthroplasty is emerging as a new alternative surgical approach requiring a minimally invasive intervention^{5,10}. The DAA was introduced as a minimally invasive surgical approach for use in performance of total hip arthroplasty (THA) that could reduce damage to muscle and soft tissue and relieve postoperative pain, enabling more rapid recovery from injury^{5,11}. As such, many studies have reported on use of the DAA, particularly for treatment of femoral neck fractures, but rarely for intertrochanteric fractures. Thus, we used the DAA in performance of bipolar hemiarthroplasty for treatment of femoral intertrochanteric fractures in elderly patients and evaluated its feasibility and stability¹², compared with the conventional PLA.

MATERIALS AND METHODS

The PLA was used in 55 cases from December 2016 to April 2019, and the DAA was then used in 57 cases from April 2019 to February 2021. Of 112 patients with femoral intertrochanteric fractures who underwent bipolar hemiarthroplasty from December 2016 to February 2021 at our hospital, 100 patients were included in the study. Patients who were not followed-up for more than six months and died during follow-up were excluded. Five patients in the

PLA group (three follow-up losses, two deaths) and seven patients in the DAA group (four follow-up losses, three deaths) were excluded. All operations were performed by a single surgeon using cementless femoral stems (Wagner SL Revision Hip Stem, Wagner Cone Prosthesis Hip Stem; Zimmer). No statistically significant difference in age, sex, body mass index (BMI), and bone mineral density (BMD) was observed between the two groups.

The mean age of the patients was 82.74±7.44 years in the PLA group, and 83.48±7.33 years in the DAA group. The PLA group included seven males and 43 females, while the DAA group included 10 males and 40 females. The mean BMI was 22.03±3.60 kg/m² in the PLA group, and 21.72±3.19 kg/m² in the DAA group. The mean BMD T-score was -3.58±0.75 in the PLA group, and -3.43±0.77 in the DAA group. No statistically significant difference in age, sex, BMI, and BMD was observed between the two groups (Table 1). Fractures of the greater trochanter (GT) were classified into four types according to the author's classification criteria¹³ (Fig. 1), and no statistically significant difference was observed between the two groups (Table 2).

In the PLA group, one or more wirings was used for fixation of the GT during the operation; however, fixation of the GT was not performed in the DAA group. An assessment of migration of the GT and subsidence of the femoral stem was performed postoperatively using plain radiographs. Displacement of the fractured GT was defined as a progressive migration of the GT more than 5 mm on follow-up radiographs. Subsidence of the femoral stem was measured according to the distance from the top of the stem shoulder to the horizontal line drawn across the bottom of each teardrop.

Analysis of the clinical results, including operative time, amount of blood loss, walking ability, hospitalization period, and complications was performed. The operative time was calculated as the time from skin incision to closure. The amount of blood loss was calculated as the total intraoperative bleeding with two days postoperative accumulation

Table 1. Demographic Data

	PLA (n=50)	DAA (n=50)	P-value
Age (yr)	82.74±7.44	83.48±7.33	0.622
Sex, male:female	7:43	10:40	0.430
BMI (kg/m ²)	22.03±3.60	21.72±3.19	0.649
BMD (T-score)	-3.58±0.75	-3.43±0.77	0.329

Values are presented as mean±standard deviation or number only.

PLA: posterolateral approach, DAA: direct anterior approach, BMI: body mass index, BMD: bone mineral density.

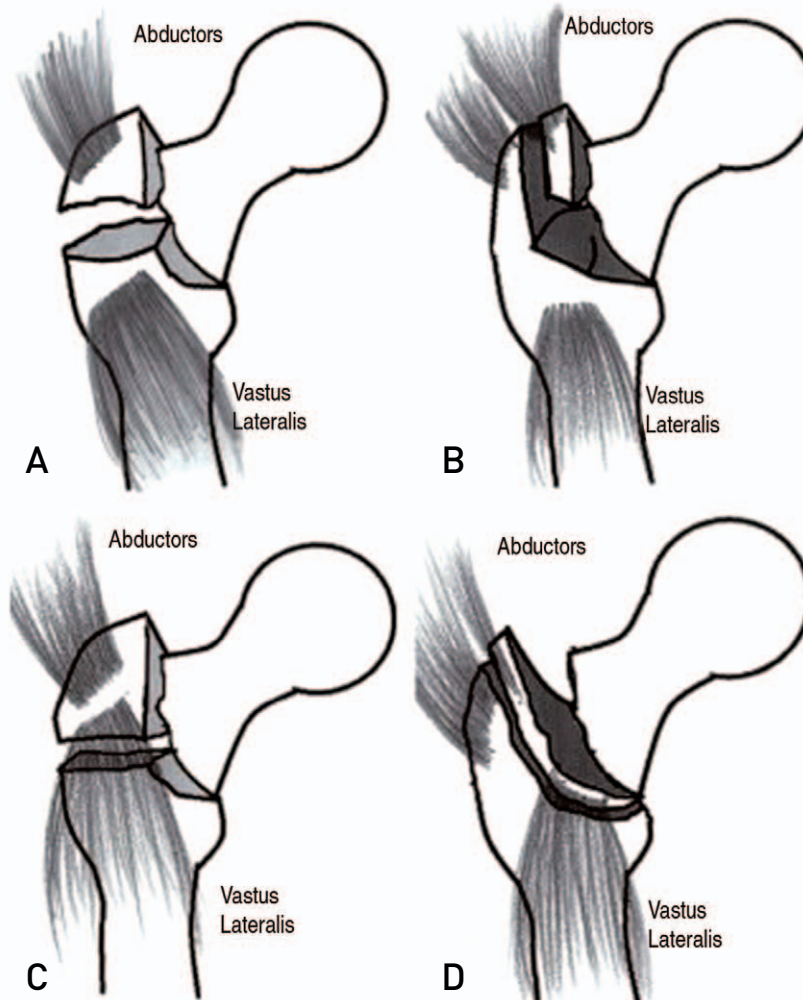


Fig. 1. Greater trochanter (GT) fracture classification. (A) Type A is a fracture with transverse direction above the inferior border of the GT. (B) Type B is a fracture with oblique direction above the inferior border of the GT. (C) Type C is a fracture with transverse direction below the inferior border of the GT. (D) Type D is a fracture with oblique direction below the inferior border of the GT.

Adapted from the article of Kim et al. (Hip Pelvis. 2019;31:144-9)¹³⁾ under the terms of the Creative Commons Attribution Non-Commercial (CC BY-NC 4.0) license.

Table 2. Classification of Greater Trochanter (GT) Fractures

Type	PLA (n=50)	DAA (n=50)
A	7 (14.0)	9 (18.0)
B	30 (60.0)	29 (58.0)
C	8 (16.0)	6 (12.0)
D	5 (10.0)	6 (12.0)

Values are presented as number (%).

Type A is a fracture with transverse direction above the inferior border of the GT. Type B is a fracture with oblique direction above the inferior border of the GT. Type C is a fracture with transverse direction below the inferior border of the GT. Type D is a fracture with oblique direction below the inferior border of the GT.

PLA: posterolateral approach, DAA: direct anterior approach.

in a drainage bag. Walking ability before injury and after the operation was classified according to the following four categories: walking without aid, walking with a cane, walking with a walker, and use of a wheelchair¹⁴⁾ (walking with assistance from another person) (Fig. 2). Patients started ambulation using a walker first three days after the operation, and gradually performed the rehabilitation. The complications included intraoperative fracture, infection, and dislocation.

This study was approved by the Institutional Review Board (IRB) of Kwangju Christian Hospital (KCH-M-2022-09-011), and the written informed consent was waived by the IRB due to the retrospective nature of the study. Statistical

analyses were performed using PASW Statistics (ver. 18.0; IBM). *P*-values less than 0.05 were statistically significant.

RESULTS

The mean operative time was 73.60 ± 14.56 minutes in the PLA group and 79.80 ± 8.89 minutes in the DAA group ($P=0.013$). More time was required for cases in the DAA group compared with the PLA group; however, after experiencing 20 cases using the DAA, there was no statistically significant difference in operative time between the two groups (Table 3).

The mean blood loss was 380.76 ± 180.67 mL in the PLA group and 318.14 ± 138.51 mL in the DAA group ($P=0.048$),

and was lower in the DAA group compared with the PLA group (Table 3).

Six months after the operation, walking without aid and walking using a cane or a walker was possible in 86.0% (43/50) of patients in the PLA group and 90.0% (45/50) of patients in the DAA group, with no significant difference between the two groups (Mann–Whitney U test; $P=0.238$) (Fig. 2).

The mean hospitalization time was 23.76 ± 11.89 days in the PLA group and 21.45 ± 4.18 days in the DAA group ($P=0.207$), and was shorter in the DAA group compared with the PLA group, but without statistically significant difference (Table 3).

There were no cases of progressive migration of the frac-

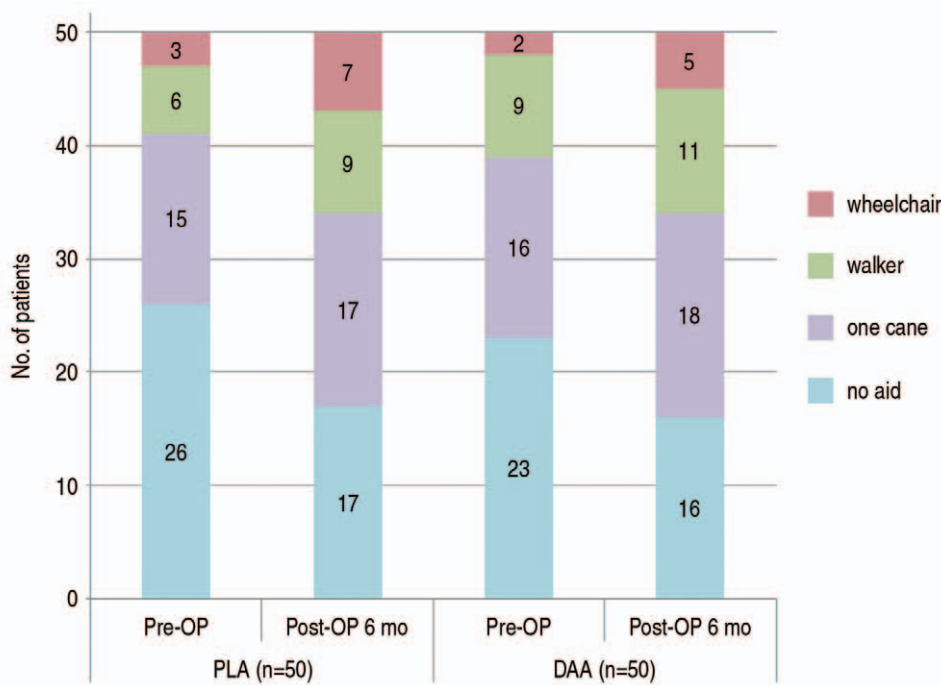


Fig. 2. Walking ability before injury and after surgery.

Pre-OP: preoperative, Post-OP: postoperative, PLA: posterolateral approach, DAA: direct anterior approach.

Table 3. Comparison of the Mean Operative Time, Blood Loss, and Hospitalization Period

	PLA (n=50)	DAA (n=50)	<i>P</i> -value
Operative time (min)	73.60 ± 14.56	79.80 ± 8.89	0.013
	73.60 ± 14.56	$74.83 \pm 7.36^*$	0.331
Blood loss and hospitalization period			
Blood loss (mL)	380.76 ± 180.67	318.14 ± 138.51	0.048
Hospitalization (day)	23.76 ± 11.89	21.45 ± 4.18	0.207

Values are presented as mean \pm standard deviation.

PLA: posterolateral approach, DAA: direct anterior approach.

* n=30; after experiencing 20 cases using the DAA total hip arthroplasty.

tured GT more than 5 mm on the last follow-up radiographs.

Intraoperative fractures and dislocation were not observed in either group. The only case of infection was detected in the PLA group.

DISCUSSION

Development of osteoporosis or osteoporosis-related frac-

tures is more likely with aging of the population. These elderly patients often have some type of chronic disease, so that there is potential for occurrence of many life-threatening complications after a hip fracture. Healing of fractures can be impaired as a result of poor bone quality. Early recovery from injury and early return to life after surgery could prevent serious complications^{15,16}. Arthroplasty could allow the patients to get out of bed earlier after surgery, although

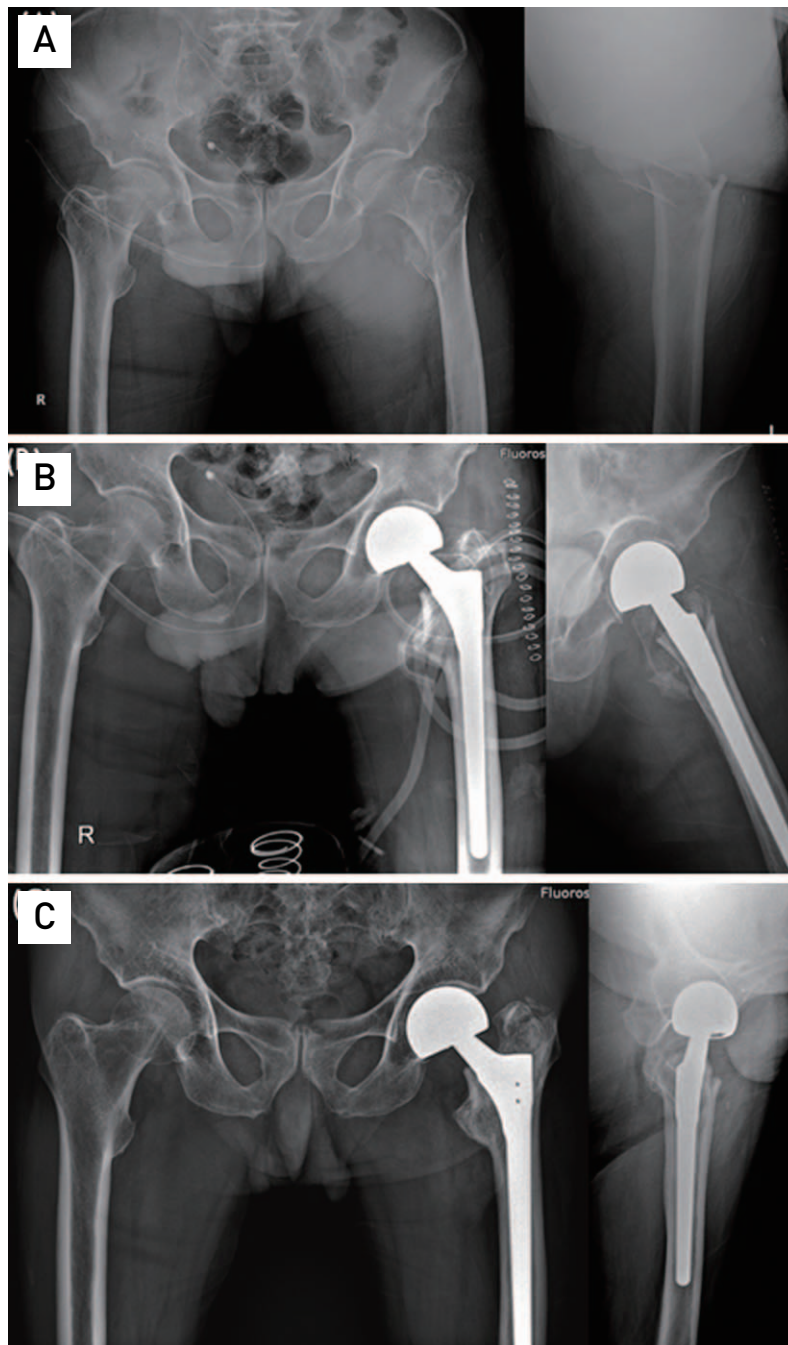


Fig. 3. (A) An 86-year-old male had a femoral intertrochanteric fracture. (B) Bipolar hemiarthroplasty using direct anterior approach was performed. (C) Six months after surgery, there was no complication.

increased soft tissue damage and bleeding can occur with use of arthroplasty compared to osteosynthesis^{9,17,18}. Use of the DAA, which was introduced as a minimally invasive surgical approach for use in performance of THA, could reduce damage to muscle and soft tissue and relieve postoperative pain^{5,11}. Despite these advantages of the DAA, there is still controversy regarding use of the DAA. A primary concern regarding use of the DAA is its steep learning curve. The learning curve for the DAA was previously reported as 10-200 cases¹⁹. Stone et al.²⁰ reported that 500 cases of DAA were required for learning; however, Spaans et al.²¹ reported that the mean operative time decreased with increasing experience in 46 DAA cases. In this study, operative time was shorter in the PLA group than in the DAA group; however, after experiencing 20 cases using the DAA, there was no statistically significant difference in operative time. We determined that a massive number of cases is not necessary for learning. Because the clinical results of our previous study of THA using the DAA for treatment of femoral neck fractures were satisfactory, we decided to perform surgery using the DAA and compare the clinical results from use of the DAA with those of the PLA.

Some studies reported that the amount of blood loss was greater when using the DAA compared with the PLA in performance of THA^{22,23}. In our study the mean amount of bleeding was 318.14 ± 138.51 mL in the DAA group, which was statistically lower than that of the PLA group. It was assumed that intraoperative bleeding would be similar in both groups; however, bleeding drainage from postoperative two days was lower in the DAA group due to preservation of soft tissue and muscle.

The fracture fragments of the GT are usually fixed with cerclage wiring or a cable system in arthroplasty for treatment of intertrochanteric fractures^{4,24}. Lee et al.²⁵ reported satisfactory results of GT fixation using only non-absorbable Ethibond sutures after hemiarthroplasty using the PLA for treatment of unstable intertrochanteric fractures. However, posterior soft tissues such as short external rotators, hip abductors, and posterior capsule are preserved when using the DAA. Therefore, fixation of the fractured fragments of the GT was not performed when using the DAA, which could shorten the operative time and provide protection from soft tissue damage. No migration of the GT more than 5 mm was observed on the last follow-up radiographs. Patients did not complain of pain and limping despite slight migration of the GT, which was less than 5 mm (Fig. 3). It is assumed that the fractured GT fragment might be stabilized by fibrous union due to preservation of muscle and

soft tissue, thus it did not affect the clinical results.

Intraoperative fracture is a common complication when using the DAA in performance of THA. Some studies have reported 0.9-6.5% intraoperative fractures when using the DAA in performance of THA²⁶⁻²⁸. However, in this study, there were no intraoperative or postoperative fractures even though patients had osteoporosis with BMD T-scores less than -2.5. Use of a special fracture table in the early period of the learning curve can be helpful. Obvious exposure of the GT is important when inserting the femoral stem on a special fracture table for placement of a retractor behind the GT and for elevating the femur using a femur elevation hook to prevent intraoperative fractures. However, in type D of the author's classification of GT fracture type¹³, elevation of the proximal femur outside into the operation field is difficult. Thus use of the DAA is considered difficult only in this type of intertrochanteric fracture.

This study had some limitations. Because it was retrospective in design, risk factors and comorbidities of patients to adverse outcome could not be stratified. The other limitation was the small number of cases, which may mask other rarer complications such as dislocation. Conduct of additional studies will be needed and long-term follow-up is also necessary.

CONCLUSION

We believe that the DAA for performance of hemiarthroplasty could be utilized as an alternative, safe surgical option for treatment of femoral intertrochanteric fractures in elderly patients without increasing the risk of early complications.

FUNDING

No funding to declare.

CONFLICT OF INTEREST

No potential conflict of interest relevant to this article was reported.

ORCID

Young Yool Chung (<https://orcid.org/0000-0002-4959-1230>)
Seung-Woo Shim (<https://orcid.org/0000-0001-6974-7151>)
Min Young Kim (<https://orcid.org/0000-0003-3073-5481>)
Young-Jae Kim (<https://orcid.org/0000-0002-1732-0698>)

REFERENCES

1. Park BJ, Cho HM, Min WB. A comparison of internal fixation and bipolar hemiarthroplasty for the treatment of reverse oblique intertrochanteric femoral fractures in elderly patients. *Hip Pelvis*. 2015;27:152-63. <https://doi.org/10.5371/hp.2015.27.3.152>
2. Green S, Moore T, Proano F. Bipolar prosthetic replacement for the management of unstable intertrochanteric hip fractures in the elderly. *Clin Orthop Relat Res*. 1987;(224):169-77.
3. Lee YK, Ha YC, Chang BK, Kim KC, Kim TY, Koo KH. Cementless bipolar hemiarthroplasty using a hydroxyapatite-coated long stem for osteoporotic unstable intertrochanteric fractures. *J Arthroplasty*. 2011;26:626-32. <https://doi.org/10.1016/j.arth.2010.05.010>
4. Grimsrud C, Monzon RJ, Richman J, Ries MD. Cemented hip arthroplasty with a novel cerclage cable technique for unstable intertrochanteric hip fractures. *J Arthroplasty*. 2005;20:337-43. <https://doi.org/10.1016/j.arth.2004.04.017>
5. Rachbauer F, Kain MS, Leunig M. The history of the anterior approach to the hip. *Orthop Clin North Am*. 2009;40:311-20. <https://doi.org/10.1016/j.oocl.2009.02.007>
6. Yoo JI, Ha YC, Lim JY, Kang H, Yoon BH, Kim H. Early rehabilitation in elderly after arthroplasty versus internal fixation for unstable intertrochanteric fractures of femur: systematic review and meta-analysis. *J Korean Med Sci*. 2017;32:858-67. <https://doi.org/10.3346/jkms.2017.32.5.858>
7. Krenk L, Kehlet H, Bæk Hansen T, Solgaard S, Soballe K, Rasmussen LS. Cognitive dysfunction after fast-track hip and knee replacement. *Anesth Analg*. 2014;118:1034-40. <https://doi.org/10.1213/ANE.0000000000000194>
8. Krenk L, Rasmussen LS, Hansen TB, Bogø S, Søballe K, Kehlet H. Delirium after fast-track hip and knee arthroplasty. *Br J Anaesth*. 2012;108:607-11. <https://doi.org/10.1093/bja/aer493>
9. Kurtz S, Ong K, Lau E, Mowat F, Halpern M. Projections of primary and revision hip and knee arthroplasty in the United States from 2005 to 2030. *J Bone Joint Surg Am*. 2007;89:780-5. <https://doi.org/10.2106/JBJS.F.00222>
10. Kennon RE, Keggi JM, Wetmore RS, Zatorski LE, Huo MH, Keggi KJ. Total hip arthroplasty through a minimally invasive anterior surgical approach. *J Bone Joint Surg Am*. 2003;85(Suppl 4):39-48. <https://doi.org/10.2106/00004623-200300004-00005>
11. Sibia US, Turner TR, MacDonald JH, King PJ. The impact of surgical technique on patient reported outcome measures and early complications after total hip arthroplasty. *J Arthroplasty*. 2017;32:1171-5. <https://doi.org/10.1016/j.arth.2016.10.031>
12. Park JH, Chung YY, Baek SN, Park TG. Hemiarthroplasty through direct anterior approach for unstable femoral intertrochanteric fractures in the elderly: analysis of early cases. *Hip Pelvis*. 2022;34:79-86. <https://doi.org/10.5371/hp.2022.34.2.79>
13. Kim MW, Chung YY, Lim SA, Shim SW. Selecting arthroplasty fixation approach based on greater trochanter fracture type in unstable intertrochanteric fractures. *Hip Pelvis*. 2019;31:144-9. <https://doi.org/10.5371/hp.2019.31.3.144>
14. Baba T, Shitoto K, Kaneko K. Bipolar hemiarthroplasty for femoral neck fracture using the direct anterior approach. *World J Orthop*. 2013;4:85-9. <https://doi.org/10.5312/wjo.v4.i2.85>
15. Hwang DS, Jung HT, Kim SB, Kim JS. Recovery of walking ability after operation for unstable intertrochanteric fractures of the femur in elderly: timing on weight bearing. *J Korean Fract Soc*. 1998;11:296-303. <https://doi.org/10.12671/jksf.1998.11.2.296>
16. Ceder L, Thorngren KG, Wallden B. Prognostic indicators and early home rehabilitation in elderly patients with hip fractures. *Clin Orthop Relat Res*. 1980;(152):173-84.
17. Stern MB, Angerman A. Comminuted intertrochanteric fractures treated with a Leinbach prosthesis. *Clin Orthop Relat Res*. 1987;(218):75-80.
18. Chan KC, Gill GS. Cemented hemiarthroplasties for elderly patients with intertrochanteric fractures. *Clin Orthop Relat Res*. 2000;(371):206-15. <https://doi.org/10.1097/00003086-200002000-00025>
19. den Hartog YM, Mathijssen NM, Vehmeijer SB. The less invasive anterior approach for total hip arthroplasty: a comparison to other approaches and an evaluation of the learning curve: a systematic review. *Hip Int*. 2016;26:105-20. <https://doi.org/10.5301/hipint.5000319>
20. Stone AH, Sibia US, Atkinson R, Turner TR, King PJ. Evaluation of the learning curve when transitioning from posterolateral to direct anterior hip arthroplasty: a consecutive series of 1000 cases. *J Arthroplasty*. 2018;33:2530-4. <https://doi.org/10.1016/j.arth.2018.02.086>
21. Spaans AJ, van den Hout JA, Bolder SB. High complication rate in the early experience of minimally invasive total hip arthroplasty by the direct anterior approach. *Acta Orthop*. 2012;83:342-6. <https://doi.org/10.3109/17453674.2012.711701>
22. Barrett WP, Turner SE, Leopold JP. Prospective randomized study of direct anterior vs postero-lateral approach for total hip arthroplasty. *J Arthroplasty*. 2013;28:1634-8. <https://doi.org/10.1016/j.arth.2013.01.034>
23. Nakata K, Nishikawa M, Yamamoto K, Hirota S, Yoshikawa H. A clinical comparative study of the direct anterior with mini-posterior approach: two consecutive series. *J Arthroplasty*. 2009;24:698-704. <https://doi.org/10.1016/j.arth.2008.04.012>
24. Hamadouche M, Zniber B, Dumaine V, Kerboull M, Courpied JP. Reattachment of the ununited greater trochanter following total hip arthroplasty. The use of a trochanteric claw plate. *J Bone Joint Surg Am*. 2003;85:1330-7. <https://doi.org/10.2106/00004623-200307000-00020>
25. Lee KH, Lee DH, Noh JH, Kim YV. Is rigid fixation of the greater trochanter necessary for arthroplasty of intertrochanteric fractures? *Orthop Traumatol Surg Res*. 2019;105:41-5. <https://doi.org/10.1016/j.otsr.2018.09.015>
26. Hartford JM, Knowles SB. Risk factors for perioperative femoral fractures: cementless femoral implants and the direct anterior approach using a fracture table. *J Arthroplasty*. 2016;31:2013-8. <https://doi.org/10.1016/j.arth.2016.02.045>
27. Berend KR, Mirza AJ, Morris MJ, Lombardi AV Jr. Risk of periprosthetic fractures with direct anterior primary total hip arthroplasty. *J Arthroplasty*. 2016;31:2295-8. <https://doi.org/10.1016/j.arth.2016.03.007>
28. Jewett BA, Collis DK. High complication rate with anterior total hip arthroplasties on a fracture table. *Clin Orthop Relat Res*. 2011;469:503-7. <https://doi.org/10.1007/s11999-010-1568-1>