



# Functional Outcome after Reimplantation in Patients Treated with and without an Antibiotic-Loaded Cement Spacers for Hip Prosthetic Joint Infections

Michele Fiore, MD, Claudia Rondinella, MD, Azzurra Paolucci, MD, Lorenzo Morante, MD,  
Massimiliano De Paolis, MD, Andrea Sambri, MD, PhD

*Orthopaedics and Traumatology Unit, IRCCS Azienda Ospedaliera Universitaria di Bologna, Bologna, Italy*

**Purpose:** A staged revision with placement of a temporary antibiotic-loaded cement spacer after removal of the implant is the “gold standard” for treatment of chronic prosthetic joint infection (PJI). It enables local delivery of antibiotics, maintenance of limb-length and mobility, easier reimplantation. However, bacterial colonization of spacers and mechanical complications can also occur. The aim of this study is to evaluate functional results and infection control in two-stage treatment of total hip arthroplasty (THA) PJI with and without a spacer.

**Materials and Methods:** A retrospective review of 64 consecutive patients was conducted: 34 underwent two-stage revision using a cement spacer (group A), 30 underwent two-stage revision without a spacer (group B). At the final follow-up, functional evaluation of patients with a THA in site, without PJI recurrence, was performed using the Harris hip score (HHS). Measurement of limb-length and off-set discrepancies was performed using anteroposterior pelvic X-rays.

**Results:** Most patients in group B were older with more comorbidities preoperatively. Thirty-three patients (97.1%) in group A underwent THA reimplantation versus 22 patients (73.3%) in group B ( $P < 0.001$ ). No significant differences in limb-length and off-set were observed. The results of functional evaluation performed during the final follow-up (mean, 41 months) showed better function in patients in group A (mean HHS, 76.3 vs. 55.9;  $P < 0.001$ ).

**Conclusion:** The use of antibiotic-loaded cement spacer seems superior in terms of functional outcomes and reimplantation rate. Resection arthroplasty might be reserved as a first-stage procedure in patients who are unfit, who might benefit from a definitive procedure.

**Key Words:** Hip, Prosthetic joint infections, Two-stage, Cement spacers, Polymethylmetacrilate

**Submitted:** September 27, 2022 **1st revision:** October 24, 2022  
**2nd revision:** November 9, 2022 **Final acceptance:** November 14, 2022

**Address reprint request to**

**Massimiliano De Paolis, MD**

(<https://orcid.org/0000-0002-6182-9870>)

Orthopaedics and Traumatology Unit, IRCCS Azienda Ospedaliera  
Universitaria di Bologna, via Massarenti 9, 40138 Bologna, Italy

**TEL:** +39-0512142670 **FAX:** +39-0512142670

**E-mail:** [massimiliano.depaolis@aosp.bo.it](mailto:massimiliano.depaolis@aosp.bo.it)

This is an Open Access article distributed under the terms of the Creative Commons Attribution Non-Commercial License (<http://creativecommons.org/licenses/by-nc/4.0>) which permits unrestricted non-commercial use, distribution, and reproduction in any medium, provided the original work is properly cited.

## INTRODUCTION

A staged revision is the “gold standard” for treatment of chronic prosthetic joint infection (PJI). The first stage includes removal of the implant and debridement of bone and soft tissue, as well as concomitant treatment with a microbe-specific antibiotic. Implantation of a temporary antibiotic-loaded cement spacer is usually performed at the time of prostheses removal<sup>1,2</sup>.

The use of antibiotic-loaded cement spacers enables local delivery of large amounts of antibiotics, maintenance of the length, and patient mobility while waiting for eradication of the infection. Other potential benefits of spacers include improved function and less pain during the interval, as well as a shorter second stage resulting from reduced intra-articular fibrosis and retraction<sup>3-6</sup>.

However, bacterial colonization of cement spacers can also occur<sup>7</sup>. In addition, numerous complications have been reported, including dislocation, migration, or breakage of the spacer, femur fractures, and loss of acetabular bone<sup>8</sup>. Therefore, in two-stage revision for treatment of PJI of the hip, there is a question regarding whether an antibiotic-loaded cement spacer should be used during the interval between stages. A non-spacer two-stage exchange is a feasible option for management of chronically infected hip arthroplasties with severe bone loss or abductor deficiency. Reimplantation is impeded by muscle contractures, leading to development of a limb-length discrepancy and worse functional outcomes, which is a major concern when performing a non-spacer exchange<sup>9</sup>. However, only a few studies directly comparing the Girdlestone procedure and spacer implantation in the two-stage protocol have been reported<sup>1,10</sup>.

The aim of this study was to compare patients who underwent treatment using a two-stage approach with and without the use of an antibiotic-loaded cement spacer for treatment of PJI of the hip. Therefore, we sought to determine the following: (1) can a better functional or radiographic result be obtained with use of a spacer? (2) Is the rate of infection control comparable between the two groups?

## MATERIALS AND METHODS

A retrospective review of the prospectively maintained databases of our institution for patients affected by PJI of the hip who underwent treatment using a staged approach was conducted.

Inclusion criteria for the study were patients undergoing two-stage revision surgery for treatment of total hip arthro-

plasty (THA) PJI. Patients who underwent treatment between 2015 and 2020 were included. Sixty-four patients were included. All patients provided consent for the use of their clinical information at the time of admission and the complete medical records and images were available for revision. The study was approved by the local Ethics Committee (approval No. 0038362) and the written informed consent was obtained from all patients. The study have been performed in accordance with the ethical standards laid down in the 1964 Declaration of Helsinki and its later amendments.

Clinical confirmation of infection was based on criteria defined by the Musculoskeletal Infection Society (MSIS)<sup>11</sup>.

In detail, during the first stage, complete removal of the prosthesis was performed using the previously utilized surgical approach. All prosthetic components were removed. An extended trochanteric osteotomy was performed if required in order to aid in removal of the femoral stem or bone cement. The prosthesis was sent for sonication each time<sup>12-14</sup>. All infected or necrotic bone and soft tissue were debrided. Specimens from representative areas were taken for performance of an antibiotic susceptibility test (AST). Patients underwent placement of a spacer (spacer G; Tecres SpA, Verona, Italy) (group A) or a resection arthroplasty without a spacer (group B). The decision regarding whether to use a spacer was made by the orthopedic surgeon on a case-by-case basis after a discussion with a multidisciplinary infection board, composed of an infectious disease specialist and a microbiologist. Patients with defects of acetabular or femoral bone (type 2B-C or 3 on the acetabular side, type 3 on the femoral side) usually underwent the first stage procedure with no spacer in order to minimize spacer-related complications such as acetabular lysis or peri-spacer fracture<sup>15,16</sup>. A resection arthroplasty without a spacer was often preferred in patients with many comorbidities and those with a case of PJI that was difficult to treat PJI (based on the responsible bacteria)<sup>8</sup>.

Based on AST, bacteria were classified as highly virulent (*Staphylococcus aureus*, *Enterococcus* spp., *Pseudomonas aeruginosa*) and low virulent pathogens (coagulase negative staphylococci, including *Staphylococcus epidermidis*)<sup>13</sup>. After surgery, another discussion of all patients with the multidisciplinary infection board was conducted, and suitable antibiotic therapy was administered according to AST.

Each spacer was maintained for at least six weeks. Patients were allowed non-weight-bearing de-ambulation using two crutches during this period. The use of a hip brace was also recommended. In cases where clinical evidence showed persistent infection, repeated debridement and spacer exchange

were performed, and the patient remained on antibiotics.

Antibiotic was discontinued for a period of two weeks in cases where laboratory results (C-reactive protein levels) and clinical evaluation showed no indication of residual infection<sup>17</sup>. If no sign of infection was observed during this period, the patient then underwent the second stage of the prosthetic revision. All reimplantation procedures were performed using cementless implants.

Radiographic analysis of all anteroposterior hip radiographs after THA reimplantation was performed by a trained orthopedic surgeon (A.S.). Measurement of limb length discrepancy was based on vertical height difference between the inter-teardrop or interpubic tubercle lines and the lesser tubercle line. Calculation of offset discrepancy was based on the difference between the reimplant offset and contralateral offset.

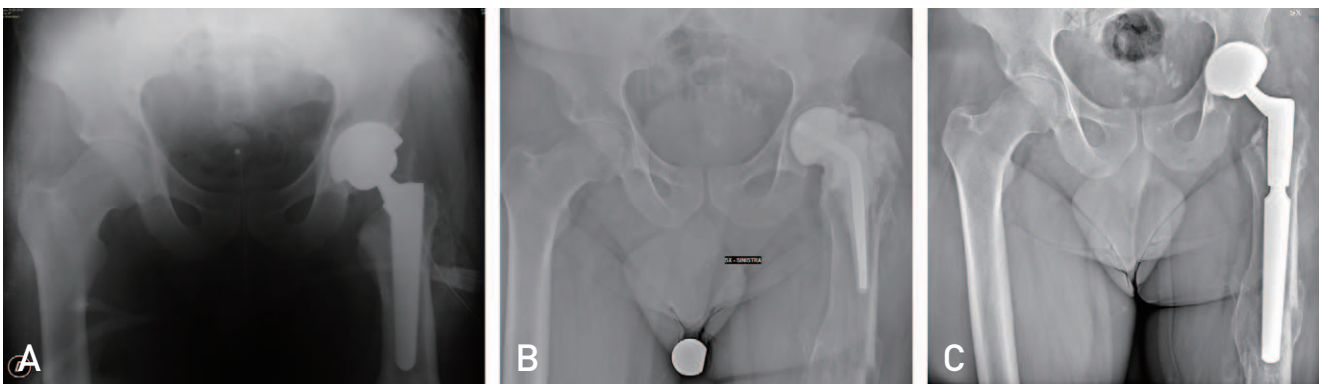
Blood tests including C-reactive protein were performed once a month during the first year after surgery. Evaluation

of patients was performed every three months during the first year after surgery and once a year thereafter with antero-posterior radiographs of the pelvis.

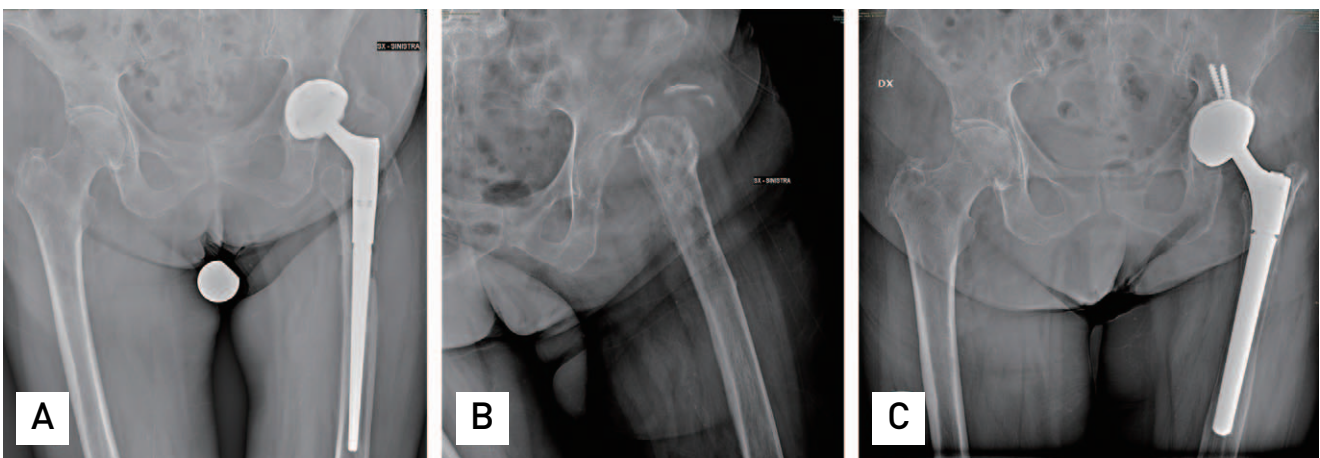
Successful eradication of the infection was defined according to Fillingham et al.<sup>18</sup>.

Assessment of the functional outcome for all surviving patients who did not require revision surgery after second stage reimplantation at the final follow-up was performed using the modified Harris hip score (HHS)<sup>19</sup>.

Descriptive statistics are reported as number (percentage) or mean (standard deviations and range), as appropriate. Comparison of continuous variables was performed using the Mann–Whitney U test and comparison of categorical variables was performed using the chi-square test. *P*-values  $\leq 0.05$  were considered significant; statistical analyses were performed using IBM SPSS Statistics for Windows (ver. 22.0; IBM, Armonk, NY, USA).



**Fig. 1.** (A) Anteroposterior X-rays of the pelvis showing a left hip prosthetic joint infection. (B) The prosthesis was removed and a poly(methyl methacrylate) (PMMA) spacer was implanted. (C) Reimplantations with a cementless total hip arthroplasty.



**Fig. 2.** (A) Anteroposterior X-rays of the pelvis showing a left hip prosthetic joint infection. (B) The prosthesis was removed by performance of a spacer-free procedure. (C) Reimplantations with a cementless total hip arthroplasty.

**RESULTS**

A total of 34 patients underwent two-stage revision with implantation of an antibiotic-loaded cement spacer (group A) (Fig. 1), while 30 patients underwent THA removal without implantation of a spacer (group B) (Fig. 2) (Table 1).

The mean surgical time for the first stage was 151 minutes (range, 65-183 minutes) in group A and 153 minutes (range, 70-179 minutes) in group B ( $P=0.877$ ). An extend-

ed trochanteric osteotomy was required during the first stage in 15 patients (44.1%) in group A and in 12 patients (40.0%) in group B. A shorter hospital stay was observed after prosthesis removal in group A ( $13.7 \pm 7.8$  days) compared with group B ( $21.7 \pm 19.5$  days) ( $P=0.048$ ) (Table 2).

All patients met the complete MSIS criteria for infection. Thirteen patients presented with a multibacterial infection with isolation of different overlapping pathogens. The most frequent pathogens are shown in Table 2.

**Table 1.** Characteristics of Patients at Baseline

	Total (n=64)	Group A (n=34)	Group B (n=30)	P-value
Sex, M:F	34:30	19:15	15:15	0.534
Age (yr)	68.2±18.9 (36-93)	61.1±13.3 (36-76)	75.6±10.2 (61-93)	0.026
BMI (kg/m <sup>2</sup> )	27.3±3.0 (23.3-33.2)	26.9±2.7 (23.3- 31.4)	27.7±3.1 (24.1-33.2)	0.321
Fistula	20 (31.3)	10 (29.4)	10 (33.3)	0.912
ASA score	2.6±0.5 (1-4)	2.3±0.6 (1-4)	2.9±0.4 (2-4)	0.747
CCI	3.9±1.5 (2-8)	2.4±0.8 (2-6)	5.5±2.1 (3-8)	<0.001
Mean time between implant and explant (mo)	59.3±38.9 (3-121)	59.5±37.1 (3-110)	58.5±39.0 (4-121)	0.937

Values are presented as number only, mean±standard deviation (range), or number (%).

Group A: patients underwent two-stage revision using a cement spacer, Group B: patients underwent two-stage revision without a spacer.

M: male, F: female, BMI: body mass index, ASA score: American Society of Anesthesiologists score, CCI: Charlson comorbidity index.

**Table 2.** Treatment Details

	Total (n=64)	Group A (n=34)	Group B (n=30)	P-value
Mean surgical time (I stage) (min)	152.3±21.2 (65-183)	151.2±23.1 (65-183)	153.3±18.9 (70-179)	0.877
Extended trochanteric osteotomy	27 (42.2)	15 (44.1)	12 (40.0)	0.461
Estimated blood loss (mL)	4.8±1.1 (1-6)	4.5±0.6 (1-5)	5.2±0.8 (1-6)	0.237
Mean length of hospital (day)	16.8±12.8 (7-24)	13.7±7.8 (7-19)	21.7±19.5 (10-24)	0.048
Antibiotic therapy duration (day)	59.1±13.2 (42-85)	73.1±7.5 (44-85)	49.2±1.8 (47-82)	0.044
More frequent pathogens*				
MRSA	16	7	9	
MSSA	14	8	6	
MR CoNS	14	7	7	
MS CoNS	19	13	6	
<i>Enterococcus</i> spp.	9	3	6	
<i>Streptococcus</i> spp.	3	2	1	
<i>Citrobacter</i> spp.	1	-	1	
Reimplants	55 (85.9)	33 (97.1)	22 (73.3)	<0.001
Time between 1st and 2nd stage <sup>†</sup> (day)	123±39 (61-321)	111±33 (61-185)	143±46 (66-321)	0.063
Mean surgical time (II stage) (min)	148.7±33.4 (77-234)	111.3±29.8 (77-179)	173.4±37.2 (82-234)	<0.001

Values are presented as mean±standard deviation (range), number (%), or number only.

Group A: patients underwent two-stage revision using a cement spacer, Group B: patients underwent two-stage revision without a spacer.

MR: methicillin resistant, SA: *Staphylococcus aureus*, MS: methicillin sensitive, CoNS: coagulase negative staphylococci.

\* 76 pathogens in 64 patients.

† In patients undergoing a second stage.



A suppressive specific antibiotic therapy was administered in all patients according to AST for a mean duration of 59.1 days (range, 42-85 days), with a longer duration of therapy (mean, 73.1 days; range, 44-85 days) in group A compared with group B (mean, 49.2 days; range, 47-82 days) ( $P=0.044$ ).

Two spacer-related complications were observed during the interval between the first and second stages: one spacer dislocation and one diaphyseal femoral fracture for which additional surgery was required. Some minor complications were also reported in group B, including three hematomas and one wound dehiscence which were managed conservatively.

Infection was not eradicated after the first-stage revision and a repeated first-stage revision procedure was required in 12 patients. Fifty-five patients underwent the second stage surgery at a median of 123 days (range, 61-321 days). In detail, 33 patients (97.1%) in group A underwent reimplantation with a THA, while only 22 patients (73.3%) in group B underwent reimplantation. Eight of these patients did not undergo reconstruction after the first stage procedure due to medical co-morbidities that rendered them unfit for administration of anesthesia, thus, they remained with a Girdlestone hip indefinitely. Three patients died of non-treatment related causes.

Among patients who underwent reimplantation, reinfection occurred in four patients (12.1%) in group A and two patients (9.1%) in group B. Two of these patients underwent a repeated two-stage revision, while four patients remained on long-term antibiotic suppressive therapy. In group B, among eight patients who did not undergo reimplantation, six patients showed remission of the infection, while two of these patients developed a chronic infection.

At the final follow-up (mean, 41 months; range, 18-82 months), the results of functional evaluation of 49 patients

with a THA in site, without recurrence of PJI, showed better function in patients in group A (mean HHS, 76.3 vs. 55.9;  $P<0.001$ ). In addition, the worst functional results were observed for the eight patients with a definitive Girdlestone hip with a mean HHS of 48 (Table 3).

Among patients with a THA in site, comparable limb-length discrepancy was observed between the two groups ( $P=0.953$ ). Higher mean off-set discrepancy was observed in group B compared with group A, although without statistical significance.

## DISCUSSION

A few studies directly comparing the Girdlestone procedure and spacer implantation in the two-stage protocol have been reported<sup>1,10</sup>. However, to the best of our knowledge, this is the first study conducted with the primary aim of performing functional and radiographic assessment of patients after prosthesis reimplantation, after two stage revision surgery with or without a cement spacer.

In the current series, patients who underwent a spacer-free procedure (group B) were older, presented with more comorbidities preoperatively, and often had larger defects of bone and soft tissue. This is in agreement with our selection process, where high-risk patients were preferentially allocated to undergo a spacer-free procedure. In fact, although two-stage exchange arthroplasty using antibiotic-loaded spacers is the most widely applied treatment for patients with chronically infected THA<sup>20,21</sup>, placement of spacers in patients with defects of bone and soft tissue is challenging with a high risk of mechanical failure and progressive bone loss during the interim period. A complication rate of 22-58% for placement of spacers has been reported<sup>22,23</sup>. In addition, implantation of a spacer requires a second surgery for its removal, even in cases where an indefinite Girdlestone can be expected, which

**Table 3.** Functional Outcomes and Infection Control

	Total (n=64)	Group A (n=34)	Group B (n=30)	P-value
Limb length discrepancy* (mm)	-16.5±8.3 [-1 to -34]	-16.5±7.5 [-1 to -27]	-16.3±8.1 [-2 to -34]	0.953
Off-set discrepancy* (mm)	-9.7±2.9 [-3 to -13]	-8.1±2.7 [-3 to -12]	-17.6±2.2 [-6 to -13]	0.072
Harris hip score*	68.3±11.3 [33-87]	76.3±6.8 [55-87]	55.9±10.1 [33-75]	<0.001
PJI recurrence <sup>†</sup>	6/55 (10.9)	4/33 (12.1)	2/22 (9.1)	0.768

Values are presented as mean±standard deviation (range), number (%), or number only.

Group A: patients underwent two-stage revision using a cement spacer, Group B: patients underwent two-stage revision without a spacer.

PJI: periprosthetic joint infection.

\* In 49 patients with the prosthesis in site and no signs of infection at the final follow-up.

<sup>†</sup> Assessed in patients who underwent reimplantation.

increases the risk of morbidity in patients who are unfit. Several possible mechanical complications can occur with use of cement spacers: spacer fractures, dislocations (up to 16.4%), and femoral fractures have frequently been reported<sup>8)</sup>. A much lower rate of mechanical complications associated with use of spacers was found in the current study, and only one spacer dislocation was reported. The risk of mechanical complications might have been reduced by selection of patients who should undergo the procedure using a spacer during the interstage phase. The risk for development of mechanical complications during the interstage phase is particularly high for patients with large acetabular or femoral osteolysis<sup>24,25)</sup>.

The period of recovery appeared to be shorter in patients who underwent implantation of a spacer at the time of prosthesis removal, as indicated by the significantly shorter hospital stay. Implantation of a spacer can result in less postoperative pain with immediate commencement of rehabilitation and attainment of early functional recovery<sup>1)</sup>.

Our findings also showed that repeated debridement was required for 12 of 64 hips (18.8%) due to persistent infection before second stage reimplantation. These figures are comparable with those reported in the literature showing a wide variety of spacer exchange rates ranging between 6% and 21%<sup>4,26,27)</sup>.

Our findings confirm those of previous studies, which reported that the duration of the second-stage operation was longer when implantation of the spacer was not performed during the first stage<sup>1,10,28,29)</sup>. Reimplantation without a spacer is a more complex procedure due to the difficulty in locating the surgical planes, identifying bone structures, and constructing the bed to accept the prosthesis. Extended surgical time is required in cases of extensive fibrosis. The operation was approximately one hour shorter when a spacer was used, with easier location of surgical planes, identification of bone structures, and construction of the bed for the implant, compared with the control group.

A higher rate of reimplantation was observed in the spacer group (97.1%) compared with the spacer-free group (73.3%). Varying rates (60-100%) have been reported for successful reimplantation in two-stage exchange using a spacer<sup>26,27,30,31)</sup>. Many of the patients who underwent reimplantation in the spacer-free group underwent definitive resection arthroplasty without an intention of undergoing reimplantation during the first stage; therefore, the lower percentage of these patients was expected. This finding could be attributable to severe comorbidities and older age, a more severe infection, or lower functional expectations

leading to the decision to perform a resection arthroplasty during the first stage.

A shorter mean duration of antibiotic therapy in the no-spacer group could be a result of reduced tolerance to long-term administration of antibiotics in patients who are unfit. In addition, the duration of antibiotic therapy in the spacer group might have been prolonged by the need for a more solid guarantee that the infection has been cured in patients scheduled to undergo reimplantation.

Successful eradication of the infection following two-stage reimplantation has been reported in 84-100% of cases<sup>32-34)</sup>, which is consistent with our findings. Both groups showed a comparable rate of reinfection: 12.1% in the spacer group and 9.1% in the non-spacer group. However, these findings differ from those reported by Cabrita et al.<sup>1)</sup>, who observed a lower rate of infection after the second stage of revision with the use of a spacer compared to a hanging hip. In contrast, Marczak et al.<sup>10,35)</sup> reported that the rate of re-infection in the spacer group was twice that of the non-spacer group.

However, despite the reliability of resection arthroplasty in eradicating reinfection, the fact that it often results in poor function is a major concern<sup>25,36)</sup>. We observed better functional results in the spacer group, similar to the findings reported by Marczak et al.<sup>10,35)</sup>. In a study comparing antibiotic-loaded cement beads and antibiotic-loaded cement prosthesis reported by Hsieh et al.<sup>29)</sup>, the use of a spacer showed an association with a higher level of functioning and better walking capacity during the interim period. However, there is no clarity with regard to the literature review on the effect of using a spacer on the final clinical results. Cabrita et al.<sup>1)</sup> reported that no significant difference in functional results was observed in patients who underwent treatment using a two-stage procedure, either with or without a spacer.

Successful restoration of limb length to the length before the two-stage exchange arthroplasty was observed in both groups. This finding can be regarded as acceptable when compared with the findings reported by Alexeeff et al.<sup>37)</sup>, who found no discrepancy greater than 3.0 cm when a spacer was used and with data reported by Charlton et al.<sup>38)</sup>, who achieved full correction in only 50% of patients after treatment using a spacer. In contrast, Cabrita et al.<sup>1)</sup> and Marczak et al.<sup>10)</sup> reported on complaints of leg length discrepancy by patients who underwent resection arthroplasty.

Some limitations of this study must be acknowledged. First, its retrospective study design is subject to associated biases common to these types of studies. A higher prevalence of older patients with more comorbidities who underwent treatment without a spacer may indicate an important

selection bias. There might also be bias of selection among patients who underwent reimplantation, which could potentially affect the functional results. Second, although a standardized two-stage protocol was used, several variables, including the decision regarding whether to use a spacer or not during the first stage, the degree of debridement, length of the prosthesis-free interval, implant selection for reimplantation, and the decision regarding long-term antibiotic suppression showed minor variations in accordance with the preferences of the surgeon and infectious disease specialist. In addition, further sub-analysis could not be performed due to the small sample size and the heterogeneity of the two groups. Finally, regarding hip function, self-assessment of HHS is performed by each patient, which might have influenced the functional results.

Of note, the difference in reimplantation rate between the two treatments is also largely dependent on the patient's pre-operative condition, such as the age of the patient. Finally, a significant dropout bias must be acknowledged as 27% patients in group B did not undergo reimplantation.

## CONCLUSION

Our results suggest that superior functional outcomes after reimplantation in the two-stage treatment of infected hip arthroplasties can be obtained with use of an antibiotic-loaded cement spacer compared with those for the two-stage surgery performed without a spacer. Nevertheless, based on the limitations described above, confirmation of our findings will be required through conduct of larger scale prospective studies. Resection arthroplasty might be reserved as a first-stage procedure in cases of patients who are unfit, who might benefit from a definitive procedure.

## FUNDING

No funding to declare.

## CONFLICT OF INTEREST

The authors declare that there is no potential conflict of interest relevant to this article.

## REFERENCES

1. Cabrita HB, Croci AT, Camargo OP, Lima AL. *Prospective study of the treatment of infected hip arthroplasties with or without the use of an antibiotic-loaded cement spacer. Clinics (Sao Paulo)*. 2007;62:99-108.

2. Diamond OJ, Masri BA. *Articulating antibiotic impregnated spacers in prosthetic joint infections: where do we stand? Int J Surg*. 2018;54(Pt B):345-50. <https://doi.org/10.1016/j.ijisu.2017.07.044>
3. Sandiford NA, Duncan CP, Garbuz DS, Masri BA. *Two-stage management of the infected total hip arthroplasty. Hip Int*. 2015;25:308-15. <https://doi.org/10.5301/hipint.5000265>
4. Erivan R, Lecointe T, Villatte G, Mulliez A, Descamps S, Boisgard S. *Complications with cement spacers in 2-stage treatment of periprosthetic joint infection on total hip replacement. Orthop Traumatol Surg Res*. 2018;104:333-9. <https://doi.org/10.1016/j.otsr.2017.11.016>
5. Leunig M, Chosa E, Speck M, Ganz R. *A cement spacer for two-stage revision of infected implants of the hip joint. Int Orthop*. 1998;22:209-14. <https://doi.org/10.1007/s002640050244>
6. Romanò CL, Romanò D, Meani E, Logoluso N, Drago L. *Two-stage revision surgery with preformed spacers and cementless implants for septic hip arthritis: a prospective, non-randomized cohort study. BMC Infect Dis*. 2011;11:129. <https://doi.org/10.1186/1471-2334-11-129>
7. Sambri A, Maso A, Storni E, et al. *Is sonication of antibiotic-loaded cement spacers useful in two-stage revision of prosthetic joint infection? J Microbiol Methods*. 2019;156:81-4. <https://doi.org/10.1016/j.mimet.2018.12.006>
8. Sambri A, Fiore M, Rondonella C, et al. *Mechanical complications of hip spacers: a systematic review of the literature. Arch Orthop Trauma Surg*. Published online Apr 12, 2022; <https://doi.org/10.1007/s00402-022-04427-z>
9. Hipfl C, Carganico T, Leopold V, Perka C, Müller M, Hardt S. *Two-stage revision total hip arthroplasty without spacer placement: a viable option to manage infection in patients with severe bone loss or abductor deficiency. J Arthroplasty*. 2021;36:2575-85. <https://doi.org/10.1016/j.arth.2021.02.040>
10. Marczak D, Synder M, Sibiński M, Polguj M, Dudka J, Kowalczewski J. *Two stage revision hip arthroplasty in periprosthetic joint infection. Comparison study: with or without the use of a spacer. Int Orthop*. 2017;41:2253-8. <https://doi.org/10.1007/s00264-017-3500-8>
11. Parvizi J, Tan TL, Goswami K, et al. *The 2018 definition of periprosthetic hip and knee infection: an evidence-based and validated criteria. J Arthroplasty*. 2018;33:1309-14.e2. <https://doi.org/10.1016/j.arth.2018.02.078>
12. Sambri A, Fiore M, Tedeschi S, De Paolis M. *The need for multidisciplinary in modern medicine: an insight into orthopaedic infections. Microorganisms*. 2022;10:756. <https://doi.org/10.3390/microorganisms10040756>
13. Sambri A, Cadossi M, Giannini S, et al. *Is treatment with dithiothreitol more effective than sonication for the diagnosis of prosthetic joint infection? Clin Orthop Relat Res*. 2018;476:137-45. <https://doi.org/10.1007/s11999.0000000000000060>
14. Sambri A, Maso A, Storni E, et al. *Sonication improves the diagnosis of megaprosthesis infections. Orthopedics*. 2019;42:28-32. <https://doi.org/10.3928/01477447-20181010-06>
15. Ibrahim DA, Fernando ND. *Classifications in brief: the Paprosky classification of femoral bone loss. Clin Orthop Relat Res*. 2017;475:917-21. <https://doi.org/10.1007/s11999-016-5012-z>
16. Telleria JJ, Gee AO. *Classifications in brief: Paprosky classification of acetabular bone loss. Clin Orthop Relat Res*. <https://doi.org/10.1590/S0009-2165-2017-0000000000000000>

- 2013;471:3725-30. <https://doi.org/10.1007/s11999-013-3264-4>
17. Tan TL, Kheir MM, Rondon AJ, Parvizi J, George J, Higuera CA, et al. Determining the role and duration of the “antibiotic holiday” period in periprosthetic joint infection. *J Arthroplasty*. 2018;33:2976-80. <https://doi.org/10.1016/j.arth.2018.04.019>
  18. Fillingham YA, Della Valle CJ, Suleiman LI, et al. Definition of successful infection management and guidelines for reporting of outcomes after surgical treatment of periprosthetic joint infection: from the workgroup of the musculoskeletal infection society (MSIS). *J Bone Joint Surg Am*. 2019;101:e69. <https://doi.org/10.2106/JBJS.19.00062>
  19. Harris IE, Leff AR, Gitelis S, Simon MA. Function after amputation, arthrodesis, or arthroplasty for tumors about the knee. *J Bone Joint Surg Am*. 1990;72:1477-85.
  20. Mabry TM, Hanssen AD. Articulating antibiotic spacers: a matter of personal preference. *Orthopedics*. 2007;30:783-5. <https://doi.org/10.3928/01477447-20070901-02>
  21. Bloomfield MR, Klika AK, Barsoum WK. Antibiotic-coated spacers for total hip arthroplasty infection. *Orthopedics*. 2010;33:649. <https://doi.org/10.3928/01477447-20100722-21>
  22. Gramlich Y, Hagebusch P, Faul P, Klug A, Walter G, Hoffmann R. Two-stage hip revision arthroplasty for periprosthetic joint infection without the use of spacer or cemented implants. *Int Orthop*. 2019;43:2457-66. <https://doi.org/10.1007/s00264-019-04297-y>
  23. Jung J, Schmid NV, Kelm J, Schmitt E, Anagnostakos K. Complications after spacer implantation in the treatment of hip joint infections. *Int J Med Sci*. 2009;6:265-73. <https://doi.org/10.7150/ijms.6.265>
  24. Garvin KL, Hanssen AD. Infection after total hip arthroplasty. Past, present, and future. *J Bone Joint Surg Am*. 1995;77:1576-88. <https://doi.org/10.2106/00004623-199510000-00015>
  25. Pagnano MW, Trousdale RT, Hanssen AD. Outcome after reinfection following reimplantation hip arthroplasty. *Clin Orthop Relat Res*. 1997;(338):192-204. <https://doi.org/10.1097/00003086-199705000-00026>
  26. Gomez MM, Tan TL, Manrique J, Deirmengian GK, Parvizi J. The fate of spacers in the treatment of periprosthetic joint infection. *J Bone Joint Surg Am*. 2015;97:1495-502. <https://doi.org/10.2106/JBJS.N.00958>
  27. George J, Miller EM, Curtis GL, et al. Success of two-stage reimplantation in patients requiring an interim spacer exchange. *J Arthroplasty*. 2018;33(7S):S228-32. <https://doi.org/10.1016/j.arth.2018.03.038>
  28. Jahoda D, Sosna A, Landor I, Vavřík P, Pokorný D, Hudec T. [Two-stage reimplantation using spacers--the method of choice in treatment of hip joint prosthesis-related infections. Comparison with methods used from 1979 to 1998]. *Acta Chir Orthop Traumatol Cech*. 2003;70:17-24. Czech.
  29. Hsieh PH, Shih CH, Chang YH, Lee MS, Shih HN, Yang WE. Two-stage revision hip arthroplasty for infection: comparison between the interim use of antibiotic-loaded cement beads and a spacer prosthesis. *J Bone Joint Surg Am*. 2004;86:1989-97.
  30. Cancienne JM, Werner BC, Bolarinwa SA, Browne JA. Removal of an infected total hip arthroplasty: risk factors for repeat debridement, long-term spacer retention, and mortality. *J Arthroplasty*. 2017;32:2519-22. <https://doi.org/10.1016/j.arth.2017.03.018>
  31. Wang Q, Goswami K, Kuo FC, Xu C, Tan TL, Parvizi J. Two-stage exchange arthroplasty for periprosthetic joint infection: the rate and reason for the attrition after the first stage. *J Arthroplasty*. 2019;34:2749-56. <https://doi.org/10.1016/j.arth.2019.06.021>
  32. Klouche S, Leonard P, Zeller V, et al. Infected total hip arthroplasty revision: one- or two-stage procedure? *Orthop Traumatol Surg Res*. 2012;98:144-50. <https://doi.org/10.1016/j.otsr.2011.08.018>
  33. Leonard HA, Liddle AD, Burke O, Murray DW, Pandit H. Single- or two-stage revision for infected total hip arthroplasty? A systematic review of the literature. *Clin Orthop Relat Res*. 2014;472:1036-42. <https://doi.org/10.1007/s11999-013-3294-y>
  34. Kunutsor SK, Whitehouse MR, Lenguerrand E, Blom AW, Beswick AD; INFORM Team. Re-infection outcomes following one- and two-stage surgical revision of infected knee prosthesis: a systematic review and meta-analysis. *PLoS One*. 2016;11:e0151537. <https://doi.org/10.1371/journal.pone.0151537>
  35. Marczak D, Synder M, Sibiński M, Waśko M, Polgaj M, Kowalczewski J. Comparison of patients treated with or without a spacer in two stage revision hip arthroplasty for periprosthetic joint infection. *J Infect*. 2016;73:520-2. <https://doi.org/10.1016/j.jinf.2016.09.006>
  36. Castellanos J, Flores X, Llusà M, Chiriboga C, Navarro A. The Girdlestone pseudarthrosis in the treatment of infected hip replacements. *Int Orthop*. 1998;22:178-81. <https://doi.org/10.1007/s002640050236>
  37. Alexeeff M, Mahomed N, Morsi E, Garbuz D, Gross A. Structural allograft in two-stage revisions for failed septic hip arthroplasty. *J Bone Joint Surg Br*. 1996;78:213-6.
  38. Charlton WP, Hozack WJ, Teloken MA, Rao R, Bissett GA. Complications associated with reimplantation after girdlestone arthroplasty. *Clin Orthop Relat Res*. 2003;(407):119-26. <https://doi.org/10.1097/00003086-200302000-00019>