

Side-viewing scope insertion using a large-diameter overtube designed for colonoscopy in a patient with a cascade stomach 📺

Hirokazu Saito, Yoshitaka Kadowaki, Atsushi Fujimoto, Kana Ohmoto, Shuji Tada

Department of Gastroenterology, Kumamoto City Hospital, Kumamoto, Japan

Endoscopic retrograde cholangiopancreatography (ERCP) is an invaluable procedure for managing biliopancreatic disorders. Successful side-viewing scope insertion into the descending part of the duodenum is the first step in ERCP. However, delivering the side-viewing scope into the descending part of the duodenum is difficult in some patients with a cascade stomach, as the scope is deflected in the stomach. Forced insertion of a side-viewing scope in such patients may tear the gastric mucosa and result in gastric perforation and bleeding due to excessive shearing force on the gastric wall.^{1,2} To overcome this problem, we used a large-diameter overtube designed for colonoscopy in patients in whom side-viewing scope insertion into the descending part of the duodenum was difficult due to a cascade stomach.

An 88-year-old man who had required biliary stent insertion for acute cholangitis caused by bile duct stones 2 months prior was admitted to our hospital for removal of the biliary stent and bile duct stones. However, scope insertion into the descending part of the duodenum using a side-viewing endoscope (TJF-260V; Olympus, Tokyo, Japan) during ERCP was difficult

because the patient had a cascade stomach that deflected the scope (Fig. 1).

Hence, a large-diameter overtube designed for colonoscopy (ST-CB1; Olympus) was used (Supplementary Video 1). The overtube had a length of 770 mm and outer and inner diameters of 16.2 mm and 13.8 mm, respectively (Fig. 2). We found it better to attach the top hood of the scope to the TJF-260V scope after attaching an overtube. The side-viewing scope with the overtube was easily inserted into the duodenum, as the overtube reduced scope deflection in the stomach (Fig. 3A). After

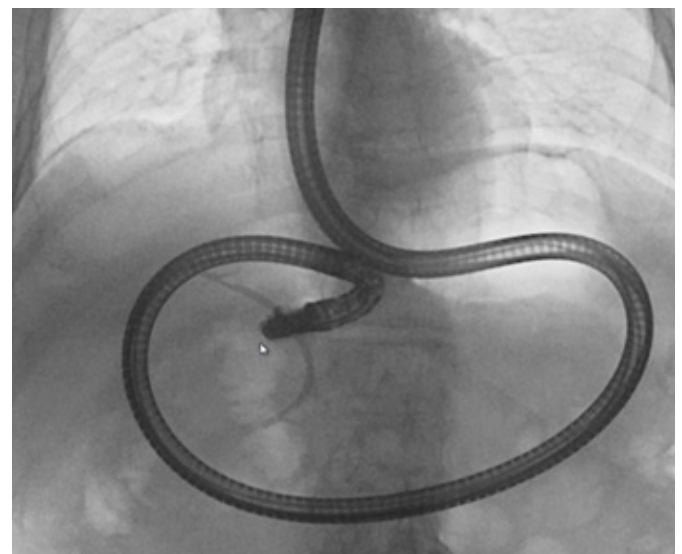


Fig. 1. Side-viewing scope insertion into the duodenum during endoscopic retrograde cholangiopancreatography was difficult given the patient's cascade stomach, which deflected the scope.

Received: February 28, 2022 **Revised:** March 4, 2022
Accepted: March 9, 2022

Correspondence: Hirokazu Saito
Department of Gastroenterology, Kumamoto City Hospital, 4-1-60,
Higashimachi, Higashi-ku, Kumamoto 862-8505, Japan
E-mail: arnestwest@yahoo.co.jp

© This is an Open Access article distributed under the terms of the Creative Commons Attribution Non-Commercial License (<http://creativecommons.org/licenses/by-nc/4.0/>) which permits unrestricted non-commercial use, distribution, and reproduction in any medium, provided the original work is properly cited.




Fig. 2. A large-diameter overtube (ST-CB1; Olympus, Tokyo, Japan), which was designed for colonoscopy, had a length of 770 mm and outer and inner diameters of 16.2 mm and 13.8 mm, respectively.

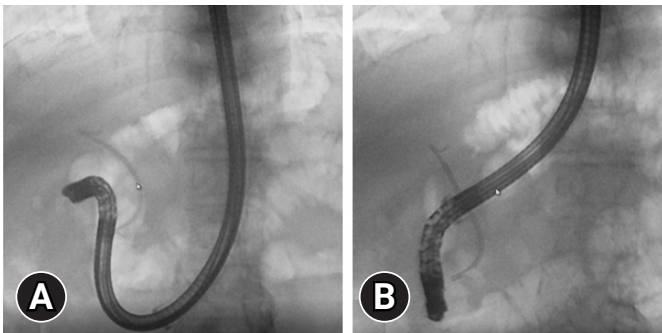


Fig. 3. (A) The overtube reduced the deflection of the scope in the cascade stomach, allowing the side-viewing scope to be easily inserted into the duodenum. (B) After the scope reached the duodenum, the side-viewing scope was carefully straightened.

the scope reached the duodenum, it was carefully straightened (Fig. 3B). The biliary stent and bile duct stones were successfully removed without complications.

In conclusion, the large-diameter overtube designed for colonoscopy can be useful for ERCP in patients in whom side-viewing scope insertion into the descending part of the duodenum is difficult due to scope deflection in the stomach.

Supplementary Material

Supplementary Video 1. Side-viewing scope insertion using a large-diameter overtube designed for colonoscopy (<https://doi.org/10.5946/ce.2022.089.v001>).

Supplementary materials related to this article can be found online at <https://doi.org/10.5946/ce.2022.089>.

Conflicts of Interest

The authors have no potential conflicts of interest.

Funding

None.

Author Contributions

Conceptualization: HS; Investigation: HS, YK, AF, KO, ST; Methodology: HS, YK, AF, KO, ST; Project administration: HS, YK, AF, KO, ST; Resources: HS, YK, AF, KO, ST; Supervision: ST; Validation: HS, ST; Visualization: HS; Writing—original draft: HS; Writing—review & editing: HS, YK, AF, KO, ST.

ORCID

Hirokazu Saito	https://orcid.org/0000-0001-8729-9604
Yoshitaka Kadowaki	https://orcid.org/0000-0003-0227-9802
Atsushi Fujimoto	https://orcid.org/0000-0003-4222-8065
Kana Ohmoto	https://orcid.org/0000-0002-9312-4015
Shuji Tada	https://orcid.org/0000-0001-9087-5457

REFERENCES

1. Chandrasekhara V, Khashab MA, Muthusamy VR, et al. Adverse events associated with ERCP. *Gastrointest Endosc* 2017;85:32–47.
2. Li G, Chen Y, Zhou X, et al. Early management experience of perforation after ERCP. *Gastroenterol Res Pract* 2012;2012:657418.