

# Diagnostic performance of artificial intelligence using cone-beam computed tomography imaging of the oral and maxillofacial region: A scoping review and meta-analysis

Farida Abesi<sup>1,\*</sup>, Mahla Maleki<sup>2</sup>, Mohammad Zamani<sup>2</sup>

<sup>1</sup>Department of Oral and Maxillofacial Radiology, Dental Faculty, Babol University of Medical Sciences, Babol, Iran

<sup>2</sup>Student Research Committee, Babol University of Medical Sciences, Babol, Iran

## ABSTRACT

**Purpose:** The aim of this study was to conduct a scoping review and meta-analysis to provide overall estimates of the recall and precision of artificial intelligence for detection and segmentation using oral and maxillofacial cone-beam computed tomography (CBCT) scans.

**Materials and Methods:** A literature search was done in Embase, PubMed, and Scopus through October 31, 2022 to identify studies that reported the recall and precision values of artificial intelligence systems using oral and maxillofacial CBCT images for the automatic detection or segmentation of anatomical landmarks or pathological lesions. Recall (sensitivity) indicates the percentage of certain structures that are correctly detected. Precision (positive predictive value) indicates the percentage of accurately identified structures out of all detected structures. The performance values were extracted and pooled, and the estimates were presented with 95% confidence intervals (CIs).

**Results:** In total, 12 eligible studies were finally included. The overall pooled recall for artificial intelligence was 0.91 (95% CI: 0.87-0.94). In a subgroup analysis, the pooled recall was 0.88 (95% CI: 0.77-0.94) for detection and 0.92 (95% CI: 0.87-0.96) for segmentation. The overall pooled precision for artificial intelligence was 0.93 (95% CI: 0.88-0.95). A subgroup analysis showed that the pooled precision value was 0.90 (95% CI: 0.77-0.96) for detection and 0.94 (95% CI: 0.89-0.97) for segmentation.

**Conclusion:** Excellent performance was found for artificial intelligence using oral and maxillofacial CBCT images. (*Imaging Sci Dent* 2023; 53: 101-8)

**KEY WORDS:** Artificial Intelligence; Cone-Beam Computed Tomography; Predictive Value of Tests; Dentistry

## Introduction

Cone-beam computed tomography (CBCT) is a special type of X-ray equipment that can prepare images with a lower radiation dose within a shorter scanning time than traditional CT. Among all available imaging options, CBCT is notable because it can provide comprehensive 3-dimensional volumetric data on oral and maxillofacial lesions.<sup>1,2</sup> It has become popular in dental practice over the past 2 decades. However, various factors can negatively affect the

clinical interpretation of CBCT images, such as low interobserver/intraobserver reliability (especially for less experienced practitioners).<sup>3,4</sup> For example, Parker et al.<sup>4</sup> reported that clinicians' experience was associated with their ability to correctly detect periapical lesions on CBCT imaging and could also result in better inter-rater reliability (with better results found for endodontic faculty than for endodontic residents, and better results for endodontic residents than for dental students).

Artificial intelligence refers to a domain of computer science related to building smart machines that perform tasks generally associated with human intelligence. Dental professionals have used artificial intelligence for disease diagnosis and treatment planning in recent years.<sup>5,6</sup> Artificial intelligence can interpret complex characteristics through an automated approach with the highest precision possible;

Received December 27, 2022; Revised February 13, 2023; Accepted February 22, 2023  
Published online March 24, 2023

\*Correspondence to : Dr. Farida Abesi

Dental Materials Research Center, Department of Oral and Maxillofacial Radiology, Dental School, Babol University of Medical Sciences, Ganjafrooz street, Babol, Mazandaran, Iran  
Tel) 98-911-3132-388, E-mail) abesifarida1@gmail.com

Copyright © 2023 by Korean Academy of Oral and Maxillofacial Radiology

This is an Open Access article distributed under the terms of the Creative Commons Attribution Non-Commercial License (<http://creativecommons.org/licenses/by-nc/3.0>) which permits unrestricted non-commercial use, distribution, and reproduction in any medium, provided the original work is properly cited.

Imaging Science in Dentistry · pISSN 2233-7822 eISSN 2233-7830

therefore, this method can enhance diagnostic accuracy as a supplement to other imaging methods, especially for junior or general dental practitioners.<sup>7,8</sup> According to recent reviews, most studies have found that the diagnostic accuracy of artificial intelligence models using dental and maxillofacial radiology (panoramic and cephalometric radiographs, and CBCT images) was higher than 90%.<sup>7,8</sup>

A possible solution for improving the diagnostic performance of CBCT imaging would be to integrate it with artificial intelligence. Prior studies have endeavored to propose new artificial intelligence systems for clinical practice using oral and maxillofacial CBCT; however, those studies reported varying diagnostic values for the given artificial intelligence models.<sup>9-11</sup> Setzer et al.<sup>12</sup> developed a deep learning algorithm (convolutional neural network) for the automated detection of preapical lesions with a recall of 0.87 and a precision of 0.93. In another study by Lin et al.,<sup>13</sup> which developed a deep learning technique (convolutional neural network [U-Net]) for the automatic segmentation of the pulp cavity and tooth, the authors reported a recall of 0.91 and a precision of 0.93 for the artificial intelligence application. However, there is a limited number of reviews exploring the performance of artificial intelligence applications in dentomaxillofacial CBCT imaging, and existing reviews have limitations in the methodology and studies included.<sup>14,15</sup> Therefore, a comprehensive review study is needed to resolve debates on this subject. The present study performed a scoping review and meta-analysis to provide overall estimates of the recall and precision values of artificial intelligence methods using oral and maxillofacial CBCT imaging. Recall (sensitivity) indicates the proportion of certain structures that are correctly detected. Precision (positive predictive value) indicates the proportion of accurately identified structures out of all detected structures.

## Materials and Methods

### Information sources and search strategy

A search of the medical literature was carried out using electronic databases (Embase, PubMed, and Scopus) from inception to October 31, 2022, with no language restriction. The following keywords were used: *artificial intelligence* OR *deep learning* OR *machine learning* OR *automatic* OR *automated* AND *cone-beam computed tomography* OR *CBCT*. The search was applied to the title/abstract field. Further hand-searching was also conducted using the references of the included articles. The present study was report-

ed in accordance with the Preferred Reporting Items for Systematic Reviews and Meta-Analysis (PRISMA) guideline.<sup>16</sup> This review was not registered.

### Inclusion and exclusion criteria

Eligible studies were those that investigated artificial intelligence systems using oral and maxillofacial CBCT images for the automatic detection or segmentation of anatomical landmarks or pathological lesions. The studies had to report the outcomes in terms of recall and precision values. The exclusion criteria included 1) reviews, case reports, editorials, and letters to the editor; 2) duplicate publications; 3) studies without extractable data on the study outcome; and 4) studies for which the full texts were not available.

### Study selection and data extraction

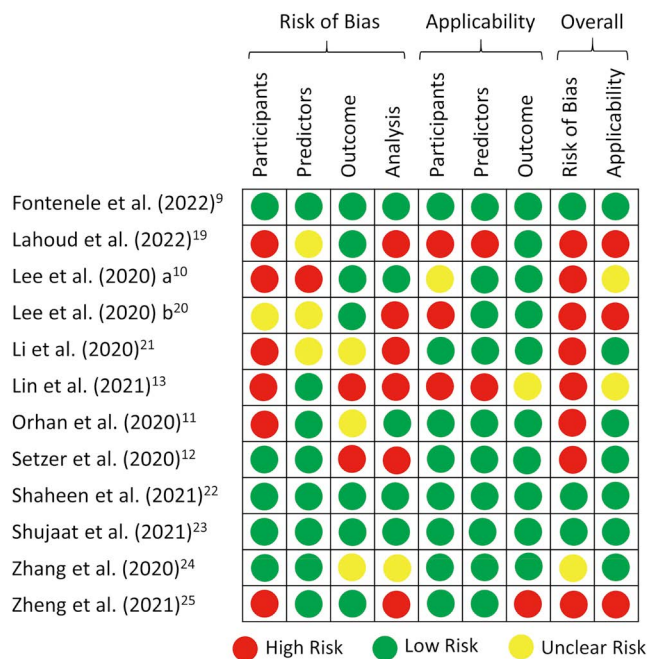
The titles and abstracts of the identified citations were screened by 3 independent reviewers (FA, MM, and MZ) using pre-designed eligibility forms. The full texts of the relevant papers were obtained and evaluated for more details when necessary. Any disagreements were resolved by consensus. The following data were extracted independently by 3 investigators (FA, MM, and MZ) for each eligible study into a Microsoft Excel spreadsheet (Microsoft Corp, Redmond, WA USA): the first author's name, publication year, sample size, artificial intelligence technique, study design, validation method, recall value, and precision value. Google Translate was used to translate non-English reports.

### Risk of bias assessment

The risk of bias of the enrolled studies was examined using the adapted criteria of the Prediction Model Risk of Bias Assessment Tool (PROBAST).<sup>17</sup> Based on PROBAST, the studies were rated for risk of bias and concerns about applicability as low, high, or unclear. The details of this assessment tool are summarized in Figure 1.

### Statistical analysis

The primary outcomes for this review were the recall and precision values of artificial intelligence systems using oral and maxillofacial CBCT for the detection or segmentation of anatomical landmarks or pathological lesions. The diagnostic performance (recall/precision) values of artificial intelligence were pooled using a random-effects model. The pooled diagnostic performance values were also estimated for detection and segmentation as a subgroup analysis. The estimates were presented with 95% confidence intervals



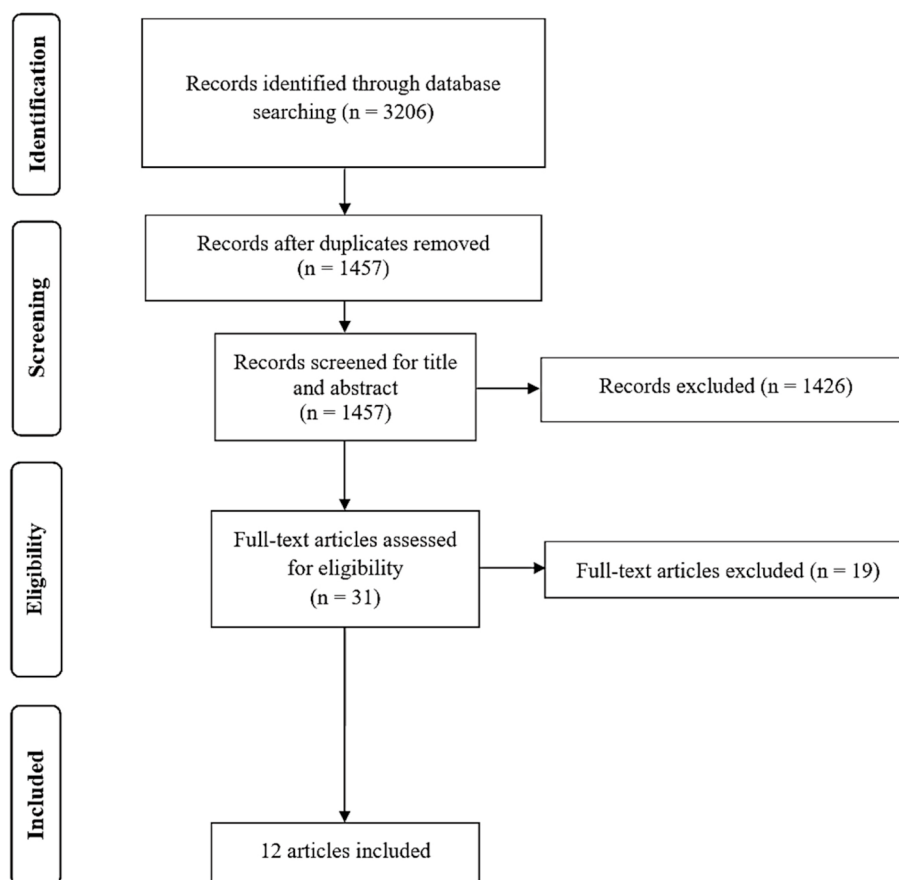
**Fig. 1.** Risk of bias assessment of the included studies according to the Prediction Model Risk of Bias Assessment Tool (PROBAST).

(CIs). Heterogeneity between the studies was examined by the  $I^2$  index, which ranges from 0.0% to 100.0%, and a  $P$ -value less than 0.10 was considered significant.<sup>18</sup> Forest plots were utilized to describe the results of the meta-analysis. Publication bias was evaluated using a funnel plot. All statistical analyses were performed using Comprehensive Meta-Analysis V2 software (Biostat, Englewood, NJ, USA).

## Results

### Search results and study selection

The initial database search yielded 3,206 citations. After the exclusion of duplicates and unsuitable articles during the title/abstract screening, 31 articles remained, and their full texts were obtained and assessed. After removing ineligible papers, 12 studies were finally included.<sup>9-13,19-25</sup> A flowchart of the search strategy and results at each stage is depicted in Figure 2, in accordance with the PRISMA guidelines.

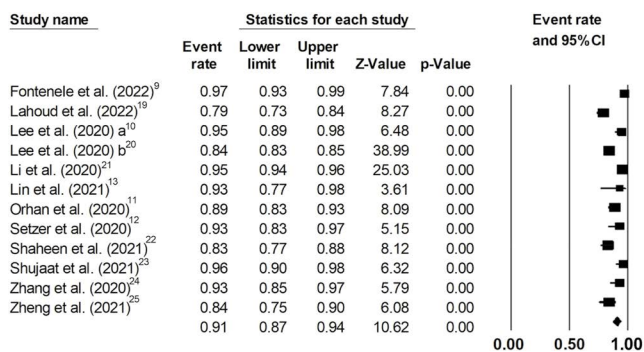


**Fig. 2.** PRISMA flow diagram.

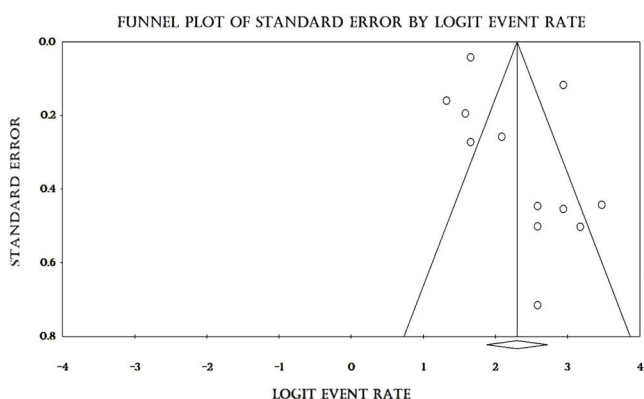
**Table 1.** Basic information of the individual studies included

Study	Objective	Sample size (n)	Convolutional neural network architectures	Validation	Outcomes of interest
Fontenele et al. (2022) <sup>9</sup>	Tooth segmentation	175 scans (500 teeth) for training (140 CBCT scans - 400 teeth) and validation (35 CBCT scans - 100 teeth)	3D U-Net	Split-sample validation	Recall: 0.97 Precision: 1.00
Lahoud et al. (2022) <sup>19</sup>	Mandibular canal segmentation	235 scans (166 cases for training, 39 cases for testing, 30 cases for final validation)	3D U-Net	Split-sample validation	Recall: 0.79 Precision: 0.78
Lee et al. (2020) a <sup>10</sup>	Tooth segmentation	102 scans (69 datasets and 1066 images for training, 1 dataset and 400 images for validation, 32 datasets and 151 images for testing)	UDS-Net	Split-sample validation	Recall: 0.95 Precision: 0.88
Lee et al. (2020) b <sup>20</sup>	Temporomandibular joint osteoarthritis detection	314 patients (3,514 images for training, 600 images for testing)	Single-shot detector	Split-sample validation	Recall: 0.84 Precision: 0.85
Li et al. (2020) <sup>21</sup>	Tooth root segmentation	24 patients (1160 images) for training, 5 patients (361 images) for testing	Attention U-Net/ recurrent neural networks	Split-sample validation	Recall: 0.95 Precision: 0.96
Lin et al. (2021) <sup>13</sup>	Pulp cavity and tooth segmentation	30 teeth (25 sets for training, 5 sets for testing)	U-Net	External validation	Recall: 0.93 Precision: 0.91
Orhan et al. (2020) <sup>11</sup>	Periapical pathosis detection	153 periapical lesion images (109 patients)	U-Net	External validation	Recall: 0.89 Precision: 0.95
Setzer et al. (2020) <sup>12</sup>	Periapical lesion detection	20 CBCT volumes (61 roots); 16 images for training, 4 images for validation	Multilabel U-Net	Five-fold cross-validation	Recall: 0.93 Precision: 0.87
Shahen et al. (2021) <sup>22</sup>	Multi-class tooth segmentation	186 scans (140 scans for training, 35 scans for validation, 11 scans for testing)	3D U-Net	Split-sample validation	Recall: 0.83 Precision: 0.98
Shujaat et al. (2021) <sup>23</sup>	Pharyngeal airway space segmentation	103 scans (48 scans for training, 30 scans for validation, 25 scans for testing)	3D U-Net	Split-sample validation	Recall: 0.96 Precision: 0.97
Zhang et al. (2020) <sup>24</sup>	Cranio-maxillofacial bone segmentation and landmark digitization	77 CBCT scans	Fully convolutional network (FCN)/FCN2	Five-fold cross-validation	Recall: 0.93 Precision: 0.94
Zheng et al. (2021) <sup>25</sup>	Periapical lesion detection	20 patients (100 images); 15 patients for training, 5 patients for validation	Dense U-Net	Four-fold cross-validation	Recall: 0.84 Precision: 0.90

CBCT: cone-beam computed tomography



**Fig. 3.** Recall values of artificial intelligence using oral and maxillofacial cone-beam computed tomography imaging.



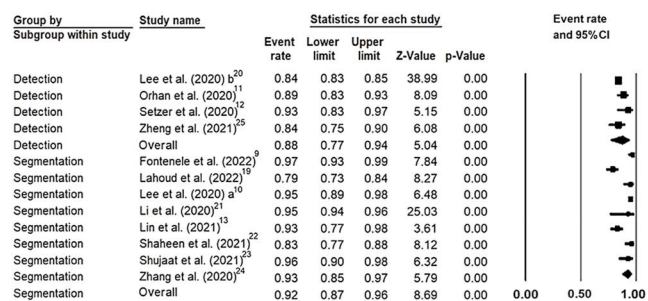
**Fig. 4.** Funnel plot assessing publication bias across studies assessing recall values of artificial intelligence using oral and maxillofacial cone-beam computed tomography imaging.

**Study characteristics**

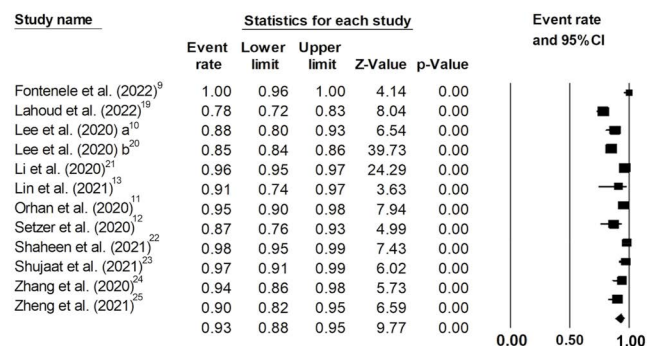
In total, 12 studies were included in this scoping review and meta-analysis. The publication date ranged from 2020 to 2022. The language of all papers was English. The technique of artificial intelligence in all studies was deep learning. The detection tasks included the detection of temporomandibular joint osteoarthritis and periapical lesions. The segmentation tasks comprised the segmentation of teeth, the mandibular canal, pulp cavities, the pharyngeal airway space, and craniomaxillofacial bone. The extracted data are presented in Table 1 and in forest plots.

**Recall**

There were 12 studies that reported recall values for artificial intelligence using CBCT imaging. The lowest and highest recall values reported were 0.79 and 0.97, respectively. The overall pooled recall for artificial intelligence was 0.91 (95% CI: 0.87-0.94;  $I^2=92.8\%$ ;  $P<0.001$ ) (Fig. 3). The funnel plot was suggestive of publication bias (Fig.



**Fig. 5.** Recall values of artificial intelligence systems for detection and segmentation using oral and maxillofacial cone-beam computed tomography scans.

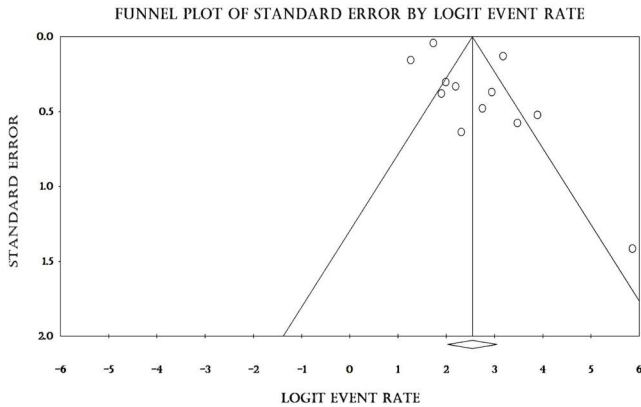


**Fig. 6.** Precision values of artificial intelligence systems using oral and maxillofacial cone-beam computed tomography imaging.

4). The detection and segmentation performance of artificial intelligence using CBCT were evaluated in 4 and 8 studies, respectively; a subgroup analysis showed that the overall pooled recall for artificial intelligence was 0.88 (95% CI: 0.77-0.94;  $I^2=90.4\%$ ;  $P<0.001$ ) for detection and 0.92 (95% CI: 0.87-0.96;  $I^2=95.9\%$ ;  $P<0.001$ ) for segmentation (Fig. 5).

**Precision**

Twelve studies reported precision values for artificial intelligence using CBCT. The precision in the different studies varied from 0.78 to 1.00. The overall pooled precision for artificial intelligence was 0.93 (95% CI: 0.88-0.95;  $I^2=93.5\%$ ;  $P<0.001$ ) (Fig. 6). The funnel plot was relatively symmetrical (Fig. 7). The detection and segmentation performance of artificial intelligence using CBCT were assessed in 4 and 8 studies, respectively. In a subgroup analysis, the overall pooled precision for artificial intelligence was 0.90 (95% CI: 0.77-0.96;  $I^2=91.7\%$ ;  $P<0.001$ ) for detection and 0.94 (95% CI: 0.89-0.97;  $I^2=96.8\%$ ;  $P<0.001$ ) for segmentation (Fig. 8).



**Fig. 7.** Funnel plot assessing publication bias across studies assessing precision values of artificial intelligence using oral and maxillofacial cone-beam computed tomography imaging.

Group by Subgroup within study	Study name	Statistics for each study					Event rate and 95%CI
		Event rate	Lower limit	Upper limit	Z-Value	p-Value	
Detection	Lee et al. (2020) <sup>b20</sup>	0.85	0.84	0.86	39.73	0.00	
Detection	Orhan et al. (2020) <sup>11</sup>	0.95	0.90	0.98	7.94	0.00	
Detection	Setzer et al. (2020) <sup>12</sup>	0.87	0.76	0.93	4.99	0.00	
Detection	Zheng et al. (2021) <sup>25</sup>	0.90	0.82	0.95	6.59	0.00	
Detection	Overall	0.90	0.77	0.96	4.45	0.00	
Segmentation	Fontenele et al. (2022) <sup>9</sup>	1.00	0.96	1.00	4.14	0.00	
Segmentation	Lahoud et al. (2022) <sup>19</sup>	0.78	0.72	0.83	8.04	0.00	
Segmentation	Lee et al. (2020) <sup>a10</sup>	0.88	0.80	0.93	6.54	0.00	
Segmentation	Li et al. (2020) <sup>21</sup>	0.96	0.95	0.97	24.29	0.00	
Segmentation	Lin et al. (2021) <sup>13</sup>	0.91	0.74	0.97	3.63	0.00	
Segmentation	Shaheen et al. (2021) <sup>22</sup>	0.98	0.95	0.99	7.43	0.00	
Segmentation	Shujaat et al. (2021) <sup>23</sup>	0.97	0.91	0.99	6.02	0.00	
Segmentation	Zhang et al. (2020) <sup>4</sup>	0.94	0.86	0.98	5.73	0.00	
Segmentation	Overall	0.94	0.89	0.97	7.45	0.00	

**Fig. 8.** Precision values of artificial intelligence for detection and segmentation using oral and maxillofacial cone-beam computed tomography scans.

## Discussion

Despite the advantages of CBCT systems, the measurement of CBCT findings may be negatively influenced by technical errors from clinicians. Recent developments in artificial intelligence could establish learning models (especially deep learning) for the computer-aided clinical diagnosis of medical and dental health problems. These algorithms can automatically learn imaging patterns for discrimination and efficiently discover the relevant features concerning a specific class of object. Several recent studies have focused on the use of artificial intelligence models with oral and maxillofacial CBCT, with the goal of assisting practitioners in better patient management;<sup>14,19,23,26</sup> however, no articles have comprehensively provided overall estimates for the diagnostic performance of these applications. Therefore, a scoping review was done on the available data regarding this topic in the literature. Medical databases were searched using various keywords to find studies that reported the recall and precision values for artificial intelligence systems

using oral and maxillofacial CBCT images.

After screening thousands of sources with rigorous suitability criteria, a total of 12 eligible surveys were included in this scoping review and meta-analysis. The overall pooled recall of artificial intelligence was 0.91. The subgroup analysis showed that the overall pooled recall of artificial intelligence was 0.88 for detection and 0.92 for segmentation. The overall pooled precision of artificial intelligence was 0.93. The subgroup analysis found that the overall pooled precision of artificial intelligence was 0.90 for detection and 0.94 for segmentation. Overall, the results of the present study showed excellent performance of artificial intelligence in the detection and segmentation of oral and maxillofacial CBCT scans.

The high diagnostic accuracy of artificial intelligence systems integrated with CBCT has led to their clinical usage in different dental fields, such as endodontics, implantology, oral and maxillofacial surgery, and orthodontics. The use of artificial intelligence could potentially reduce manual labor, wasted time, the number of required images, and concerns about likely health risks caused by excessive radiation doses.<sup>27-30</sup> In the endodontics field, deep learning models have been proposed and trained for detecting and segmenting teeth, alveolar bone, and periapical lesions (e.g., periapical periodontitis), using approaches that integrate orofacial anatomical knowledge, requiring fewer images for training.<sup>12,25,30</sup> With respect to dental implant planning, 3-dimensional deep convolutional neural network and region-based convolutional neural network algorithms have been developed for qualitative and quantitative evaluations of alveolar bone with high performance.<sup>29,31,32</sup> Some studies have used deep learning and machine learning techniques to diagnose and classify temporomandibular joint diseases, perform maxillary and mandible segmentation, and guide oral and maxillofacial surgeons with acceptable diagnostic accuracy.<sup>28,33,34</sup> In the orthodontics field, some studies have proposed deep learning frameworks for cluster-based segmentation and automatic landmark detection in cephalometric analysis.<sup>35,36</sup>

Tooth segmentation is an essential step in generating 3-dimensional models for the clinical management of maxillofacial abnormalities. Segmentation is commonly conducted manually, but manual segmentation is a labor-intensive task and depends on the operator's expertise.<sup>37</sup> CBCT segmentation has some challenges, such as inadequate density, image artifacts, noise, and limited contrast resolution.<sup>37,38</sup> The development and validation of new artificial intelligence systems with large datasets (such as the automated convolutional neural network [U-Net] and ToothNet algorithms) in

recent years have been solutions to partially overcome the weaknesses of manual CBCT segmentation.<sup>39,40</sup>

The present scoping review and meta-analysis has some limitations. First, there was high heterogeneity between the individual studies, which could be explained by differences in study location, objectives, sample size, and interobserver/intraobserver agreement. A subgroup analysis was performed according to system tasks to minimize the influence of heterogeneity; however, the heterogeneity remained high for the recall and precision outcomes. It is noteworthy that publication bias could potentially explain the heterogeneity for recall. Second, a high risk of bias was observed in most studies, mainly resulting from inadequate sample size and incomplete reporting. Overall, it is proposed to design and conduct more homogeneous research. Third, the gray literature was not searched for unpublished studies. Finally, it is also suggested that systematic reviews and meta-analyses should be conducted that include other diagnostic performance indices, such as the Dice similarity coefficient.

In conclusion, the results of this scoping review and meta-analysis demonstrated the excellent performance of artificial intelligence in the detection and segmentation of oral and maxillofacial CBCT scans. Integrating artificial intelligence and CBCT imaging has the potential to speed up the dental workflow, streamline oral healthcare, and facilitate preventive dentistry.

**Conflicts of Interest:** None

## References

1. Signorelli L, Patcas R, Peltomäki T, Schätzle M. Radiation dose of cone-beam computed tomography compared to conventional radiographs in orthodontics. *J Orofac Orthop* 2016; 77: 9-15.
2. Abesi F, Alimohamadi M. Cone beam computed tomography (CBCT) findings of fungal sinusitis in post COVID-19 patient: a case report. *Caspian J Intern Med* 2022; 13(Suppl 3): 307-10.
3. Barnett CW, Glickman GN, Umorin M, Jalali P. Interobserver and intraobserver reliability of cone-beam computed tomography in identification of apical periodontitis. *J Endod* 2018; 44: 938-40.
4. Parker JM, Mol A, Rivera EM, Tawil PZ. Cone-beam computed tomography uses in clinical endodontics: observer variability in detecting periapical lesions. *J Endod* 2017; 43: 184-7.
5. Fatima A, Shafi I, Afzal H, Díez IT, Lourdes DR, Breñosa J, et al. Advancements in dentistry with artificial intelligence: current clinical applications and future perspectives. *Healthcare (Basel)* 2022; 10: 2188.
6. Agrawal P, Nikhade P. Artificial intelligence in dentistry: past, present, and future. *Cureus* 2022; 14: e27405.
7. Hung K, Montalvao C, Tanaka R, Kawai T, Bornstein MM. The use and performance of artificial intelligence applications in dental and maxillofacial radiology: a systematic review. *Dentomaxillofac Radiol* 2020; 49: 20190107.
8. Khanagar SB, Al-Ehaideb A, Maganur PC, Vishwanathaiah S, Patil S, Baeshen HA, et al. Developments, application, and performance of artificial intelligence in dentistry - a systematic review. *J Dent Sci* 2021; 16: 508-22.
9. Fontenele RC, Gerhardt MD, Pinto JC, Van Gerven A, Willems H, Jacobs R, et al. Influence of dental fillings and tooth type on the performance of a novel artificial intelligence-driven tool for automatic tooth segmentation on CBCT images - a validation study. *J Dent* 2022; 119: 104069.
10. Lee S, Woo S, Yu J, Seo J, Lee J, Lee C. Automated CNN-based tooth segmentation in cone-beam ct for dental implant planning. *IEEE Access* 2020; 8: 50507-18.
11. Orhan K, Bayrakdar IS, Ezhov M, Kravtsov A, Özyürek T. Evaluation of artificial intelligence for detecting periapical pathosis on cone-beam computed tomography scans. *Int Endod J* 2020; 53: 680-9.
12. Setzer FC, Shi KJ, Zhang Z, Yan H, Yoon H, Mupparapu M, et al. Artificial intelligence for the computer-aided detection of periapical lesions in cone-beam computed tomographic images. *J Endod* 2020; 46: 987-93.
13. Lin X, Fu Y, Ren G, Yang X, Duan W, Chen Y, et al. Micro-computed tomography-guided artificial intelligence for pulp cavity and tooth segmentation on cone-beam computed tomography. *J Endod* 2021; 47: 1933-41.
14. Badr FF, Jadu FM. Performance of artificial intelligence using oral and maxillofacial CBCT images: a systematic review and meta-analysis. *Niger J Clin Pract* 2022; 25: 1918-27.
15. Mureşanu S, Almăşan O, Hedeşiu M, Dioşan L, Dinu C, Jacobs R. Artificial intelligence models for clinical usage in dentistry with a focus on dentomaxillofacial CBCT: a systematic review. *Oral Radiol* 2023; 39: 18-40.
16. Moher D, Liberati A, Tetzlaff J, Altman DG, PRISMA Group. Preferred reporting items for systematic reviews and meta-analyses: the PRISMA statement. *PLoS Med* 2009; 6: e1000097.
17. Moons KG, Wolff RF, Riley RD, Whiting PF, Westwood M, Collins GS, et al. PROBAST: a tool to assess risk of bias and applicability of prediction model studies: explanation and elaboration. *Ann Intern Med* 2019; 170: W1-33.
18. Higgins JP, Thompson SG, Deeks JJ, Altman DG. Measuring inconsistency in meta-analyses. *BMJ* 2003; 327: 557-60.
19. Lahoud P, Diels S, Niclaes L, Van Aelst S, Willems H, Van Gerven A, et al. Development and validation of a novel artificial intelligence driven tool for accurate mandibular canal segmentation on CBCT. *J Dent* 2022; 116: 103891.
20. Lee KS, Kwak HJ, Oh JM, Jha N, Kim YJ, Kim W, et al. Automated detection of TMJ osteoarthritis based on artificial intelligence. *J Dent Res* 2020; 99: 1363-7.
21. Li Q, Chen K, Han L, Zhuang Y, Li J, Lin J. Automatic tooth roots segmentation of cone beam computed tomography image sequences using U-net and RNN. *J Xray Sci Technol* 2020; 28: 905-22.
22. Shaheen E, Leite A, Alqahtani KA, Smolders A, Van Gerven A, Willems H, et al. A novel deep learning system for multi-class tooth segmentation and classification on cone beam computed tomography. A validation study. *J Dent* 2021; 115: 103865.
23. Shujaat S, Jazil O, Willems H, Van Gerven A, Shaheen E, Politis

- C, et al. Automatic segmentation of the pharyngeal airway space with convolutional neural network. *J Dent* 2021; 111: 103705.
24. Zhang J, Liu M, Wang L, Chen S, Yuan P, Li J, et al. Context-guided fully convolutional networks for joint craniomaxillofacial bone segmentation and landmark digitization. *Med Image Anal* 2020; 60: 101621.
25. Zheng Z, Yan H, Setzer FC, Shi KJ, Mupparapu M, Li J. Anatomically constrained deep learning for automating dental CBCT segmentation and lesion detection. *IEEE Trans Autom Sci Eng* 2021; 18: 603-14.
26. Abesi F, Motaharinia S, Moudi E, Haghanifar S, Khafri S. Prevalence and anatomical variations of maxillary sinus septa: a cone-beam computed tomography analysis. *J Clin Exp Dent* 2022; 14: e689-93.
27. Jaskari J, Sahlsten J, Järnstedt J, Mehtonen H, Karhu K, Sundqvist O, et al. Deep learning method for mandibular canal segmentation in dental cone beam computed tomography volumes. *Sci Rep* 2020; 10: 5842.
28. Rasteau S, Ernenwein D, Savoldelli C, Bouletreau P. Artificial intelligence for oral and maxillo-facial surgery: a narrative review. *J Stomatol Oral Maxillofac Surg* 2022; 123: 276-82.
29. Sorkhabi MM, Khajeh MS. Classification of alveolar bone density using 3-D deep convolutional neural network in the cone-beam CT images: a 6-month clinical study. *Measurement* 2019; 148: 106945.
30. Liao WC, Chen CH, Pan YH, Chang MC, Jeng JH. Vertical root fracture in non-endodontically and endodontically treated teeth: current understanding and future challenge. *J Pers Med* 2021; 11: 1375.
31. Kurt Bayrakdar S, Orhan K, Bayrakdar IS, Bilgir E, Ezhov M, Gusarev M, et al. A deep learning approach for dental implant planning in cone-beam computed tomography images. *BMC Med Imaging* 2021; 21: 86.
32. Cha JY, Yoon HI, Yeo IS, Huh KH, Han JS. Peri-implant bone loss measurement using a region-based convolutional neural network on dental periapical radiographs. *J Clin Med* 2021; 10: 1009.
33. Park S, Kim H, Shim E, Hwang BY, Kim Y, Lee JW, et al. Deep learning-based automatic segmentation of mandible and maxilla in multi-center ct images. *Appl Sci (Basel)* 2022; 12: 1358.
34. Jha N, Lee KS, Kim YJ. Diagnosis of temporomandibular disorders using artificial intelligence technologies: a systematic review and meta-analysis. *PLoS One* 2022; 17: e0272715.
35. Codari M, Caffini M, Tartaglia GM, Sforza C, Baselli G. Computer-aided cephalometric landmark annotation for CBCT data. *Int J Comput Assist Radiol Surg* 2017; 12: 113-21.
36. Torosdagli N, Liberton DK, Verma P, Sincan M, Lee JS, Bagci U. Deep geodesic learning for segmentation and anatomical landmarking. *IEEE Trans Med Imaging* 2019; 38: 919-31.
37. Lahoud P, EzEldeen M, Beznik T, Willems H, Leite A, Van Gerven A, et al. Artificial intelligence for fast and accurate 3-dimensional tooth segmentation on cone-beam computed tomography. *J Endod* 2021; 47: 827-35.
38. Kim YH, Jeon KJ, Lee C, Choi YJ, Jung HI, Han SS. Analysis of the mandibular canal course using unsupervised machine learning algorithm. *PLoS One* 2021; 16: e0260194.
39. Cui Z, Li C, Wang W. ToothNet: automatic tooth instance segmentation and identification from cone beam CT images. *Proceedings of 2019 IEEE/CVF Conference on Computer Vision and Pattern Recognition*; 2019 Jun 15-20; Long Beach, USA: IEEE; 2019, p. 6361-70.
40. Cui Z, Fang Y, Mei L, Zhang B, Yu B, Liu J, et al. A fully automatic AI system for tooth and alveolar bone segmentation from cone-beam CT images. *Nat Commun* 2022; 13: 2096.