

Letter to the Editor



Dot-Like Hippocampal Hyperintensities on Diffusion-Weighted MRI in a Patient With Vomiting Caused by Benign Paroxysmal Positional Vertigo Without Amnesia

Dae-Seop Shin , Eu Jene Choi

Department of Neurology, Soonchunhyang University Gumi Hospital, Gumi, Korea

OPEN ACCESS

Received: Jun 4, 2023

Revised: Jul 9, 2023

Accepted: Jul 19, 2023

Published online: Jul 24, 2023

Correspondence to

Eu Jene Choi

Department of Neurology, Soonchunhyang University Gumi Hospital, 179 Igongdan-ro, Gumi 39371, Korea.

Email: suitomoy@gmail.com

© 2023 Korean Dementia Association

This is an Open Access article distributed under the terms of the Creative Commons Attribution Non-Commercial License (<https://creativecommons.org/licenses/by-nc/4.0/>) which permits unrestricted non-commercial use, distribution, and reproduction in any medium, provided the original work is properly cited.

ORCID iDs

Dae-Seop Shin

<https://orcid.org/0009-0009-9980-2241>

Eu Jene Choi

<https://orcid.org/0000-0002-0826-6001>

Conflict of Interest

The authors have no financial conflicts of interest.

Author Contributions

Conceptualization: Shin DS, Choi EJ;
Investigation: Shin DS; Methodology: Shin DS;
Supervision: Choi EJ; Writing - original draft: Shin DS; Writing - review & editing: Shin DS, Choi EJ.

<https://dnd.or.kr>

Dear Editor,

Dot-like hippocampal hyperintensities on diffusion-weighted magnetic resonance imaging (DWI) are characteristic findings of transient global amnesia (TGA).¹ These hyperintensities present as single or multiple hyperintensities in one or both hippocampi. However, some studies have reported that these lesions were present in patients without amnesia, a characteristic symptom of TGA.²⁻⁴ We report a case of dot-like hippocampal hyperintensities on DWI in a patient with benign paroxysmal positional vertigo without amnesia.

A 64-year-old woman presented to the hospital with the wake-up onset of vertigo, which developed suddenly upon turning around. She had vomited several times before visiting the hospital and complained of nausea. She did not complain of headache or amnesia, nor did she ask the same questions repeatedly during history-taking. She was taking medications for hyperlipidemia and had no other relevant medical history. Her vital signs were stable, and her orientations of time, place, and person remained intact. No spontaneous nystagmus was observed. However, stronger nystagmus was induced on the right side during the head roll test than on the left side. Laboratory examinations, including lipid profiling, revealed no abnormal findings. DWI performed eight hours after symptom onset revealed two dot-like high signal intensities with diffusion restriction in the right hippocampus (**Fig. 1**). The magnetic resonance angiography, electrocardiography, Holter monitoring, and transthoracic and transesophageal echocardiographic findings were normal. She was diagnosed with benign paroxysmal positional vertigo of the horizontal semicircular canal. The patient's symptoms subsided following canalith repositioning maneuvers. The patient had no specific complaints three weeks after discharge.

Patients with TGA typically present with amnesia, which can involve patients asking the same questions repeatedly. These patients usually recover within 24 hours.⁵ However, there are reports of dot-like lesions in the hippocampus accompanied by other symptoms without amnesia.²⁻⁴ Förster et al.³ reported 10 non-TGA patients with isolated punctate ischemic lesions in the hippocampus and classified them as a hippocampal infarction

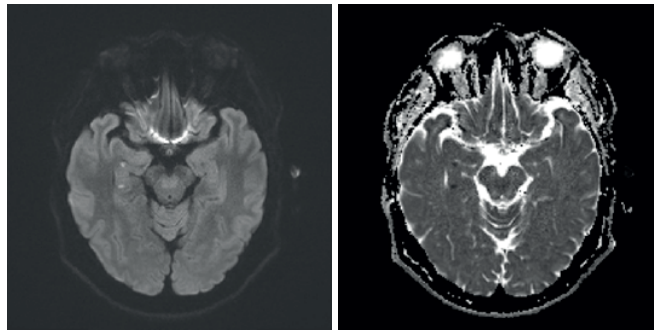


Fig. 1. Brain DWI of the patient. Two dot-like high signal intensities with diffusion restriction were observed in the right hippocampus.
DWI: diffusion-weighted magnetic resonance imaging.

group. Only some displayed disorientation and memory defects, while most presented with atypical symptoms, such as nausea, vertigo, and aphasia, which were less likely to be directly associated with the lesion. Jeong et al.⁴ compared eight non-TGA patients who showed dot-like hippocampal hyperintensities on DWI without amnesia to 16 TGA patients. Four of the non-TGA group underwent DWI owing to dizziness or vertigo, all of whom had a single hippocampal lesion. Valsalva-associated activities, such as vomiting, preceded in >50% of the patients in both groups. A Valsalva maneuver can precede TGA, which increases intrathoracic pressure and reduces venous return to the heart.⁶ Venous congestion of the hippocampus due to venous back pressure has been proposed as the pathophysiology of TGA.⁶ Jeong et al.⁴ suggested that a Valsalva maneuver could cause asymptomatic hippocampal lesions. However, symptoms may range from typical symptoms of TGA to asymptomatic, depending on individual susceptibility.⁴ Neuropsychological tests can help clarify mild memory impairments that patients do not recognize, but it is difficult to conduct these tests on patients complaining of severe vertigo or vomiting, like our patient. Our patient's hyperlipidemia was well-controlled, and no specific stroke risk factors were identified. It is likely that the Valsalva maneuver, caused by vomiting, resulted in venous ischemia in the hippocampus. To our knowledge, this is the first report of multiple dot-like hyperintensities in the hippocampus of a patient with benign paroxysmal positional vertigo. The pathophysiology of the DWI dot-like hyperintensities associated with TGA or diseases other than TGA is still unclear. It is also unclear what multiple dot-like hyperintensities suggest. Further studies focusing on a predisposing hippocampal microstructure or individual susceptibility are needed.

REFERENCES

1. Förster A, Griebe M, Gass A, Kern R, Hennerici MG, Szabo K. Diffusion-weighted imaging for the differential diagnosis of disorders affecting the hippocampus. *Cerebrovasc Dis* 2012;33:104-115.
[PUBMED](#) | [CROSSREF](#)
2. Park JH, Oh CG, Kim SH, Lee SH, Jang JW. Hippocampal lesions of diffusion weighted magnetic resonance image in patients with headache without symptoms of transient global amnesia. *Dement Neurocogn Disord* 2017;16:87-90.
[PUBMED](#) | [CROSSREF](#)
3. Förster A, Al-Zghloul M, Wenz H, Böhme J, Groden C, Neumaier-Probst E. Isolated punctuate hippocampal infarction and transient global amnesia are indistinguishable by means of MRI. *Int J Stroke* 2017;12:292-296.
[PUBMED](#) | [CROSSREF](#)
4. Jeong M, Jin J, Kim JH, Moon Y, Choi JW, Kim HY. Incidental hippocampal hyperintensity on diffusion-weighted MRI. *Neurologist* 2017;22:103-106.
[PUBMED](#) | [CROSSREF](#)

5. Spiegel DR, Smith J, Wade RR, Cherukuru N, Ursani A, Dobruskina Y, et al. Transient global amnesia: current perspectives. *Neuropsychiatr Dis Treat* 2017;13:2691-2703.
[PUBMED](#) | [CROSSREF](#)
6. Lewis SL. Aetiology of transient global amnesia. *Lancet* 1998;352:397-399.
[PUBMED](#) | [CROSSREF](#)