Safety and Health at Work 14 (2023) 118–123

Contents lists available at ScienceDirect

Safety and Health at Work

journal homepage: www.e-shaw.net

Original article

The Effects of Resveratrol on Silica-Induced Lung Oxidative Stress and Inflammation in Rat

Maryam Esfahani [1], Amir Hossein Rahbar [2], Sara Soleimani Asl [3], Saed Bashirian [4], Effat Sadat Mir Moeini [5], Fereshteh Mehri [6,*]

[1] Nutrition Health Research Center, Hamadan University of Medical Sciences, Hamadan, Iran
[2] Ayatollah Bahari Hospital, Hamadan University of Medical Sciences, Hamadan, Iran
[3] Department of Anatomical Sciences, School of Medicine Endometrium and Endometriosis Research Center, Hamadan University of Medical Sciences, Hamadan, Iran
[4] Research Center for Health Sciences, School of Public Health, Hamadan University of Medical Sciences, Hamadan, Iran
[5] Center of Excellence for Occupational Health, Research Center for Health Sciences, School of Public Health, Hamadan University of Medical Sciences, Hamadan, Iran
[6] Nutrition Health Research Center, Center of Excellence for Occupational Health, Research Center for Health Sciences, School of Public Health, Hamadan University of Medical Sciences. Hamadan, Iran

ARTICLE INFO

Article history:
Received 24 June 2022
Received in revised form
21 January 2023
Accepted 6 February 2023
Available online 10 February 2023

Keywords:
Silicosis
Vitamin D
Oxidative stress
Inflammation
TNF-α

ABSTRACT

Background: Chronic exposure to silica is related with the provocation of an inflammatory response and oxidative stress mechanism. Vitamin D has multiple benefits in biological activities particularly respiratory system disease.
Method: In this research, 20 male Wistar rats were randomly allocated into four groups (5 rats /group) as follow: Group1 received saline as (negative control) group. The group 2 received a single IT instillation of silica (positive control) group; the group 3 was co-administrated with single IT silica and Vitamin D (20 mg/kg/day) daily for a period of 90 days. The rats of group 4 received Vitamin D daily for a period of 90 days.
Results: Silica significantly increased serum and lung total Oxidant Status (TOS). Meanwhile, silica reduced serum and lung total antioxidant capacity (TAC), GSH and tumor necrosis factor-α (TNF-a). Vitamin D treatment meaningfully reversed oxidative stress, antioxidants status and inflammatory response. Also, Vitamin D improved histopathological changes caused by silica.
Conclusion: These findings indicate that Vitamin D exerts protective effects against silica-induced lung injury. It seems that Vitamin D has potential use as a therapeutic object for silica induced lung injure.

1. Introduction

Silicosis is a dangerous chronic occupational disease caused by prolonged inhalation exposure to crystalline silica (silicon dioxide), a major component of sand or rock [1]. There are various forms of crystalline silica, including silicon dioxide and alpha quartz, as the most abundant form of silica [2]. Annually, millions of workers involved in industrialization processes (e.g., sandblasting, drilling, pulverizing, cutting, grinding tools, jackhammering, drilling, mining, construction, and stone cutting) are exposed to free crystalline silica [3]. In these industries, the inhalation of crystalline silica particles smaller than 10 μm can lead to silicosis or cancer [4]. The lung as a vital organ is seriously affected by crystalline silica particles. The pathological process of silicosis is characterized by lung tissue inflammation and fibrosis [5]. A silicosis patient suffers from breathing difficulty and symptoms such as chronic obstructive pulmonary disease (COPD) [3]. Silicosis happens in two forms: (i) accelerated silicosis due to exposure to low silica concentration over a long period and (ii) acute silicosis caused by short-term exposure to a very large amount of silica [6]. Identifying the molecular

Maryam Esfahani: https://orcid.org/0000-0001-5718-7126; Amir Hossein Rahbar: https://orcid.org/0000-0001-6015-5109; Saed Bashirian: https://orcid.org/0000-0003-2133-087X; Fereshteh Mehri: https://orcid.org/0000-0003-0106-245X
* Corresponding author.
E-mail addresses: esfahanimr21@yahoo.com (M. Esfahani), rahbari1229@yahoo.com (A.H. Rahbar), s.soleimaniasl@umsha.ac.ir (S.S. Asl), s_bashirian@yahoo.com (S. Bashirian), emirmoeini@hotmail.com (E.S. Mir Moeini), freshteh_mehri@yahoo.com (F. Mehri).

2093-7911/$ – see front matter
https://doi.org/10.1016/j.shaw.2023.02.001

mechanism of cell injury induced by silica is the main purpose of in vivo and in vitro studies [7,8]. After the first exposure to crystalline silica, alveolar macrophages begin to inflammatory responses. The consistency exposure stimulates oxidative stress in many macrophages by reactive oxygen species (ROS) and hydrogen peroxide production [9]. These oxidants can damage lung cells and increase the expression of tumor necrosis factor (TNF)-α and other inflammatory cytokines [10]. Previous studies have described that oxidative stress is involved in pulmonary fibrosis [11]. However, the actual molecular mechanisms are still unclear. There is no effective treatment to control lung fibrosis [12,13]. This issue is important, particularly in workers exposed to silica crystals. Resveratrol (Res) (5-[(*Z*)-2-(4hydroxyphenyl) ethenyl] benzene-1, 3-diol), as a small polyphenol compound, is abundant in different plant species, including berries, nuts, pistachios, and grapes [14]. This natural product has several protective effects, including anti-oxidative and anti-inflammatory properties, capillary protective action, anti-mutagenic effect, heart and neuroprotective effects, and anti-allergic activities [15,16]. Hemmati et al. (2008) indicated that grape seed extract could reduce the fibrogenic effect of silica in male albino Wistars [3]. In another study, Liu et al. (2017) reported that supplementation with grape seed extracts improves the quality of life of lung fibrosis patients [17]. The present study aimed to investigate the possible protective effects of Res against silica-induced lung injure in a rat model.

2. Material and method

2.1. Material

Crystalline silica (1–2 μm) was purchased from Nanozarat (Tehran, Iran). The surface characteristic was determined by Oxford scanning electron microscope (Fig. 1). Res were purchased from (FIRAT ECZANEST, Turkey, and Code: 166354). The other chemical substances used in this research were of high available grade of purity.

2.2. Animal treatment schedule

Male Wistar rats (150–180 g), aged 4 weeks, were purchased from the Animal Care Center, Hamadan University of Medical Sciences. All animal treatment protocol was approved by the guidelines established by the Review Board of Hamadan University of Medical Sciences with the code number of IR. UMSHA.REC.1399.444. The rats were kept in air-conditioned room at 21–23°C, humidity (50 ± 10%), and a regular 12 h light/12 h dark cycle. The animals were permitted free water and food during investigational procedure. The ethics in experiments were cautiously monitored.



Fig. 1. SEM images of crystalline silica particles used in the study. White bar represents 1–2 μm.

2.3. Silica-induced lung injure

The silica-induced lung toxicity was performed according to Hemmati et al. study [3]. The crystalline silica particles were weighted, suspended in normal saline (0.9% w/v) and autoclaved (in order to sterilize), and mixed with 20,000 IU penicillin. Silica suspension was used as intratracheally instillation (IT) (50 mg/rat, 0.1 mL/rat), and ketamine and xylazine were used for anesthetizing.

2.4. Experimental design

In order to study the effect of Res on silica-induced lung injure in rats, a total of 20 male Wistar albino rats were randomly classified into four groups (n = 5): control group received 1 ml of saline; Res group received orally 20 mg/kg of Res (based on previous studies [3,18]. Silica group received a single dose of 1 ml silica suspension IT; silica and Res group received co-administration of single IT silica and oral Res (20 mg/kg/day). Res (100 mg/60 tablet) purchased from (FIRAT ECZANEST), and Turkey were suspended in deionized water and administered orally by gavage to rats for 90 days (20 mg/kg/day). Finally, animals were deeply anesthetized by ketamine and xylazine injections. Blood samples were collected from left ventricle. Serum was separated, alliquted, and stored at -80C for subsequent analyses. In order to collect Bronchoalveolar lavage fluid (BALF), the lungs were lavaged three times with 6 ml of sterile saline, and the recovery ratio was 70%–80%. BALF was centrifuged (1500 g, 10 min at 4 C), and supernatant was stored at -80.

2.5. Total protein assay

The lung protein content measurement was conducted by the Bradford technique, and bovine serum albumin was used as standard.

3. Quantification of LDH activity contents of BALF

Lactate Dehydrogenase Activity (LDH) activity was evaluated using commercially available Pars Azmun kits (KSOD88, Iran). The procedures were conducted as supplied manufacturer's instructions; the change in absorbance was recorded at λ340 nm.

3.1. The evaluation of MDA, SOD, CAT, and TNF-α in serum and lung tissue

Lung and serum malondialdehyde (MDA) level (as end production of lipid peroxidation) were determined by thiobarbituric acid method (TBA) based on Esfahani et al. studies [18]. Serum and lung activities of superoxide dismutase (SOD) and catalase (CAT) were evaluated by Kiazist kits (KSOD96 and KCAT96, respectively). The serum and lung level of TNF-α were measured by Carmona Pars Gene (Iran, Cat. No: KPG-RTNF96).

3.2. Histopathology examination

The left lung tissues were excised, washed with iced-cold saline, and prepared for lung homogenization according to previous

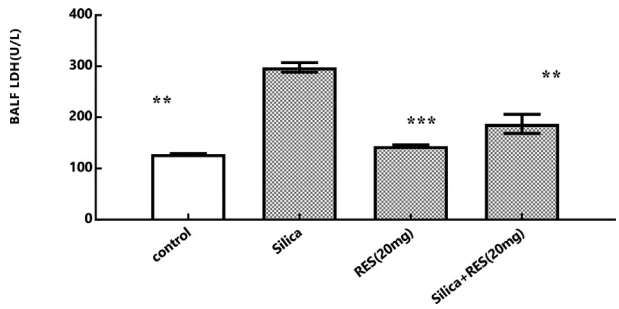

Fig. 2. The effect of daily oral Res (20 mg/kg) on BALFs LDH activity: silica-induced lung injure was induced intratechally instillation (50 mg/kg in 0.1 ml saline/rat). Res treatment began 24 h after silica instillation and continued for 90 days. Results are presented as the mean ± standard error of 5 rats in each group. **p<0.01 significantly different Vs Silis group; ***p<0.001 significantly different Vs Silis group (one-way ANOVA followed by Bonferroni post hoc test).

studies [19]. Also, the left lung was rinsed with iced cold saline, following then fixed in 4% paraformaldehyde for the assessment of morphological changes, in order to evaluate pulmonary fibrosis size, and deposition of extracellular matrix (ECM) deposition was used for Masson's trichrome staining. In order to evaluate the collagen deposition, the sections were inspected and photographed by use of a light microscope with digital camera (Nikon E800, Japan). Histopathological scoring of pulmonary fibrosis was reported according to Ashcroft score [20].

3.3. Statistical analysis

The SPSS-20 software ((SPSS, Inc., Chicago, IL, USA) was used to perform data analyses. The normal distribution of data was assessed by Kolmogrov–Smirnov test. Multiple group comparisons were accomplished by one-way analysis of variance (ANOVA) followed by Bonferroni post hoc test. The data are presented as mean ± SEM. In all cases, $P < 0.05$ was considered significant.

4. Results

4.1. Effect of Resveratrol (20 mg/kg) on LDH activity in the BALF

As shown in Fig. 2, the silica group revealed a significant elevation in LDH activity as compared to control group ($p < 0.001$). In contrast, treatment with Res induced a significant reduction in LDH activity in comparison with silica group ($p < 0.001$).

4.2. Effect of Resveratrol (20 mg/kg) on MDA level in serum and lung tissue

Based on Tables 1 and 2, intratracheal silica installation significantly increased the serum and lung MDA levels as compared with the control group ($p < 0.001$ and $p < 0.001$, respectively), While daily oral Res administration reversed these changes in serum and lung, as compared with silica group ($p < 0.001$ and $p < 0.001$, respectively). The serum level of MDA in the Silica + Res groups was higher in comparison with the MDA level of lung tissues.

4.3. Effect of Resveratrol (20 mg/kg) on antioxidant markers in serum and lung tissue

The activities of antioxidant enzymes, including SOD and CAT, were measured in the serum and lung tissue. As shown in Tables 1 and 2, intratracheal instillation of silica significantly decreased the activities of SOD, and CAT in serum and lung ($p < 0.01$ and $p < 0.01$, respectively) compared to the control group. However, orally Res administration could improve the alterations of SOD activities in serum and lung tissues compared to the silica group ($p < 0.001$and $p < 0.05$), although the activities of CAT increased in Silica + Res groups, the changes were not statically significant compared to the silica group.

4.4. Effect of Resveratrol (20 mg/kg) on serum and lung level of TNF-a

In the current study, silica instillation was associated with a significant increase in serum and lung level of TNF-α compared with control group ($p < 0.001$ and $p < 0.001$, respectively). Based on results, daily RES treatment meaningfully decreased serum and lung TNF-α levels compared with silica group ($p < 0.01$ and $p < 0.001$, respectively), and details are indicated in Tables 1 and 2.

4.5. Effect of Resveratrol (20 mg/kg) on silica-induced histopathological modifications in the lung

Histopathological assessments of the Masson's trichrome staining of the pulmonary tissue are shown in Figs. 3A–D and 4. Lungs of rats in control and Res group showed normal lung structure without any signs of lesion (Fig. 3A–B) ($P < 0.001$). In silica group, silica-induced lung toxicity caused marked increase in collagen deposition (Fig. 3C). However, treatment with Res significantly ameliorated these histopathological changes (Figs. 3D and 4) ($P < 0.01$).

5. Discussion

The current study evaluated the effects of Res on silica-induced lung injury. Successful silica-induced lung injure induction in the rat model was approved by detecting morphological and pathological changes in lung tissue. Also, we measured oxidative, antioxidative, and inflammatory markers in serum and lung. The molecular mechanism of silica-induced lung toxicity is still the topic of various studies. It is described chiefly by huge pulmonary fibrosis due to proliferation and progressive increase in connective tissue, which is substituted for normal functional parenchyma [1]. As a result, it has a detrimental effect on patients' quality of life. The

Table 1
The effects of daily oral RES treatment on serum TNF-α, oxidative, and anti-oxidative markers

Parameters	Control	Silica	Res	Silica + Res (20 mg)
MDA (μM/L)	1.81 ± 0.33***	5.99 ± 0.49	2.66 ± 0.55**	4.12 ± 0.43**
SOD (U/ml)	1.95 ± 0.92***	0.95 ± 0.12	1.89 ± 0.07**	1.49 ± 0.19***
CAT (U/ml)	174.8 ± 13.26***	107.2 ± 9.63	156.8 ± 6.53***	160.6 ± 9.86***
TNF-α (pg/mL)	10.92 ± 1.21***	19.63 ± 2.41	11.67 ± 2.02**	15.26 ± 1.5**

Silicosis was induced intratechally instillation of silica (50 mg/kg in 0.1 ml saline/rat). Res treatment began 24 h after silica instillation and continued for 90 days. Results are presented as the mean ± standard error of five rats in each group. **p<0.01 significantly different Vs Silis group; ***p<0.001 significantly different Vs Silis group (one-way ANOVA followed by Bonferroni post hoc test); MDA, malondialdehyde; CAT, catalase; SOD, superoxide dismutase; TNF-a, tumor necrosis factor.

Table 2
The effects of daily oral RES treatment on lung TNF-α, oxidative, and anti-oxidative markers

Parameters	Control	Silica	Res	Silica + Res (20 mg)
MDA (μM/g tissue)	1.27 ± 0.27***	3.14 ± 0.48	1.64 ± 0.36***	2.09 ± 0.15**
SOD (U/mg tissue)	1.58 ± 0.32*	0.79 ± 0.22	1.49 ± 0.28	1.39 ± 0.11
CAT (U/mg tissue)	422.22 ± 61**	283.2 ± 17.91	553.14 ± 52.44	318.84 ± 22.5
TNF-α (pg/mg tissue)	296.8 ± 43.05***	561.8 ± 33.48	274.8 ± 45.83***	397.76 ± 54.13**

Silicosis was induced intratechally instillation of silica (50 mg/kg in 0.1 ml saline/rat). Res treatment began 24 h after silica instillation and continued for 90 days. Results are presented as the mean ± standard error of five rats in each group. **p<0.01 significantly different Vs Silis group; ***p<0.001 significantly different Vs Silis group (one-way ANOVA followed by Bonferroni post hoc test); MDA, malondialdehyde; CAT, catalase; SOD, superoxide dismutase; TNF-a, tumor necrosis factor.

pulmonary fibrosis mechanisms induced by silica are distinct from other pulmonary fibrosis types. According to Heppleston and Styles' hypothesis, silica acid groups (in crystalline silica particles) can interact with the membrane of macrophages, impair the cell membrane, and ultimately discharge silica crystals and digesting enzymes [21]. Silica crystals are insoluble particles that can activate alveolar macrophages, epithelial, and fibroblast cells. These lead to the proliferation and migration of macrophages, the production of inflammatory markers and collagen fibers, and ultimately lung injury [3]. These events are considered the major causes of oxidative and inflammatory mediators releasing, including TNF-α, ROS, and RNS, which can recall neutrophils and lymphocytes [12]. Oxidative stress and inflammation are regarded as indicators of silicosis [19]. ROS generated at the surface of silica particles and phagocytic cells are involved in silica particles' digestion [5]. Accumulating evidence demonstrated that oxidative stress has a vital role in initiating and developing fibrotic lung disease [3]. The plasma levels of MDA can be an important biomarker of silicosis severity [22]. The high level of oxidant radicals can disturb the balance between free radical production and the biological antioxidant systems [10]. SOD is a pivotal enzyme involved in cell redox potential, and CAT involves in hydrogen peroxide decomposition [23]. These enzymes are regarded as the first line of antioxidant defense [24]. Our results confirmed that silica increased lipid peroxidation as evidenced by increased serum and lung levels of MDA, concomitant with suppression of CAT and SOD levels in serum and lung. In line with our results, Abdelaziz et al. reported that silica increased pulmonary oxidative markers such as MDA and decreased anti-oxidative markers such as Glutathione (GSH) content and SOD activity in lung tissue [19]. In another study, Orman et al. indicated an increase in plasma MDA levels and a decrease in erythrocyte GSH levels in construction workers exposed to cement dust [25]. In a rat model, Peng et al. showed that silica

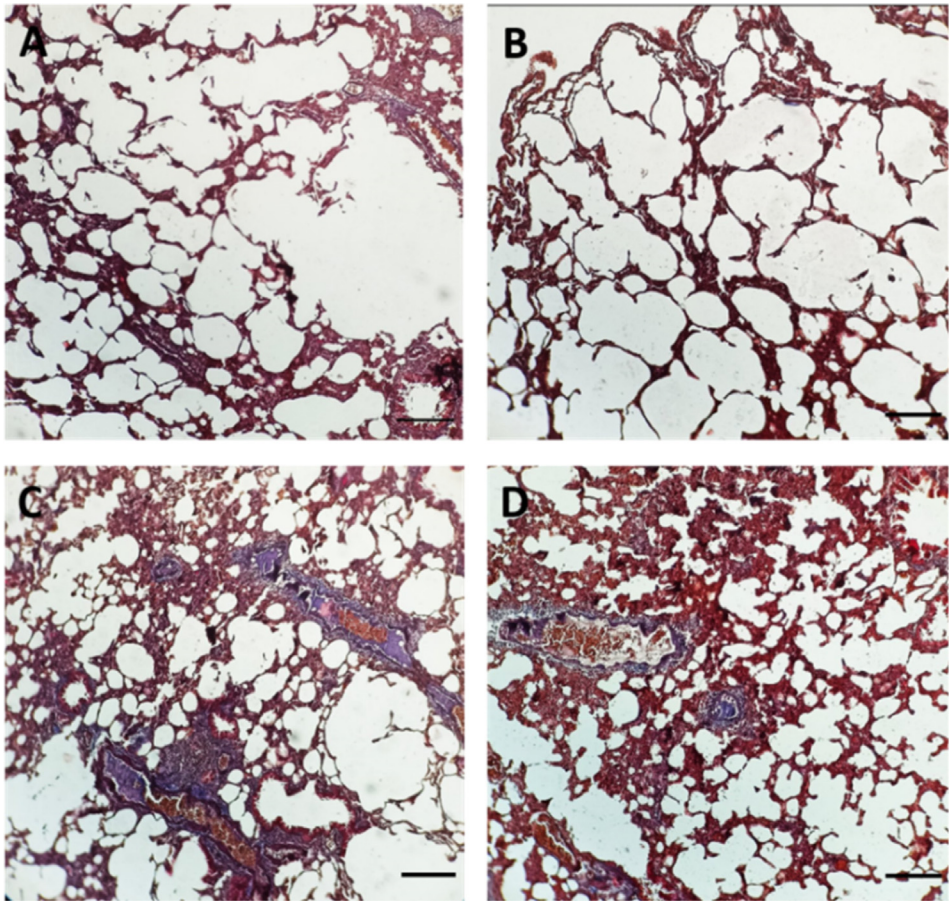

Fig. 3. Photomicrograph of Masson's trichrome staining of lung tissue, control groups (A), resveratrol treatment (Res 20 mg/kg) (B), silica (IT instillation) after 90 days (C), silica (IT instillation) along with 20 mg/kg of Res (D).

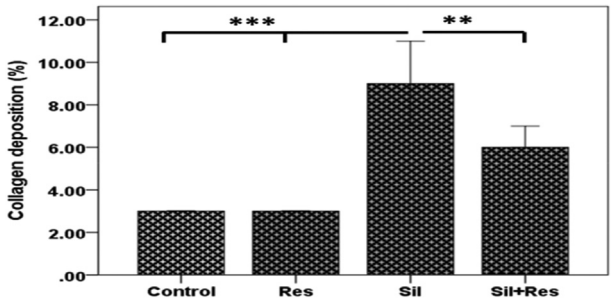

Fig. 4. Deposition of collagen is evident (magnification 200 ×), control groups (A), resveratrol treatment (Res 20 mg/kg) (B), silica (IT instillation) after 90 days (C), silica (IT instillation) along with 20 mg/kg of Res (D); ***p<0.001 (compared to control group); **p<0.01 (compared to silica group).

exposure-induced p-AKT/NF-ƙβ expression increased collagen content and inflammatory cytokines (i.e., TNF-α and TGF-β) in the lung, as well as increased serum MDA level [5]. Another study was conducted on cement plant workers, and their results indicated that plasma MDA levels in workers exposure silica dust were significantly high than control group [25]. In a similar study, Fahmy, F. C., et al. reported that occupational exposure to silica dust could increased induce oxidative stress in workers exposure silica dust [26]. Anlar et al. and Azari et al. indicated a significant increase in MDA plasma levels of workers in the field of ceramics and glass sandblasters exposed to crystalline silica, than workers unexposed, respectively [27,28]. Intracellular ROS has a fundamental role in the activation of NF-κB, which has a significant function in inflammatory responses. NF-κB is a major mediator of TNF-α, a pleiotropic cytokine [29]. Previous research has reported that in the silicosis model, TNF-α released from activated macrophages is involved in inflammation and lung fibrosis [30]. TNF-α can activate neutrophils, eosinophils, superoxide, and lysosomal enzymes. In addition, this inflammatory cytokine can promote the proliferation of fibroblasts and collagen synthesis [31]. The current study indicated high levels of serum and lung TNF-α, following silica intratracheal instillation compared with the control group. In line with our observation, Peng et al. confirmed that TNF-α generated at the initial phase of inflammation in silica group, as well as significantly increased and persisted 14 days after silica instillation [5]. Some plants or herbal combinations can act as strong antioxidants [32]. Our previous studies proved the protective effects of Res against diazinon-induced oxidative stress in the liver and kidney [33]. In this study, Res treatment improved antioxidant status (including SOD and CAT) and diminished oxidative stress markers, such as MDA. Meanwhile, Res mitigated inflammation via a decrease in serum and lung levels of TNF-α. Also, the results of this study indicated that Res administration decreased BALF LDH activity and moderated histopathological changes following silica exposure. Many preclinical studies documented lung-protective effects of Res due to its anti-inflammatory, antioxidant, and antifibrotic properties [34]. Research has proven the anti-inflammatory effects of Res in mice model of COPD caused by smoking [35]. In addition, in COPD patients, Res can suppress inflammation in macrophages of bronchoalveolar lavage fluid and bronchial smooth muscle cells [36,37]. In this regard, epidemiological and pathological results indicated that silica exposure has a close association with COPD, independent of silicosis. Alveolar epithelial type II is important for sustaining lung hemostasis [38]. In vitro studies have shown that Res can suppress inflammation in type II alveolar epithelial cell line via decreasing expression of IL-1B and IL-6 and increase in IL-10 and surfactant proteins expressions. These effects were mediated by the inhibition of NF-κB pathway [39], an increase in SIRT1, and a decrease in FoxO3a. SIRT1 enhances PGC-1 α expression, which can attenuate ROS production via detoxifying enzymes induction. Also, PGC-1α activates mitochondrial biogenesis and has a significant role in the regulation of antioxidant enzymes, such as SOD, CAT, and Plasma glutathione peroxidase (GSH-Px) [40]. Indeed, Res enhances mitochondrial oxidative capacity through AMPK-SIRT1-PGC-1α axis. Preclinical researches have shown that inhaled formulation of Res increased the mitochondrial function of the lung and preserved lung structure [41]. Consistent with our study, Hamza et al. demonstrated that Res with free radical scavenging activity and antioxidant properties improved lung histopathological changes and nicotine-induced oxidative stress status [42]. The study of Kashef DH et al., in silica model, proved a decrease in the level of nuclear elytroid 2-related factor 2 (Nrf-2) and HO-1 in BALF. Nrf-2 is a significant molecule in the activation of antioxidant enzymes transcription [43]. Moreover, this transcription factor is involved in inflammation protein degradation; thus, Nrf-2 is critical in the regulation of oxidative stress [44]. In vitro studies have shown that Res can protect human alveolar epithelial cells against oxidative stress induced by cigarette smoke extract (CSE), and Res increases GSH level through Nrf2 activation [45]. Res improved antioxidant capacity and attenuated apoptotic processes through Nrf2/HO signaling activation in human bronchial epithelial cells exposed to CSE [46]. In addition, Res increased SIRT1 expression and augmented antioxidant enzymes, including SOD and CAT, in lung injury induced by organophosphate pesticide [47]. These effects showed that Res can decrease lung injury and may potentially decrease anti-inflammatory drugs requirement with disadvantages and complications [47]. Several clinical trials indicated anti-inflammatory effect of Res including reduce in IL 6 and TNF-α [48,49]. Also, human studies indicated that Res treatment diminished oxidative stress markers (such as protein carbonyl content and O2-level of PBMCs) and increased plasma antioxidant capacity [50]. Res had a beneficial effect in prolonged job-related exposure to electromagnetic fields [51]. These evidence suggested that Res supplementation may be candidate agents in inflammatory lung diseases, particularly silica-induced lung injury.

6. Conclusion

Our results demonstrated that silica caused oxidative stress and inflammation in serum and lung tissue of rat model. We indicated the evidence that Res has protection effects on these harmful effects of silica by an increase in antioxidants and a decrease in oxidative stress and inflammatory biomarkers in rats. Moreover, Res ameliorated histopathological changes induced by silica. There were some limitations in this study that should be considered in future studies. Since lung injuries induced by silica are a chronic respiratory disease, it is necessary to administrate silica in the inhalation route. It is required to investigate molecular mechanisms involved in the anti-inflammatory and antioxidant effects of Res against silica-induced lung impairment. Furthermore, we recommended next studies on other animals closely associated with humans and eventually in a clinical setting. Undoubtedly, such studies can help to provide a novel vista in the nature-based therapeutic strategy for silicosis.

Ethical approval

This study was approved by the Research Ethics Committee of Hamadan University (No. IR. UMSHA.REC.1399.444).

Funding

This study was financially supported by Hamadan University of Medical Sciences, Hamadan, Iran (project number: 9906183906).

Conflicts of interest

The authors declare that they have no known competing financial interests or personal relationships that could have appeared to influence the work reported in this paper.

Acknowledgements

The authors would appreciate the Deputy of Research and Technology, Hamadan University of Medical Sciences, for financial support of the study.

References

[1] Hamilton Jr RF, Thakur SA, Holian A. Silica binding and toxicity in alveolar macrophages. Free Radic Biol Med 2008;44(7):1246–58.
[2] Ding M, Chen F, Shi X, Yucesoy B, Mossman B, Vallyathan V. Diseases caused by silica: mechanisms of injury and disease development. Int Immunopharmacol 2002;2(2–3):173–82.
[3] Hemmati AA, Nazari Z, Samei M. A comparative study of grape seed extract and vitamin E effects on silica-induced pulmonary fibrosis in rats. Pulm Pharmacol Ther 2008;21(4):668–74.
[4] Pollard KM. Silica, silicosis, and autoimmunity. Front Immunol 2016;7:97.
[5] Peng HB, Wang RX, Deng HJ, Wang YH, Tang JD, Cao FY, Wang JH. Protective effects of oleanolic acid on oxidative stress and the expression of cytokines and collagen by the AKT/NF-κB pathway in silicotic rats. Mol Med Rep 2017;15(5):3121–8.
[6] Murray JF, Nadel J. Textbook of respiratory medicine; 1987.
[7] Caillet S, Salmiéri S, Lacroix M. Evaluation of free radical-scavenging properties of commercial grape phenol extracts by a fast colorimetric method. Food Chem 2006;95(1):1–8.
[8] Shi X, Mao Y, Saffiotti U, Wang L, Rojanasakul Y, Leonard SS, Vallyathan V. Antioxidant activity of tetrandrine and its inhibition of quartz-induced lipid peroxidation. J Toxicol Environ Health - A: Curr Issue. 1995;46(2):233–48.
[9] Zhang L, He YL, Li QZ, Hao XH, Zhang ZF, Yuan JX, Bai YP, Jin YL, Chen G, Yun X. N-acetylcysteine alleviated silica-induced lung fibrosis in rats by down-regulation of ROS and mitochondrial apoptosis signaling. Toxicol Mech Methods 2014;24(3):212–9.
[10] Porter DW, Millecchia LL, Willard P, Robinson VA, Ramsey D, McLaurin J, Khan A, Brumbaugh K, Beighley CM, Teass A, Castranova V. Nitric oxide and reactive oxygen species production causes progressive damage in rats after cessation of silica inhalation. Toxicol Sci 2006;90(1):188–97.
[11] El-Kashef DH. Nicorandil ameliorates pulmonary inflammation and fibrosis in a rat model of silicosis. Int Immunopharmacol 2018;64:289–97.
[12] Rimal B, Greenberg AK, Rom WN. Basic pathogenetic mechanisms in silicosis: current understanding. Curr Opin Pulm Med 2005;11(2):169–73.
[13] Flynn MR, Susi P. Engineering controls for selected silica and dust exposures in the construction industry–a review. J Occup Environ Hyg 2003;18(4):268–77.
[14] Abbasi Oshaghi E, Goodarzi MT, Higgins V, Adeli K. Role of resveratrol in the management of insulin resistance and related conditions: mechanism of action. Crit Rev Clin Lab Sci 2017;54(4):267–93.
[15] Lu DL, Ding DJ, Yan WJ, Li RR, Dai F, Wang Q, Yu SS, Li Y, Jin XL, Zhou B. Influence of glucuronidation and reduction modifications of resveratrol on its biological activities. Chembiochem 2013;14(9):1094–104.
[16] Pallares V, Calay D, Cedo L, Castell-Auvi A, Raes M, Pinent M, Ardevol A, Arola L, Blay M. Enhanced anti-inflammatory effect of resveratrol and EPA in treated endotoxin-activated RAW 264.7 macrophages. Br J Nutr 2012;108(9):1562–73.
[17] Zhang J, Lv G, Yao J, Hong X. Assessment of serum antioxidant status in patients with silicosis. Int J Med Res 2010;38(3):884–9.
[18] Liu Q, Jiang J-x, Liu Y-n, Ge L-t, Guan Y, Zhao W, Jia YL, Dong XW, Sun Y, Xie QM. Grape seed extract ameliorates bleomycin-induced mouse pulmonary fibrosis. Toxicol Lett 2017;273:1–9.
[19] Esfahani M, Rahbar AH, Soleimani Asl S, Mehri F. Resveratrol: a panacea compound for diazinon-induced renal toxicity. Toxin Rev 2021:1–11.
[20] Abdelaziz RR, Elkashef WF, Said E. Tadalafil reduces airway hyperactivity and protects against lung and respiratory airways dysfunction in a rat model of silicosis. Int Immunopharmacol 2016;40:530–41.
[21] Ashcroft T, Simpson JM, Timbrell V. Simple method of estimating severity of pulmonary fibrosis on a numerical scale. J Clin Pathol 1988;41(4):467–70.
[22] Heppleston A. The fibrogenic achon of silica. Br Med Bull 1969;25(3):282–7.
[23] Leonard SS, Xia C, Jiang B-H, Stinefelt B, Klandorf H, Harris GK, Shi X. Resveratrol scavenges reactive oxygen species and effects radical-induced cellular responses. Biochem Biophys Res Commun 2003;309(4):1017–26.
[24] Maurya R, Namdeo M. Superoxide dismutase: a key enzyme for the survival of intracellular pathogens in host. Reactive Oxygen Species 2021.
[25] Ighodaro O, Akinloye O. First line defence antioxidants-superoxide dismutase (SOD), catalase (CAT) and glutathione peroxidase (GPX): their fundamental role in the entire antioxidant defence grid. Alexandria J Med 2018;54(4):287–93.
[26] Orman A, Kahraman A, Çakar H, Ellidokuz H, Serteser M. Plasma malondialdehyde and erythrocyte glutathione levels in workers with cement dust-exposure silicosis. Toxicology 2005;207(1):15–20.
[27] Fahmy F, Abdel-Hamid M, Abbas F, El-Gazzar R. Renal affection and some oxidative stress biomarkers among workers exposed to silica dust. Egypt. J Occup Med 2011;35(1):1–19.
[28] Anlar HG, Bacanli M, İritaş S, Bal C, Kurt T, Tutkun E, Hinc Yilmaz O, Basaran N. Effects of occupational silica exposure on oxidative stress and immune system parameters in ceramic workers in Turkey. J Toxicol Environ Health A 2017;80(13–15):688–96.
[29] Azari MR, Ramazani B, Mosavian MA, Movahadi M, Salehpour S. Serum malondialdehyde and urinary neopterin levels in glass sandblasters exposed to crystalline silica aerosols. Int J Occup Hyg 2011;3(1):29–32.
[30] Hop HT, Reyes AW, Huy TX, Arayan LT, Min W, Lee HJ, Rhee MH, Chang HH, Kim S. Activation of NF-kB-mediated TNF-induced antimicrobial immunity is required for the efficient Brucella abortus clearance in RAW 264.7 cells. Front Cell Infect Microbiol 2017;7:437.
[31] Li Z, Xue J, Yan S, Chen P, Chen L. Association between tumor necrosis factor-α 308G/A gene polymorphism and silicosis susceptibility: a meta-analysis. PLoS One 2013;8(10):e76614.
[32] Ortiz LA, Lasky J, Gozal E, Ruiz V, Lungarella G, Cavarra E, Brody AR, Pardo A, Selman M. Tumor necrosis factor receptor deficiency alters matrix metalloproteinase 13/tissue inhibitor of metalloproteinase 1 expression in murine silicosis. Am J Respir Crit Care Med 2001;163(1):244–52.
[33] Alok S, Jain SK, Verma A, Kumar M, Mahor A, Sabharwal M. Herbal antioxidant in clinical practice: a review. Asian Pac J Trop Biomed 2014;4(1):78–84.
[34] Mehri F, Ranjbar A, Shirafkan N, Asl SS, Esfahani M. The protective effect of resveratrol on diazinon-induced oxidative stress and glucose hemostasis disorder in rats' liver. J Biochem Mol Toxicol 2022:e23063.
[35] Beijers RJ, Gosker HR, Schols AM. Resveratrol for patients with chronic obstructive pulmonary disease: hype or hope? Curr Opin Clin Nutr Metab Care 2018;21(2):138.
[36] Chen J, Yang X, Zhang W, Peng D, Xia Y, Lu Y, Han X, Song G, Zhu J, Liu R. Therapeutic effects of resveratrol in a mouse model of LPS and cigarette smoke-induced COPD. Inflammation 2016;39(6):1949–59.
[37] Culpitt S, Rogers DF, Fenwick PS, Shah P, De Matos C, Russell RE, Barnes PJ, Donnelly LE. Inhibition by red wine extract, resveratrol, of cytokine release by alveolar macrophages in COPD. Thorax 2003;58:942–6.
[38] Knobloch J, Sibbing B, Jungck D, Lin Y, Urban K, Stoelben E, Strauch J, Koch A. Resveratrol impairs the release of steroid-resistant inflammatory cytokines from human airway smooth muscle cells in chronic obstructive pulmonary disease. J Pharmacol Exp Ther 2010;335(3):788–98.
[39] Hnizdo E, Vallyathan V. Chronic obstructive pulmonary disease due to occupational exposure to silica dust: a review of epidemiological and pathological evidence. Occup Environ Med 2003;60(4):237–43.
[40] Liu J, Mrc Y, Hsieh YZ, Wiesler D, Novotny M. 19911 Design of 3-(4-Carboxybenzoyll-2-quinolinecarboxaldehyde as a reagent for ultrasensitive determination of primary amines hy capillary electrophoresis using laser fluorescence detection. Chem 2001;63:408–12.
[41] Chen S-D, Yang D-I, Lin T-K, Shaw F-Z, Liou C-W, Chuang Y-C. Roles of oxidative stress, apoptosis, PGC-1α and mitochondrial biogenesis in cerebral ischemiaInt. J Mol Sci 2011;12(10):7199–215.
[42] Navarro S, Reddy R, Lee J, Warburton D, Driscoll B. Inhaled resveratrol treatments slow ageing-related degenerative changes in mouse lung. Thorax 2017;72(5):451–9.
[43] Hamza RZ, El-Shenawy NS. Anti-inflammatory and antioxidant role of resveratrol on nicotine-induced lung changes in male rats. Toxicol Rep 2017;4:399–407.
[44] Dong J, Sulik KK, Chen S-y. Nrf2-mediated transcriptional induction of antioxidant response in mouse embryos exposed to ethanol in vivo: implications for the prevention of fetal alcohol spectrum disorders. Antioxid Redox Signaling 2008;10(12):2023–33.
[45] Wang X. The expanding role of mitochondria in apoptosis. Genes Dev 2001;15(22):2922–33.
[46] Kode A, Rajendrasozhan S, caito S, Yang SR, Megson IL, Rahman I. Resveratrol induces glutathione synthesis by activation of Nrf2 and protects against cigarette smoke-mediated oxidative stress in human lung epithelial cells. Am J Physiol Lung Cell Mol Physiol 2008;294:L478–88.
[47] Zhang H, Shih A, Rinna A, Forman HJ. Exacerbation of tobacco smoke mediated apoptosis by resveratrol: an unexpected consequence of its antioxidant action. Int J Biochem Cell Biol 2011;43(7):1059–64.
[48] Li S, Zhao G, Chen L, Ding Y, Lian J, Hong G, Lu Z. Resveratrol protects mice from paraquat-induced lung injury: the important role of SIRT1 and NRF2 antioxidant pathways. Mol Med Rep 2016;13(2):1833–8.
[49] Miraghajani MS, Esmaillzadeh A, Najafabadi MM, Mirlohi M, Azadbakht L. Soy milk consumption, inflammation, coagulation, and oxidative stress among type 2 diabetic patients with nephropathy. Diabetes Care 2012;35(10):1981–5.
[50] Seyyedebrahimi S, Khodabandehloo H, Nasli Esfahani E, Meshkani R. The effects of resveratrol on markers of oxidative stress in patients with type 2 diabetes: a randomized, double-blind, placebo-controlled clinical trial. Acta Diabetol 2018;55(4):341–53.
[51] Zhang D, Zhang Y, Zhu B, Zhang H, Sun Y, Sun C. Resveratrol may reverse the effects of long-term occupational exposure to electromagnetic fields on workers of a power plant. Oncotarget 2017;8(29):47497.