

# Three-dimensional printing of temporary crowns with polylactic acid polymer using the fused deposition modeling technique: a case series

Eun-Kyong Kim<sup>1</sup>, Eun Young Park<sup>2</sup>, Sohee Kang<sup>2</sup>

<sup>1</sup>Department of Dental Hygiene, College of Science and Technology, Kyungpook National University, Sangju, Korea

<sup>2</sup>Department of Dentistry, Yeungnam University College of Medicine, Daegu, Korea

With recent developments in digital dentistry, research on techniques and materials for three-dimensional (3D) printing is actively underway. We report the clinical applications and outcomes of 3D printing of temporary crowns fabricated with polylactic acid (PLA) using a fused deposition modeling (FDM) printer. Five participants were recruited from among patients scheduled to be treated with a single full-coverage crown at a dental clinic in a university medical center from June to August 2022. We used 3D-printed crowns fabricated with PLA using an FDM printer as temporary crowns and were assessed for discomfort, fracture, and dislodging. The 3D-printed temporary crowns were maintained without fracture, dislodging, or discomfort until the permanent prosthesis was ready. The average time required for printing the temporary crowns was approximately 7 minutes. The 3D printing of temporary crowns with PLA using an FDM printer is a convenient process for dentists. However, these crowns have some limitations, such as rough surface texture and translucency; therefore, the 3D printing process should be improved to produce better prostheses.

**Keywords:** Digital dentistry; Polylactic acid; Temporary dental restoration; Three-dimensional printing

## Introduction

Temporary crowns are a critical part of fixed prosthodontic treatment because they protect the prepared teeth, provide positional stability, and maintain functions, such as mastication and esthetics [1]. Temporary crowns can be fabricated directly on the prepared tooth or indirectly on a model of the prepared tooth [2]. The direct method is convenient but entails significant disadvantages such as irritation to the adjacent tissue and polymer shrinkage [3]. In addition, the chemical odor generated during polymerization causes severe discomfort to patients. The conventional indirect fabrication method can overcome these shortcomings [2], but ad-

ditional processes, such as impression making and plaster modeling, may be required. If the temporary crown is prepared arbitrarily before tooth preparation, its accuracy is reduced, causing similar problems in the relining process as in the direct method. If the temporary crown is prepared by an indirect method after tooth preparation, the chair time will increase because of the impression and model-making processes.

However, with the recent development of digital dentistry, an indirect temporary prosthesis fabrication method using three-dimensional (3D) printing has been introduced and is being actively developed to overcome the limitations of the conventional indirect method. For fabricating 3D objects from 3D digital data, 3D print-

Received: September 2, 2022 • Revised: September 14, 2022 • Accepted: September 22, 2022

Corresponding author: Sohee Kang, DDS, PhD

Department of Dentistry, Yeungnam University College of Medicine, 170 Hyeonchung-ro, Nam-gu, Daegu 42415, Korea

Tel: +82-53-620-3282 • Fax: +82-53-629-1772 • E-mail: kangsh@yu.ac.kr

Copyright © 2023 Yeungnam University College of Medicine, Yeungnam University Institute of Medical Science

This is an Open Access article distributed under the terms of the Creative Commons Attribution Non-Commercial License (<http://creativecommons.org/licenses/by-nc/4.0/>) which permits unrestricted non-commercial use, distribution, and reproduction in any medium, provided the original work is properly cited.

ing is an additive manufacturing technique. A 3D-printed temporary crown is manufactured through a digital flow process that includes 3D scanning of the prepared tooth, digitalization on a computer, transfer to the 3D printer, and fabrication of the 3D structure [4].

The 3D-printing technologies commonly used for preparing dental polymers include stereolithography apparatus (SLA), digital light processing (DLP), material jetting (MJT), and fused deposition modeling (FDM) [5]. SLA and DLP are currently the most popular technologies in dentistry. Both processes produce 3D structures by the photopolymerization of a liquid photopolymer and can quickly produce high-resolution restorations [6]. MJT is a direct 3D-printing process in which molten droplets of material are ejected onto a heated build platform and bonded; MJT is also accurate and fast, but it is expensive. In the FDM technique, 3D structures are fabricated such that the solid filament material is melted in a nozzle, polymerized while being extruded, and stacked layer by layer. The equipment and materials required for FDM are less expensive and more convenient to use than those required for SLA or DLP. However, although 3D objects printed by FDM have appropriate physical properties, they are not popular in dentistry because they require a long printing time and have low resolution [4].

Interest in the 3D printing of temporary crowns has been increasing, but limited studies have assessed the use of 3D-printing technologies and materials used for manufacturing temporary prostheses. A few studies on 3D printing of temporary crowns have focused on SLA and DLP [7,8]. However, FDM has advantages such as being economical, highly convenient, and producing

material with appropriate physical properties. If the shortcomings of the rough surface of the end product and slow working speed are improved, FDM could be successfully used in dental clinics.

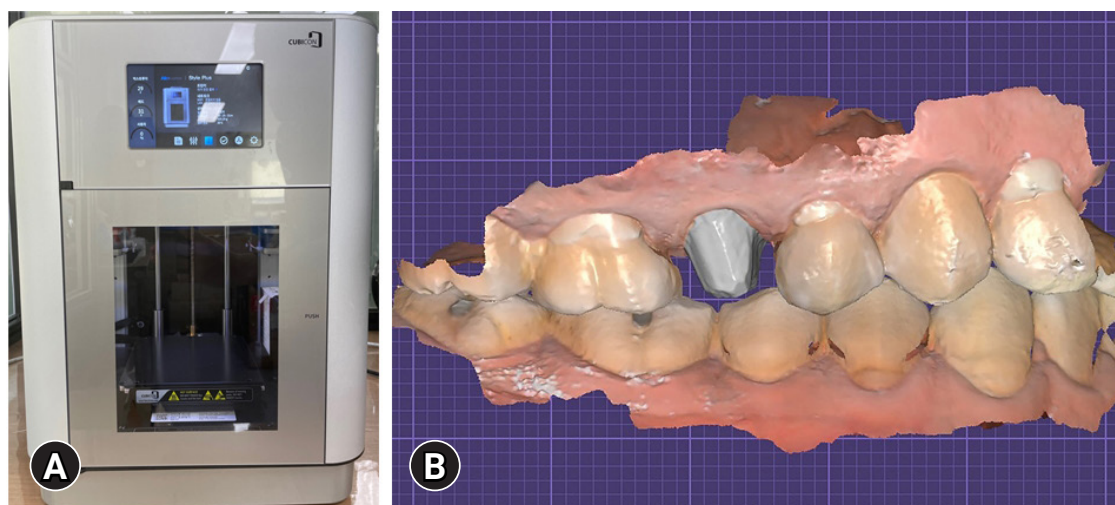
Herein, we report our experience with the printability and clinical application of a relatively convenient filamentous polymer (polylactic acid [PLA]; QUVE Co. Ltd., Seoul, Korea), which has been developed and marketed as a temporary restoration material for use in FDM 3D printers (CUBICON Style Plus - A15D; CUBICON Co. Ltd., Seoul, Korea).

## Cases

**Ethical statements:** This study was approved by the Institutional Review Board (IRB) of Yeungnam University Hospital (IRB No: YUMC-2021-07-019). Written informed consent was obtained from the patients for the publication of this case series and accompanying images.

Potential participants were recruited from among patients who visited a dental clinic in Yeungnam University Medical Center from June to August 2022. Five patients were enrolled, and five teeth were scheduled for treatment with a single full-coverage restoration. The teeth were prepared by an experienced dentist, and 3D-printed temporary crowns were luted onto the prepared teeth with Temp-Bond NE (Kerr Dental, Brea, CA, USA) and maintained until the final prosthesis was ready.

After tooth preparation, intraoral scanning of the prepared tooth was performed using a 3D scanner (Medit i500; MEDIT Corp.,



**Fig. 1.** Intraoral scanning after tooth preparation. (A) Three-dimensional scanner (Medit i500; MEDIT Corp., Seoul, Korea). (B) Intraoral scanning image.

Seoul, Korea) (Fig. 1). The digital data were then transferred to a NexWay platform (QUVE Co. Ltd.) as an STL file, and the temporary crown was designed by an experienced dental technician using computer-aided design/computer-aided manufacturing (CAD/CAM) software (Exocad GmbH, Darmstadt, Germany) (Fig. 2). Finally, the design was transferred to an FDM 3D printer (CUBICON Style Plus - A15D) installed in the dental clinic and printed into a 3D structure using PLA polymer (Fig. 3).

**1. Case 1**

A 59-year-old man complained of pain emanating from tooth #15 during mastication. The patient was diagnosed with cracked tooth #15 based on clinical and radiographic data; therefore, he underwent root canal treatment and core build-up. A porcelain-fused-to-metal (PFM) crown was planned to cover the treated tooth, which was prepared according to the preparation requirements of PFM crowns. A temporary crown was fabricated with PLA using the FDM method.

**2. Case 2**

A 45-year-old woman visited our clinic because her old crown on tooth #36 was dislodged. Secondary caries were present in tooth #36, and an infection was found in the previously treated root canal system. Restoration with a gold crown after repeated root canal treatments was planned. A temporary crown was fabricated with PLA using the FDM method.


**3. Case 3**

A 34-year-old man presented with the chief complaint of spontaneous pain emanating from tooth #37. Clinical and radiographic examinations revealed irreversible pulpitis of tooth #37. Restoration with a gold crown was planned after root canal treatment.

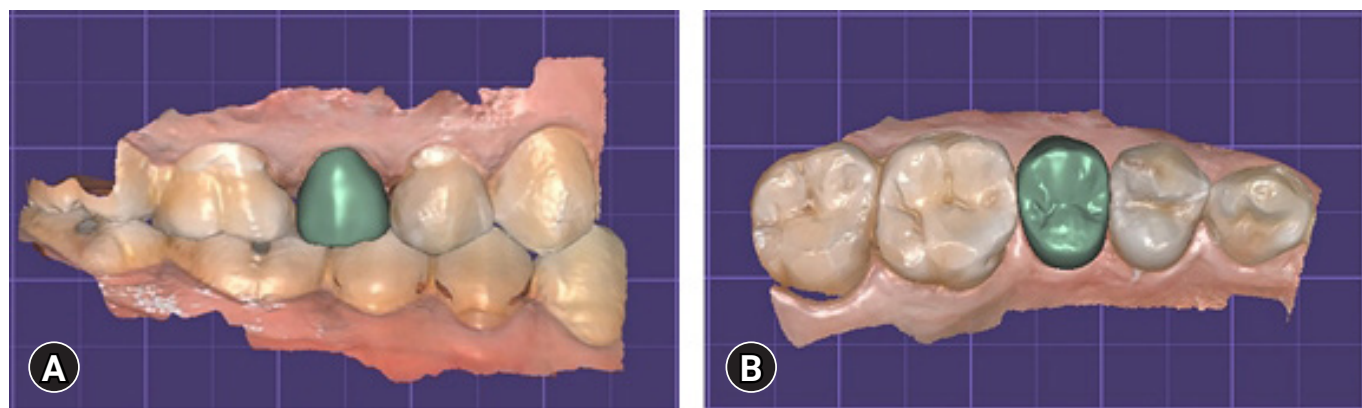
A temporary crown was fabricated with PLA using the FDM method.

**4. Case 4**

A 54-year-old woman visited our clinic for prosthetic treatment of tooth #46 after root canal treatment. Restoration with a gold crown was planned, and a temporary crown for the tooth was fabricated with PLA using the FDM method.



**Fig. 3.** Fabrication of a three-dimensional (3D)-printed temporary crown using the fused deposition modeling (FDM) method and polylactic acid (PLA) polymer. (A) FDM 3D printer (CUBICON Style Plus - A15D; CUBICON Co. Ltd., Seoul, Korea). (B) Nexway PLA (QUVE Co. Ltd., Seoul, Korea). (C, D) Fabrication of a single temporary crown using PLA. (E) Single temporary crown made with PLA.



**Fig. 2.** Crown design using computer-aided design/computer-aided manufacturing (CAD/CAM) software (Exocad GmbH, Darmstadt, Germany). (A) Lateral view. (B) Occlusal view.

## 5. Case 5

An 80-year-old man complained of pain emanating from tooth #14 when biting, and chewing difficulty over the entire dentition. The maxillary right first premolar was diagnosed with irreversible pulpitis. He experienced prolonged abnormal occlusion due to missing teeth #15, 16, 17, 45, 46, and 47; therefore, the remaining anterior teeth showed severe pathological attrition, and there was no space for the prosthesis in the mandible. Root canal treatment was planned for tooth #14, which was subsequently covered with a surveyed crown so that it could be used as an abutment for removable partial dentures. Owing to the short clinical crown length and low esthetic expectations, a gold crown was planned, and a temporary crown was fabricated with PLA using the FDM method.

The printing process for each crown took approximately 7 minutes. The workplace was not polluted by noise or dust and was kept clean. No failure occurred due to fracture or dislodging of the temporary crown, and no complaints of discomfort, poor esthetics, or surface roughness were reported during the temporary restoration period, which took an average of 7 days (Table 1). Occlusal adjustment was achieved using a denture bur, as would be performed with a temporary, conventional direct resin crown. However, these single provisional crown cases required almost no occlusal adjustment, as few high spots or guide interferences were observed.

## Discussion

With the recent development of digital equipment and materials in the dental field, the popularity of digital dental technologies has increased [9-11]. The digital process of printing crowns is a novel method that is highly accurate and has low technique sensitivity, allowing dental prostheses to be manufactured by 3D printing, including model-making, without complex lab work [12-14].

Although 3D printing is fast and precise and most printed objects have smooth surface, it is mostly used to produce temporary prostheses. The brittleness, easy deformability, poor weather resistance, and low biocompatibility of 3D-printed objects fabricated using the photo-curing technique limit their performance [15].

Various types of 3D printers and materials are used in the 3D printing of temporary prostheses; however, evidence of their clinical application is still lacking. Therefore, advanced research on materials for the 3D printing of temporary restorations is needed [4]. Convenience, cost, and accuracy are more important factors for temporary crowns than for permanent prostheses.

The equipment and materials involved in SLA are expensive and inconvenient for clinical handling because of the sticky and messy photopolymer used. SLA also produces large amounts of waste material [4,5]. However, the equipment and materials involved in FDM are relatively economical, easy to handle, and possess excellent strength [16].

PLA is one of the most commonly used materials in FDM printers. PLA is biocompatible and nontoxic because it is synthesized from renewable resources, such as sugarcane or cornstarch [17]. In a few *in vitro* studies, 3D-printed temporary crowns fabricated with PLA using an FDM printer were appropriate in terms of fit and mechanical strength. Molinero-Mourelle et al. [18] reported that the mean marginal fit of PLA provisional crowns was  $122.89 \pm 26.04 \mu\text{m}$ , which was clinically acceptable. Crenn et al. [19] reported that PLA temporary crowns had superior flexural strength ( $115.8 \pm 2.11 \text{ MPa}$ ), hardness (Vickers hardness number of  $17.5 \pm 0.7$ ), and elastic modulus ( $3,784 \pm 98.9 \text{ MPa}$ ) compared with those of temporary crowns fabricated with poly(methyl methacrylate), which is an autopolymerizing temporary resin used in the conventional direct method. However, there is a lack of evidence regarding the clinical application of PLA provisional crowns.

Hence, we examined the efficiency of PLA as a temporary crown material fabricated using an FDM dental 3D printer. We used the PLA polymer that was made by blending less than one part polybutylene adipate-co-terephthalate with more than nine parts PLA. All 3D temporary crowns manufactured using this PLA were simply and accurately applied after intraoral scanning.

Both the printer and PLA were easy to handle in the clinic, the workload of the dental staff was reduced owing to digitalization, and contamination of the clinic by volatile liquids was reduced.

**Table 1.** Characteristics of the patients and three-dimensional printing of temporary crowns

Case No.	Sex/age (yr)	Tooth No.	Working time (min:sec)	Failure of the temporary restoration
1	Male/59	#15	7:02	No event
2	Female/45	#36	7:12	No event
3	Male/34	#37	7:10	No event
4	Female/54	#46	7:08	No event
5	Male/80	#14	6:58	No event

The working time was length of the time required to manufacture the temporary crown.

There were no complaints of patient discomfort and no failures, including fractures and dislodgements, occurred until the final prosthesis was ready. However, PLA products tend to undergo thermal degradation, making high-speed polishing difficult. Therefore, it is important to find ways to reduce the surface roughness of PLA crowns.

The average working time for the 3D printing of temporary crowns is  $21 \pm 5$  minutes, which is shorter than the time taken for the direct method, and similar to the time required for impression taking, enabling the efficient use of chair time.

In the 3D-printing process, after tooth preparation, points that require correction can be checked and corrected immediately on the screen by direct communication between the dental technician and the dentist. Digital data can also be used to fabricate permanent prostheses.

However, our reported cases were limited to single restorations in the posterior region, which is associated with the fact that the accuracy of oral scanning is limited to single-tooth or short-span prostheses. Along with improvements in digital scanning, further research on long-span 3D-printed prostheses should be conducted. Because of the limited surface texture of PLA temporary crowns, their application was limited to the posterior teeth; this limitation should be addressed in future studies to enable the use of 3D-printed crowns for anterior teeth. In addition, assessment of the patients in this study was subjective. Further studies are needed to evaluate PLA 3D-printed crowns using objective data.

## Notes

### Conflicts of interest

No potential conflict of interest relevant to this article was reported.

### Funding

This study was supported by the National IT Industry Promotion Agency (A1602-22-1003).

### Author contributions

Conceptualization, Funding acquisition, Validation: EK, EYP, SK; Formal analysis, Supervision: EK, SK; Methodology: EYP; Project administration, Investigation, Resources: SK; Visualization: EK; Writing-original draft: EK; Writing-review & editing: EK, EYP.

### ORCID

Eun-Kyong Kim, <https://orcid.org/0000-0001-9582-1415>

Eun Young Park, <https://orcid.org/0000-0002-1860-5425>

Sohee Kang, <https://orcid.org/0000-0002-3667-1952>

## References

1. Burns DR, Beck DA, Nelson SK; Committee on Research in Fixed Prosthodontics of the Academy of Fixed Prosthodontics. A review of selected dental literature on contemporary provisional fixed prosthodontic treatment: report of the Committee on Research in Fixed Prosthodontics of the Academy of Fixed Prosthodontics. *J Prosthet Dent* 2003;90:474–97.
2. Regish KM, Sharma D, Prithviraj DR. Techniques of fabrication of provisional restoration: an overview. *Int J Dent* 2011;2011:134659.
3. Syed M, Chopra R, Sachdev V. Allergic reactions to dental materials: a systematic review. *J Clin Diagn Res* 2015;9:ZE04–9.
4. Schweiger J, Edelhoff D, Güth JF. 3D printing in digital prosthetic dentistry: an overview of recent developments in additive manufacturing. *J Clin Med* 2021;10:2010.
5. Jockusch J, Özcan M. Additive manufacturing of dental polymers: an overview on processes, materials and applications. *Dent Mater J* 2020;39:345–54.
6. Monzón M, Ortega Z, Hernández A, Paz R, Ortega F. Anisotropy of photopolymer parts made by digital light processing. *Materials (Basel)* 2017;10:64.
7. Li X, Xie B, Jin J, Chai Y, Chen Y. 3D printing temporary crown and bridge by temperature controlled mask image projection stereolithography. *Procedia Manuf* 2018;26:1023–33.
8. Son K, Lee JH, Lee KB. Comparison of intaglio surface trueness of interim dental crowns fabricated with SLA 3D printing, DLP 3D printing, and milling technologies. *Healthcare (Basel)* 2021;9:983.
9. Miyazaki T, Hotta Y, Kunii J, Kuriyama S, Tamaki Y. A review of dental CAD/CAM: current status and future perspectives from 20 years of experience. *Dent Mater J* 2009;28:44–56.
10. Beuer F, Schweiger J, Edelhoff D. Digital dentistry: an overview of recent developments for CAD/CAM generated restorations. *Br Dent J* 2008;204:505–11.
11. Alghazzawi TF. Advancements in CAD/CAM technology: options for practical implementation. *J Prosthodont Res* 2016;60:72–84.
12. Joda T, Ferrari M, Gallucci GO, Wittneben JG, Brägger U. Digital technology in fixed implant prosthodontics. *Periodontol* 2000 2017;73:178–92.
13. Infante L, Yilmaz B, McGlumphy E, Finger I. Fabricating complete dentures with CAD/CAM technology. *J Prosthet Dent* 2014;111:351–5.
14. Schneider D, Marquardt P, Zwahlen M, Jung RE. A systematic review on the accuracy and the clinical outcome of computer-guided template-based implant dentistry. *Clin Oral Implants*

- Res 2009;20(Suppl 4):73–86.
15. Quan H, Zhang T, Xu H, Luo S, Nie J, Zhu X. Photo-curing 3D printing technique and its challenges. *Bioact Mater* 2020;5:110–5.
  16. Kruth JP, Leu MC, Nakagawa T. Progress in additive manufacturing and rapid prototyping. *CIRP Annals* 1998;47:525–40.
  17. Singhvi MS, Zinjarde SS, Gokhale DV. Polylactic acid: synthesis and biomedical applications. *J Appl Microbiol* 2019;127:1612–26.
  18. Molinero-Mourelle P, Canals S, Gómez-Polo M, Solá-Ruiz MF, Del Río Highsmith J, Viñuela AC. Polylactic acid as a material for three-dimensional printing of provisional restorations. *Int J Prosthodont* 2018;31:349–50.
  19. Crenn MJ, Rohman G, Fromentin O, Benoit A. Polylactic acid as a biocompatible polymer for three-dimensional printing of interim prosthesis: mechanical characterization. *Dent Mater J* 2022;41:110–6.