









# Immunoglobulin G4-Related Lung Disease with Waxing and Waning Pulmonary Infiltrates: A Case Report

호전과 악화를 반복하는 폐 병변을 가진 면역글로불린 G4 관련 폐 질환: 증례 보고

John Baek, MD<sup>1</sup> , Jongmin Park, MD<sup>1\*</sup> , Byunggeon Park, MD<sup>1</sup> ,  
Jae-Kwang Lim, MD<sup>1</sup> , Chun Geun Lim, MD<sup>1</sup> , An Na Seo, MD<sup>2</sup> 

<sup>1</sup>Department of Radiology, School of Medicine, Kyungpook National University, Daegu, Korea


<sup>2</sup>Department of Pathology, School of Medicine, Kyungpook National University, Kyungpook National University Chilgok Hospital, Daegu, Korea

## ORCID iDs


John Baek  <https://orcid.org/0000-0002-3249-2359>

Jongmin Park  <https://orcid.org/0000-0001-9240-4181>

Byunggeon Park  <https://orcid.org/0000-0002-5807-9271>

Jae-Kwang Lim  <https://orcid.org/0000-0002-1299-9996>

Chun Geun Lim  <http://orcid.org/0000-0002-5876-659X>

An Na Seo  <https://orcid.org/0000-0001-6412-3067>

Received December 21, 2022

Revised February 22, 2023

Accepted June 11, 2023

\*Corresponding author

Jongmin Park, MD  
Department of Radiology,  
School of Medicine,  
Kyungpook National University,  
680 Gukchaebosang-ro, Jung-gu,  
Daegu 41944, Korea.

Tel 82-53-200-5390

Fax 82-53-422-2677

E-mail [jmmpark@naver.com](mailto:jmmpark@naver.com)

This is an Open Access article distributed under the terms of the Creative Commons Attribution Non-Commercial License (<https://creativecommons.org/licenses/by-nc/4.0>) which permits unrestricted non-commercial use, distribution, and reproduction in any medium, provided the original work is properly cited.

Immunoglobulin G4 (IgG4)-related lung disease can have various clinical courses. To our knowledge, reports of IgG4-related lung disease with waxing and waning pulmonary infiltrates only are very rare. A few lung nodules and ground glass opacities were incidentally found in a pre-operative evaluation in a 36-year-old female. The lung lesions showed waxing and waning in the follow-up chest CT. She underwent a surgical biopsy, and IgG4-related lung disease was confirmed.

**Index terms** Immunoglobulin G; Immunoglobulins; Lung Diseases; Computed Tomography, X-Ray

## INTRODUCTION

Immunoglobulin G4 (IgG4)-related disease is a systemic fibroinflammatory disease characterized by the substantial infiltration of IgG4-positive plasmacytes into various organs (1). IgG4-related lung disease accounts for 14%–54% of patients with IgG4-related disease. The patterns of IgG4-related lung disease are divided into five types. They are solid nodular, round-shaped ground glass opacity (GGO), bronchovascular, alveolar interstitial, and alveolar

consolidative types (2, 3). When left untreated, the disease spreads and progresses. This study describes the case of a 36-year-old female with solid nodular and round-shaped GGOs in bilateral lung fields. The lung lesions showed waxing and waning features in follow-up studies. The patient underwent surgical resection and was confirmed to have IgG4-related lung disease.

## **CASE REPORT**

A 36-year-old female had incidental abnormal basal lung findings on pre-operative abdominal CT. She was a non-smoker with an unremarkable medical or drug history. The patient had no history of raw food ingestion and no respiratory symptoms. Laboratory testing showed a white blood cell count of 4960/ $\mu$ L, C-reactive protein (CRP) of < 0.1 mg/dL, and erythrocyte sedimentation rate (ESR) of 15 mm/h (reference: 0–20 mm/h). Chest CT was conducted, and several GGOs were noted in the right lung (Fig. 1A). The initial radiological diagnosis was focal pneumonia. Since she had no respiratory complaints, the patient remained under close observation.

On follow-up CT 8 months later, previous GGOs were completely resolved. However, several new GGOs developed bilaterally in the lungs (Fig. 1B). The patient remained asymptomatic. The radiological impression was eosinophilic pneumonia. Subsequent laboratory tests showed an elevated IgE level (230 IU/mL, reference: < 100 IU/mL), CRP level of 0.1 mg/dL, ESR of 36 mm/h, and an eosinophil level within the normal range (1.2%, reference: 0%–7%). Additionally, the sparganum IgG test result was positive. The patient was diagnosed with sparganum infection, and praziquantel 600 mg was administered thrice daily for two days.

In the follow-up CT 26 months later, the previous GGOs had resolved, but new solid nodules were observed (Fig. 1C). The serum IgE level (227 IU/mL) and ESR (65 mm/h) were elevated. The CRP level was normal (0.19 mg/dL), and the sparganum IgG was negative. A surgical biopsy was performed to confirm the diagnosis. Right middle lobe (RML) wedge resection was done. The H&E staining of the pathological specimen revealed an inflammatory nodule with heavy infiltration of lymphoplasmic cells (Fig. 1D). Immunohistochemical staining of the specimen showed positive for IgG and IgG4 (Fig. 1E). There was no evidence of sparganum infection. The serum IgG was 1516 mg/dL, and the serum IgG4 was 650 mg/dL. The IgG4+ IgG ratio was 0.43. We made the diagnosis of IgG4-related lung disease based on the 2019 American College of Rheumatology/European League against Rheumatism classification criteria for IgG4-related disease (4). Steroids were administered. The follow-up chest CT a month after treatment showed almost complete resolution of the GGOs in the left and right lung fields (Fig. 1F). At the follow-up four months later, the patient was healthy without additional symptoms.

This study was approved by the Institutional Review Board of our hospital, and the requirement for informed consent was waived (IRB No. KNUH 2022-10-030).

## **DISCUSSION**

IgG4-related diseases are rare, with an incidence from 0.28 to 1.08/100000. Among those patients, 14% to 35% have lung involvement (5). About 75% of patients with IgG4-related lung

**Fig. 1.** IgG4-related lung disease with waxing and waning pulmonary infiltrates in a 36-year-old female.

**A.** Initial chest CT scan reveals a small ground glass opacity (arrow) in the RML.

**B.** Follow-up chest CT eight months later shows the disappearance of previous ground glass opacities and several newly developed ground glass opacities in bilateral lungs (arrows).

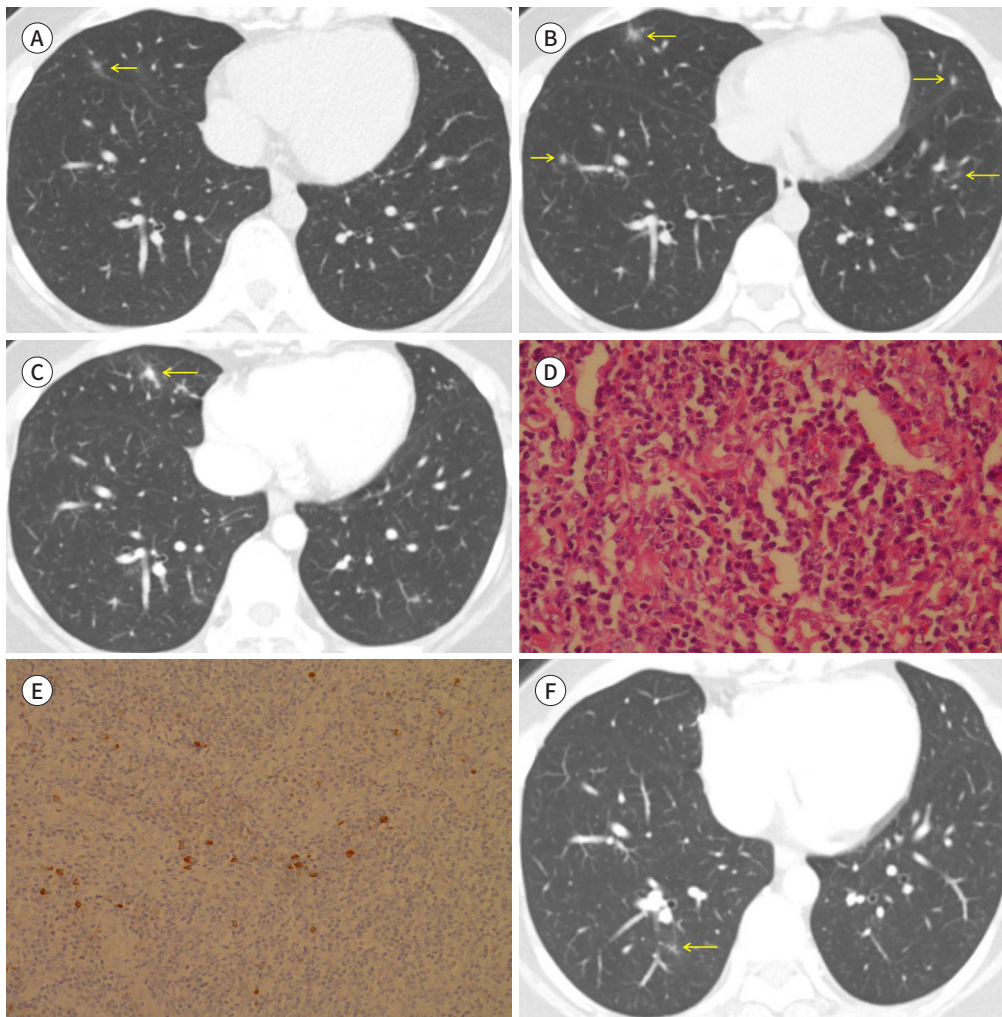
**C.** Follow-up chest CT 26 months later shows the resolution of previous lesions and a new nodule (arrow) after praziquantel administration.

**D.** H&E staining of the specimen from the lung (RML) shows an inflammatory nodule with heavy infiltration of lymphoplasmacytic cells ( $\times 200$ ).

**E.** Immunohistochemical staining of the specimen positive for IgG and IgG4 ( $\times 100$ ).

**F.** Follow-up chest CT one month after RML wedge resection shows postoperative changes and decreased size of the previous nodule (arrow) in the right lung.

IgG = immunoglobulin G, RML = right middle lobe



disease are asymptomatic and identified only by imaging. Chest CT images can show hilar or mediastinal lymphadenopathy, bronchovascular bundle thickening, interlobular septal wall thickening, nodules or infiltrations, and pleural thickening or pleural effusions (5).

The long-term clinical outcomes of IgG4-related lung disease have been evaluated in several studies. The common clinical course of IgG4-related lung disease is increased number and size of preexisting nodules in intervals. Depending on the stage of the disease, it varies from nodules to fibrosis (6). The atypical clinical course of IgG4-related lung disease is character-

ized by waxing and waning lung lesions. Lee & Ham (6) reported a case of a 73-year-old male with waxing and waning IgG4-related lung disease. Another atypical clinical course of IgG4-related lung disease is characterized by the spontaneous regression of the lung lesions. Seki et al. (7) reported cases of IgG4-related lung disease that underwent spontaneous regression. Waxing and waning of lung lesions in the clinical course of IgG4-related disease is rare. Jandee & Boonsri (8) reported the case of a 50-year-old male with IgG4-related disease, multiple liver abscesses, and waxing and waning lung nodules, mimicking a parasite infection. However, IgG4-related lung disease with waxing and waning pulmonary infiltrates only is very rare. In this case, the patient presented with several solid nodules and GGOs that exhibited a waxing and waning pattern.

The radiological differential diagnosis of typical IgG4-related lung disease includes infections, malignancies, and vasculitis (9). The lung lesions exhibited a waxing and waning nature in the present case. The differential diagnoses of waxing and waning pulmonary infiltrates include recurrent aspiration, cryptogenic organizing pneumonia, parasitic infections, and eosinophilic granulomatosis with polyangiitis. The patient had no underlying conditions (e.g., gastroesophageal reflux), resulting in recurrent aspiration. Additionally, the lesions were not distributed in dependent lung regions. The lung lesions did not exhibit a subpleural distribution or a reverse halo sign, characteristic of cryptogenic organizing pneumonia. Rather, he had a normal eosinophil count and no history of asthma. Therefore, eosinophilic granulomatosis with polyangiitis was unlikely.

Differentiating a parasitic infection was difficult in our patient. The patient was positive for serum sparganum antibody, which led to a misdiagnosis of sparganum infection. However, the serum sparganum antibody was negative in the follow-up study. The initial sparganum test likely yielded a false positive result (10). The false positive rate of the sparganum test is 6% (10).

Our patient underwent a surgical biopsy of the lesion in the RML and was diagnosed with IgG4-related lung disease according to the 2019 American College of Rheumatology/European League against Rheumatism classification criteria (4). In patients with IgG4-related lung disease, atypical features, such as the waxing and waning nature of nodules or GGOs, may be observed on chest CT.

### Author Contributions

Conceptualization, B.J., P.J., P.B., L.J., L.C.G.; investigation, B.J., P.J.; project administration, B.J., P.J.; resources, B.J., P.J., S.A.N.; supervision, P.J.; writing—original draft, B.J., P.J.; and writing—review & editing, B.J., P.J.

### Conflicts of Interest

The authors have no potential conflicts of interest to disclose.

### Funding

None

## REFERENCES

1. Stone JH, Zen Y, Deshpande V. IgG4-related disease. *N Engl J Med* 2012;366:539-551
2. Inoue D, Zen Y, Abo H, Gabata T, Demachi H, Kobayashi T, et al. Immunoglobulin G4-related lung disease: CT findings with pathologic correlations. *Radiology* 2009;251:260-270

3. Kang J, Park S, Chae EJ, Song JS, Hwang HS, Kim SJ, et al. Long-term clinical course and outcomes of immunoglobulin G4-related lung disease. *Respir Res* 2020;21:273
4. Wallace ZS, Naden RP, Chari S, Choi H, Della-Torre E, Dicaire JF, et al. The 2019 American College of Rheumatology/European League Against Rheumatism classification criteria for IgG4-related disease. *Arthritis Rheumatol* 2020;72:7-19
5. Morales AT, Cignarella AG, Jabeen IS, Barkin JS, Mirsaeidi M. An update on IgG4-related lung disease. *Eur J Intern Med* 2019;66:18-24
6. Lee DK, Ham SY. Sequential CT findings in two cases of immunoglobulin G4-related lung disease: focused on disease progression. *J Korean Soc Radiol* 2018;79:276-281
7. Seki N, Yamazaki N, Kondo A, Nomura K, Himi T. Spontaneous regression of lung lesions after excision of the submandibular gland in a patient with chronic sclerosing sialadenitis. *Auris Nasus Larynx* 2012;39:212-215
8. Jandee S, Boonsri P. Atypical manifestations of IgG4-related disease as multiple liver abscesses with subcapsular tracts and migratory pulmonary nodules mimicking parasitic infection. *Case Rep Gastroenterol* 2020;14:458-466
9. Kamisawa T, Zen Y, Pillai S, Stone JH. IgG4-related disease. *Lancet* 2015;385:1460-1471
10. Yeo IS, Yong TS, Im K. Serodiagnosis of human sparganosis by a monoclonal antibody-based competition ELISA. *Yonsei Med J* 1994;35:43-48

## 호전과 악화를 반복하는 폐 병변을 가진 면역글로불린 G4 관련 폐 질환: 증례 보고

백요한<sup>1</sup> · 박종민<sup>1\*</sup> · 박병건<sup>1</sup> · 임재광<sup>1</sup> · 임춘근<sup>1</sup> · 서안나<sup>2</sup>

면역글로불린 G4 (immunoglobulin G4; 이하 IgG4) 관련 폐 질환은 다양한 임상 경과를 가질 수 있다. 우리가 아는 한, 호전과 악화를 반복하는 폐 침윤을 동반한 IgG4 관련 폐 질환의 단독 보고는 매우 드물다. 36세 여성이 수술 전 평가에서 폐에 결절성 및 등근 모양의 간유리 음영을 발견했다. 폐 병변은 후속 흉부 컴퓨터 단층 촬영에서 호전과 악화를 반복하였다. 병변은 수술 후 IgG4 관련 폐 질환으로 확인되었다.

<sup>1</sup>경북대학교 의과대학 영상의학교실, <sup>2</sup>경북대학교 의과대학 칠곡경북대학교병원 병리학과