



CT Findings of May–Thurner Syndrome in Diffuse Idiopathic Skeletal Hyperostosis: A Case Report

특발성 골격 과골증과 병발한 메이-터너 증후군의 컴퓨터단층촬영 소견: 증례 보고

Jiwook Jeong, MD , Tae Eun Kim, MD*

Department of Radiology, Daegu Fatima Hospital, Daegu, Korea

ORCID iDs

Jiwook Jeong <https://orcid.org/0000-0001-6529-3383>

Tae Eun Kim <https://orcid.org/0000-0002-9874-0247>

May-Thurner syndrome (MTS) is a rare cause of deep vein thrombosis. Several cases of MTS because of various causes have been reported. However, MTS due to osteophytes in patients with underlying diffuse idiopathic skeletal hyperostosis (DISH) has not been reported in English literature, to the best of our knowledge. Here, we present the CT findings of MTS in patient with DISH.

Index terms Diffuse Idiopathic Skeletal Hyperostosis; May-Thurner Syndrome; Computed Tomography, X-Ray

INTRODUCTION

May-Thurner syndrome (MTS) is a rare vascular condition characterized by compression of the left common iliac vein between the right common iliac artery and lower lumbar spine. This condition can increase the risk of ipsilateral venous obstruction and deep vein thrombosis (DVT) (1).

The incidence of MTS remains largely unknown, and it occurs in approximately 2%–5% of patients with lower-extremity DVTs (1, 2). However, the actual incidence is estimated to be higher, and autopsy studies have shown that the incidence of MTS ranges between 14% and 32% (2).

Generally known risk factors of MTS include the female sex, postpartum, multiparity, oral contraceptives, scoliosis, dehydration, and hypercoagulable conditions (3). Osteophytes are a

Received September 26, 2022

Revised November 4, 2022

Accepted December 27, 2022

*Corresponding author

Tae Eun Kim, MD
Department of Radiology,
Daegu Fatima Hospital,
99 Ayang-ro, Dong-gu,
Daegu 41199, Korea.

Tel 82-53-940-7166

Fax 82-53-954-7417

E-mail kte1974@gmail.com

This is an Open Access article distributed under the terms of the Creative Commons Attribution Non-Commercial License (<https://creativecommons.org/licenses/by-nc/4.0>) which permits unrestricted non-commercial use, distribution, and reproduction in any medium, provided the original work is properly cited.

possible cause of MTS (4); however, a case of MTS in a patient with diffuse idiopathic skeletal hyperostosis (DISH) has not been reported.

In this report, we present a rare case of MTS caused by anterior osteophytes in a patient with underlying DISH.

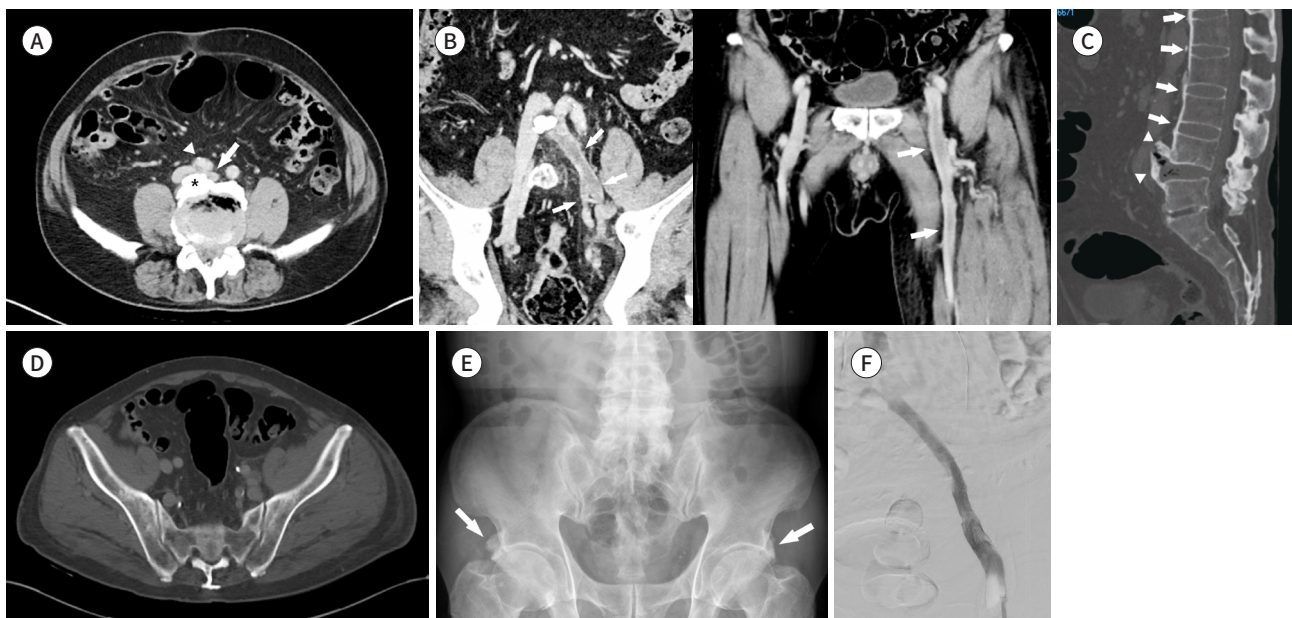
CASE REPORT

A 74-year-old male patient presented with a 3-days history of swelling in the left lower limb. He had no history of thromboembolic disease, symptoms such as chest pain and dyspnea, or a family history of hypercoagulable disorders. Laboratory findings revealed elevated D-dimer levels (8.70 mg/L fibrinogen equivalent units [FEU]). Physical examination revealed unilateral leg swelling on the left side, with cramping pain. CT venography of the lower extremity showed left common iliac vein compression between the right common iliac artery and vigorous lumbar osteophytes (Fig. 1A), with left common, internal, external iliac, and femoral vein thrombosis (Fig. 1B).

Sagittal reconstruction CT demonstrated continuous anterior bony bridges at the thoracolumbar spine with vigorous osteophyte formation at the anterior portion of the L4, 5 vertebral bodies (Fig. 1C). The intervertebral disc heights in the involved segments were preserved (Fig. 1C). Axial CT images provided no evidence of sacroiliitis (Fig. 1D). Pelvic radiographs showed bone proliferation (arrows) at the anterior inferior iliac spine, suggesting bilateral enthesopathy (Fig. 1E). Venography shows stent placed at iliac vein occlusion site with intact venous flow (Fig. 1F).

Fig. 1. May-Thurner syndrome underlying diffuse Idiopathic skeletal hyperostosis in a 74-years-old male patient.

- A.** Axial CT image shows the compressed left common iliac vein (arrow) between the right common iliac artery (arrowhead) and vigorous lumbar osteophytes (asterisk).
- B.** Coronal CT images show the left common, external, internal iliac, and femoral vein thrombosis (arrows).
- C.** Sagittal CT image demonstrates continuous anterior bony bridges (arrows) at the thoracolumbar spine with vigorous osteophytes (arrowheads) at the anterior portion of the L4-L5 vertebral bodies and preserved intervertebral disc height in involved segments.
- D.** Axial CT image demonstrates no evidence of sacroiliitis.
- E.** Pelvic radiograph shows bone proliferation (arrows) at the anterior inferior iliac spine, suggesting bilateral enthesopathy.
- F.** Venography shows stent placed at iliac vein occlusion site with intact venous flow.



showed bone proliferation at both anterior inferior iliac spine (AIIS), suggesting bilateral enthesopathy (Fig. 1E).

Prompt venography confirmed thrombotic occlusion of the left iliac to the femoral vein. After aspiration thrombectomy and percutaneous transluminal angioplasty, a 1.2 cm × 8 cm stent was placed at the site of iliac vein occlusion site (Fig. 1F). The patient recovered well and received anticoagulation therapy for 6 months. To date, there has been no evidence of DVT recurrence for 6 months.

This study was approved by the Institutional Review Board of our hospital and the requirement for informed consent was waived (IRB No. 2022-09-002).

DISCUSSION

DISH is a systemic non-inflammatory disease characterized by calcification and ossification of the ligaments and entheses. This condition mainly involves the spine and affects peripheral tendons and entheses (5, 6). Although the prevalence of DISH remains undetermined, some studies from the 1990s postulated that its prevalence is higher than 10% in patients over 70 years of age. This condition occurs more commonly in men than in women, and its incidence increases with age (7).

The etiology and pathogenesis of DISH remain unclear. However, this condition must be considered a bone-forming disease. New linear bone formation along the anterolateral aspect of the vertebral body is observed in the thoracic spine. Moreover, bony excrescences with bumpy and irregular contours at the superior and inferior vertebral margins are observed in the cervical and lumbar regions. In the lumbar region, cortical hyperostosis initially occurred at the anterior surface of the vertebral body. Subsequently, bony excrescences at the anterior margin of the vertebral body grew across the intervertebral disc space. In the progressive phase, anteriorly pointed bony excrescences develop with anterior disc extension (5).

The clinical presentation of DISH primarily includes spinal involvement-induced pain and limited range of motion. However, extraskelatal comorbidities, such as swallowing or respiratory problems, neurological symptoms, and metabolic or cardiovascular comorbidities, can occur because of prominent osteophytes in DISH.

In the DISH classification criteria, a diagnosis can be considered when two contiguous vertebrae are involved or when symmetrical enthesopathies are present without spinal involvement (6). In this case, radiologic images showed four or more continuous anterior bony bridges in the thoracolumbar spine. The intervertebral disc heights of the involved segments were preserved. Bone proliferation at both AIIS suggested bilateral enthesopathy, and no evidence of sacroiliitis was observed. Although the patient's exact history was not well known, we suspected that he had DISH based on radiological findings.

MTS is a rare venous obstruction caused by extrinsic compression. The common pathology of MTS is compression of the left common iliac vein between the right common iliac artery and lower lumbar spine. This condition increases the resistance of the iliac vein, resulting in possible obstruction and extensive DVT in the ipsilateral lower extremity (1). The conditions of patients, such as female sex, postpartum, multiparity, oral contraceptive use, dehydration, and hypercoagulable state, are known risk factors for MTS (3). Furthermore,

extrinsic compression due to endometriosis, distended bladder, iliac artery aneurysm, and penile prosthesis reservoir have been previously reported as rare causes of MTS (8). Lumbar spondylolisthesis and lumbosacral exostosis have also been reported to cause extrinsic compression of the iliac vein, resulting in MTS (4, 9).

Although various cases of MTS have been reported, MTS caused by osteophytes in patients with underlying DISH has not been reported. Anatomical deformity of the lumbar spine can cause MTS, as indicated by a case report of MTS secondary to lumbar spondylolisthesis or lumbosacral exostosis (4, 9). In this case, the patient was diagnosed with DISH based on several radiological findings. DISH can cause bumpy, irregular bony excrescence at the superior and inferior vertebral margins in the cervical and lumbar regions (5). These bony excrescences can cause many problems, such as dysphagia or airway obstruction due to extrinsic compression (10), and tend to be larger and more irregular than those usually noted in spondylosis deformans (5). In this patient, MTS occurred due to compression of the left common iliac vein between vigorous lumbar osteophytes in DISH and the right common iliac artery. Therefore, lumbar osteophytes in DISH may be a rare cause of MTS.

In the setting of MTS, CT shows a compressed left common iliac vein between the right common iliac artery and the lower lumbar spine with or without DVT. If DVT was present, low-density lesions in the left common iliac vein to the deep veins of the lower extremity could be seen on pre-contrast CT, and venous filling defects on post-contrast CT. Abnormal vein dilatation due to DVT and venous varicosities can also be observed on CT. In some cases, CT may reveal an unusual cause of compression of the left common iliac vein in the pelvic cavity.

In conclusion, radiologists reporting cross-sectional imaging of the lumbar spine should be perceptive to filling defects or abnormal dilatation of the left common iliac vein in patients with DISH for an early diagnosis of MTS.

Author Contributions

Conceptualization, K.T.E.; data curation, K.T.E.; project administration, K.T.E.; visualization, all authors; writing—original draft, all authors; and writing—review & editing, all authors.

Conflicts of Interest

The authors have no potential conflicts of interest to disclose.

Funding

None

REFERENCES

1. Mousa AY, AbuRahma AF. May-Thurner syndrome: update and review. *Ann Vasc Surg* 2013;27:984-995
2. Harbin MM, Lutsey PL. May-Thurner syndrome: history of understanding and need for defining population prevalence. *J Thromb Haemost* 2020;18:534-542
3. Hng J, Su S, Atkinson N. May-Thurner syndrome, a diagnosis to consider in young males with no risk factors: a case report and review of the literature. *J Med Case Rep* 2021;15:141
4. Wasserburger J, Haponyuk A, Modhia UM, Langsfeld M, Paterson AJ, Rana MA. Lumbosacral exostosis as a rare cause of iliac vein compression and significant limb swelling. *J Vasc Surg Cases Innov Tech* 2019;5: 529-531
5. Resnick D, Niwayama G. Radiographic and pathologic features of spinal involvement in diffuse idiopathic skeletal hyperostosis (DISH). *Radiology* 1976;119:559-568

6. Utsinger PD. Diffuse idiopathic skeletal hyperostosis. *Clin Rheum Dis* 1985;11:325-351
7. Nascimento FA, Gatto LA, Lages RO, Neto HM, Demartini Z, Koppe GL. Diffuse idiopathic skeletal hyperostosis: a review. *Surg Neurol Int* 2014;5(Suppl 3):S122-S125
8. Janczak D, Ruciński A, Skóra J, Szyber P. [Iliac-femoral vein thrombosis as a first symptom of the isolated common and internal iliac artery aneurysm]. *Wiad Lek* 2000;53:458-461. Polish
9. McKean D, Allman Sutcliffe J, El Hassan H, Parvizi N, Wali A, Warakaulle D, et al. May-Thurner variant secondary to degenerative lumbar spondylolisthesis: a case report. *BJR Case Rep* 2017;3:20170011
10. Terzi R. Extraskelatal symptoms and comorbidities of diffuse idiopathic skeletal hyperostosis. *World J Clin Cases* 2014;2:422-425

특발성 골격 과골증과 병발한 메이-터너 증후군의 컴퓨터단층촬영 소견: 증례 보고

정지욱 · 김태은*

메이-터너 증후군은 심부정맥혈전증을 유발할 수 있는 흔하지 않은 원인으로 알려져 있다. 다양한 원인에 의한 메이-터너 증후군 사례가 보고되고 있지만 우리가 아는 한, 미만성 골격 과골증 환자에서 뼈결돌기에 의한 메이-터너 증후군 사례는 영어 논문으로 보고된 바가 없다. 저자들은 특발성 골격 과골증 환자에서 발생한 메이-터너 증후군의 컴퓨터단층촬영 소견을 제시하고자 한다.

대구파티마병원 영상의학과