



Gerstmann-Sträussler-Scheinker Disease: A Case Report

Gerstmann-Sträussler-Scheinker병: 증례 보고

Minji Shin, MD , Donghyun Kim, MD* , Young Jin Heo, MD ,
Jin Wook Baek, MD , Suyoung Yun, MD , Hae Woong Jeong, MD

Department of Radiology, Inje University College of Medicine, Busan Paik Hospital, Busan, Korea

ORCID iDs

Minji Shin <https://orcid.org/0000-0002-9584-0066>
Donghyun Kim <https://orcid.org/0000-0002-3429-7557>
Young Jin Heo <https://orcid.org/0000-0002-4765-0727>
Jin Wook Baek <https://orcid.org/0000-0003-4632-4951>
Suyoung Yun <https://orcid.org/0000-0001-5064-1082>
Hae Woong Jeong <https://orcid.org/0000-0002-4912-9302>

Received June 7, 2022
Revised August 7, 2022
Accepted October 2, 2022

*Corresponding author

Donghyun Kim, MD
Department of Radiology,
Inje University College of Medicine,
Busan Paik Hospital,
75 Bokji-ro, Busanjin-gu,
Busan 47392, Korea.

Tel 82-51-890-6579

Fax 82-51-896-1085

E-mail dionephy@gmail.com

This is an Open Access article distributed under the terms of the Creative Commons Attribution Non-Commercial License (<https://creativecommons.org/licenses/by-nc/4.0>) which permits unrestricted non-commercial use, distribution, and reproduction in any medium, provided the original work is properly cited.

Gerstmann-Sträussler-Scheinker (GSS) disease is a rare hereditary prion disease which is clinically characterized by a progressive cerebellar ataxia followed by cognitive impairment. We report a rare case of GSS disease in a 39-year-old male patient who complained of a progressive gait disturbance followed by dysarthria with cognitive impairment, after five months from the onset of initial symptom. His brain MRI scan revealed multifocal symmetric diffusion restricted lesions with T2/FLAIR hyperintensities in bilateral cerebral cortices, basal ganglia, and thalami. His family members also manifested similar symptoms in their 40–50s, suggesting the possibility of a genetic disease. Finally, he was genetically diagnosed with GSS disease by real-time quaking-induced conversion and prion protein (*PRNP*) gene sequencing test.

Index terms Prion Disease; Gerstmann-Sträussler-Scheinker Syndrome; Prion Protein; Magnetic Resonance Imaging

INTRODUCTION

Gerstmann-Sträussler-Scheinker disease (GSS) is a rare hereditary prion disease caused by prion protein gene (*PRNP*) gene mutation on chromosome 20. The incidence is about 1–10 per 100 million per year, with clinical onset in the fifth decade. It is characterized by prominent cerebellar ataxia and following gradually progressive cognitive impairment (1). Herein, we report a case of GSS in a 39-year-old male patient.

CASE REPORT

The patient was a 39-year-old-male who was referred to our hospital with a 7-month history of rapidly progressive gait disturbance. After five months from the initial symptom onset, dysarthria and cognitive impairment developed. He was on medication for diabetes mellitus.

Neurologic examination at our hospital revealed poor performance on the finger-to-nose and rapid alternative tests with an ataxic gait. On Seoul Neuropsychological Screening Battery, he showed severe impairments in all domains, including attention, frontal/executive function, memory, visuospatial function, and language.

Many family members exhibited similar symptoms in their early 40s, including his paternal grandmother, father, three uncles and aunt, and female/male cousins (Fig. 1A). They all died in their 40s to 50s, about 7 to 8 years from the symptom onset, without a definite diagnosis.

Routine laboratory tests at the outside hospital revealed no evidence of paraneoplastic disorders, autoimmune thyroiditis, or systemic vasculitis. On laboratory examinations at the previous hospital, gene analyses for spinocerebellar ataxia (SCA1, 2, 3, 6, 7, 17) and Dentatorubro-Pallidoluysian atrophy (DRPLA) were negative.

On brain MR imaging, there were multifocal symmetric diffusion-restricted lesions with T2/FLAIR hyperintensities involving both cerebral cortex, basal ganglia, and thalami (Fig. 1B), suggesting sporadic type Creutzfeldt-Jakob disease (CJD). Cerebellar atrophy was not definite.

Electroencephalogram (EEG) was non-specific, and periodic sharp wave complexes, which are characteristic of CJD, were not shown. Routine CSF analysis was normal, but the Tau protein level was elevated (8798.4 pg/mL), and 14-3-3 protein was positive. Moreover, the RT-QuIC assay on CSF also showed positivity. Finally, the *PRNP* gene test revealed proline-to-leucine (P102L) mutation in codon 102, confirming the diagnosis of GSS (Fig. 1C).

This study was approved by the Institutional Review Board of Inje University Busan Paik Hospital, and the requirement for written informed consent was waived (IRB No. 2022-04-035).

DISCUSSION

GSS is one of the familial prion diseases that account for 10%–15% of all human prion diseases. According to their pathophysiologic characteristics, familial prion diseases are classified into Genetic CJD, Fatal familial insomnia, and GSS (2).

GSS was first described in an Austrian family in 1936, and later Kretzschmarv detected the P102L mutation in the *PRNP* gene in 1991. *PRNP* gene mutation predisposes mutant Pr^{PC} to convert spontaneously into misfolded pathogenic isoform (Pr^{PSc}) (3). This disease was known to exhibit an autosomal inheritance pattern, but now it is understood that one-third of GSS patients are *de novo* (1). Also, other than P102L mutation (wherein valine is replaced by leucine), more than 30 sites of *PRNP* gene mutations have been reported. GSS is also well known for its clinical heterogeneity according to various gene mutations and even within families showing the same gene mutations.

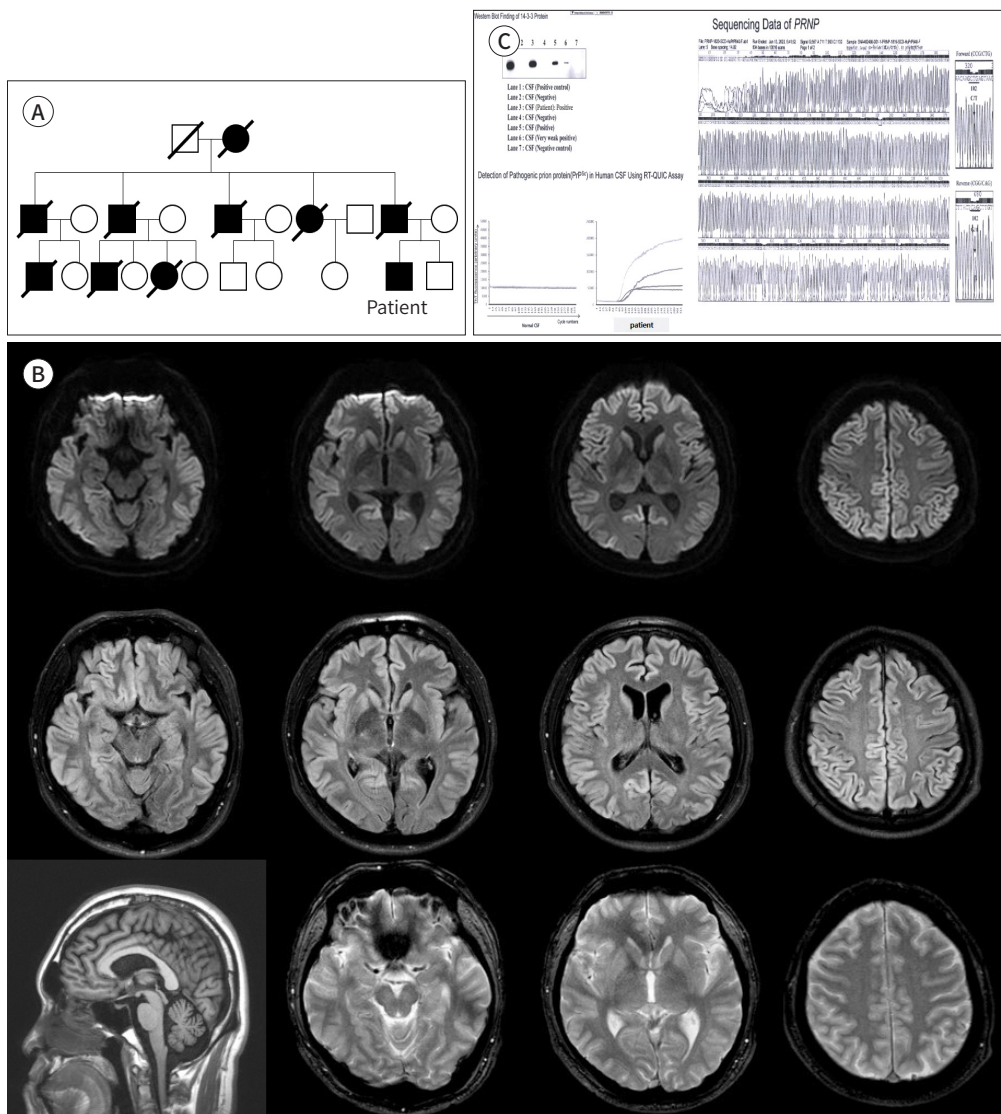
According to CDC's diagnostic criteria for CJD in 2018, familial CJD can be diagnosed when the patient and the first-degree relative of the patient have definite or probable CJD or the patient has a neuropsychiatric disorder and disease-specific PrP gene mutation. Our patient

Fig. 1. A 39-year-old male diagnosed with Gerstmann-Sträussler-Scheinker disease.

A. Pedigree of the patient. Filled symbols refer to the affected patients, and diagonal lines refer to the deceased. Circles stand for females, and squares stand for males.

B. Axial diffusion weighted imaging (1st row) and fluid attenuated inversion recovery (2nd row) images show multifocal symmetric hyperintense lesions involving the bilateral cerebral cortex, basal ganglia, and thalami. The T1 sagittal image (3rd row, first image) shows no definite cerebellar atrophy. The gradient echo sequences images (3rd row, right three images) show no evidence of hemorrhage.

C. Western blot test confirming 14-3-3 protein positivity (left upper). RT-QuIC and sequencing result of *PRNP* gene, proline replaced by leucine at codon 102 (P102L) (left lower and right).



showed a positive P102L mutation, which is a disease-specific mutation for GSS. Therefore, he could be diagnosed with GSS.

Typical clinical presentation of GSS patients is slowly progressing cerebellar ataxia at the beginning, with cognitive decline that develops later, around 2 to 4 years from the initial onset (4). Movement disorders, typically myoclonus and athetosis can also occur in the disease course (5). The median survival time from symptom onset to death is reported to be two to ten years, which is longer than in other prion diseases (6).

Brain MR imaging of GSS patients is usually normal early in the course of the disease, and then cortical and/or cerebellar atrophy follows later with disease progression. A recent study reported that 42.9% of GSS patients only exhibited cortical or cerebellar atrophy. In 20.6% of patients, high signal intensity appeared in the cortex, caudate nucleus, or putamen on DWI or FLAIR images, which were similar to findings of sporadic CJD (7).

The cognitive decline of our patient had developed after five months from the first cerebellar symptom onset, which is earlier than previous reports of GSS. This feature makes our patient fall into the CJD phenotype of P102L mutation patients.

Patients with P102L mutation can be clinically divided into two categories (8); 79% of patients show cerebellar symptoms in the early disease courses, so-called GSS phenotype, and other 21% show rapidly developing dementia in the early disease courses, CJD phenotype. Compared to the GSS type, the CJD type was less frequently accompanied by abnormalities in brain MR imaging, EEG, and CSF study. However, our patient was CJD phenotype and did show abnormal brain MR findings, with increased Tau protein level in CSF as well. There was a case report of a CJD phenotype GSS patient in Korea, and that patient also showed diffuse DWI/FLAIR high SI, similar to our patient (9). With sufficient cases, future studies may focus on imaging differentiation of sporadic CJD and GSS using advanced techniques, such as volumetric analysis.

Our patient's clinical presentation, brain MR imaging, and CSF studies, including increased Tau protein and 14-3-3 protein positivity, could all suggest sporadic CJD. However, he had a family history with distinctive symptoms, and P102L mutation could finally make the diagnosis of GSS.

To conclude, we present a rare case of GSS disease. GSS typically shows progressing cerebellar ataxia at first, and following cognitive decline occurs later. GSS patients can exhibit a wide range of MRI findings. Some appear normal or cortical/cerebellar atrophy, and others show high signal intensity in the cortices and striatum, the same as in sporadic CJD patients. Although GSS and sporadic CJD share the clinical and radiological findings, especially in specific phenotypes including our patient, family history could raise the possibility of familial diseases, and additional gene tests could finally help differentiate GSS from sporadic CJD.

Author Contributions

Writing—original draft, S.M.; and writing—review & editing, K.D., H.Y.J., B.J.W., Y.S., J.H.W.

Conflicts of Interest

The authors have no potential conflicts of interest to disclose.

Funding

None

REFERENCES

1. Kovács GG, Puopolo M, Ladogana A, Pocchiari M, Budka H, van Duijn C, et al. Genetic prion disease: the EURO-CJD experience. *Hum Genet* 2005;118:166-174
2. Fragoso DC, Gonçalves Filho AL, Pacheco FT, Barros BR, Aguiar Littig I, Nunes RH, et al. Imaging of Creutzfeldt-Jakob disease: imaging patterns and their differential diagnosis. *Radiographics* 2017;37:234-257
3. Zhao MM, Feng LS, Hou S, Shen PP, Cui L, Feng JC. Gerstmann-Sträussler-Scheinker disease: a case report.

World J Clin Cases 2019;7:389-395

4. Arata H, Takashima H, Hirano R, Tomimitsu H, Machigashira K, Izumi K, et al. Early clinical signs and imaging findings in Gerstmann-Sträussler-Scheinker syndrome (Pro102Leu). *Neurology* 2006;66:1672-1678
5. Smid J, Studart A Neto, Landemberger MC, Machado CF, Nóbrega PR, Canedo NHS, et al. High phenotypic variability in Gerstmann-Sträussler-Scheinker disease. *Arq Neuropsiquiatr* 2017;75:331-338
6. Shetty PD. Gerstmann-Straussler-Scheinker disease-a review. *J Neurol Neurosci* 2021;12:378
7. Kang MJ, Suh J, An SS, Kim S, Park YH. Pearls & Oy-sters: challenging diagnosis of Gerstmann-Sträussler-Scheinker disease: clinical and imaging findings. *Neurology* 2019;92:101-103
8. Higuma M, Sanjo N, Satoh K, Shiga Y, Sakai K, Nozaki I, et al. Relationships between clinicopathological features and cerebrospinal fluid biomarkers in Japanese patients with genetic prion diseases. *PLoS One* 2013; 8:e60003
9. Jung SH, Chae SH, Hwangbo J, Kim HS, Lee YJ, Kim YS, et al. Gerstmann-Sträussler-Scheinker disease (Pro-102Leu) presenting as rapidly progressive dementia. *J Korean Neurol Assoc* 2019;37:384-387

Gerstmann-Sträussler-Scheinker병: 증례 보고

신민지 · 김동현* · 허영진 · 백진욱 · 윤수영 · 정해웅

Gerstmann-Sträussler-Scheinker (이하 GSS) disease는 드문 유전성 프리온 질환으로 초기에 발생해 진행되는 소뇌실조와 후기에 발생하는 인지기능 저하가 특징적이다. 저자들은 진행하는 보행장애와 5개월 후 발생한 구음 장애, 인지 기능 저하를 주소로 내원한 39세 남성 환자의 증례를 보고하고자 한다. 뇌 MRI에서 양측 대뇌피질과 기저핵, 시상하부에 확산 저하를 동반한 T2 강조영상에서의 고신호 강도 병변이 관찰되었다. 환자는 모두 40-50대에 비슷한 증상을 호소하였던 가족력을 동반하였으며 PRNP 유전자 검사를 통해 GSS로 확진되었다.

인제대학교 의과대학 부산백병원 영상의학과