

Significance of Preoperative Nerve Reconstruction Using Diffusion Tensor Imaging Tractography for Facial Nerve Protection in Vestibular Schwannoma

Yuanlong Zhang,^{1,2} Hongliang Ge,^{1,2} Mingxia Xu,^{1,2} Wenzhong Mei^{1,2}

Department of Neurosurgery,¹ The First Affiliated Hospital, Fujian Medical University, Fuzhou, China

Department of Neurosurgery,² Binhai Branch of National Regional Medical Center, The First Affiliated Hospital, Fujian Medical University, Fuzhou, China

Objective : The facial nerve trace on the ipsilateral side of the vestibular schwannoma was reconstructed by diffusion tensor imaging tractography to identify the adjacent relationship between the facial nerve and the tumor, and to improve the level of intraoperative facial nerve protection.

Methods : The clinical data of 30 cases of unilateral vestibular schwannoma who underwent tumor resection via retrosigmoid approach were collected between January 2019 and December 2020. All cases underwent magnetic resonance imaging examination before operation. Diffusion tensor imaging and anatomical images were used to reconstruct the facial nerve track of the affected side, so as to predict the course of the nerve and its adjacent relationship with the tumor, to compare the actual trace of the facial nerve during operation, verify the degree of coincidence, and evaluate the nerve function (House-Brackmann grade) after surgery.

Results : The facial nerve of 27 out of 30 cases could be displayed by diffusion tensor imaging tractography, and the tracking rate was 90% (27/30). The intraoperative locations of facial nerve shown in 25 cases were consistent with the preoperative reconstruction results. The coincidence rate was 92.6% (25/27). The facial nerves were located on the anterior middle part of the tumor in 14 cases, anterior upper part in eight cases, anterior lower part in seven cases, and superior polar in one case. Intraoperative facial nerve anatomy was preserved in 30 cases. Among the 30 patients, total resection was performed in 28 cases and subtotal resection in two cases. The facial nerve function was evaluated 2 weeks after operation, and the results showed grade I in 12 cases, grade II in 16 cases and grade III in two cases.

Conclusion : Preoperative diffusion tensor imaging tractography can clearly show the trajectory and adjacent position of the facial nerve on the side of vestibular schwannoma, which is beneficial to accurately identify and effectively protect the facial nerve during the operation, and is worthy of clinical application and promotion.

Key Words : Acoustic neuroma · Diffusion tensor imaging · Facial nerve · Fiber tracking.

• Received : June 8, 2022 • Revised : August 14, 2022 • Accepted : October 9, 2022

• Address for correspondence : **Wenzhong Mei**

Department of Neurosurgery, Binhai Branch of National Regional Medical Center, The First Affiliated Hospital, Fujian Medical University, Chazhong road, Jin an District, Fuzhou 350005, China

Tel : +86-059187982122, Fax : +86-059187982126, E-mail : 13705964171@163.com, ORCID : <https://orcid.org/0000-0001-6459-837X>

This is an Open Access article distributed under the terms of the Creative Commons Attribution Non-Commercial License (<http://creativecommons.org/licenses/by-nc/4.0>) which permits unrestricted non-commercial use, distribution, and reproduction in any medium, provided the original work is properly cited.

INTRODUCTION

Vestibular schwannoma (VS) is a benign intracranial tumor, which can cause cranial nerve and cerebellar dysfunction such as hearing loss and gait instability. Total tumor removal can effectively prevent tumor recurrence, but it may increase the probability of facial nerve (FN) injury, cause postoperative facial paresis or paralysis and reduce the quality of life of patients. Therefore, preservation of the FN is of paramount importance during tumor excision¹⁾.

It is a major challenge for the neurosurgeon to accurately assess the risk of FN injury before surgery, to avoid FN injury during surgery, and reduce the occurrence of postoperative facial paralysis. We can judge the approximate position and course of FN, and predict the anatomical relationship between FN and VS before operation using diffusion tensor imaging (DTI) tractography, which can provide important reference for the surgeons.

In this study, DTI tractography was used to establish the relationship between FN and VS before surgery. During the operation, the FN was protected under the guidance of neurophysiological monitoring, so as to reduce the probability of FN injury and improve the preservation rate of FN and postoperative quality of life of patients.

MATERIALS AND METHODS

The study was approved by the Research Ethics Board of The First Affiliated Hospital of Fujian Medical University (IRB number [2019]170).

Clinical information

A total of 30 consecutive patients with unilateral VS were surgically treated at The First Affiliated Hospital of Fujian Medical University between January 2019 and December 2020, including 10 males and 20 females, with an average age of 50.6 years (range, 23–75). The disease course ranged from 1 week to 11 years. The tumors were located on the left in 13 cases and on the right in 17 cases. The largest tumor diameter was 57 mm, the smallest diameter was 21 mm, and the average was 35 mm. The major clinical symptoms before operation included hearing loss (n=23), dizziness (n=5), facial pain (n=2).

The tumor extent was graded using the Hannover classifica-

tion system : T1, purely intrameatal; T2, intra- and extrameatal; T3a, filling the cerebellopontine cistern; T3b, reaching the brainstem; T4a, compressing the brainstem; T4b, severely dislocating the brainstem and compressing the fourth ventricle¹⁴⁾. Patients whose tumors were located in the cerebellopontine angle area, were preliminarily diagnosed as VS (patients with Hannover classification higher than T3a) and underwent surgical treatment at our department were included. Patients with a history of intracranial surgery, radiotherapy, and non-schwannoma diagnosed by postoperative pathology were excluded.

Methods

DTI parameters by a 3-T magnetic resonance imaging (MRI) scanner (Siemens, Erlangen, Germany) were as follows : 1.0-mm thickness, 31 slices, 30 directions, echo time 96 msec, repetition time 11700 msec, number of excitations=1, acquisition matrix size 256×256, b value=1000 sec/mm². Anatomical images were preoperatively obtained by routine T1-weighted and T2-weighted imaging. The imaging data were transferred to the neuronavigation workstation (iPlan 3.05; Brainlab, Heimstetten, Germany) via network with Dicom format. The locations of the ipsilateral internal auditory canal and the FN entry area at the brainstem were considered as the region of interest (ROI) preoperatively on the workstation, and the nerve fiber bundles passing through the ROI were tracked. The FN was reconstructed with the help of DTI. A fractional anisotropy (FA) threshold of 0.1 was used, and the minimum fiber length was 5 mm. During the operation, the resection of the VS was performed through the retrosigmoid approach in the park bench position. The FN location was categorized according to the classification (anterior, posterior, superior, or inferior to the tumor) by Sampath et al.²⁴⁾ Anterior and posterior locations were further subdivided into superior one-third, middle one-third, and inferior one-third.

The FN was identified and protected during tumor resection according to the course reconstructed pre-operation, combined with neurophysiological monitoring system (Nihon Kohden, Tokyo, Japan). To identify the FN during the operation, facial muscle action potential was evoked by direct stimulation of the FN bundle at 0.1 mA. The degree of tumor extirpation was assessed by postoperative imaging. The FN function was evaluated by House-Brackmann classification system, 2 weeks post-operation¹²⁾.

RESULTS

The FNs of 27 out of 30 cases could be displayed by DTI, and the tracking rate was 90% (27/30). The positions of FN identified in 25 cases during the operation were consistent with the locations of preoperative reconstruction. The coincidence rate of intraoperative verification and preoperative localization of FN was 92.6% (25/27). Among them, the FNs were located on the anterior middle part to the tumor in 14 cases, anterior upper in eight cases, anterior lower in seven cases, and superior polar in one case.

The anatomy of FN was preserved in all 30 cases. Total resection was performed in 28 cases and subtotal resection in

two cases. The FN function was evaluated two weeks after the operation as follows : grade I in 12 cases, grade II in 16 cases, and grade III in two cases. The FN reconstruction result of a left VS (case 22) is shown in Fig. 1. The clinical characteristics of the 30 patients, including the FN location and function, are shown in Table 1.

DISCUSSION

With the development of microsurgical technology and use of neurophysiological monitoring, the mortality rate of VS surgery has remained below 0.5%, but the facial paralysis as-

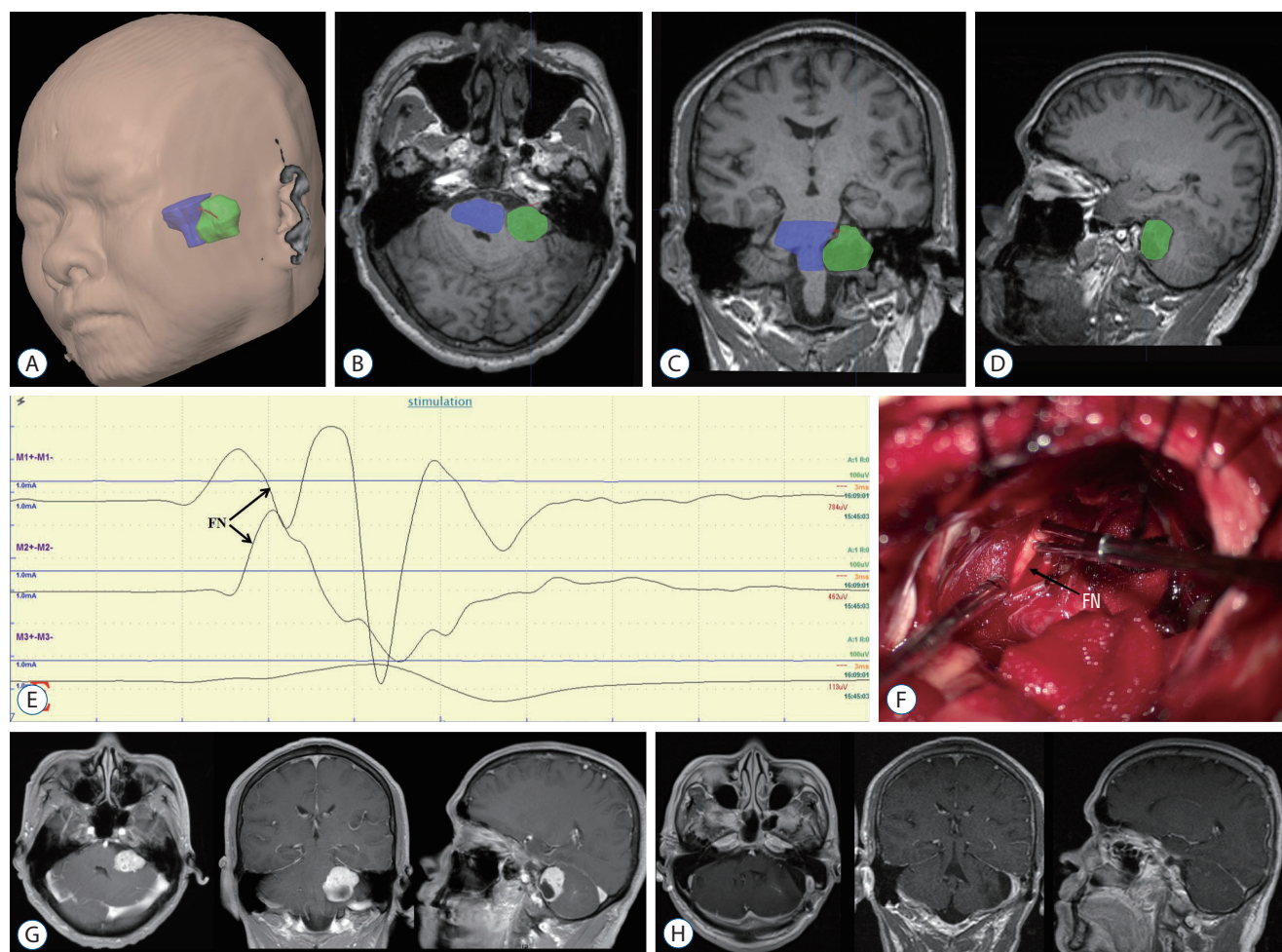


Fig. 1. In the case 22, the facial nerve (FN) was located on the anterior upper part of the vestibular schwannoma (VS). A : The three-dimensional reconstruction showing the spatial relationship between the FN (red) and the VS (green). The blue object represents the brain stem. B-D : Axial/coronal/sagittal view showing the FN on the anterior upper of the VS. E and F : Neurophysiological monitoring and intraoperative image confirming the FN and its relationship with VS. G and H : Axial/coronal/sagittal view showing the preoperative and postoperative magnetic resonance imaging images of the VS.

sociated with surgery seriously affects the quality of life of patients⁷⁾. The focus of VS surgery has shifted from simple tumor excision to preservation of nerve function. Therefore, how to maximally preserve the FN function of patients has become a challenge for neurosurgeons²⁸⁾.

Intraoperative identification of the FN mainly relies on elec-

trophysiological monitoring. It has been reported that the preservation rate of FN by neurophysiological monitoring is related to tumor size, ranging from 80–92% for tumors measuring <1 cm, 80–92% for tumors measuring 1–2 cm, and 50–70% for tumors measuring >2 cm²⁷⁾. Moreover, FN monitoring has a false-positive rate of 12–62%¹⁶⁾. However, neuro-

Table 1. Summary of the patient demographic and clinical characteristic

Case No.	Sex	Age (years)	Tumor side	Tumor diameter (mm)	FN location		Correlation	FN function	
					DTI fiber tracking	Intraop findings		Preop	Postop
1	F	52	R	43	AM	AI	No	I	II
2	M	44	R	35	AI	AI	Yes	I	II
3	M	44	R	26	AM	AM	Yes	I	II
4	F	32	L	31	AM	AM	Yes	I	I
5	F	67	R	30	S	S	Yes	I	I
6	F	48	R	34	AS	AM	No	I	II
7	F	49	R	31	AM	AM	Yes	I	I
8	F	67	L	29	AS	AS	Yes	I	II
9	F	64	L	45	AS	AS	Yes	I	III
10	F	59	R	32	AM	AM	Yes	I	II
11	M	67	R	32	AM	AM	Yes	I	I
12	F	51	R	29	AI	AI	Yes	I	II
13	M	25	L	42	AS	AS	Yes	I	II
14	F	75	L	37	AS	AS	Yes	I	II
15	M	44	R	26	AS	AS	Yes	I	I
16	F	40	R	35	AM	AM	Yes	I	I
17	F	38	R	54	N/A	AM	-	I	II
18	M	70	L	30	AI	AI	Yes	I	II
19	F	74	L	52	N/A	AS	-	I	II
20	M	39	L	36	AM	AM	Yes	I	II
21	M	23	L	30	AM	AM	Yes	I	I
22	M	57	L	31	AS	AS	Yes	I	II
23	M	62	L	36	AM	AM	Yes	I	I
24	F	44	R	27	AM	AM	Yes	I	I
25	F	54	L	21	AM	AM	Yes	I	I
26	F	29	R	42	AI	AI	Yes	I	II
27	F	59	L	41	AS	AS	Yes	I	I
28	F	54	R	57	N/A	AI	-	I	II
29	F	32	R	41	AI	AI	Yes	I	III
30	F	55	R	26	AM	AM	Yes	I	I

Postop FN function : House-Brackmann grade determined 2 weeks after surgery. FN : facial nerve, DTI : diffusion tensor imaging, F : female, R : right, AM : anterior middle one-third, AI : anterior inferior one-third, M : male, L : left, S : superior to the tumor, AS : anterior superior one-third, N/A : not available

physiological monitoring plays an important role in the protection of FN. In order to protect the FN, it is necessary to examine all areas of the tumor during the operation to identify the FN, and to confirm that there is no electrical response of the FN before tumor resection, since the adjacent relationship between the tumor and the FN cannot be established before the operation. Studies have shown that electrophysiological stimulation may damage the FN¹⁵⁾. Repeated stimulation can further diminish the already damaged FN function²⁷⁾. Hong et al.¹¹⁾ pointed out that the deterioration of FN function after VS was related to repeated stimulation of the FN during operation. Therefore, the frequency of FN monitoring should be reduced to lessen the stimulation of the FN during the operation, but makes it more difficult to preserve the FN.

Protection of the FN is mainly related to the surgeon's experience, tumor size and preoperative functional status of the FN²³⁾. Surgeons with extensive experience can better protect the FN from damage, with the assistance of neurophysiological monitoring⁸⁾. However, for inexperienced surgeons, it is more difficult to preserve the FN during the operation. Accordingly, if the surgeon can predict the FN course before the operation, the FN can be protected in a targeted manner during the operation, so as to reduce the frequency of FN stimulation, thereby lessening the probability of FN injury.

Large VS often displaces the FN. Consequently, there may be some deviation in locating the FN by anatomy²⁹⁾. A massive VS may compress and distort the FN, which is thinned or even pushed, increasing the difficulty of FN protection²²⁾. In our case series, the tumor grades were T3a or higher according to the Hannover classification, which makes it challenging to preserve the FN.

DTI is a new MRI technology based on the diffusion characteristics of water molecules in tissues. It was proposed by Pierpaoli et al.¹⁸⁾ in 1994 and applied to the imaging of white matter fibers in the brain. It is the only method that can display white matter fiber bundles *in vivo*. DTI is widely used to trace intracranial fibers, such as pyramidal tract¹⁷⁾, optic radiation⁴⁾, and arcuate fasciculus¹⁹⁾.

Hodaie first applied DTI to reconstruct cranial nerves in healthy adults¹⁰⁾. Taoka et al.²⁶⁾ used DTI to show the FN course of VS for the first time. Since then, DTI has been increasingly employed to reconstruct the FN course of VS^{3,20,21)}.

Sampath et al.²⁴⁾ reported that the FN was anterior to the tumor in most cases, and the most common position was

anterior middle part of the tumor. A few cases were superior polar, inferior polar and posterior to the tumor, and in rare cases, the FN passed through the tumor²⁴⁾. Ma et al.¹³⁾ reported that anterior to the tumor, the FN was located anterior superior to the tumor in most cases, followed by the anterior middle. Among the 30 cases in our series, the proportion of FN located anterior to the tumor was the highest (14 cases), accounting for 46.7% (14/30), which was similar to that reported by Sampath et al.²⁴⁾. In this case series, the FN was located on the anterior upper of the tumor in eight cases, anterior lower in seven cases, and superior polar in one case. There were no cases in which the FN was located on the inferior polar or posterior to the tumor, which may be related to the small number of cases.

In a study of 24 large VS cases by Gerganov et al.⁶⁾, 22 cases successfully demonstrated FN traces by DTI (22/24). Taoka et al.²⁶⁾ studied eight cases of VS, and FN trajectories were successfully displayed in seven cases by DTI (7/8). Choi et al.⁵⁾ reported that FN courses were successfully showed in all 11 cases of VS (11/11). Hilly et al.⁹⁾ reported 21 cases of VS, of which 20 cases demonstrated FN, and the reconstruction rate was 95% (20/21). Among the 30 patients in our series, the FN was displayed by DTI in 27 cases, and the tracking rate was 90% (27/30). The three patients for which the FN could not be reconstructed by DTI had giant VS (>5 cm in diameter). The reason might be that the massive tumor severely crushed and damaged the FN, and the sheath structure had degenerated, resulting in changes in the anisotropy of water molecules, which could not be completely tracked in the DTI scan. During the operation, we saw that the FNs were compressed, very thin, and adhered closely to the tumor in these three cases.

Gerganov et al.⁶⁾, Song et al.²⁵⁾, and Borkar et al.²⁾ reported the concordance rates of 90.9% (20/22), 92.9% (13/14), and 89% (16/18), respectively, between the reconstructed FN course preoperatively and the position of FN intraoperatively. The agreement rate of FN in our series was 92.6% (25/27). The locations of FN during operation were inconsistent with the position of FN tracked before operation in two cases, both of which were cystic VS. It is speculated that the larger cystic change may interfere with the FA value around the nerve, resulting in errors in the tracking results.

Among the 30 patients in our series, total tumor resection was performed in 28 patients, subtotal resection in two

patients. In the latter two cases, a thin layer of tumor tissue was left on the nerve in order to protect the FN function due to unclear boundary and adhesion between the VS and the FN. The anatomical structure of FN was preserved. The FN function was evaluated 2 weeks after operation, which showed grade I in 12 cases, grade II in 16 cases, and grade III in two cases. The two cases are case 9 and case 29. Although we have found the FN location in the operation, but the tumor adhered closely to the FN, and the nerve was harassed by accident during the tumor resection.

Among the 30 cases, FNs were demonstrated in 27 cases by DTI tractography before operation. The FN trace could be identified in a timely and accurate manner preoperatively by predicting the relationship between the FN and the tumor, combined with intraoperative nerve electrophysiological monitoring. During the operation, the VS was gently, carefully and sharply separated to reduce the traction of the FN and avoid direct injury of the FN, so as to protect the FN and achieve satisfactory clinical results.

This study had some limitations. There was no control group in which FN reconstruction was not performed. This was a preliminary study at a single center. Further research such as a study on the relationship between tumor character and DTI reconstruction possibility is needed in the future.

CONCLUSION

DTI tractography can clearly display the trajectory of the FN and the adjacent VS before the operation, which has a high coincidence rate with the intraoperative FN identification, and is helpful to accurately identify and effectively protect the FN during operation, which is worthy of clinical application and promotion.

AUTHORS' DECLARATION

Conflicts of interest

No potential conflict of interest relevant to this article was reported.

Informed consent

Informed consent was obtained from all individual partici-

pants included in this study.

Author contributions

Conceptualization : YZ; Data curation : YZ; Formal analysis : HG; Funding acquisition : HG; Methodology : MX; Project administration : MX; Visualization : WM; Writing - original draft : YZ; Writing - review & editing : WM

Data sharing

None

Preprint

None

ORCID

Yuanlong Zhang	https://orcid.org/0000-0003-4457-7373
Hongliang Ge	https://orcid.org/0000-0001-5499-6710
Mingxia Xu	https://orcid.org/0000-0002-6493-5353
Wenzhong Mei	https://orcid.org/0000-0001-6459-837X

• Acknowledgements

This study is supported by Startup Fund for scientific research, Fujian Medical University (grant No. 2018QH1079, 2019QH1087) and Guiding Project of Fujian Science and Technology Department (grant No. 2016Y0037, 2021Y0013).

References

1. Baro V, Landi A, Brigadoi S, Castellaro M, Moretto M, Anglani M, et al. : Preoperative prediction of facial nerve in patients with vestibular schwannomas: the role of diffusion tensor imaging-a systematic review. **World Neurosurg** 125 : 24-31, 2019
2. Borkar SA, Garg A, Mankotia DS, Joseph SL, Suri A, Kumar R, et al. : Prediction of facial nerve position in large vestibular schwannomas using diffusion tensor imaging tractography and its intraoperative correlation. **Neurol India** 64 : 965-970, 2016
3. Chen DQ, Quan J, Guha A, Tymianski M, Mikulis D, Hodaie M : Three-dimensional in vivo modeling of vestibular schwannomas and surrounding cranial nerves with diffusion imaging tractography. **Neurosurgery** 68 : 1077-1083, 2011
4. Chen X, Weigel D, Ganslandt O, Buchfelder M, Nimsky C : Prediction of visual field deficits by diffusion tensor imaging in temporal lobe epilepsy

- surgery. **Neuroimage** **45** : 286-297, 2009
5. Choi KS, Kim MS, Kwon HG, Jang SH, Kim OL : Preoperative identification of facial nerve in vestibular schwannomas surgery using diffusion tensor tractography. **J Korean Neurosurg Soc** **56** : 11-15, 2014
6. Gerganov VM, Giordano M, Samii M, Samii A : Diffusion tensor imaging-based fiber tracking for prediction of the position of the facial nerve in relation to large vestibular schwannomas. **J Neurosurg** **115** : 1087-1093, 2011
7. Gurgel RK, Theodosopoulos PV, Jackler RK : Subtotal/near-total treatment of vestibular schwannomas. **Curr Opin Otolaryngol Head Neck Surg** **20** : 380-384, 2012
8. Heros RC, Bhatia R : Editorial: vestibular schwannoma and the facial nerve. **J Neurosurg** **116** : 695-696; discussion 696, 2012
9. Hilly O, Chen JM, Birch J, Hwang E, Lin VY, Aviv RI, et al. : Diffusion tensor imaging tractography of the facial nerve in patients with cerebellopontine angle tumors. **Otol Neurotol** **37** : 388-393, 2016
10. Hodaie M, Quan J, Chen DQ : In vivo visualization of cranial nerve pathways in humans using diffusion-based tractography. **Neurosurgery** **66** : 788-795; discussion 795-796, 2010
11. Hong W, Cheng H, Wang X, Feng C : Influencing factors analysis of facial nerve function after the microsurgical resection of acoustic neuroma. **J Korean Neurosurg Soc** **60** : 165-173, 2017
12. House JW, Brackmann DE : Facial nerve grading system. **Otolaryngol Head Neck Surg** **93** : 146-147, 1985
13. Ma J, Su S, Yue S, Zhao Y, Li Y, Chen X, et al. : Preoperative visualization of cranial nerves in skull base tumor surgery using diffusion tensor imaging technology. **Turk Neurosurg** **26** : 805-812, 2016
14. Matthies C, Samii M : Management of 1000 vestibular schwannomas (acoustic neuromas): clinical presentation. **Neurosurgery** **40** : 1-9; discussion 9-10, 1997
15. Nakao Y, Piccirillo E, Falcioni M, Taibah A, Kobayashi T, Sanna M : Electromyographic evaluation of facial nerve damage in acoustic neuroma surgery. **Otol Neurotol** **22** : 554-557, 2001
16. Neff BA, Ting J, Dickinson SL, Welling DB : Facial nerve monitoring parameters as a predictor of postoperative facial nerve outcomes after vestibular schwannoma resection. **Otol Neurotol** **26** : 728-732, 2005
17. Nimsky C, Ganslandt O, Fahlbusch R : Implementation of fiber tract navigation. **Neurosurgery** **61** : 306-317; discussion 317-318, 2007
18. Pierpaoli C, Jezzard P, Basser PJ, Barnett A, Di Chiro G : Diffusion tensor MR imaging of the human brain. **Radiology** **201** : 637-648, 1996
19. Propper RE, O'Donnell LJ, Whalen S, Tie Y, Norton IH, Suarez RO, et al. : A combined fMRI and DTI examination of functional language lateralization and arcuate fasciculus structure: effects of degree versus direction of hand preference. **Brain Cogn** **73** : 85-92, 2010
20. Roundy N, Delashaw JB, Cetas JS : Preoperative identification of the facial nerve in patients with large cerebellopontine angle tumors using high-density diffusion tensor imaging. **J Neurosurg** **116** : 697-702, 2012
21. Samala R, Borkar SA, Sharma R, Garg A, Suri A, Gupta D, et al. : Effectiveness of preoperative facial nerve diffusion tensor imaging tractography for preservation of facial nerve function in surgery for large vestibular schwannomas: results of a prospective randomized study. **Neurol India** **67** : 149-154, 2019
22. Samii M, Matthies C : Management of 1000 vestibular schwannomas (acoustic neuromas): surgical management and results with an emphasis on complications and how to avoid them. **Neurosurgery** **40** : 11-21; discussion 21-23, 1997
23. Samii M, Gerganov V, Samii A : Improved preservation of hearing and facial nerve function in vestibular schwannoma surgery via the retrosigmoid approach in a series of 200 patients. **J Neurosurg** **105** : 527-535, 2006
24. Sampath P, Rini D, Long DM : Microanatomical variations in the cerebellopontine angle associated with vestibular schwannomas (acoustic neuromas): a retrospective study of 1006 consecutive cases. **J Neurosurg** **92** : 70-78, 2000
25. Song F, Hou Y, Sun G, Chen X, Xu B, Huang JH, et al. : In vivo visualization of the facial nerve in patients with acoustic neuroma using diffusion tensor imaging-based fiber tracking. **J Neurosurg** **125** : 787-794, 2016
26. Taoka T, Hirabayashi H, Nakagawa H, Sakamoto M, Myochin K, Hirohashi S, et al. : Displacement of the facial nerve course by vestibular schwannoma: preoperative visualization using diffusion tensor tractography. **J Magn Reson Imaging** **24** : 1005-1010, 2006
27. Youssef AS, Downes AE : Intraoperative neurophysiological monitoring in vestibular schwannoma surgery: advances and clinical implications. **Neurosurg Focus** **27** : E9, 2009
28. Zanoletti E, Faccioli C, Martini A : Surgical treatment of acoustic neuroma: outcomes and indications. **Rep Pract Oncol Radiother** **21** : 395-398, 2016
29. Zhang Y, Chen Y, Zou Y, Zhang W, Zhang R, Liu X, et al. : Facial nerve preservation with preoperative identification and intraoperative monitoring in large vestibular schwannoma surgery. **Acta Neurochir (Wien)** **155** : 1857-1862, 2013