

Current Concept

Clin Shoulder Elbow 2023;26(4):445-454
<https://doi.org/10.5397/cise.2022.01396>

Arthroscopic Latarjet procedure: current concepts and surgical techniques

Sang-Jin Shin, Jae Hyung Kim, Jonghyun Ahn

Department of Orthopedic Surgery, Ewha Womans University Seoul Hospital, Ewha Womans University College of Medicine, Seoul, Korea

The Latarjet procedure is a surgical procedure that can effectively restore glenohumeral stability, especially in patients with anterior shoulder instability and glenoid bone loss. Many studies have shown comparable clinical outcomes between patients undergoing the arthroscopic Latarjet procedure and those undergoing traditional open methods or other glenohumeral joint stabilization procedures. However, the arthroscopic Latarjet procedure is a challenging technique due to the unfamiliar portal placements, proximity of neurovascular structures, and serious postoperative complications. The arthroscopic Latarjet procedure has not yet been widely applied, and a clear understanding of the anatomical structure and the precise methods is required prior to operation performance. Satisfactory clinical outcomes can be achieved by thorough preoperative planning and proper implant fixation methods.

Keywords: Shoulder joint; Arthroscopy; Surgical stabilization; Orthopedic surgical procedures

INTRODUCTION

The coracoid process transfer, Latarjet, procedure was first described by Latarjet, a French physician, in 1954. The procedure is indicated for patients with recurrent shoulder instability with significant glenoid bone deficiency. The Latarjet procedure provides stability to the anterior part of the shoulder joint through three mechanisms called "triple blockings." First, the transferred coracoid process increases the surface area of the glenoid. Second, when the arm is in the abduction-external rotation position, the conjoined tendon attached to the coracoid process acts as a sling to suppress the forward translation of the humeral head. Third, the subscapularis muscle is separated and fixed by the transferred conjoined tendon, which acts as a supplement to the insufficient anterior joint capsule [1]. Traditionally, the Latarjet

procedure was performed as a salvage procedure in cases of significant glenoid bone defect or recurrent instability after stabilization surgery [2]. However, the indications are expanding, especially in Europe. The Latarjet is now considered as a primary procedure in patients with recurrent shoulder dislocation, regardless of glenoid bone defect, or multidirectional instability after failed conservative treatment [3].

Use of an arthroscopic Latarjet procedure was first reported by Lafosse in 2007. In 2010, Lafosse reported satisfactory clinical outcomes, including quick return to daily activities, in 100 patients. Since then, the arthroscopic Latarjet approach has been widely applied in clinical practice due to its several advantages. This approach can assist with the observation of other pathologic lesions within the glenohumeral joint, proper localization of the coracoid graft, and prevention of technical errors such as graft

Received: November 30, 2022 Revised: January 23, 2023 Accepted: January 25, 2023

Correspondence to: Sang-Jin Shin

Department of Orthopedic Surgery, Ewha Womans University Seoul Hospital, Ewha Womans University College of Medicine, 260 Gonghang-daero, Gangseo-gu, Seoul 07804, Korea

Tel: +82-2-6956-1656, Fax: +82-2-2642-0349, Email: sjshin622@ewha.ac.kr, ORCID: <https://orcid.org/0000-0003-0215-2860>

Copyright© 2023 Korean Shoulder and Elbow Society.

This is an Open Access article distributed under the terms of the Creative Commons Attribution Non-Commercial License (<http://creativecommons.org/licenses/by-nc/4.0/>) which permits unrestricted non-commercial use, distribution, and reproduction in any medium, provided the original work is properly cited.

overhanging above the joint line. In addition, the approach can prevent postoperative joint stiffness from scar tissue; and patients can expect a faster return to activities of daily living [4-6].

INDICATIONS

In general, marked bone defects of the glenoid and humeral head and their recurrence after Bankart repair or other joint stabilization surgery are accepted as indications for the arthroscopic Latarjet procedure. We consider the Latarjet procedure as a primary surgical choice in patients with glenoid bone loss of more than 20% or in seizure-controlled epilepsy patients. Patients with poor anterior capsulolabral tissue quality after primary repair or recurrence after Bankart revision repair are also indications. In addition, various factors such as the patient's condition and the surgeon's experience are considered before performing the Latarjet procedure. In a study of 189 patients, Yang et al. [7] compared a group that underwent arthroscopic Bankart and remplissage repair with a group that underwent the Latarjet procedure. Their findings were that those patients with less than 25% of glenoid bone loss had equivalent clinical outcomes between the two groups. Additionally, the Latarjet procedure resulted in less patient pain and low recurrence rates. In the same study, the Latarjet procedure was shown to have better clinical outcomes and lower recurrence rates in contact sports players.

PREOPERATIVE PLANNING

A preoperative glenohumeral computed tomography scan is helpful to assess anatomical information related to the procedure. During arthroscopy, accurately measuring the required length of the screw is often difficult due to unclear vision and restriction of access. Therefore, the recommendation is to determine the

length of the fixation screw to be used by measuring the anteroposterior length of the glenoid and the thickness of the coracoid process. The anatomical shape of the coracoid process should also be assessed. Since the anatomical direction and curvature of coracoid processes vary, a preoperative three-dimensional (3D) computed tomography scan can help determine the exact angle and direction when fashioning the screw hole and performing the osteotomy (Fig. 1). Hardy et al. [8] reported that preoperative computed tomography scans showed high reproducibility in identifying anatomical structures during arthroscopic Latarjet procedures. These researchers also compared the screw positions of groups with and without preoperative computed tomography and reported that the lower screw was located in a statistically unacceptable position in the group without preoperative planning, demonstrating the importance of preoperative planning [9].

Selection of Graft Fixation Methods

The first arthroscopic Latarjet fixation method introduced by Lafosse et al. [6] required the use of two cannulated screws. However, fixation using metal screws can result in screw loosening and graft non-union. Coracoid graft fracture during screw insertion and impingement of the screw head with the humeral head due to an inappropriate screw angle can also be complications.

Because of these complications, surgeons have devised a procedure using cortical bone fixation buttons. Boileau et al. [10,11] introduced a method of passing two suture strands from the coracoid process to the posterior cortex of the glenoid through the bone tunnel and fixing the strands using the cortical buttons. In a study of 136 patients, Boileau et al. [10,11] reported that bone union was achieved in 95% of patients and that no secondary surgery was required to remove the implant. Xu et al. [12] introduced a procedure using a cortical bone fixation button and

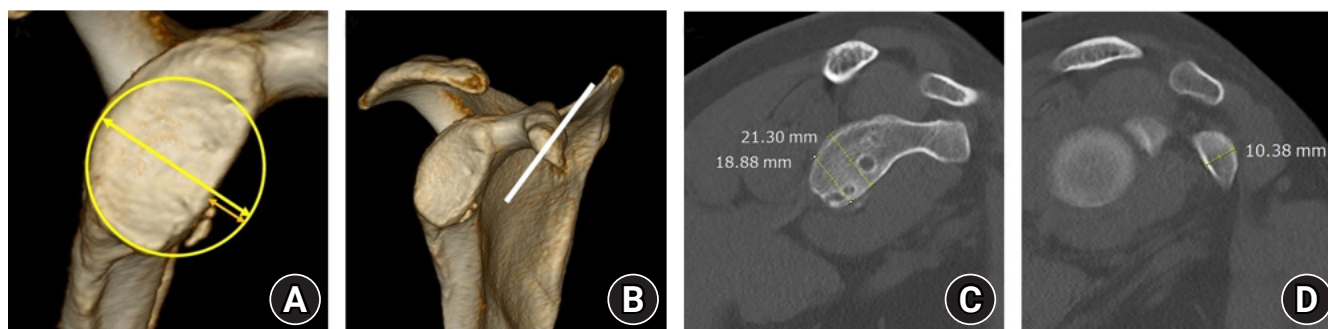


Fig. 1. Checklists with preoperative three-dimensional computed tomography right shoulder. (A) Glenoid bone defect is assessed on enface view using Sugaya method. (B) The approximate screw angle and location should be determined by analyzing the direction and inclination of the coracoid process. (C) The anteroposterior length of glenoid is checked. (D) The anteroposterior thickness of the coracoid process is assessed. Taken together with the anteroposterior glenoid size, this thickness estimates the approximate length of the screw.

an anti-rotation suture anchor; they reported that 98% of 102 patients achieved bone union after an average follow-up of 40.3 months. Similarly, Castricini et al. [13] devised a procedure using four cortical bone fixation buttons.

Controversy surrounds the optimal fixation method for the graft. In a biomechanical study using a cadaver, Provencher et al. [14] reported that there were no significant differences in the maximum tensile strength and average failure strength between the metal screws and the cortical bone fixation buttons. However, Williams et al. [15] reported that the total load at failure and maximum cycle displacement for the cortical bone fixation button were significantly lower than that for a metal screw. Hardy et al. [16] analyzed 236 patients who had metal screw fixation and 72 patients who had cortical button fixation. These researchers found a significantly lower instability recurrence of 2.5% with screw fixation compared to 8.3% in patients fixed with cortical buttons, demonstrating the superiority of metal screws in fixation. However, no patient needed revision surgery with recurrence of instability after using the cortical fixation buttons. Rather, the re-operation rate was higher (5.9%) in patients with metal screws, which was due to complications such as metal screw irritation and protrusion [16]. Therefore, each fixation method has pros and cons and is selected carefully according to the surgeon's preference and the patient's condition.

SURGICAL TECHNIQUES

We prefer the arthroscopic Latarjet procedure using two cannulated screws, the same method as that proposed by Lafosse et al. [6] The surgical procedure consists of joint space exploration, anterior glenoid preparation, exposure of the coracoid process, coracoid osteotomy, separation of the subscapularis and coracoid transfer, and fixation with cannulated screws.

Patient Position and Portal Placement

The patient is placed in a modified beach chair position, and a surgical drape is applied to sufficiently expose the center of the sternum. The patient's upper body angle should be 30°–45°, which is lower than the general beach chair position. We use six arthroscopic portals. As with any other arthroscopy procedure, the arthroscopic Latarjet procedure requires an arthroscopic portal hole in the appropriate location and thorough use of the portal. These are crucial for successful surgery (Fig. 2). Some of these portals are unfamiliar; however, since the unfamiliar ones are anatomically safe, these are made with greater confidence as surgeons gain more experience. Since there are many procedures performed on the medial side of the conjoined tendon, anatomi-

cal knowledge is essential before performing surgery. Unlike other arthroscopic procedures, the portals in the arthroscopic Latarjet procedure do not use cannulas and move freely during the operation.

Joint Space Exploration and Anterior Glenoid Preparation

The posterior portal, the arthroscopic examination viewing portal, for the introduction of the arthroscope is made parallel to the articular surface. After the arthroscopic examination, the anterior portal is made on the lateral side of the coracoacromial ligament. Instruments are inserted through the anterior portal; and the rotator interval, remnant anterior labral tissue, and joint capsule are debrided to create sufficient space and prevent interference between the glenoid and the transferred coracoid process. Marking the areas in the 2 and 5 o'clock positions from the expected location of the coracoid process graft attachment using an electric cautery device helps determine the location. Next, the lateral portal is made between the conjoined tendon and the subscapularis tendon in a direction parallel to the upper part of the subscapularis tendon. Ease in checking the location of the coracoid process is achieved by releasing the lateral and inferior surfaces of the coracoid process through the lateral portal using electric cautery.

When the arthroscopy is moved to the lateral portal, trimming the anterior glenoid bone surface by inserting the burr through the anterior portal is easy. This process not only provides debridement for bone union but is also an important task in matching the shape of the inferior part of the coracoid and the anterior glenoid surface to achieve perfect congruency (Fig. 3).

Exposure of the Coracoids Process

With the lateral portal used as the viewing portal, the inferior

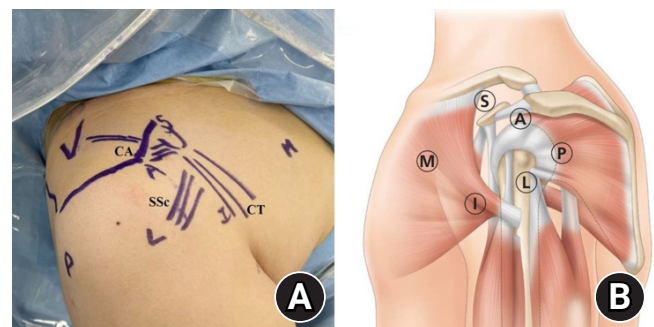


Fig. 2. Portals for the arthroscopic Latarjet procedure. (A) Surface anatomy and portals location of right shoulder. P: posterior portal, A: anterior portal, L: lateral portal, I: inferior portal, M: medial portal, S: superior portal, CA: coracoacromial ligament, CT: conjoined tendon, SSc: subscapularis tendon. (B) Schematics of portals for arthroscopic Latarjet procedure [17].

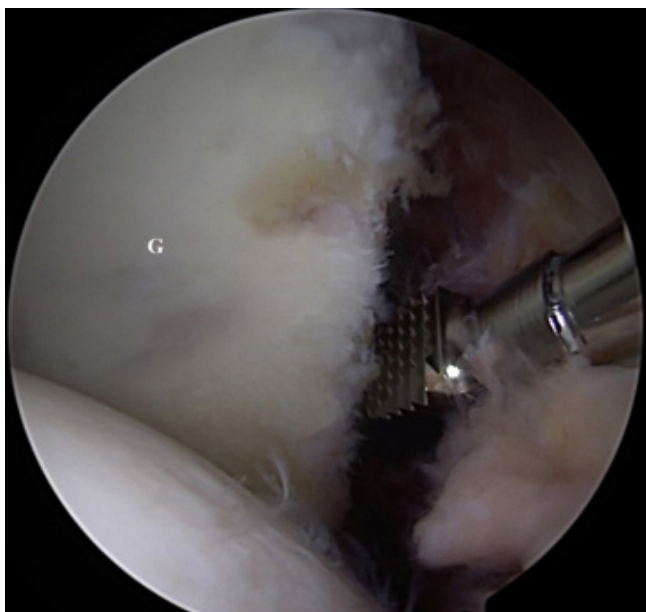


Fig. 3. Anterior glenoid preparation (viewing portal: lateral, working portal: anterior, right shoulder). An electrocautery device and burr are inserted through the anterior portal to trim the transplant site of anterior glenoid. G: glenoid.

portal is created in the long axis of the conjoined tendon, which is near the axillary pouch at the surface anatomical perspective. Using the inferior portal as the working portal, the soft tissue of the lateral and superior surface of the coracoid, including the coracoacromial ligament, is released. Inserting a Wissinger rod into the anterior portal assists in the exposure of the superior surface of the coracoid and in securing sufficient space by sustaining the deltoid and thoracic muscles.

After moving the arthroscopy to the inferior portal, the soft tissues on the superior and inferior surfaces of the coracoid are released as much as possible using the lateral portal as a working portal. Especially because the inferior surface of the coracoid will be attached to the anterior glenoid at a later stage of the operation, decortication can be performed in advance. Afterwards, the medial portal is made using a spinal needle in a position that can be entered in parallel to the glenoid articular surface. Using the medial portal as the working portal, the medial side of the coracoid is exposed. Since the musculocutaneous nerve is located medially to the coracoid, the pectoralis minor muscle is detached with caution so as not to damage the nerve. All soft tissue on the slope of the coracoid is removed, and the superior surface is exposed to the border of the coracoclavicular ligament base. The medial and lateral sides of the conjoined tendon are also released to facilitate the transfer of the coracoid.

Coracoid Osteotomy

After the exposure to the coracoid is completed, a superior portal is formed for the osteotomy. Since the superior portal is used not only for osteotome insertion but also for making a screw hole in the coracoid, the location and size of the portal should be considered carefully. With the inferior portal as the viewing portal, a guide is inserted through the superior portal to select the location to be drilled on the upper surface of the coracoid. Since the length and shape of coracoid processes differ between individuals, the use of preoperative 3D computed tomography is beneficial to determine the direction of the coracoid that can be most congruently attached to the joint when inserting a guide. In addition, not positioning the guide too far is important to avoid distal cortical bone fractures. This is accomplished by identifying the interface between the tendon and the bone. The guide is positioned 7 mm inward from the lateral surface of the coracoid, two proximal and distal guide wires are inserted along the guide, and drilling is performed along the guide wire. After drilling, a top hat is inserted in each hole to prevent the metal screw head from being inserted into the coracoid cortical bone and causing a fracture when pressure is applied during close contact with the anterior glenoid bone. The coracoid holding wire is then inserted; this plays an important role in helping to connect the coracoid positioning double cannula after the coracoid osteotomy. The coracoid holding wire passes through the proximal top hat and the inferior surface of the coracoid, returns to the distal top hat, and is withdrawn via the proximal and distal ends through the medial portal (Fig. 4).

Next, an osteotome is inserted through the superior portal to perform coracoid process osteotomy. If the burr is inserted through the lateral portal, decorticating the area in which the osteotomy is to be made can prevent fracture in an unexpected direction. When the osteotomy is performed completely, the arthroscope can be moved to the lateral portal, and two 3.5-mm coracoid screws are connected to the coracoid through a double cannula along the coracoid holding wire to manipulate the coracoid process (Fig. 5). The sharp boundaries of the osteotomized site and the inferior surface of the coracoid are trimmed to fit the shape of the glenoid and decorticated to facilitate bone union.

Subscapularis Muscle Separation and Coracoids Transfer

The lateral portal is used as the viewing portal and the inferior portal as the working portal. The separation location is generally acceptable for the boundary between the upper 2/3 and the lower 1/3 of the subscapularis tendon. However, separating the middle part of the subscapularis muscle does not affect the clinical outcome. Limiting separation to the muscle as much as possible is

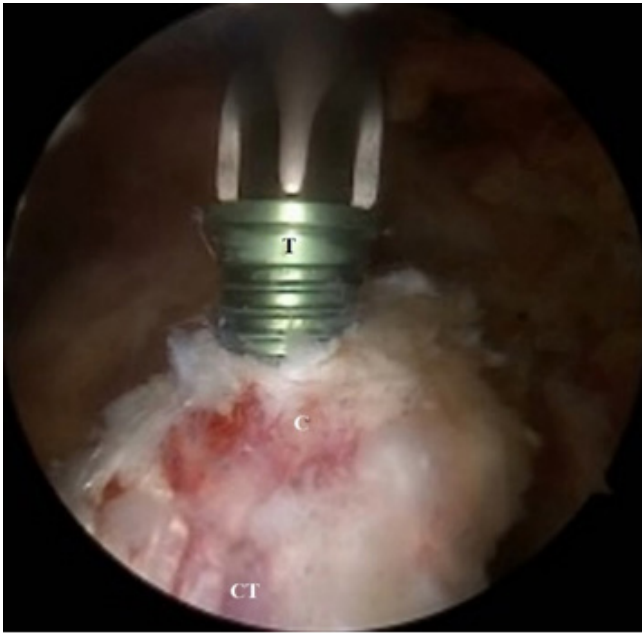

Fig. 4. Exposure of the coracoid process (viewing portal: inferior, working portal: lateral and medial, right shoulder). The coracoacromial ligament and pectoralis minor tendon were released from the lateral and medial side of the coracoid process, respectively. Then two top hats were inserted in the coracoid holes after making holes in appropriate positions using the guide. T: top hat, C: coracoid process, CT: conjoined tendon.

recommended. However, if the size of the graft is large or if the patient has bulky muscles, separating some tendinous parts of the muscle may be necessary. Since the axillary nerves are located medially, identifying the nerves to prevent damage is helpful. Separating the subscapularis muscle and securing a space through which the coracoid process will be transferred is important. We insert a silastic drain into the anterior portal to draw the superior part of the subscapularis and insert a Wissinger rod into the posterior portal to drag the inferior part downward (Fig. 6).

The coracoid graft connected to the double cannula is transferred through the separated subscapularis muscle to the anterior glenoid transplant site, which was marked previously. The Wissinger rod is inserted into the posterior portal and positioned parallel to the glenoid surfaces to determine the medial and lateral positions of the coracoid graft. Care must be taken not to under-hang or overhang the graft with joint surfaces.

Fixation with Metal Screws

Once the location of the coracoid graft has been determined, each guide pin is inserted through the coracoid screw located in the double cannula for fixation. The guide pin passes through the transferred coracoid graft, the anterior and posterior cortical bones of the glenoid, and the posterior skin of the scapula and is

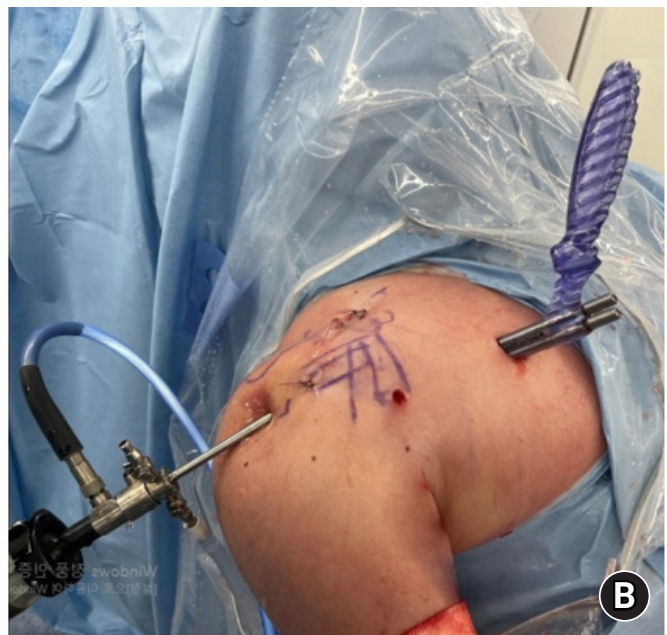
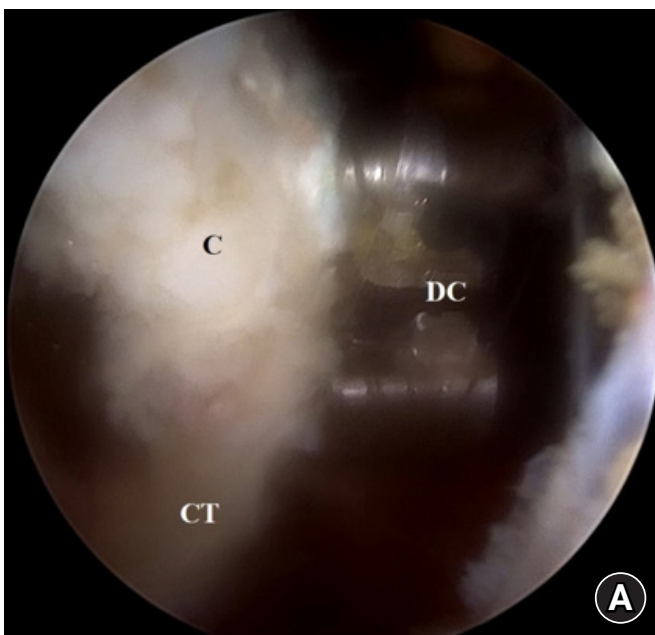


Fig. 5. The double cannula connected to the osteotomized coracoid process (viewing portal: inferior, working portal: medial, right shoulder). (A) The osteotomized coracoid process is connected by the double cannula for fixation to the anterior glenoid. (B) Extra-corporeal view of the double cannula. The coracoid process can be easily controlled using a double cannula inserted through the medial portal. C: coracoid process, DC: double cannula, CT: conjoined tendon.

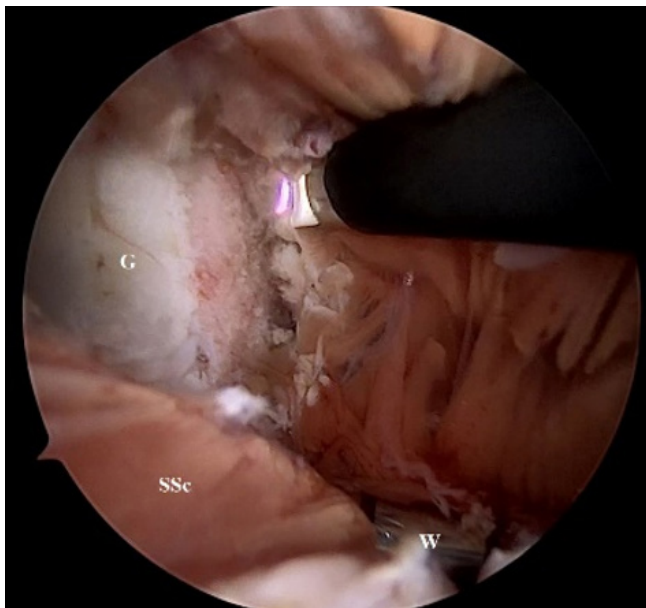


Fig. 6. Subscapularis muscle separation and anterior glenoid exposure (viewing portal: lateral, working portal: inferior, right shoulder). The subscapularis muscle was split using an electrocautery device, and a space was secured for the coracoid graft with a silastic drain and a Wissinger rod. G: glenoid, SSc: subscapularis muscle, W: Wissinger rod.

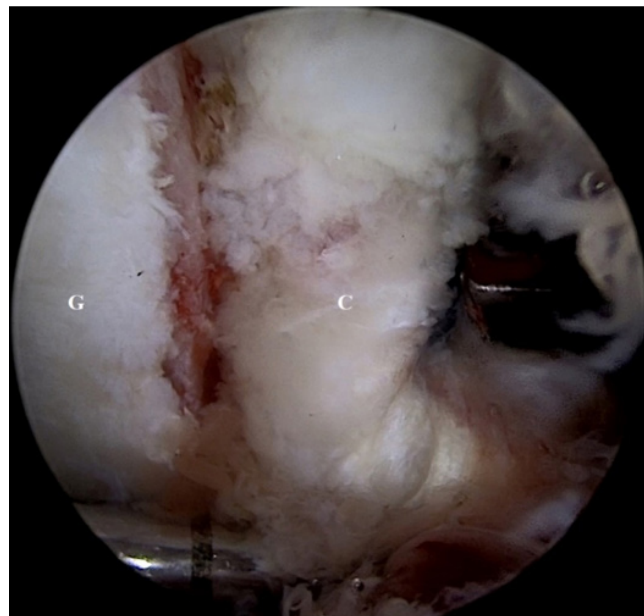


Fig. 7. Fixation of the coracoid process raft to anterior glenoid (viewing portal: lateral, working portal: medial, right shoulder). After inserting two guide pins, drill and insert the 3.5-mm cannulated screws. For proper compression, apply pressure alternately to the two upper and lower metal screws. The coracoid bone is fixed parallel to the glenoid surface. G: glenoid, C: coracoid process.

clamped outside the skin. This is to prevent the guide pin from pulling back during the removal of the cannulated drill. Once the guide pin is fixed, the coracoid screw is removed, and drilling is performed using a 3.2-mm cannulated drill bit through a double cannula. The length of the metal screw can be estimated by the depth of the drilling up to the posterior cortical bone. The 3.5-mm cannulated screw is inserted after drilling. After the two metal screws are partially inserted, insertion is completed by alternating compression of the two metal screws so that the coracoid graft can be properly compressed. Both the metal screw insertion and the glenoid and coracoid bone fixation status must be checked through the lateral portal (Fig. 7). This fixation assessment is to ensure that the fixation is parallel to the glenoid surface. After surgery, plain radiographs and computed tomography scans are used to confirm the location of the coracoid graft and the direction of the metal screw (Fig. 8).

DISCUSSION

Latarjet Procedure versus Bankart Repair

Recent studies comparing mid- to long-term clinical outcomes and complication rates of Bankart repair to the Latarjet procedure showed that the Latarjet procedure was equivalent or superior to Bankart repair. According to a meta-analysis by Imam et al. [18], which included 3,275 shoulder joints, the infection rate

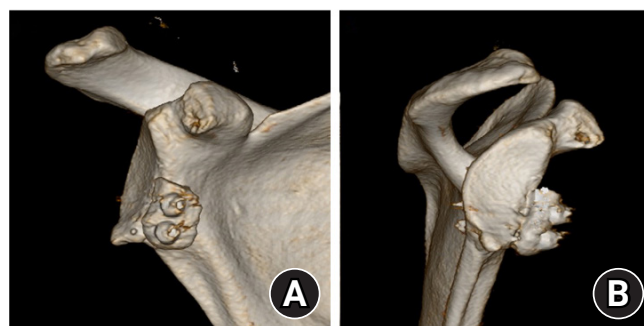


Fig. 8. Postoperative three-dimensional computed tomography after arthroscopic Latarjet procedure of right shoulder. (A) The transferred coracoid process forms proper congruency with the existing glenoid articular surface. (B) The coracoid process was well-fixed at the appropriate height in the enface view.

of patients who underwent the Latarjet procedure was higher than that of those undergoing Bankart repair. However, the risk of recurrence or reoperation rate was higher in the Bankart repair group as the follow-up period lengthened. In a long-term follow-up study of adolescent patients with recurrent anterior shoulder dislocation, Waltenspül et al. [19] found that the treatment failure and re-operation rates were significantly higher in the patients who underwent Bankart repair; however, there was no difference in the Constant scores and subjective shoulder values between the two groups. Ernstbrunner et al. [20] comparing patients with a mean age of 47 years reported that there were no

differences in subject shoulder values, glenohumeral arthritis grades at the final follow-up, and revision rates; but the rates of re-dislocation or subluxation were higher in the Bankart repair group. Rossi et al.'s study [21] of rugby players with less than 20% glenoid bone defects also found that the Latarjet procedure had lower recurrence and reoperation rates than Bankart repair despite no differences in the range of motion, Rowe scores, Athletic Shoulder Outcome Scoring System scores, and time of return to sports. Rodkey et al. [22] reported that the recurrence of instability was lower in the primary Latarjet group than with the Latarjet revision patients who failed after Bankart repair, emphasizing the importance of the Latarjet procedure as a primary surgery.

Comparison of Open versus Arthroscopic Latarjet Procedure

The biggest difference between open and arthroscopic Latarjet procedures is that in open surgery, the anterior joint capsule is reconstructed using the coracoacromial ligament. This is not true of the arthroscopic procedure. To compensate for this, one study reported good results by performing anterior capsular reconstruction using anchors in arthroscopic surgery [23]. In the results of biomechanical studies using cadavers to compare these differences, Schulze-Borges et al. [24] showed that the translation was significantly decreased in the abduction position in open surgery compared to the arthroscopic procedure. However, there was no difference between the two groups in the abduction-external rotation position. Kleiner et al. [25] reported that there was no difference in the translation of the shoulder joint regardless of reconstruction of the anterior capsule and that the range of external rotation movement decreased in the group that underwent anterior capsular reconstruction.

Clinical Outcomes of Arthroscopic Latarjet Procedure

Recently, many clinical trials have been reported to show satisfactory outcomes. Zhu et al. [23] reported that graft union was achieved in all 52 patients after an arthroscopic Latarjet procedure with anterior shoulder instability. Dumont et al. [26] also reported satisfactory clinical outcomes in a study with at least 5 years of follow-up. In addition, several prospective studies have reported equivalent clinical outcomes between arthroscopic and open Latarjet surgery, drawing more attention to its effectiveness [27-30]. Other studies comparing the clinical outcomes of arthroscopic and open Latarjet surgery have been reported recently (Table 1) [27-34]. Hurley et al. [31] compared clinical outcomes of 102 patients with an average of 51.3 months of follow-up and reported that there was no significant difference between open and arthroscopic surgery. Ali et al. [32] observed 48 patients with open and arthroscopic Latarjet surgery for an average of 30.5

months and compared the range of motion, strength, visual analog scale (VAS) scores, Rowe scores, and Western Ontario Shoulder Instability (WOSI) scores. Postoperative computed tomography was used to evaluate the Gerber index, Sugaya index, and superior-inferior position of the graft bone, as well as screw angle with glenoid surface in axial images (a-angle). Graft resorption and glenohumeral arthritis grade at final follow-up were also evaluated. These researchers reported that internal rotation was significantly reduced, the WOSI score was higher at final follow-up, and the screw tended to be angulated more medially in the arthroscopic Latarjet group. In a prospective study that analyzed 184 patients, Nourissat et al. [29] compared postoperative pain and WOSI scores and reported less pain on postoperative days 3 and 7 and better WOSI scores at 3 months postoperatively in the arthroscopic group. Marion et al. [27] evaluated VAS scores in the first week after surgery, the position of the graft using computed tomography in the third month after surgery, and WOSI scores in 58 patients. This group observed that patients had less pain in the first week after the surgery and a better equatorial position in arthroscopic surgery; there were no significant difference in the WOSI scores between the two groups. Zhu et al. [30] examined 44 patients with open surgery and 46 patients with arthroscopic surgery for at least 2 years of follow-up and evaluated the shoulder function and 1-year postoperative graft resorption. In that study, the coracoid graft was in a more proper superior-inferior position in open surgery, but there were no significant differences in other measures. Graft resorption occurred to a lesser extent in arthroscopic surgery, which may be accounted for by the maintenance of soft tissue and blood supply around the coracoid process.

Complications of Arthroscopic Latarjet Procedure

A systematic review of 89 clinical papers, including 7,175 patients, demonstrated that the short-term complication rate of the arthroscopic Latarjet procedure was 6.8%, which was not significantly different from the 6.1% complication rate of open surgery [35]. As for the types of complications, 3.2% of graft-related complications were coracoid fractures or non-unions, 1.9% were implant-related problems, 0.7% were neurological complications, 0.5% were infections, and 0.5% were other complications. However, while the graft-related complication was mainly non-union after the open surgery, arthroscopic surgery was performed mainly due to the fracture of the coracoid graft. This may be due to the technical difficulties of arthroscopic surgery. In a study on the learning curve of the arthroscopic method reported by Kordasiewicz et al. [34], complications such as graft fracture appeared at the beginning of the learning curve. In a systematic re-

Table 1. Studies comparing open vs. arthroscopic Latarjet procedures

Study	Study design	Sample size		Mean age (yr)	Follow-up (mo)	Clinical outcome (Arthro:Open)	Complication (%)		Recurrence (%)	
		Arthro	Open				(Arthro:Open)	Arthro	Open	
Cunningham et al. (2016) [33]	Retrospective	28	36	26±7.6	6.6±5.9	Walch-Duplay score (88:91)	Intraop (0:0) Postop (29:11)	3.6	0	
Metais et al. (2016) [28]	Prospective	286	104	22.7±4.1	22.7±4.1	Walch Duplay score (92.8:85.9) Rowe score (93.4:83.9) VAS score (1.2:1.6)	Intraop (1.4:3.9) Postop (12.5:8.4) NA	4.1	1.0	
Nourissat et al. (2016) [29]	Prospective	99	85	Not specified	Not specified	Symptom WOSI score (13%:18%) Sports/recreation/work WOSI score (15%:24%)	NA	NA	NA	
Marion et al. (2017) [27]	Prospective	36	22	26.9±7.7	29.8±4.4	VAS score (1.2:2.5) WOSI score (372.1:451) ASES score (93.3:93.0) Constant score (96.5:95.0)	Intraop (0:0) Postop (5.6:0) No complications	2.8	0	
Zhu et al. (2017) [30]	Prospective	44	46	30.1	28.8	Rowe score (97.1:95.4) Walch-Duplay score (92.8:85.9) Rowe score (78.9:87.8) VAS score (1.38:0.77)	NA	NA	NA	
Kordasiewicz et al. (2019) [34]	Retrospective	62	48	26.9	36.8	Patient's satisfaction (91.9%:96.8%) Residual apprehension (31%:28.7%) WOSI score (448:670) VAS score (1.2:5)	Postop (15:20)	3.0	13.3	
Ali et al. (2020) [32]	Retrospective	33	15	29.5	30.5	Rowe score (80:78) WOSI score (27.1%:24.9%) VAS score (1.3:1)	Overall (6.7:11.1)	6.7	6.9	
Hurley et al. (2021) [31]	Retrospective	30	72	30.6	51.6	VAS during sports (2.2:1.5) SSV score (75.7:74.1) SIRSI score (66.7:67) Patient's satisfaction (85.6:88.3)				

Arthro: arthroscopic Latarjet procedure, Intraop: intraoperative, Postop: postoperative, VAS: visual analog scale, NA: not available, WOSI: Western Ontario Shoulder Instability, ASES: American Shoulder and Elbow Surgeons, SSV: subjective shoulder value, SIRSI: shoulder instability-return to sport after injury.

view of 35 clinical papers, Cho et al. [36] analyzed the complications of the Latarjet procedure by categorizing them as intraoperative, postoperative, and instability-related. Intraoperative complications such as graft fractures were higher for the arthroscopic procedure, while instability-related complications were higher for open surgery.

CONCLUSIONS

The arthroscopic Latarjet procedure is a surgical method with several advantages and can result in equivalent levels of patient shoulder function and complication rates compared with open surgery. However, since the Latarjet arthroscopic techniques compared to general arthroscopic techniques are relatively difficult and the learning curves are slow, surgery should be performed by surgeons with advanced anatomical knowledge and abundant experience.

NOTES

ORCID

Sang-Jin Shin <https://orcid.org/0000-0003-0215-2860>
 Jae Hyung Kim <https://orcid.org/0000-0003-3455-8689>
 Jonghyun Ahn <https://orcid.org/0000-0002-0624-0502>

Author contributions

Conceptualization: SJS. Data curation: JHK. Formal analysis: JHK, JA. Investigation: SJS, JHK, JA. Project administration: JHK, JA. Supervision: SJS. Validation: SJS, JA. Writing—original draft: JHK. Writing—review & editing: SJS, JHK.

Conflict of interest

None.

Funding

None.

Data availability

None.

Acknowledgments

None.

REFERENCES

1. Provencher MT, Bhatia S, Ghodadra NS, et al. Recurrent shoulder instability: current concepts for evaluation and management of glenoid bone loss. *J Bone Joint Surg Am* 2010;92 Suppl 2:133–51.
2. Bishop JY, Hidden KA, Jones GL, Hettrich CM, Wolf BR; MOON Shoulder Group. Factors influencing surgeon's choice of procedure for anterior shoulder instability: a multicenter prospective cohort study. *Arthroscopy* 2019;35:2014–25.
3. Wong SE, Friedman LG, Garrigues GE. Arthroscopic Latarjet: indications, techniques, and results. *Arthroscopy* 2020;36:2044–6.
4. Arrigoni P, Huberty D, Brady PC, Weber IC, Burkhart SS. The value of arthroscopy before an open modified Latarjet reconstruction. *Arthroscopy* 2008;24:514–9.
5. Boileau P, Richou J, Lisai A, Chuinard C, Bicknell RT. The role of arthroscopy in revision of failed open anterior stabilization of the shoulder. *Arthroscopy* 2009;25:1075–84.
6. Lafosse L, Lejeune E, Bouchard A, Kakuda C, Gobezie R, Kochhar T. The arthroscopic Latarjet procedure for the treatment of anterior shoulder instability. *Arthroscopy* 2007;23:1242.
7. Yang JS, Mehran N, Mazzocca AD, Pearl ML, Chen VW, Arciero RA. Remplissage versus modified Latarjet for off-track Hill-Sachs lesions with subcritical glenoid bone loss. *Am J Sports Med* 2018;46:1885–91.
8. Hardy A, Loriaut P, Granger B, et al. Reliability of a CT reconstruction for preoperative surgical planning in the arthroscopic Latarjet procedure. *Knee Surg Sports Traumatol Arthrosc* 2018;26:40–7.
9. Hardy A, Gerometta A, Granger B, et al. Preoperative CT planning of screw length in arthroscopic Latarjet. *Knee Surg Sports Traumatol Arthrosc* 2018;26:24–30.
10. Boileau P, Gendre P, Baba M, et al. A guided surgical approach and novel fixation method for arthroscopic Latarjet. *J Shoulder Elbow Surg* 2016;25:78–89.
11. Boileau P, Saliken D, Gendre P, et al. Arthroscopic Latarjet: suture-button fixation is a safe and reliable alternative to screw fixation. *Arthroscopy* 2019;35:1050–61.
12. Xu J, Liu H, Lu W, et al. Modified arthroscopic Latarjet procedure: suture-button fixation achieves excellent remodeling at 3-year follow-up. *Am J Sports Med* 2020;48:39–47.
13. Castricini R, Taverna E, Guarrella V, De Benedetto M, Galasso O. Arthroscopic Latarjet procedure: a technique using double round ENDOBUTTONs and specific glenoid and coracoid guides. *Arthrosc Tech* 2020;9:e995–1001.
14. Provencher MT, Aman ZS, LaPrade CM, et al. Biomechanical comparison of screw fixation versus a cortical button and self-tensioning suture for the Latarjet procedure. *Orthop J Sports Med* 2018;6:2325967118777842.
15. Williams RC, Morris RP, El Beaino M, Maassen NH. Cortical

- suture button fixation vs. bicortical screw fixation in the Latarjet procedure: a biomechanical comparison. *J Shoulder Elbow Surg* 2020;29:1470–8.
16. Hardy A, Sabatier V, Schoch B, Vigan M, Werthel JD; Study Investigators. Latarjet with cortical button fixation is associated with an increase of the risk of recurrent dislocation compared to screw fixation. *Knee Surg Sports Traumatol Arthrosc* 2020; 28:2354–60.
 17. Shin SJ, Park I, Lee SH, Kim IW, Kim MS. The art of shoulder arthroscopy. *Panmun educations*; 2022.
 18. Imam MA, Shehata MS, Martin A, et al. Bankart repair versus Latarjet procedure for recurrent anterior shoulder instability: a systematic review and meta-analysis of 3275 shoulders. *Am J Sports Med* 2021;49:1945–53.
 19. Waltenspül M, Ernstbrunner L, Ackermann J, Thiel K, Galvin JW, Wieser K. Long-term results and failure analysis of the open Latarjet procedure and arthroscopic Bankart repair in adolescents. *J Bone Joint Surg Am* 2022;104:1046–54.
 20. Ernstbrunner L, De Nard B, Olthof M, et al. Long-term results of the arthroscopic Bankart repair for recurrent anterior shoulder instability in patients older than 40 years: a comparison with the open Latarjet procedure. *Am J Sports Med* 2020;48: 2090–6.
 21. Rossi LA, Tanoira I, Gorodischer T, Pasqualini I, Ranalletta M. Recurrence and revision rates with arthroscopic Bankart repair compared with the Latarjet procedure in competitive rugby players with glenohumeral instability and a glenoid bone loss < 20. *Am J Sports Med* 2021;49:866–72.
 22. Rodkey DL, Colantonio DF, LeClere LE, Kilcoyne KG, Dickens JF. Latarjet after failed arthroscopic Bankart repair results in twice the rate of recurrent instability compared with primary Latarjet. *Arthroscopy* 2021;37:3248–52.
 23. Zhu YM, Jiang C, Song G, Lu Y, Li F. Arthroscopic Latarjet procedure with anterior capsular reconstruction: clinical outcome and radiologic evaluation with a minimum 2-year follow-up. *Arthroscopy* 2017;33:2128–35.
 24. Schulze-Borges J, Agneskirchner JD, Bobrowitsch E, et al. Biomechanical comparison of open and arthroscopic Latarjet procedures. *Arthroscopy* 2013;29:630–7.
 25. Kleiner MT, Payne WB, McGarry MH, Tibone JE, Lee TQ. Biomechanical comparison of the Latarjet procedure with and without capsular repair. *Clin Orthop Surg* 2016;8:84–91.
 26. Dumont GD, Fogerty S, Rosso C, Lafosse L. The arthroscopic Latarjet procedure for anterior shoulder instability: 5-year minimum follow-up. *Am J Sports Med* 2014;42:2560–6.
 27. Marion B, Klouche S, Deranlot J, Bauer T, Nourissat G, Hardy P. A prospective comparative study of arthroscopic versus mini-open Latarjet procedure with a minimum 2-year follow-up. *Arthroscopy* 2017;33:269–77.
 28. Metais P, Clavert P, Barth J, et al. Preliminary clinical outcomes of Latarjet-Patte coracoid transfer by arthroscopy vs. open surgery: prospective multicentre study of 390 cases. *Orthop Traumatol Surg Res* 2016;102(8S):S271–6.
 29. Nourissat G, Neyton L, Metais P, et al. Functional outcomes after open versus arthroscopic Latarjet procedure: a prospective comparative study. *Orthop Traumatol Surg Res* 2016;102(8S): S277–9.
 30. Zhu Y, Jiang C, Song G. Arthroscopic versus open Latarjet in the treatment of recurrent anterior shoulder dislocation with marked glenoid bone loss: a prospective comparative study. *Am J Sports Med* 2017;45:1645–53.
 31. Hurley ET, Ben Ari E, Lorentz NA, et al. Both open and arthroscopic Latarjet result in excellent outcomes and low recurrence rates for anterior shoulder instability. *Arthrosc Sports Med Rehabil* 2021;3:e1955–60.
 32. Ali J, Altintas B, Pulatkan A, Boykin RE, Aksoy DO, Bilsel K. Open versus arthroscopic Latarjet procedure for the treatment of chronic anterior glenohumeral instability with glenoid bone loss. *Arthroscopy* 2020;36:940–9.
 33. Cunningham G, Benchouk S, Kherad O, Lädermann A. Comparison of arthroscopic and open Latarjet with a learning curve analysis. *Knee Surg Sports Traumatol Arthrosc* 2016;24:540–5.
 34. Kordasiewicz B, Kiciński M, Małachowski K, Boszczyk A, Chaberek S, Pomianowski S. Arthroscopic Latarjet stabilization: analysis of the learning curve in the first 90 primary cases: early clinical results and computed tomography evaluation. *Arthroscopy* 2019;35:3221–37.
 35. Hurley ET, Schwartz LB, Mojica ES, et al. Short-term complications of the Latarjet procedure: a systematic review. *J Shoulder Elbow Surg* 2021;30:1693–9.
 36. Cho CH, Na SS, Choi BC, Kim DH. Complications related to Latarjet shoulder stabilization: a systematic review. *Am J Sports Med* 2023;51:263–70.