

## Case Report

Clin Shoulder Elbow 2023;26(3):302-305  
<https://doi.org/10.5397/cise.2022.00794>

eISSN 2288-8721

# Transient postoperative inferior subluxation of the shoulder after surgical stabilization of recurrent anterior dislocation in a patient with myasthenia gravis: a case report

Samuel Baek<sup>1</sup>, Geum-Ho Lee<sup>1</sup>, Myung Ho Shin<sup>2</sup>, Tae Min Kim<sup>3</sup>, Kyung-Soo Oh<sup>4</sup>, Seok Won Chung<sup>4</sup>

<sup>1</sup>Department of Orthopaedic Surgery, Seoul Red Cross Hospital, Seoul, Korea

<sup>2</sup>Department of Orthopaedic Surgery, CM Hospital, Seoul, Korea

<sup>3</sup>Department of Orthopaedic Surgery, Seoul Prime Hospital, Seoul, Korea

<sup>4</sup>Department of Orthopaedic Surgery, Konkuk University School of Medicine, Seoul, Korea

The authors present a case of transient postoperative inferior subluxation of the shoulder after arthroscopic surgical stabilization for recurrent anterior dislocation. The patient was a 61-year-old woman with myasthenia gravis (MG). The first anterior shoulder dislocation occurred because of a fall to the ground. Despite a successful closed reduction, two more dislocations occurred in 3 weeks. Magnetic resonance imaging revealed an anterior labroligamentous periosteal sleeve avulsion (ALPSA) lesion, an engaging Hill-Sachs lesion, and large tears of the supraspinatus and infraspinatus tendons. The patient underwent arthroscopic rotator cuff repair and ALPSA repair with a remplissage procedure. Intraoperatively, no tendency for instability was found; however, a widened glenohumeral joint space and inferior subluxation of the humeral head without functional compromise was observed on the day after surgery and disappeared spontaneously on radiographs 2 weeks later. To the authors' knowledge, this is the first report documenting the occurrence of transient postoperative inferior subluxation of the shoulder in a patient with MG.

**Keywords:** Shoulder dislocation; Rotator cuff injuries; Myasthenia gravis; Joint subluxation; Conservative treatment

Myasthenia gravis (MG) is a B-cell mediated autoimmune disease with dominant features of muscle weakness and fatigue that is characterized by low muscle tone (hypotonia) [1]. Murotani et al. [2] reported that patients with neuromuscular diseases, including MG, have a potential risk of muscle weakness in the operated limb and experience fatigability and joint hyperlaxity in the course of disease progression. Regarding postoperative joint instability in the elbow joint, 17% of patients who underwent a surgical stabilization procedure for elbow dislocation showed a postoperative widening of the ulnohumeral space on radio-

graphs. However, to the authors' knowledge, there have been no reports on postoperative shoulder joint laxity in MG. Here, a patient is presented who experienced transient postoperative inferior subluxation of the shoulder after surgical stabilization of recurrent anterior dislocation, and who had an 18-year history of MG. The patient was successfully treated without additional procedures. Diagnostic and therapeutic perspectives and a review of the relevant literature are presented here.

Received: January 19, 2022    Revised: March 10, 2022    Accepted: March 18, 2022

Correspondence to: Seok Won Chung

Department of Orthopaedic Surgery, Center for Shoulder and Elbow Surgery, Konkuk University School of Medicine, 120-1 Neungdong-ro, Gwangjin-gu, Seoul 05030, Korea

Tel: +82-2-2030-7604, Fax: +82-2-2030-7748, E-mail: smilecsw@gmail.com, ORCID: <https://orcid.org/0000-0002-8221-9289>

Copyright© 2023 Korean Shoulder and Elbow Society.

This is an Open Access article distributed under the terms of the Creative Commons Attribution Non-Commercial License (<http://creativecommons.org/licenses/by-nc/4.0/>) which permits unrestricted non-commercial use, distribution, and reproduction in any medium, provided the original work is properly cited.

## CASE REPORT

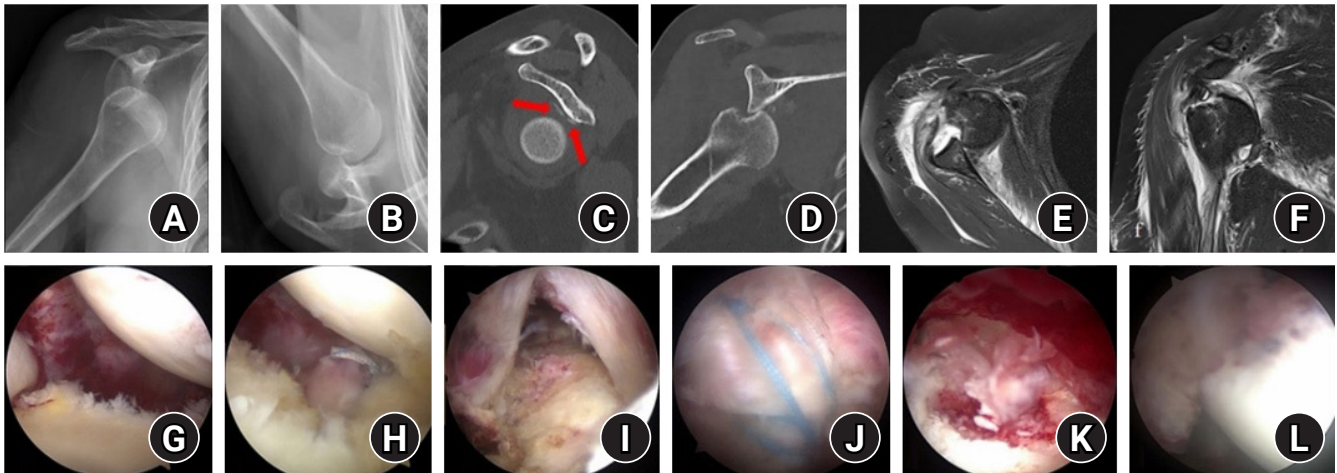
Approval for this study was waived by the Institutional Review Board (No. KUMC2021-01-001), and written informed consent was obtained from all patients.

A 61-year-old woman had fallen on level ground and complained of pain in her right shoulder. She was diagnosed with an anterior shoulder dislocation on radiographs and was treated with closed reduction followed by brace immobilization. Eighteen years prior, she had been diagnosed with MG and had undergone thymectomy 17 years prior. She presented with two more apparently spontaneous anterior dislocations at 13 days and 3 weeks after the initial dislocation.

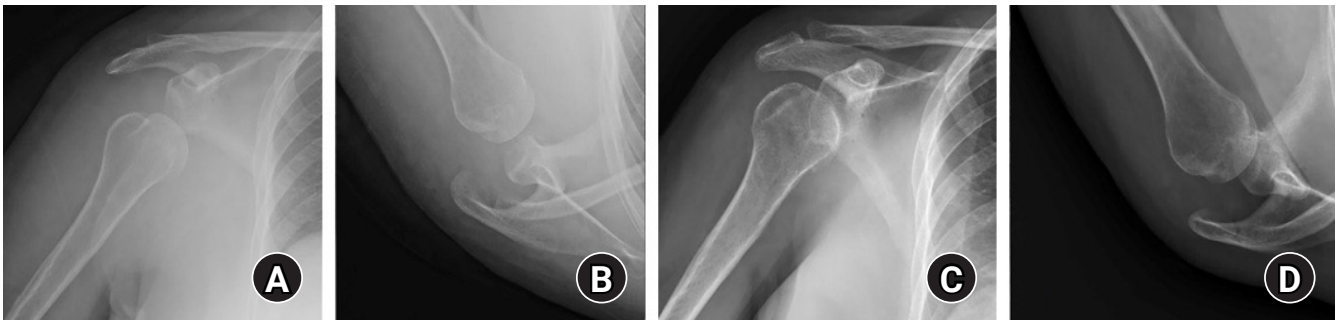
After the third dislocation, radiographs showed a locked anterior dislocation (Fig. 1A and B). Computed tomography revealed

an engaging Hill-Sachs lesion (Fig. 1C and D). Magnetic resonance imaging (MRI) revealed not only an anterior labroligamentous periosteal sleeve avulsion (ALPSA) lesion but also large tears of the supraspinatus and infraspinatus muscles (Fig. 1E and F). Arthroscopic rotator cuff repair and ALPSA repair with capsule-myo-tenodesis (remplissage) were performed (Fig. 1G-L).

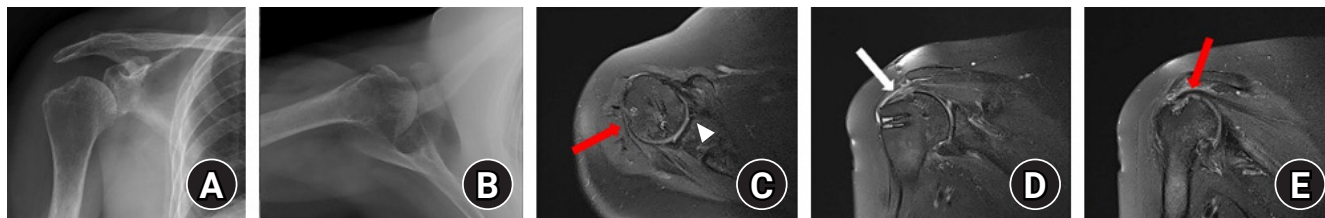
Increased glenohumeral joint space and prominent inferior subluxation of the humeral head were observed on radiographs taken one day after surgery and disappeared spontaneously in 2 weeks without restabilization (Fig. 2). At 6 weeks postoperatively, the abduction brace was discontinued and passive exercise was initiated. Six months postoperatively, a concentric glenohumeral joint was acquired on radiographs. The MRI showed a well-maintained anteroinferior capsulolabral complex with intact structural integrity of the repaired rotator cuff (Fig. 3). In addi-



**Fig. 1.** Anteroposterior (A) and axial (B) radiographs demonstrating a locked anterior glenohumeral joint dislocation. Sagittal (C) and coronal (D) computed tomography images demonstrating a large engaging Hill-Sachs lesion with periosteal avulsion of the anteroinferior glenoid rim (red arrows). T2 axial (E) and coronal (F) magnetic resonance imaging demonstrating an anterior labroligamentous periosteal sleeve avulsion (ALPSA) lesion with posterosuperior rotator cuff tear; friable anterior capsule and labral tissue (G). ALPSA repair (H). Crescent-shaped rotator cuff tear (I). Rotator cuff repair using the suture bridge technique (J). Large Hill-Sachs lesion (K). Remplissage procedure (L).



**Fig. 2.** Anteroposterior (A) and axial (B) radiographs taken 1 day after operation and demonstrating increased glenohumeral joint space and prominent inferior subluxation of the humeral head. Anteroposterior (C) and axial (D) radiographs taken 2 weeks after operation and demonstrating disappearance of the postoperative inferior subluxation.



**Fig. 3.** Anteroposterior (A) and axial (B) radiographs taken 6 months postoperatively and demonstrating the concentric glenohumeral joint without subluxation. T2 axial (C) and T2 coronal (D, E) magnetic resonance imaging demonstrating a well-maintained anteroinferior capsulolabral complex (white arrowhead) with intact structural integrity of repaired rotator cuff (white arrow) and healing of the remplissage (red arrows).

tion, all the functional scores showed excellent results with the University of California, Los Angeles score of 35 points, simple shoulder test score of 12 points, American Shoulder and Elbow Surgeons Shoulder Score of 95 points, and Constant-Murley score of 89 points. The forward flexion was 150°, external rotation at the side was 30°, and internal rotation was at the twelfth thoracic vertebral level. The patient had no discomfort, instability, or apprehension and no limitation of daily activities. No dislocation events occurred after surgery.

## DISCUSSION

Postoperative inferior subluxation of the shoulder joint may be caused by atony of the deltoid and rotator cuff muscles, loosened ligaments, and the loss of negative intraarticular pressure after surgery [3]. Previously, Khanna [4] suggested that retraction of the muscle belly during surgery may be a causative factor for deltoid atony without any nerve injury. Also, shortening of the humeral neck caused by a fracture of the proximal humerus may be the cause of deltoid atony [5]. Postoperative joint laxity is more frequently reported in elbow joints. Coonrad et al. [6] reported that the postoperative widening of the ulnohumeral joint space, named as a drop sign, occurred at an incidence of 17% to 90% after reduction of elbow dislocation, suggesting that the decreased ulnohumeral joint compression force due to decreased elbow muscle tone after reduction might be a reason [7].

MG is the largest disease group of neuromuscular junction disorders, which are caused by the binding of pathogenic autoantibodies to components in the postsynaptic muscle endplate, most commonly the acetylcholine receptor [8]. Muscle weakness, fatigability, and joint hyperlaxity are the most prominent symptoms of MG. Given these common symptoms, the possibility of postoperative subluxation may be higher in patients with MG. In particular, the shoulder joint is the most mobile joint, with a small glenoid compared to the humeral head, and the effect of the dynamic stabilizer, namely, the muscles around the shoulder

joint, is much higher than that of other joints. Thus, the loss of muscle tone in the shoulder joint may more easily cause joint laxity and resultant inferior shoulder subluxation.

Reports regarding the relationship between MG and postoperative joint laxity are limited. Murotani et al. [2] documented that myasthenic muscle weakness after total hip arthroplasty led to excessive passive motion due to hip joint hyperlaxity, increasing the risk of dislocation by excessive movement beyond the physiologic range of motion. Özkazanlı et al. [9] reported a case of recurrent anterior hip dislocation with MG that was treated with open reduction and capsular plication. For the shoulder joint, Sliwoń [10] reported a bilateral traumatic subluxation of the shoulder joint in a patient with MG, whereas Pritchett [3] reported an inferior subluxation of a prosthetic humeral head in patients with neuromuscular disorders of poliomyelitis, brachial plexus injury, and neuralgic amyotrophy. However, to the authors' knowledge, there has been no report documenting postoperative inferior shoulder subluxation related to MG.

This case report is the first to describe a transient postoperative inferior subluxation of the shoulder in a patient with MG. The subluxation in this case did not require restabilization and was not associated with poor postoperative functional outcomes; these findings are consistent with those of previous reports of postoperative elbow joint laxity [7]. Thus, surgeons should not be concerned regarding the detection of postoperative inferior subluxation of the shoulder joint on radiographs taken during the early postoperative period, and further diagnostic or treatment approaches may be unnecessary, even in patients with MG. In the present case the reduced muscle tone after surgery recovered within 2 weeks, with spontaneous stabilization of the shoulder joint achieved even in MG.

## NOTES

### ORCID

Samuel Baek

<https://orcid.org/0000-0001-9904-1184>

Geum-Ho Lee <https://orcid.org/0000-0001-7775-3017>  
 Myung Ho Shin <https://orcid.org/0000-0002-2134-6946>  
 Tae Min Kim <https://orcid.org/0000-0002-3977-536X>  
 Kyung-Soo Oh <https://orcid.org/0000-0002-9812-9130>  
 Seok Won Chung <https://orcid.org/0000-0002-8221-9289>

### Author contributions

Conceptualization: SB, MHS, TMK, SWC. Data curation: GHL, MHS, TMK. Writing – original draft: SB, SWC. Writing – review & editing: SB, KSO, SWC.

### Conflict of interest

None.

### Funding

None.

### Data availability

None.

### Acknowledgments

None.

## REFERENCES

1. Gilhus NE, Verschuuren JJ. Myasthenia gravis: subgroup classification and therapeutic strategies. *Lancet Neurol* 2015;14:1023-36.
2. Murotani Y, Kuroda Y, Goto K, Kawai T, Matsuda S. Unexpected dislocation following accurate total hip arthroplasty caused by excessive hip joint laxity during myasthenic crisis: a case report. *J Med Case Rep* 2018;12:331.
3. Pritchett JW. Inferior subluxation of the humeral head after trauma or surgery. *J Shoulder Elbow Surg* 1997;6:356-9.
4. Khanna V. Post-surgical transitory inferior subluxation of shoulder. *Bull Emerg Trauma* 2018;6:379-80.
5. Moon JG, Nam HW, Kim JO, Ha JK, Ryu SB. Inferior subluxation of humeral of head after surgery for fracture of proximal humerus. *J Korean Fract Soc* 2005;18:43-7.
6. Coonrad RW, Roush TF, Major NM, Basamania CJ. The drop sign, a radiographic warning sign of elbow instability. *J Shoulder Elbow Surg* 2005;14:312-7.
7. Rhyou IH, Lim KS, Kim KC, Lee JH, Ahn KB, Moon SC. Drop sign of the elbow joint after surgical stabilization of an unstable simple posterolateral dislocation: natural course and contributing factors. *J Shoulder Elbow Surg* 2015;24:1081-9.
8. Sanders DB, Wolfe GI, Benatar M, et al. International consensus guidance for management of myasthenia gravis: executive summary. *Neurology* 2016;87:419-25.
9. Özkazanlı G, Karaman Ö, Beng K, Muratlı HH. Recurrent anterior hip dislocation in a patient with myasthenia gravis: a case report. *Acta Orthop Traumatol Turc* 2015;49:106-10.
10. Sliwoń A. Bilateral traumatic luxation of shoulder joints in the course of myasthenia gravis. *Wiad Lek* 1969;22:59-62.