

# Pathologic conditions associated with impacted third molars: A retrospective study of panoramic radiographs in a Southern Brazilian population

Gabriela Brum Cardoso<sup>1</sup>, Gleica Dal' Ongaro Savegnago<sup>1</sup>, Wâneza Dias Borges Hirsch<sup>2</sup>, Mariana Boessio Vizzotto<sup>3</sup>, Gabriela Salatino Liedke<sup>2,\*</sup>

<sup>1</sup>Dental Sciences Post-Graduation Program, Federal University of Santa Maria, Santa Maria, Brazil

<sup>2</sup>Department of Stomatology, Federal University of Santa Maria, Santa Maria, Brazil

<sup>3</sup>Department of Surgery and Orthopedics, Federal University of Rio Grande do Sul, Porto Alegre, Brazil

## ABSTRACT

**Purpose:** This study investigated the prevalence of developmental and acquired pathologic conditions associated with impacted third molars (3Ms) in a Southern Brazilian population and evaluated whether demographic and tooth characteristics were correlated with the presence of bone or tooth lesions.

**Materials and Methods:** Panoramic radiographs were assessed for developmental (bone-related) or acquired (tooth-related) pathoses associated with impacted upper or lower 3Ms. Data on tooth positioning, tooth development, and patient demographics were collected. A trained, calibrated postgraduate student evaluated all images. Binary and multivariate logistic regression models were used to assess associations between outcomes and the demographic and radiographic variables. The threshold for statistical significance was set at 5% ( $P < 0.05$ ).

**Results:** The sample comprised panoramic radiographs from 2054 patients, predominantly female (59.2%), with a mean age of  $27.2 \pm 11.5$  years. Overall, 4066 impacted 3Ms were evaluated, revealing 471 (11.6%) developmental and 710 (17.5%) acquired pathoses. Among the developmental pathoses, 460 (95.2%) were indicative of dentigerous cysts. Male sex, lower 3M location, vertical or distoangular positioning, and incomplete root formation were associated with an elevated likelihood of developmental pathology. Lower tooth position, complete root formation, and partial eruption were linked to an increased probability of an acquired pathology in the third or second molar.

**Conclusion:** The prevalence of pathologic conditions associated with impacted 3Ms was low. Male sex, lower 3M placement, horizontal or distoangular positioning, and incomplete root formation were associated with developmental pathoses, while lower tooth position, complete root formation, and partial eruption were related to acquired pathoses. (*Imaging Sci Dent* 2023; 53: 303-12)

**KEY WORDS:** Molar, Third; Tooth, Impacted; Tooth, Extraction; Radiography, Panoramic

## Introduction

The third molar (3M) is the most frequently impacted tooth, with a global average impaction rate of 24%.<sup>1</sup> The extraction of impacted 3Ms is one of the most frequently performed procedures in maxillofacial surgery and has been extensively researched by dental professionals.<sup>2</sup> The

prophylactic removal of impacted 3Ms is typically justified by the risk of developing pathological conditions, potential hazards to the second molars (2Ms), crowding of the lower anterior teeth, or relapse after orthodontic treatment, or simply because extraction is less complex at younger ages.<sup>3-5</sup> However, recent evidence, based on biological, financial, and quality-of-life parameters, suggests and supports the notion that not all asymptomatic impacted 3Ms require extraction. Instead, treatment should be determined based on signs and symptoms.<sup>6-9</sup>

Although asymptomatic impacted 3Ms may potentially lead to pathological conditions,<sup>3</sup> the low rates of such

Received February 13, 2023; Revised June 27, 2023; Accepted July 14, 2023  
Published online September 4, 2023

\*Correspondence to : Prof. Gabriela Salatino Liedke

Division of Oral Radiology, Department of Stomatology, Santa Maria Federal University, Av. Roraima no 1000, 26F-2111, 97105-900, Santa Maria-RS, Brazil  
(Tel) 55-55-3220-9270, E-mail) gabriela.liedke@ufsm.br

Copyright © 2023 by Korean Academy of Oral and Maxillofacial Radiology

This is an Open Access article distributed under the terms of the Creative Commons Attribution Non-Commercial License (<http://creativecommons.org/licenses/by-nc/3.0>) which permits unrestricted non-commercial use, distribution, and reproduction in any medium, provided the original work is properly cited.

Imaging Science in Dentistry · pISSN 2233-7822 eISSN 2233-7830

conditions observed on panoramic radiographs do not sufficiently justify the prophylactic removal of impacted 3Ms.<sup>6,10-13</sup> According to the American Association of Oral and Maxillofacial Surgeons,<sup>14</sup> teeth without treatable clinical conditions that are affected by dental caries, periapical lesions, pericoronitis, or alveolar bone resorption, as well as those adjacent to bone pathologies, are among the indications for the extraction of impacted 3Ms. Furthermore, impacted 3Ms that are associated with or cause pathological conditions in the 2Ms may also warrant surgical intervention.<sup>14</sup> A study conducted in Brazil revealed that relatively inexperienced maxillofacial surgeons tend to recommend more extractions of impacted 3Ms compared to their counterparts with over 8 years of experience, who generally prefer to monitor asymptomatic impacted 3Ms.<sup>2</sup>

Panoramic radiography is the most commonly utilized imaging technique in the evaluation of impacted 3Ms due to its widespread availability, simplicity of execution, affordability, and relatively low radiation dose.<sup>15</sup> Despite the potential for overlap and distortion of structures,<sup>16</sup> panoramic radiography remains the recommended examination for assessing impacted 3Ms.<sup>17,18</sup> In instances where a more comprehensive investigation of the positioning of impacted teeth is required, cone-beam computed tomography (CBCT) may be indicated.<sup>19</sup> However, research has suggested that CBCT does not decrease the risks of intraoperative complications associated with the extraction of impacted 3Ms, and it also carries a greater cost and exposes the patient to a higher radiation dose.<sup>20</sup> Therefore, the use of CBCT should be restricted to cases in which panoramic radiographs would not provide sufficient information for patient assessment in diagnosis and treatment planning.<sup>21</sup>

The literature still lacks consensus on the optimal management of clinically asymptomatic impacted 3Ms without radiographic pathoses.<sup>22-25</sup> Additionally, it is clear that panoramic radiographs are crucial in evaluating impacted 3Ms, particularly in relation to postoperative outcomes.<sup>26,27</sup> Therefore, this study was conducted to determine the prevalence of developmental and acquired pathological conditions associated with impacted 3Ms in a sample from southern Brazil. It was also intended to assess whether demographic factors and tooth characteristics are correlated with the presence of bone or tooth lesions. This information could assist dentists in the decision-making process.

## Materials and Methods

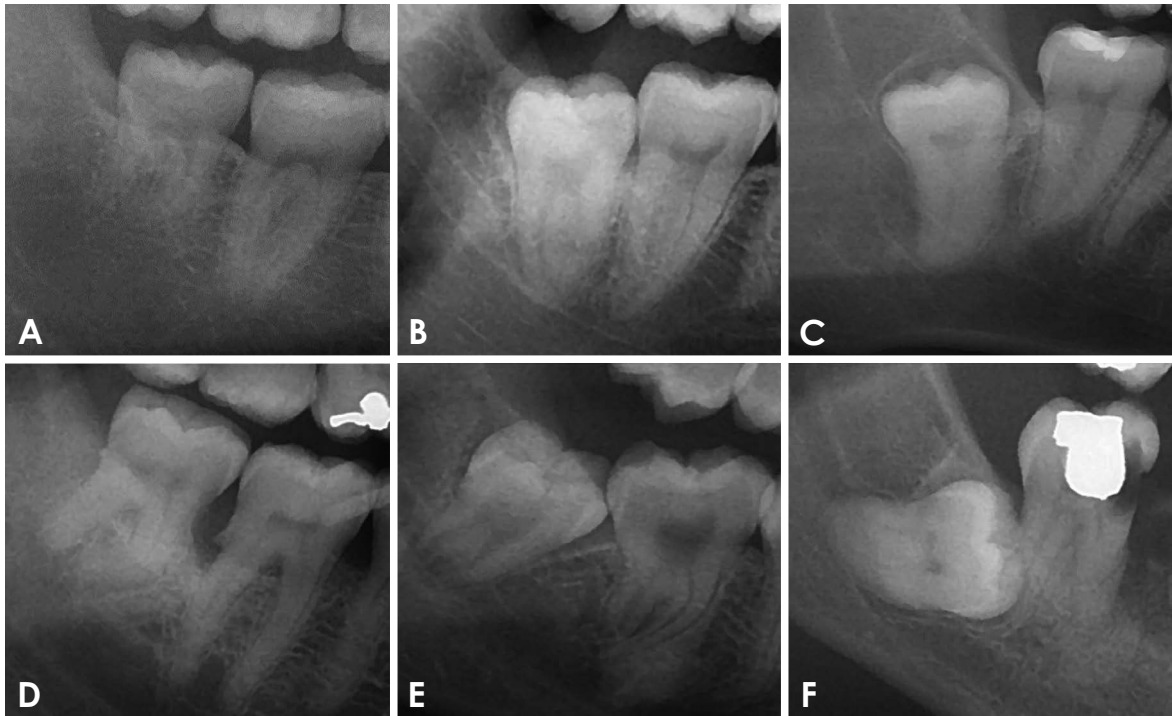
This study adhered to the principles outlined in the Declaration of Helsinki and received approval from the Ethics

Committee of the Federal University of Santa Maria (approval no. 19019319.1.0000.5346).

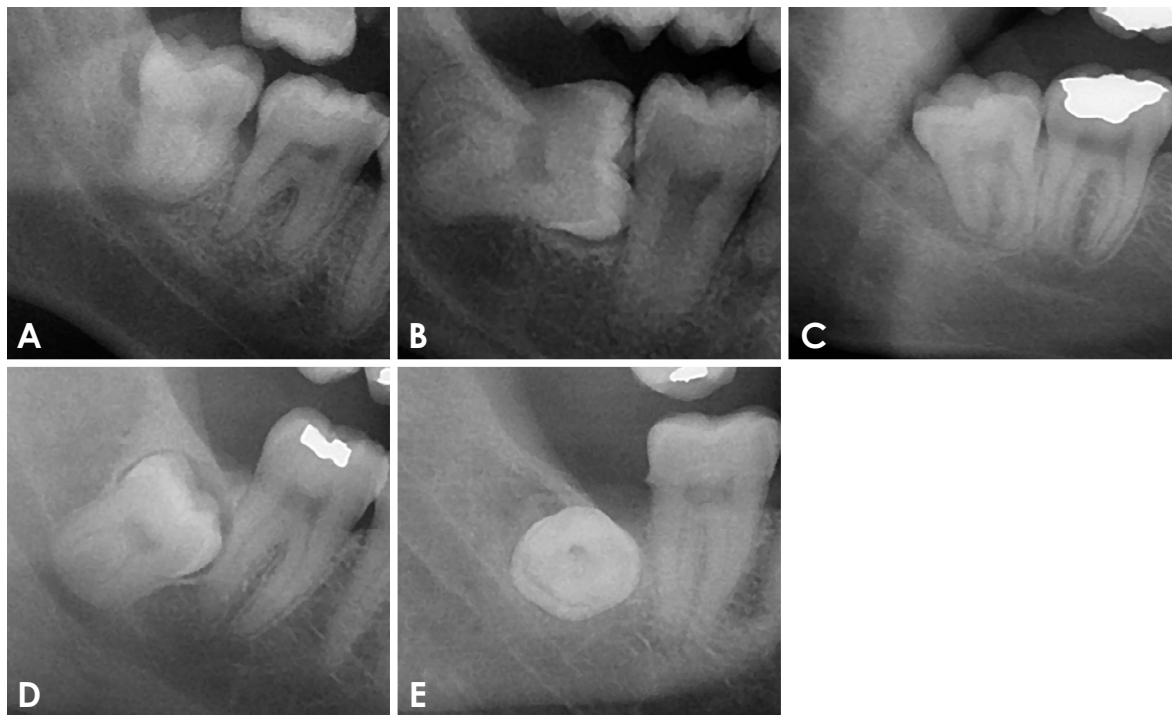
All digital panoramic radiographs (OP-200D; Instrumentarium Dental, Tuusula, Finland; exposure parameters adjusted according to patient sex and size) captured from October 2013 to December 2018 at the Federal University of Santa Maria were evaluated. Only radiographs featuring impacted 3Ms were included in the assessment. The inclusion criteria encompassed both upper and lower impacted 3Ms of Nolla developmental stage 7 and above. Any radiographs with technical errors that impeded the evaluation of the impacted 3Ms were excluded from the study.

A trained and calibrated examiner, a final-year postgraduate student in oral and maxillofacial radiology, assessed all images. CliniView software (Instrumentarium Dental) was used for this purpose, and the images were viewed on a 22-inch Thinkvision monitor (Lenovo, Morrisville, NC, USA). The viewing was conducted in a dark room with an indirect light source. The software's adjustment tools, such as zoom, gamma curve, brightness, and contrast, were utilized, along with a ruler for measuring the thickness of the dental follicular space. The training process involved the presentation and discussion of the conditions evaluated in the study, conducted by an oral and maxillofacial radiologist and an oral and maxillofacial surgeon. Calibration was achieved through the evaluation of 20 radiographs, which were not part of the study sample, on 2 separate occasions separated by a 1-week interval. The reproducibility of the evaluations, as determined by the intraclass correlation coefficient and kappa index, exceeded 0.88.

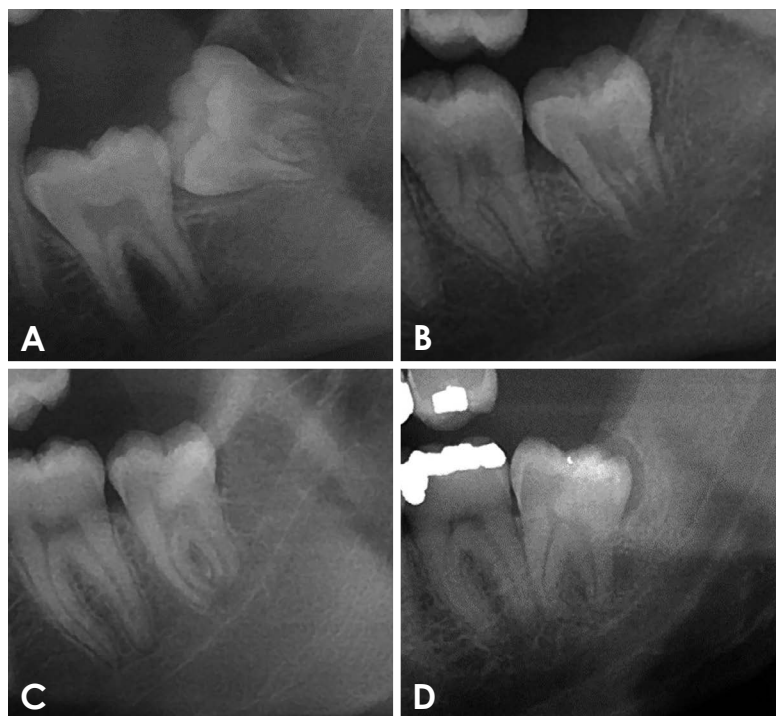The outcomes assessed in this study included developmental or acquired pathological conditions associated with impacted 3Ms. The diagnosis of a developmental pathology was made when any changes in bone structure were identified. The radiographic diagnosis of a dentigerous cyst was established when the thickness of the dental follicular space exceeded 3 mm. Acquired pathologies, such as dental caries, periapical lesions, or alveolar bone resorption, were diagnosed for impacted 3Ms as well as 2Ms. For the 2M cases, only lesions located on the distal surface of the tooth, that could be attributed to the presence of an impacted 3M, were considered. Additionally, 2Ms were examined for external root resorption. The tooth-related variables collected included the Pell and Gregory classification,<sup>28</sup> which pertains to the tooth's relation to the mandibular ramus and occlusal plane (Fig. 1); the Winter classification<sup>29</sup> concerning tooth angulation (Fig. 2); and the Nolla developmental stage<sup>30</sup> (Fig. 3). Demographic data, such as the patients' sex and age, were gathered



**Fig. 1.** Cropped panoramic radiographs show examples of impacted third molars (3Ms) organized by the Pell and Gregory classification. A: Class I. Sufficient space exists between the ramus and the distal portion of the second molar to accommodate the mesiodistal diameter of the 3M. B: Class II. The space between the second molar and the ramus of the mandible is less than the mesiodistal diameter of the 3M. C: Class III. The entirety or majority of the 3M is located within the ramus of the mandible. D: Position A. The occlusal plane of the impacted tooth aligns with the occlusal plane of the second molar. E: Position B. The occlusal plane of the impacted tooth is situated between the occlusal plane and the cervical line of the second molar. F: Position C. The impacted tooth is positioned below the cervical line of the second molar.



**Fig. 2.** Cropped panoramic radiographs illustrate examples of an impacted third molar, categorized according to the Winter classification system. A: Vertical angulation. B: Horizontal angulation. C: Distoangular angulation. D: Mesioangular angulation. E: Buccal angulation.



**Fig. 3.** Cropped panoramic radiographs display examples of impacted third molars at various Nolla stages. A: In stage 7, one-third of root formation is complete. B: In stage 8, two-thirds of root formation is complete. C: In Stage 9, the root formation is nearly complete, with the apex remaining open. D: In stage 10, root formation is complete.

from their medical records.

A descriptive analysis of the data was performed, and the prevalence rates of developmental or acquired pathologic conditions associated with impacted 3Ms were calculated. Binary and multivariate logistic regression models were utilized to assess the associations between the primary outcome (presence of pathology) and variables such as patient demographics and tooth characteristics. Multivariate logistic regression was performed, with the presence of pathology serving as the dependent variable and any variables with an initial outcome of  $P \leq 0.20$  in the binary analysis acting as independent variables. A significance level of 0.05 was applied in the multivariate model. Statistical analysis was performed using SPSS (ver. 13; SPSS Inc., Chicago, IL, USA). The threshold for statistical significance was set at 5% ( $P < 0.05$ ).

### Results

The sample consisted of 2054 panoramic radiographs and 4066 teeth. No radiographs were excluded due to technical errors.

Most of the patients were female, accounting for 59.2% of the total, and the mean age was  $27.2 \pm 11.5$  years. Dev-

elopmental pathologic conditions were found in 11.6% of the teeth (471 in total) from 398 patients, which represented 19.4% of the total patient population. Among these lesions, 460 (95.2%) were suggestive of dentigerous cysts. Only 14 (0.3%) were identified as other developmental conditions, with radiographic diagnoses suggesting lesions including compound odontomas, odontogenic keratocysts, calcifying odontogenic cysts, ameloblastomas, ameloblastic fibromas, and traumatic bone cysts. Acquired pathologic conditions were found in 17.5% of the teeth (710 in total) from 577 patients, which represented 28.1% of the total patient population. Of these conditions, 68 (9.6%) were associated with an impacted 3M, 258 (36.3%) with a 2M, and 384 (54.1%) with both the 2M and the impacted 3M. The most frequently observed acquired pathosis was dental caries, found in 689 teeth (16.9%), followed by periodontal lesions in 66 teeth (1.6%) and periapical lesions in 51 teeth (1.3%). External root resorption was identified in 54 teeth (1.3%). Table 1 presents the demographic and tooth-related variables of the sample, along with the prevalence of developmental and acquired pathologic conditions in each variable category.

Table 2 displays the results of the logistic regression analysis, which includes odds ratios (ORs) along with their

**Table 1.** Demographic and dental characteristics of the sample and the prevalence of developmental and acquired pathologic conditions identified in each variable category

	Variables	Number (%)	Developmental pathoses, number (%)	Acquired pathoses, number (%)	
Panoramic radiographs (n = 2054)	Sex: Female	1,215 (59.2%)	195 (16.0%)	330 (27.2%)	
	Male	838 (40.8%)	203 (24.2%)	247 (29.5%)	
	Age (years)	27.2 ± 11.5	26.9 ± 10.4	26.5 ± 9.2	
Teeth (n = 4066)	Right upper	535 (13.2%)	50 (9.3%)	20 (3.7%)	
	Left upper	531 (13.1%)	39 (7.3%)	15 (2.8%)	
	Left lower	1,506 (37%)	191 (12.7%)	319 (21.2%)	
	Right lower	1,494 (36.7%)	191 (12.8%)	356 (23.8%)	
	Nolla stage				
	Stage 7	191 (4.7%)	26 (13.6%)	2 (1.0%)	
	Stage 8	245 (6%)	23 (9.8%)	15 (6.1%)	
	Stage 9	396 (9.7%)	33 (8.4%)	70 (17.7%)	
	Stage 10	3,207 (78.9%)	387 (12.1%)	623 (19.4%)	
	Upper impacted third molars (n = 1066)	Winter classification			
Vertical		33 (3.1%)	0 (0.0%)	0 (0.0%)	
Mesioangular		600 (56.3%)	33 (5.5%)	27 (4.5%)	
Distoangular		366 (34.3%)	47 (12.8%)	8 (2.2%)	
Horizontal		22 (2.1%)	5 (22.7%)	0 (0.0%)	
Lower impacted third molars (n = 3000)	Pell and Gregory ramus				
	Class I	33 (1.1%)	3 (6.1%)	13 (39.4%)	
	Class II	2,864 (95.4%)	364 (12.7%)	655 (22.9%)	
	Class III	104 (3.5%)	16 (15.4%)	7 (6.7%)	
	Pell and Gregory occlusal				
	Position A	1,019 (34.1%)	223 (21.9%)	294 (28.9%)	
	Position B	1,442 (48.3%)	126 (8.8%)	336 (23.3%)	
	Position C	525 (17.6%)	30 (5.7%)	40 (7.6%)	
	Winter classification				
	Vertical	247 (8.3%)	55 (22.3%)	30 (12.1%)	
	Mesioangular	1,335 (44.6%)	109 (8.2%)	304 (22.8%)	
	Distoangular	898 (30.0%)	167 (18.6%)	177 (19.7%)	
	Horizontal	468 (15.6%)	44 (9.4%)	160 (34.2%)	
Transversal	43 (1.4%)	5 (11.6%)	1 (2.3%)		

corresponding 95% confidence intervals (CIs), as well as the significance of the associations between the presence of a developmental or acquired pathology and other variables. Male patients were 68% more likely than female patients to have a developmental pathology related to an impacted 3M (OR = 1.68; 95% CI: 1.26-2.24). This pattern was not observed in the case of acquired pathologies. Patients aged 20 to 50 years were particularly prone to exhibiting acquired pathologies related to an impacted 3M. However, the odds for patients aged 50 years or older indicated a protective effect.

The lower impacted 3Ms were relatively likely to exhibit either developmental or acquired pathologies. Furthermore, the stage of tooth development demonstrated varying associations, contingent on the type of pathology evaluated. Specifically, teeth at Nolla developmental stage 9 were less likely to present developmental pathologies, whereas teeth at Nolla developmental stages 7 and 8 were less likely to exhibit acquired pathologies.

Tooth-related analyses were performed independently for the upper and lower impacted 3Ms. For the upper 3Ms, the chances of exhibiting a developmental pathology were

**Table 2.** Multivariate logistic regression regarding the likelihood of detecting a developmental or acquired pathology associated with an impacted third molar, considering the evaluated variables

Variables	Developmental pathology			Acquired pathology		
	P-value	Odds ratio	95% CI	P-value	Odds ratio	95% CI
<b>Patient-related</b>						
Sex (female)						
Male	<0.05	1.685	1.267-2.241	0.218*	1.133	0.929-1.382
Age (up to 20 years)						
20 to 30 years	0.315	1.201	0.840-1.718	<0.05*	2.059	1.473-2.878
30 to 50 years	0.071	1.478	0.967-2.257	<0.05*	1.929	1.291-2.882
50 years or older	0.131	0.543	0.246-1.199	<0.05*	0.379	0.157-0.915
<b>Tooth-related</b>						
(Tooth 18)						
Tooth 28	0.207	0.753	0.485-1.170	0.405	0.749	0.379-1.480
Tooth 38	<0.05	1.436	1.033-1.995	<0.05	7.447	4.679-11.851
Tooth 48	<0.05	1.452	1.045-2.018	<0.05	8.645	5.438-13.749
Nolla stage (stage 10)						
Stage 7	0.742	1.075	0.700-1.649	<0.05	0.035	0.009-0.142
Stage 8	0.272	0.784	0.507-1.211	<0.05	0.252	0.147-0.429
Stage 9	<0.05	0.633	0.436-0.919	0.060	0.765	0.580-1.011
<b>Tooth-related (upper molars)</b>						
Winter classification (mesioangular)						
Vertical	0.998*	0	0	0.998*	0	0
Distoangular	<0.05*	2.531	1.589-4.033	0.068*	0.474	0.213-1.055
Horizontal	<0.05*	5.053	1.756-14.544	0.998*	0	0
Transversal	0.351*	1.676	0.566-4.961	0.998*	0	0
<b>Tooth-related (lower molars)</b>						
Pell and Gregory classification ramus (class I)						
Class II	0.808	1.198	0.279-5.144	<0.05	0.293	0.131-0.655
Class III	0.245	2.504	0.532-11.780	<0.05	0.080	0.026-0.246
Pell and Gregory classification occlusal (position A)						
Position B	<0.05	0.400	0.311-0.514	<0.05	0.601	0.492-0.734
Position C	<0.05	0.264	0.172-0.405	<0.05	0.144	0.099-0.209
Winter classification (mesioangular)						
Vertical	<0.05	2.101	1.440-3.065	<0.05	0.314	0.207-0.478
Distoangular	<0.05	1.694	1.281-2.240	<0.05	0.555	0.442-0.697
Horizontal	0.694	0.927	0.634-1.354	<0.05	1.684	1.321-2.147
Transversal	0.250	1.784	0.665-4.783	0.067	0.154	0.021-1.141

CI: confidence interval. For each variable, the reference group is in parentheses. \*: result of binary logistic regression.

elevated by 2.5 times and 5.0 times for the distoangular and horizontal positions, respectively. For the lower 3Ms, a higher likelihood of developmental pathology was observed in association with Pell and Gregory position A, in relation to the occlusal plane, as well as with Winter vertical and distoangular angulations. Furthermore, the probability of presenting an acquired pathology was elevated for

Pell and Gregory position A and class I, along with Winter horizontal angulation.

### Discussion

The extraction of impacted 3Ms is one of the most frequently performed surgical procedures in dental practice.<sup>8,23</sup>

Despite its prevalence, determining the optimal course of action for an asymptomatic impacted 3M remains challenging due to the ongoing debate between the risks of pathologic conditions in impacted teeth and those associated with prophylactic extraction.<sup>12,22-25,31</sup> Therefore, to assist dentists in their decision-making process when evaluating asymptomatic impacted 3Ms, this study was conducted to examine the prevalence of both developmental and acquired pathologic conditions in 4066 impacted 3Ms. Additionally, the study explored the association between these conditions and various demographic and dental characteristics of the patients.

The academic community has used panoramic radiographs to extensively investigate the prevalence of pathoses associated with impacted 3Ms. However, most previous studies have involved relatively small sample sizes, ranging from 95 to 3000 impacted 3Ms.<sup>10,24,27,31-36</sup> Only 2 studies have included a sample size greater than 4000.<sup>12,23</sup> Regarding the Brazilian population, only 1 study exists, which evaluated 151 teeth with the aim of correlating the positions of the impacted 3Ms with the presence of dentigerous cysts.<sup>37</sup> Therefore, a clear deficiency exists in studies with substantial sample sizes and information specifically pertaining to Brazilian samples.

In the present study, the prevalence of developmental pathologic conditions associated with impacted 3Ms was 11.6%. Of those cases, 95.2% exhibited radiographic characteristics of a dentigerous cyst. This aligns with previous research, which reported a low prevalence of bone lesions (ranging from 0.8% to 14.7%) related to impacted 3Ms, with dentigerous cysts being the most common.<sup>9,12,23,27,35</sup> In a study conducted by Patil et al.,<sup>23</sup> the prevalence of cysts was 2.2% and that of tumors was 1.2%, with 99% of the histopathological diagnoses being dentigerous cysts. Similar findings were reported by Shin et al.,<sup>12</sup> in which teeth with dental follicles exceeding 3 mm in radiographic analysis were considered pathological. Upon histopathological analysis, 76.4% were diagnosed as dentigerous cysts. In research conducted by Silva et al.,<sup>38</sup> the dentigerous cyst was identified as the most common developmental cyst. Other bone lesions were less prevalent, including odontoma (0.7%), unicystic ameloblastoma (0.4%), and ameloblastoma (0.7%).

In addition to the developmental pathologies observed in the impacted 3Ms, the present findings also revealed that 17.5% of impacted 3Ms were associated with acquired pathologies in either the 3M or the 2M. The prevalence of acquired pathologies reported in the literature ranges from 0.3% to 42.7%.<sup>4,10,27,34,35</sup> The most common lesion iden-

tified in the present study was dental caries, which was strongly associated with position A and class II according to the Pell and Gregory classification, as well as with mesioangular and horizontal angulations as per the Winter classification. This observation is consistent with the existing literature<sup>27,36,39</sup> and suggests that a partially erupted tooth may hinder the patient's ability to control plaque effectively.

The positioning of the 3M is crucial for surgical planning and risk assessment, and it is frequently utilized by oral and maxillofacial surgeons. Therefore, the Pell and Gregory and Winter classifications hold great importance for evaluating impacted 3Ms.<sup>15</sup> Few studies have investigated the correlation between the positioning of the impacted 3M and the presence of pathological conditions. It has been observed that impacted 3Ms classified as Pell and Gregory position C<sup>37</sup> and class III<sup>27</sup> are particularly prone to developing pathologies. In terms of the Winter classification, mesioangular,<sup>37</sup> vertical,<sup>27,32</sup> and horizontal<sup>32</sup> angulations have been identified as relatively likely to exhibit cystic changes. In the present study, positions B and C according to the Pell and Gregory classification were less likely than position A to display bone lesions. The distoangular and horizontal positions, according to the Winter classification, were relatively frequently associated with the presence of a developmental pathology. This could be attributed to the fact that in these positions, the tooth crown is often infrabony, increasing its susceptibility to lesion development. Ryalat et al.<sup>24</sup> have noted that the position of impacted 3Ms can change over time, underscoring the necessity of conducting radiographic follow-ups over the years.

Lower impacted 3Ms were found to be more likely to exhibit pathology than upper impacted teeth, a finding that supports previous studies.<sup>23,37,40</sup> In the maxilla, both the prevalence of impacted 3Ms (26.3%) and the occurrence of pathologic conditions (16.5%) were less frequent than in the mandible, for which the rates were 73.7% and 26.3%, respectively. As reported by Hounsoume et al.,<sup>9</sup> the prevalence of prophylactic extractions was considerably higher among upper 3Ms (79%) compared to lower 3Ms (22%). Sebastiani et al.<sup>15</sup> noted that one of the most common complications during the extraction of 3Ms is the fracture of the maxillary tuberosity, which is particularly associated with teeth in a vertical position, as per the Winter classification.

Demographic details, including age and sex, were assessed to determine their potential influence on the likelihood of a patient presenting with a pathology associated with an impacted 3M. The majority of the patients were female (59.2%), which could be attributed to the generally higher frequency of women seeking health care compared

to men.<sup>41</sup> However, male patients demonstrated a higher likelihood of 3M pathology compared to their female counterparts. This higher rate of pathologic conditions in males has been corroborated by previous studies,<sup>12,42</sup> although the underlying reasons for this predisposition remain unclear in the existing literature. In terms of age, no significant association was identified in this study. This lack of correlation continues to be a contentious issue in the literature. Some studies have suggested that the incidence of pathologic conditions associated with impacted 3Ms decreases with age,<sup>9,11</sup> while others have proposed that the proportion may actually increase.<sup>12,42</sup> Additional demographic factors such as occupation, income, religion, ethnicity, and education level were not considered in this study. Rather, the focus of this research was to evaluate the potential influence of biological factors, on either the individual or the tooth level, on the development of pathological conditions. As such, sex and age were deemed to be the most relevant variables. Furthermore, those demographic variables have been the subject of investigation in previous studies.<sup>10,12,32,40</sup>

The binary logistic regression results indicated that older patients were relatively likely to exhibit an acquired pathology associated with an impacted 3M. This finding aligns with other studies that have demonstrated an increased prevalence of dental caries and periodontal lesions over time.<sup>43</sup> Therefore, the evaluation and preservation of an impacted 3M should be strategically planned, taking into account the potential impact on the adjacent tooth. In instances in which tooth lesions appear in both the 2M and the 3M, particularly in more severe cases, it is advisable to extract both teeth.<sup>3</sup>

Tooth development is traditionally measured using the Nolla staging system, which ranges from stage 1 (bone crypt) to stage 10 (root formation completed and apex closed).<sup>30</sup> Full development of the 3M is generally expected to occur by the age of 20 years, although this can vary based on the population.<sup>44,45</sup> The findings of this study indicated that impacted 3M teeth at Nolla developmental stage 9 were less prone to pathology than fully developed teeth. The data also implied a potential correlation between the early Nolla stages and an increase in dental follicle thickness; this supports the observation that dentigerous cysts are more prevalent in the second and third decades of life, a period during which root formation may not yet be complete.<sup>46</sup> In a separate study,<sup>47</sup> the dental follicle of the 3M was examined, revealing that root formation resulted in cellular changes, follicle maturation, and a cessation of cellular activity. This was also correlated with a decrease

in the width of the radiographic pericoronal space. However, a comprehensive understanding of the longitudinal behavior of dental follicles can only be achieved through clinical and radiographic follow-up, with a primary emphasis on histopathological analysis.

This study employed radiographic criteria to diagnose developmental or acquired lesions. While the lack of clinical data presented a limitation, radiographic data are frequently utilized in this type of survey.<sup>18,24,44,45</sup> Studies involving the histopathological evaluation of dental follicles have revealed that spaces smaller than 2.5 mm could already exhibit cystic characteristics.<sup>33,35,42</sup> However, other research has indicated that, on panoramic radiographs, dental follicle spaces larger than 3 mm should be considered as potentially indicative of dentigerous cysts.<sup>12,27,48</sup> Therefore, given the exclusively radiographic focus of this study, employing a 3 mm classification enhances the reliability of the radiographic diagnosis in the absence of histopathological analysis. Regarding the imaging technique, although CBCT provides a more accurate assessment of the size of the follicular space,<sup>33</sup> panoramic radiography is the preferred examination to evaluate impacted 3Ms.<sup>15</sup> CBCT is recommended for pre-surgical evaluations when radiographs suggest a close interrelationship between the 3M and anatomical structures, such as the mandibular canal or an adjacent tooth. However, this method should not be used routinely for all impacted 3M cases.<sup>19</sup> As for the diagnosis of acquired pathoses, it is important to note that panoramic radiographs are less accurate than intraoral radiographs for tooth diagnosis. Consequently, the actual prevalence of tooth disease in the evaluated population may be higher than the reported prevalence. Additionally, this study did not investigate the prevalence of pericoronitis, which, despite its common association with 3Ms, necessitates a clinical examination for diagnosis.<sup>49</sup> Finally, many registries included incomplete data regarding patient age, limiting the ability to assess the associations with this variable.

In conclusion, the prevalence of radiographic pathologic conditions associated with impacted 3Ms was relatively low in the assessed population. Developmental pathosis was associated with male sex, lower 3M placement, horizontal or distoangular positioning, and incomplete root formation. In contrast, acquired pathoses were related to lower tooth position, complete root formation, and partial eruption. This underscores the importance of clinical and especially radiographic monitoring of impacted 3Ms.

**Conflicts of Interest:** None



## References

- Carter K, Worthington S. Predictors of third molar impaction: a systematic review and meta-analysis. *J Dent Res* 2016; 95: 267-76.
- Camargo IB, Melo AR, Fernandes AV, Cunningham LL, Laureano Filho JR, Van Sickels JE. Decision making in third molar surgery: a survey of Brazilian oral and maxillofacial surgeons. *Int Dent J* 2015; 65: 169-77.
- Shoshani-Dror D, Shilo D, Ginini JG, Emodi O, Rachmiel A. Controversy regarding the need for prophylactic removal of impacted third molars: an overview. *Quintessence Int* 2018; 49: 653-62.
- Toedtling V, Devlin H, O'Malley L, Tickle M. A systematic review of second molar distal surface caries incidence in the context of third molar absence and emergence. *Br Dent J* 2020; 228: 261-6.
- Vandeplass C, Vranckx M, Hekner D, Politis C, Jacobs R. Does retaining third molars result in the development of pathology over time? A systematic review. *J Oral Maxillofac Surg* 2020; 78: 1892-908.
- Friedman JW. The prophylactic extraction of third molars: a public health hazard. *Am J Public Health* 2007; 97: 1554-9.
- Zawawi KH, Melis M. The role of mandibular third molars on lower anterior teeth crowding and relapse after orthodontic treatment: a systematic review. *ScientificWorldJournal* 2014; 2014: 615429.
- Duarte-Rodrigues L, Miranda EF, Souza TO, de Paiva HN, Falci SG, Galvão EL. Third molar removal and its impact on quality of life: systematic review and meta-analysis. *Qual Life Res* 2018; 27: 2477-89.
- Hounsoume J, Pilkington G, Mahon J, Boland A, Beale S, Kotas E, et al. Prophylactic removal of impacted mandibular third molars: a systematic review and economic evaluation. *Health Technol Assess* 2020; 24: 1-116.
- van der Linden W, Cleaton-Jones P, Lownie M. Diseases and lesions associated with third molars. Review of 1001 cases. *Oral Surg Oral Med Oral Pathol Oral Radiol Endod* 1995; 79: 142-5.
- Adeyemo WL. Do pathologies associated with impacted lower third molars justify prophylactic removal? A critical review of the literature. *Oral Surg Oral Med Oral Pathol Oral Radiol Endod* 2006; 102: 448-52.
- Shin SM, Choi EJ, Moon SY. Prevalence of pathologies related to impacted mandibular third molars. *Springerplus* 2016; 5: 915.
- Mello FW, Melo G, Kammer PV, Speight PM, Rivero ER. Prevalence of odontogenic cysts and tumors associated with impacted third molars: a systematic review and meta-analysis. *J Craniomaxillofac Surg* 2019; 47: 996-1002.
- American Association of Oral and Maxillofacial Surgeons. Management of impacted third molar teeth [Internet]. American Association of Oral and Maxillofacial Surgeons: Rosemont; 2016 [cited 2023 Feb 11]. Available from [https://www.aaoms.org/docs/govt\\_affairs/advocacy\\_white\\_papers/management\\_third\\_molar\\_white\\_paper.pdf](https://www.aaoms.org/docs/govt_affairs/advocacy_white_papers/management_third_molar_white_paper.pdf).
- Sebastiani AM, Todero SR, Gabardo G, da Costa DJ, Rebelatto NL, Scariot R. Intraoperative accidents associated with surgical removal of third molars. *Braz J Oral Sci* 2014; 13: 276-80.
- Atieh MA. Diagnostic accuracy of panoramic radiography in determining relationship between inferior alveolar nerve and mandibular third molar. *J Oral Maxillofac Surg* 2010; 68: 74-82.
- Matzen LH, Wenzel A. Efficacy of CBCT for assessment of impacted mandibular third molars: a review - based on a hierarchical model of evidence. *Dentomaxillofac Radiol* 2015; 44: 20140189.
- Tantanapornkul W, Mavin D, Prapaiphittayakun J, Phipatboonyarat N, Julphantong W. Accuracy of panoramic radiograph in assessment of the relationship between mandibular canal and impacted third molars. *Open Dent J* 2016; 10: 322-9.
- Sedentext Radiation protection: cone beam CT for dental and maxillofacial radiology. Evidence based guidelines 2011 (v2.0) [Internet]. SEDENTEXCT project; 2011 [cited 2023 Feb 10]. Available from: Available from: <https://sedentext.eu/content/guidelines-cbct-dental-and-maxillofacial-radiology.htm>. Cone Beam CT for Dental and Maxillofacial Radiology (Evidence-based Guidelines). *Radiat Prot Eur Comm* 2012; 1-156.
- Matzen LH, Berkhout E. Cone beam CT imaging of the mandibular third molar: a position paper prepared by the European Academy of DentoMaxilloFacial Radiology (EADMFR). *Dentomaxillofac Radiol* 2019; 48: 20190039.
- Jaju PP, Jaju SP. Cone-beam computed tomography: time to move from ALARA to ALADA. *Imaging Sci Dent* 2015; 45: 263-5.
- Costa MG, Pazzini CA, Pantuzo MC, Jorge ML, Marques LS. Is there justification for prophylactic extraction of third molars? A systematic review. *Braz Oral Res* 2013; 27: 183-8.
- Patil S, Halgatti V, Khandelwal S, Santosh BS, Maheshwari S. Prevalence of cysts and tumors around the retained and unerupted third molars in the Indian population. *J Oral Biol Craniofac Res* 2014; 4: 82-7.
- Ryalat S, AlRyalat SA, Kassob Z, Hassona Y, Al-Shayyab MH, Sawair F. Impaction of lower third molars and their association with age: radiological perspectives. *BMC Oral Health* 2018; 18: 58.
- Ghaemini H, Nienhuijs ME, Toedtling V, Perry J, Tummers M, Hoppenreijts TJ, et al. Surgical removal versus retention for the management of asymptomatic disease-free impacted wisdom teeth. *Cochrane Database Syst Rev* 2020; 5: CD003879.
- Vranckx M, Lauwens L, Moreno Rabie C, Politis C, Jacobs R. Radiological risk indicators for persistent postoperative morbidity after third molar removal. *Clin Oral Investig* 2021; 25: 4471-80.
- Haddad Z, Khorasani M, Bakhshi M, Tofangchiha M, Shalli Z. Radiographic position of impacted mandibular third molars and their association with pathological conditions. *Int J Dent* 2021; 2021: 8841297.
- Pell GJ, Gregory GT. Impacted mandibular third molars: classification and modified technique for removal. *Dent Dig* 1933; 39: 330-8.
- Winter GB. Principles of exodontia as applied to the impacted third molar: a complete treatise on the operative technic with clinical diagnoses and radiographic interpretations. St. Louis: American Medical Book; 1926. pp. 21-58.
- Nolla CM. The development of permanent teeth. *J Dent Child*

- 1960; 27: 254-66.
31. Kruger E, Thomson WM, Konthasinghe P. Third molar outcomes from age 18 to 26: findings from a population-based New Zealand longitudinal study. *Oral Surg Oral Med Oral Pathol Oral Radiol Endod* 2001; 92: 150-5.
  32. Baykul T, Saglam AA, Aydin U, Başak K. Incidence of cystic changes in radiographically normal impacted lower third molar follicles. *Oral Surg Oral Med Oral Pathol Oral Radiol Endod* 2005; 99: 542-5.
  33. Haghanifar S, Moudi E, Seyedmajidi M, Mehdizadeh M, Nosrati K, Abbaszadeh N, et al. Can the follicle-crown ratio of the impacted third molars be a reliable indicator of pathologic problem? *J Dent (Shiraz)* 2014; 15: 187-91.
  34. Chu FC, Li TK, Lui VK, Newsome PR, Chow RL, Cheung LK. Prevalence of impacted teeth and associated pathologies - a radiographic study of the Hong Kong Chinese population. *Hong Kong Med J* 2003; 9: 158-63.
  35. Al-Khateeb TH, Bataineh AB. Pathology associated with impacted mandibular third molars in a group of Jordanians. *J Oral Maxillofac Surg* 2006; 64: 1598-602.
  36. Claudia A, Barbu HM, Adi L, Gultekin A, Reiser V, Gultekin P, et al. Relationship between third mandibular molar angulation and distal cervical caries in the second molar. *J Craniofac Surg* 2018; 29: 2267-71.
  37. Miranda da Rosa F, Oliveira MG, Palmeira da Silva V, Rados PV, Sant'Ana Filho M. Relationship between the positions of impacted third molars and the presence of dentigerous cysts. *Gen Dent* 2015; 63: 43-6.
  38. Silva K, Alves A, Correa M, Etges A, Vasconcelos AC, Gomes AP, et al. Retrospective analysis of jaw biopsies in young adults. A study of 1599 cases in Southern Brazil. *Med Oral Patol Oral Cir Bucal* 2017; 22: e702-7.
  39. Marques J, Montserrat-Bosch M, Figueiredo R, Vilchez-Pérez MA, Valmaseda-Castellón E, Gay-Escoda C. Impacted lower third molars and distal caries in the mandibular second molar. Is prophylactic removal of lower third molars justified? *J Clin Exp Dent* 2017; 9: e794-8.
  40. Shoae S, Khazaei P, Mashhadiabbas F, Varshosaz M, Sharifi F, Hessari H. Association between tooth impaction and odontogenic lesions: a matched case-control study. *Med J Islam Repub Iran* 2018; 32: 57.
  41. Pinkhasov RM, Wong J, Kashanian J, Lee M, Samadi DB, Pinkhasov MM, et al. Are men shortchanged on health? Perspective on health care utilization and health risk behavior in men and women in the United States. *Int J Clin Pract* 2010; 64: 475-87.
  42. Haidry N, Singh M, Mamatha NS, Shivhare P, Girish HC, Ranganatha N, et al. Histopathological evaluation of dental follicle associated with radiographically normal impacted mandibular third molars. *Ann Maxillofac Surg* 2018; 8: 259-64.
  43. Fisher EL, Garaas R, Blakey GH, Offenbacher S, Shugars DA, Phillips C, et al. Changes over time in the prevalence of caries experience or periodontal pathology on third molars in young adults. *J Oral Maxillofac Surg* 2012; 70: 1016-22.
  44. Kasper KA, Austin D, Kvanli AH, Rios TR, Senn DR. Reliability of third molar development for age estimation in a Texas hispanic population: a comparison study. *J Forensic Sci* 2009; 54: 651-7.
  45. Berkvens ME, Fairgrieve SI, Keenan S. A comparison of techniques in age estimation using the third molar. *Can Soc Forensic Sci J* 2017; 50: 74-83.
  46. Kambalimath DH, Kambalimath HV, Agrawal SM, Singh M, Jain N, Anurag B, et al. Prevalence and distribution of odontogenic cyst in indian population: a 10 year retrospective study. *J Maxillofac Oral Surg* 2014; 13: 10-5.
  47. de Oliveira DM, de Souza Andrade ES, da Silveira MM, Cargamo IB. Correlation of the radiographic and morphological features of the dental follicle of third molars with incomplete root formation. *Int J Med Sci* 2008; 5: 36-40.
  48. Kotrashetti VS, Kale AD, Bhalaerao SS, Hallikeremath SR. Histopathologic changes in soft tissue associated with radiographically normal impacted third molars. *Indian J Dent Res* 2010; 21: 385-90.
  49. Leone SA, Edenfield MJ, Cohen ME. Correlation of acute pericoronitis and the position of the mandibular third molar. *Oral Surg Oral Med Oral Pathol* 1986; 62: 245-50.