



# The function of the tensor tympani muscle: a comprehensive review of the literature

Alexis Edmonson<sup>1</sup>, Joe Iwanaga<sup>2,3,4</sup>, Łukasz Olewnik<sup>5</sup>, Aaron S. Dumont<sup>2</sup>, R. Shane Tubbs<sup>1,2,3,6,7,8</sup>

<sup>1</sup>Department of Structural & Cellular Biology, Tulane University School of Medicine, New Orleans, LA, <sup>2</sup>Department of Neurosurgery, Tulane Center for Clinical Neurosciences, Tulane University School of Medicine, New Orleans, LA, <sup>3</sup>Department of Neurology, Tulane Center for Clinical Neurosciences, Tulane University School of Medicine, New Orleans, LA, USA, <sup>4</sup>Division of Gross and Clinical Anatomy, Department of Anatomy, Kurume University School of Medicine, Kurume, Fukuoka, Japan, <sup>5</sup>Department of Anatomical Dissection and Donation, Medical University of Lodz, Lodz, Poland, <sup>6</sup>Department of Neurosurgery and Ochsner Neuroscience Institute, Ochsner Health System, New Orleans, LA, USA, <sup>7</sup>Department of Anatomical Sciences, St. George's University, St. George's, Grenada, <sup>8</sup>Department of Surgery, Tulane University School of Medicine, New Orleans, LA, USA

**Abstract:** The tensor tympani muscle is structurally important in the middle ear, specifically through its involvement in the impedance of sound in response to intense auditory and non-auditory stimuli. Despite numerous studies, its true function has been debated for many years; questions still remain about its role in auditory and non-auditory reflexes and in sound damping. Some studies suggest that the tensor tympani muscle contracts as a result of non-auditory stimulation such as facial or head movements; others suggest that it contracts due to input from the cochlear nucleus, therefore by way of auditory stimulation. Whatever the cause, contraction of the tensor tympani muscle results in low frequency mixed hearing loss, either to protect the inner ear from loud sounds or to desensitize the ear to self-generated sounds. A review of these studies indicated that the tensor tympani muscle has a wide range of functions, yet the mechanisms of some of them have not been clearly demonstrated. One major question is whether the tensor tympani muscle contributes to sound damping; and if it does, what specific role it serves. The primary purpose of this review article is to explore the functions of the tensor tympani muscle in light of recent research advances.

**Key words:** Ear, Sound, Hearing, Muscles, Anatomy


Received February 15, 2021; 1st Revised April 6, 2021; 2nd Revised November 3, 2021; 3rd Revised December 14, 2021; Accepted January 13, 2022

## Introduction

The tensor tympani muscle (TTM) (Fig. 1) resides in the middle ear. It arises from the cartilaginous part of the pharyngotympanic tube and inserts on the manubrium of the malleus [1]. It is innervated by the nerve to the tensor tympani, which originates from the mandibular division of

the trigeminal nerve. It functions to tension the tympanic membrane by drawing it medially [2]. Although much is known about the TTM, researchers still question its exact function. One aspect that is debated is whether the TTM is responsible for sound damping although it is clear that the stapedius muscle is primarily involved in this function. It could achieve this by stiffening the ossicular chain, which decreases the amplitude of sound being transmitted to the cochlea; however, much research concerns whether the TTM produces this stiffening directly or indirectly. It could even contribute to certain pathological conditions of the ear [3, 4]. For example, a tenotomy of the middle ear muscles (MEM) can relieve some symptoms of conditions such as Ménière's disease. However, there is no clear explanation as to why this

### Corresponding author:

Joe Iwanaga   
Department of Neurosurgery, Tulane Center for Clinical Neurosciences,  
Tulane University School of Medicine, New Orleans, LA 70112, USA  
E-mail: iwanagajoe@gmail.com

Copyright © 2022. Anatomy & Cell Biology

This is an Open Access article distributed under the terms of the Creative Commons Attribution Non-Commercial License (<http://creativecommons.org/licenses/by-nc/4.0/>) which permits unrestricted non-commercial use, distribution, and reproduction in any medium, provided the original work is properly cited.

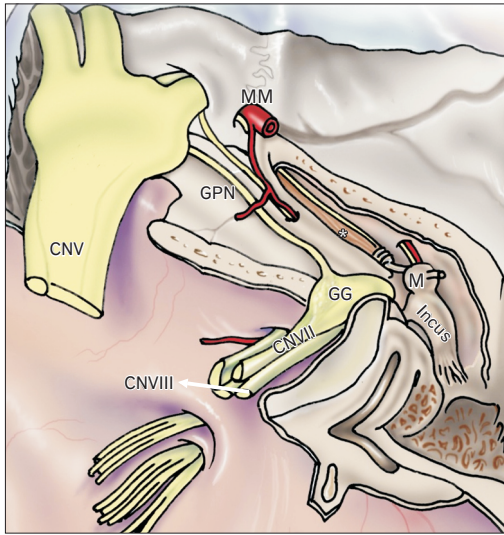


Fig. 1. Schematic drawing of the right skull base illustrating the tensor tympani muscle (asterisk) after the roof of the middle ear has been removed. Note the muscles attachment onto the malleus (M). For reference, note the middle meningeal artery (MM), greater petrosal nerve (GPN), geniculate ganglion (GG), and cranial nerves trigeminal (CNV), facial (CNVII), and vestibulocochlear (CNVIII).

occurs.

The purpose of this comprehensive review is to examine the true function of the TTM in light of recent reports in the literature.

## Review

### Database search

Using PubMed, “tensor tympani”, “tensor tympani muscle”, “tensor muscle”, “ear”, “middle ear muscles”, “function”, “physiology”, and “anatomy” were searched. Inclusion criteria included articles dealing with the function/physiology/pathology of the TTM and published in English including studies in both animals and humans. Exclusion criteria included articles published in languages other than English and papers not dealing specifically with the function or proposed function of the TTM. A total of approximately 50 papers were reviewed and distilled down to the paper used in this review.

### Muscle fiber types

In animals, the TTM contains numerous type II muscle fibers, as demonstrated by immunohistochemistry using myosin-type specific antisera [5]. This study also proved that although the TTM and the stapedius muscle have many

similarities, their difference in fiber composition could account for their distinct functional roles. Whether the TTM comprised mainly slow or fast muscle fibers had been debated; it has now been accepted that to serve its role a functional component of the MEM reflex, it contains fibers that contract quickly and are fatigue-resistant [6]. The MEM reflex is the contraction of both these muscles in response to excessive auditory input to the ear. Its purpose is believed to be the prevention of injury to the inner ear. It causes impedance of sound by decreasing the volume in the middle ear, which leads to increased pressure because the TTM forces the manubrium of the malleus inward as a result of the influx of sound through the middle ear [7, 8]. Along with type II muscle fibers, in animals, it also contains abundant elastic fibers that allow it to stiffen the ossicles during loud sounds [6].

### Middle ear muscle reflex

Although the true function of the TTM is not yet fully understood, some specific roles have been revealed through multiple studies. The TTM, in conjunction with the stapedius muscle, is important in the MEM reflex. As mentioned earlier, the MEM reflex is the contraction of both these muscles in response to excessive auditory input to the ear. Although both the TTM and the stapedius muscle are involved in the MEM reflex, the stapedius appears to dominate. For example, one study found that patients with paralysis of the stapedius muscle but an intact TTM had no MEM reflex [9].

### Stimulation, function, and embryology

In animals, the TTM is partly innervated by motor neurons that consist of cochlear nuclear inputs [10]; therefore, it does respond to auditory input. Since the MEM reflex is lost even with a fully functioning TTM, it is believed that in humans, the TTM contracts in response to self-generated auditory stimuli such as swallowing [11], chewing [9], or vocalization [12-15]. Interestingly, both the TTM and the tensor veli palatini muscle are derived from the first pharyngeal arch, the latter being involved in swallowing. This embryological connection could suggest that swallowing and contraction of the TTM coincide [16]. Additionally, cranial nerves involved with feeding, e.g., mastication muscles, tongue muscles, pharyngeal muscles are thought to have central connections with the brainstem [17].

Another function specific to the TTM is the low frequency mixed (combination of conductive and sensorineural)

hearing loss that occurs when it contracts after auditory and non-auditory stimulation. When the TTM contracts it pulls on and stiffens the middle ear ossicles, which decreases the sound input to the cochlea. The auditory stimulation that leads to contraction of the TTM is due to the actions described, while non-auditory stimulation includes the startle reflex, anticipation of loud sounds, orbital air jet, and tactile stimulation of the face [18]. Bance et al. [19] in 2013 showed that when these non-auditory stimuli were presented to patients with conductive hearing loss, there was increased stiffness in the ossicles of the middle of ear because the TTM contracted, leading to a decrease in the low frequency vibrations transmitted to the umbo and stapes [19]. The audiometric findings showed that the decrease in vibrations resulted in the low frequency mixed hearing loss experienced by the subjects.

### **Testing and microstructure**

It is important to determine when the TTM contracts. In 2017, Wickens et al. [3] tested volunteers who could voluntarily contract their TTM, measuring the contractions using standard audiometric testing. The resulting audiogram showed a specific pattern portraying the differences between the air and bone conduction thresholds when the TTM was relaxed or contracted. The participants experienced reversible, low-frequency conductive hearing loss when the muscle was contracted owing to a lack of sound transmission through the ossicles.

A study conducted in 1990 was designed to test the potential role of the TTM in animals in sound transmission using immunohistochemistry, gross and microscopic anatomical analyses, morphometry, histochemistry, and electron microscopy [12]. For morphometry, the researchers took a cross-section of the muscle to examine the fiber composition. Histochemistry was used to analyze enzyme activity, which enabled the researchers to determine whether fast or slow oxidative fibers predominated in the TTM. Immunohistochemistry showed that most of the fibers reacted positively to anti-IIB antibody, so they corresponded to type II muscle fibers. Electron microscopy was used to determine muscle fiber ultrastructure, including the arrangement of mitochondria. Major conclusions from this study were that the TTM contains fast and slow oxidative glycolytic fibers, as indicated by their arrangement and the large number of mitochondria; its movement is consistent with isometric contraction; and its fiber composition indicates a fatigue-resistant and rapidly-

contracting muscle. These features of the TTM are consistent with its contraction in response to loud sounds. The results supported the primary aim of this study, which was to determine whether the TTM is involved in sound transmission. Subsequent experiments showed that the TTM contracts in response to non-auditory or self-generated auditory stimuli.

### **Eliciting TTM contraction**

In 2010, Mukerji et al. [6] conducted a study that helped to explain why the TTM contracts in response to self-generated auditory stimuli such as chewing and swallowing, and why this mechanism is different from the contraction of the stapedius muscle. This study provided a basis for understanding the MEM reflex and the structural and functional differences between the stapedius muscle and TTM. One interesting finding was that the motor neurons corresponding to the TTM are located on a portion of the brainstem near the motor neurons that also relay information to the masseter and digastric muscles. This could explain the TTM's response to swallowing. The study used electron microscopy to explore the contrasting structures of the stapedius muscle and TTM motor neurons. A pseudo-rabies virus was used to track the pathways of the MEM reflex, specifically between the cochlear nuclear interneurons and the motor neurons supplying each muscle. The purpose was to locate the interneurons on the cochlear nucleus. Since the interneurons of the cochlear nucleus between the stapedius and the TTM were located on separate sections, it was concluded that they functioned in different reflex pathways. This study confirmed previous research on the MEM reflex and a specific role for each muscle involved.

A study in 2013 took a deeper look into the contraction of the TTM in response to non-auditory stimuli and how these findings could be used to investigate the causes of many otological conditions [19]. The aim was to measure the changes in contraction of the TTM when the subject was exposed to non-auditory stimuli, using a middle ear laser Doppler vibrometer. Participants were subjected to one of three conditions: stroking the face with a fine brush, mentally counting to ten, or having air puffed into their eye while closed. The first two conditions did not elicit a TTM contraction; however, participants who had air puffed into their eyes reported changes in sound impedance, implying contraction of the TTM. The extent of muscle contraction was predicted by a computer model simulating the participant's conditions. An important aspect addressed by this research paper was that

hypercontraction of the TTM can be the trigger for certain diseases of the ear. This is because intense stimulation of the TTM results in low frequency conductive hearing loss consequent on decreased vibration from the TTM to the umbo and stapes. Some design flaws in this study were the small number of participants (twenty) and the stipulation that the participants must be able to contract their TTM voluntarily for a substantial time, which is not a common ability according to the authors. It would therefore be difficult to replicate the study and its results exactly.

### ***Association with Ménière's disease***

The clinical implications of TTM function include potential causes of many otological conditions such as Ménière's disease and tinnitus. In 2018, Azuma et al. [4] examined the outcome of tenotomy in patients order to determine whether the TTM is involved in these disorders. The researchers hypothesized that the differences in anatomical structure between the TTM, tympanic diaphragm, epitympanum, and protympanum could account for the development of Ménière's disease in patients. They used temporal bones from patients with Ménière's disease and determined whether they had developed any otitis media, cholesteatoma, or endolymphatic hydrops. In Study 1, they examined the difference in structure between the TTM and its tendon and the tympanic isthmus. In Study 2, they investigated the structure of the protympanum. The protympanum is the bony portion of the Eustachian tube. In both studies, the measurements of the structures in patients with or without Ménière's disease did not differ significantly. The authors also reported no signs of otitis media, cholesteatoma, or endolymphatic hydrops in any of the patients. This meant that the anatomical differences in these structures do not contribute to the development of Ménière's disease. They determined that the root of Ménière's is not likely to be dysventilation in the middle ear because there were no observable differences in anatomical structure between patients with and without the disease. The results did not support the hypothesis; however, the findings from this research will help to narrow down the possible causes of this condition to be evaluated in future studies. The researchers said that they did not focus particularly on the Eustachian tube as a structure possibly involved in dysventilation in Ménière's disease patients; this could be a potential topic of future research.

### **Conclusion**

The function of the TTM has been strongly debated for years, and despite the numerous research projects conducted there are still many unanswered questions. One of the biggest questions in the research community is whether this muscle is involved in sound damping. All the research papers examined in this comprehensive study agree that the TTM contracts when exposed to self-generated auditory stimuli such as swallowing, speaking, or chewing, and non-auditory stimuli such as a jet of air on to the eye or in anticipation of loud sounds. The earlier hypothesis that the TTM is involved in protecting the ear from loud sounds was not entirely incorrect; however, the muscle does not contract in response to external stimuli such as fireworks. This protective reflex is known as the MEM reflex. Both the stapedius muscle and the TTM are involved in it and have similar fiber compositions; however, each of these muscles has a different role, indicated by their different innervations and specific reflex pathways, as seen in previous studies. The stapedius is the main muscle involved in protecting the ear from external auditory stimuli, as confirmed in the study showing that the MEM reflex could no longer be elicited in patients who had lost stapedius muscle function.

TTM contraction results in low frequency conductive hearing loss while modulating the passage of sound through the middle ear. The 2017 study by Wickens et al. [3] provided evidence for sound impedance during TTM contraction in volunteers; however, it could be difficult to replicate owing to the small number of participants, results being gathered from only one ear, and tests being conducted at different times. Since the capacity for voluntary contraction of the TTM is rare, larger studies on this topic could be difficult to perform.

Future studies in this field should include investigating structural differences in the Eustachian tube between patients with and without Ménière's disease, examining patients with tinnitus to observe if they can contract their TTM voluntarily, and conducting further research on patients diagnosed with an otological disease to see if a response is elicited by non-auditory stimuli. In addition, studying patients who have lost TTM function would be helpful to determine if this muscle is responsible for other functions in the ear.

## ORCID

Alexis Edmonson: <https://orcid.org/0000-0001-5157-5953>  
 Joe Iwanaga: <https://orcid.org/0000-0002-8502-7952>  
 Łukasz Olewnik: <https://orcid.org/0000-0002-6414-9504>  
 Aaron S. Dumont: <https://orcid.org/0000-0002-8077-8992>  
 R. Shane Tubbs: <https://orcid.org/0000-0003-1317-1047>

## Author Contributions

Conceptualization: RST, JI. Data acquisition: RST, JI. Data analysis or interpretation: AE, LO, ASD. Drafting of the manuscript: AE, JI, LO. Critical revision of the manuscript: ASD, RST. Approval of the final version of the manuscript: all authors.

## Conflicts of Interest

No potential conflict of interest relevant to this article was reported.

## References

- Møller AR. Hearing: anatomy, physiology, and disorders of the auditory system. 2nd ed. Amsterdam: Elsevier; 2006.
- Standring S. Gray's anatomy: the anatomical basis of clinical practice. 41st ed. London: Elsevier; 2015.
- Wickens B, Floyd D, Bance M. Audiometric findings with voluntary tensor tympani contraction. *J Otolaryngol Head Neck Surg* 2017;46:2.
- Azuma T, Nogaki T, Schachern P, Paparella MM, Cureoglu S. Structural analysis of tensor tympani muscle, tympanic diaphragm, epitympanum, and protympanum in Menière's disease: a human temporal bone study. *Otol Neurotol* 2018;39:499-505.
- Mascarello F, Veggetti A, Cerpenè E, Rowlerson A. An immunohistochemical study of the middle ear muscles of some carnivores and primates, with special reference to the IIM and slow-tonic fibre types. *J Anat* 1983;137(Pt 1):95-108.
- Mukerji S, Windsor AM, Lee DJ. Auditory brainstem circuits that mediate the middle ear muscle reflex. *Trends Amplif* 2010;14:170-91.
- Borg E, Counter SA, Rösler G. Theories of middle-ear muscle functions. In: Silman S, editor. *The Acoustic Reflex*. London: Academic Press; 1984. p.63-99.
- Møller AR. Neurophysiological basis of the acoustic middle-ear reflex. In: Silman S, editor. *The Acoustic Reflex*. London: Academic Press; 1984. p.1-34.
- Stach BA, Jerger JF, Jenkins HA. The human acoustic tensor tympani reflex. A case report. *Scand Audiol* 1984;13:93-9.
- Benson TE, Lee DJ, Brown MC. Tensor tympani motoneurons receive mostly excitatory synaptic inputs. *Anat Rec (Hoboken)* 2013;296:133-45.
- Salomon G, Starr A. Electromyography of middle ear muscles in man during motor activities. *Acta Neurol Scand* 1963;39:161-8.
- van den Berge H, Kingma H, Kluge C, Marres EH. Electrophysiological aspects of the middle ear muscle reflex in the rat: latency, rise time and effect on sound transmission. *Hear Res* 1990;48:209-19.
- Gelfand SA. The contralateral acoustic-reflex threshold. In: Silman S, editor. *The Acoustic Reflex*. London: Academic Press; 1984. p.137-86.
- Horner KC. The tensor tympani muscle reflex in the mouse. *Hear Res* 1986;24:117-23.
- Relkin EM, Sterns A, Azeredo W, Prieve BA, Woods CI. Physiological mechanisms of onset adaptation and contralateral suppression of DPOAEs in the rat. *J Assoc Res Otolaryngol* 2005;6:119-35.
- Rodríguez-Vázquez JF, Sakiyama K, Abe H, Amano O, Murakami G. Fetal tendinous connection between the tensor tympani and tensor veli palatini muscles: a single digastric muscle acting for morphogenesis of the cranial base. *Anat Rec (Hoboken)* 2016;299:474-83.
- Maynard TM, Zohn IE, Moody SA, LaMantia AS. Suckling, feeding, and swallowing: behaviors, circuits, and targets for neurodevelopmental pathology. *Annu Rev Neurosci* 2020;43:315-36.
- Djupesland G. Middle ear muscle reflexes elicited by acoustic and nonacoustic stimulation. *Acta Otolaryngol* 1964;57(Suppl 188):287-92.
- Bance M, Makki FM, Garland P, Alian WA, van Wijhe RG, Savage J. Effects of tensor tympani muscle contraction on the middle ear and markers of a contracted muscle. *Laryngoscope* 2013;123:1021-7.