

Case Report

Clin Shoulder Elbow 2022;25(3):236-239
<https://doi.org/10.5397/cise.2021.00500>

eISSN 2288-8721

Intraoperative pulmonary embolism in shoulder arthroscopy in a patient with previous SARS-CoV-2 infection: a case report

Alejandro Holgado-Rodriguez de Lizana, Alberto Izquierdo-Fernandez, Jesus Manuel Mendez-Sanchez, Jose Carlos Diaz-Miñarro

Orthopaedics and Traumatology Unit, Reina Sofia University Hospital, Cordoba, Spain

The objective of this article is to describe intraoperative pulmonary embolism during shoulder arthroscopy in a patient with previous severe acute respiratory syndrome coronavirus 2 (SARS-CoV-2) infection. Further, we describe how the pandemic has influenced the population by increasing the rate of embolisms. Awareness of such cases will help to increase knowledge regarding SARS-Cov-2 and to determine if such patients should receive routine antithrombotic prophylaxis.

Keywords: Shoulder; Arthroscopy; Embolism; SARS-CoV-2; Surgery; Immunoglobulin G

Shoulder arthroscopy has experienced tremendous growth since the first clinical publication on this technique by Andren and Lundberg in 1965 [1]. The complications reported in the literature are scarce and usually limited to case series. Indeed, the first report on complications among 14,329 shoulder arthroscopies by Small in 1986 [2]. Some were classified as anesthesia-related, such as airway compromise, pneumothorax, and air embolism. General surgical complications included infection, neurovascular traction injury, and thromboembolism. Technical complications specific to shoulder arthroscopy were more frequent, including stiffness and fluid extravasation.

Venous thrombosis after shoulder arthroscopy is rare, observed in less than 1% of all cases [3]. There is no substantial evidence to support routine use of anticoagulants after surgery [4]. The current severe acute respiratory syndrome coronavirus 2

(SARS-CoV-2) pandemic has raised concern about the increased cases of thromboembolic disease in infected patients. Through microvascular activity, the virus seems to stimulate a strong response that lead to thromboembolic phenomena [5].

In our hospital, 48 hours prior to surgery, patients undergo a nasopharyngeal swab to detect SARS-CoV-2 RNA. This new protocol was established in 2020 and is subject to continuous change as the pandemic evolves. The objective of this article is to describe intraoperative pulmonary embolism during shoulder arthroscopy in a patient with previous SARS-CoV-2 infection.

CASE REPORT

We conducted this study in compliance with the principles of the Declaration of Helsinki. The study protocol was reviewed and

Received: September 21, 2021 Revised: October 17, 2021 Accepted: October 26, 2021

Correspondence to: Alejandro Holgado-Rodriguez de Lizana

Orthopaedics and Traumatology Unit, Reina Sofia University Hospital, Avenida Menéndez Pidal S/N, Cordoba, Spain

Tel: +34-667-715-560, E-mail: alx_holgado@hotmail.com, ORCID: <https://orcid.org/0000-0003-4631-7014>

Financial support: None.

Conflict of interest: None.

Copyright© 2022 Korean Shoulder and Elbow Society.

This is an Open Access article distributed under the terms of the Creative Commons Attribution Non-Commercial License (<http://creativecommons.org/licenses/by-nc/4.0/>) which permits unrestricted non-commercial use, distribution, and reproduction in any medium, provided the original work is properly cited.

approved by Reina Sofia University Hospital's Ethics Committee. Written informed consent was obtained.

A 45-year-old male patient with no personal history of interest except morbid obesity (body mass index [BMI], 39.45 kg/m²) received arthroscopic shoulder surgery. The patient was not receiving anticoagulant therapy, nor had he suffered any previous thrombotic episode. The patient is right-handed and presented with pain in the right shoulder deltoid area, which had been present for one year. Clinical examination showed complete passive and active range of motion. Shoulder flexion range of 120°, extension of 80°, and abduction range of 125° were observed in passive and active motion. The Hawkins and Neer's tests were both positive. The Jobe test was positive, while the Gerber test was negative. Shoulder X-rays showed no acute or chronic alterations. Ultrasound was inconclusive due to poor visualization caused by excessive subcutaneous cellular tissue. Magnetic resonance imaging showed a 6×4-mm-thick partial tear of the articular side of the supraspinatus, with no other alterations except subacromial-subdeltoid and subcoracoid bursitis (Fig. 1). Conservative treatment was performed with physiotherapy for 6 months, and then two injections with corticosteroids were administered without clinical improvement. After exhausting the conservative approach, we performed for surgical intervention once informed consent had been obtained. Preoperatively, the patient showed 43 points on the Constant test and eight of 10 on the visual analogue scale for pain. A polymerase chain reaction (PCR) test for SARS-CoV-2 was performed 48 hours prior to surgery, and the result was negative. In addition, the patient had

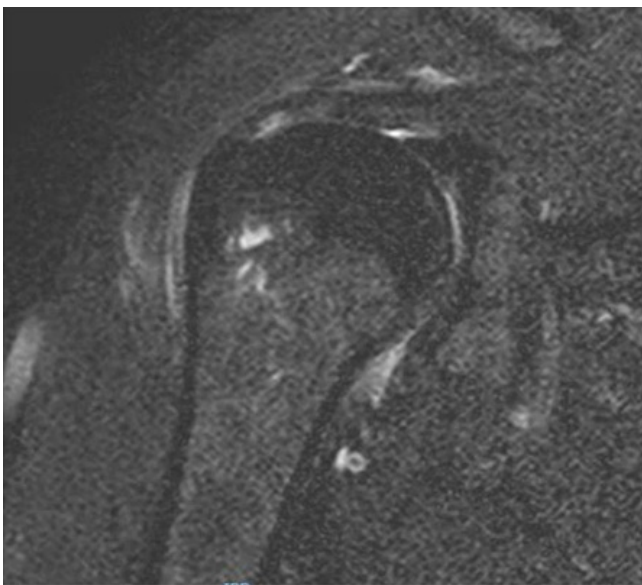


Fig. 1. A 6×4-mm-thick partial tear of the joint margin of the supraspinatus.

no symptoms associated with SARS-CoV-2 virus infection.

Under general anesthesia, we performed arthroscopy with the patient in the left lateral decubitus position, using posterior and anterolateral portals. Debridement of the partially ruptured supraspinatus articular side, bursectomy, and sectioning of the coracoacromial ligament were performed. Operative time was 45 minutes. Anti-thrombotic prophylaxis measures such as compression devices were not used during surgery since they are not established for routine use in our hospital.

During awakening, the patient suffered an episode of low cardiac output with respiratory failure, requiring continuous mechanical ventilation with orotracheal intubation. The patient was transferred to the intensive care unit (ICU). Upon arrival, the patient showed signs of poor perfusion and oxygenation with hemodynamic instability (heart rate of 115 BPM and blood pressure of 50/30 mmHg) despite vasoactive amine perfusion. O₂ saturation was 86%. Electrocardiogram showed negative T waves in V1-V2-V3 and a D-dimer of 16,000 (normal 0–500 ng/mL). Chest computed tomography (CT) angiography showed a contrast repletion defect related to pulmonary thromboembolism in the subsegmental branch of the left upper lobe and subsegmental branch of the right upper lobe (Fig. 2).

The patient required mechanical ventilation, treatment with vasoactive drugs, and anticoagulation with heparin at therapeutic doses. On the fourth day of admission to the ICU, the patient was extubated and presented incoherent speech consistent with motor dysphasia. Follow-up by neurology was requested, and cranial CT scan+angio-CT scan+perfusion CT scan showed no evidence of ischemic lesions; occlusion of large arteries; or atheromatous plaques or stenosis and no asymmetries in the perfusion maps. The patient was diagnosed with encephalopathy of probable toxic metabolic origin.

During the hospital stay, a coagulation study showed no alterations in coagulation, and CT angiography of supra-aortic trunk and upper extremity was normal. SARS-CoV-2 serology was performed 48 hours after surgery, and immunoglobulin G antibodies were positive, indicating prior infection. Tests for immunoglobulin M (IgM) antibodies were negative. The patient had presented no SARS-CoV-2 infection-related symptoms during 2020, nor was he aware of having the disease. The patient had not received the SARS-CoV-2 vaccine. With no clear etiology and no prothrombotic risk factors other than obesity (the patient had no history of thrombotic episodes or family history of thrombosis, and operative time was less than 90 minutes), we suggest that the pulmonary thromboembolism was a result of past COVID-19 infection.

After being treated with a multi-disciplinary approach involv-

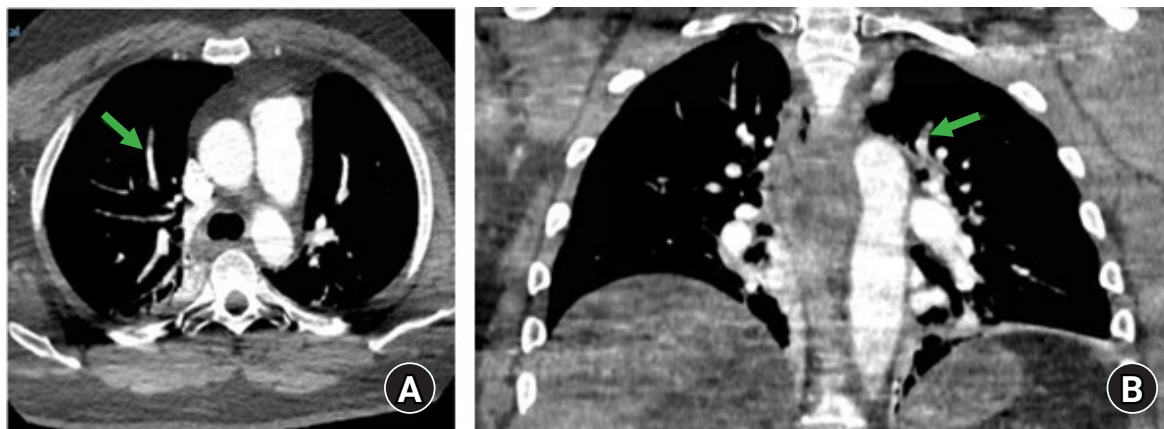


Fig. 2. (A) The green arrow points at a subsegmental branch of the right upper lobe related to pulmonary thromboembolism. (B) The green arrow points at a contrast repletion defect in the subsegmental branch of the left upper lobe.

ing internal medicine, neurology, and traumatology, and when the patient's condition was stable, he was discharged from the hospital. Currently, 6 months after surgery, the patient is undergoing rehabilitation aimed at improving his neurological condition.

DISCUSSION

Emergence of a new coronavirus has triggered major changes in all areas of life, including the hospital setting. Orthopedic surgery and traumatology services in our hospital suspended all scheduled activities, devoting themselves exclusively to emergency pathology. As the incidence rate decreased, new scheduled operations were incorporated following the protocols implemented that year to detect SARS-CoV-2. As we mentioned, all patients preparing for surgical intervention at our center receive a PCR test within 48 hours prior to surgery. The sensitivity and specificity of this test are 71%–98% and 95%, respectively.

The 2020 pandemic has resulted in a vast scope of work, and we found a study similar to ours involving pulmonary thromboembolism in a patient who underwent shoulder arthroscopy and showed a positive PCR result for SARS-CoV-2 at three days after the operation. Unlike in our study, that patient was IgM positive [6]. Numerous studies have shown that hospitalized COVID-19 positive patients are more likely to experience deep vein thrombosis and pulmonary disease than are those who do not have the disease. In addition, such patients have longer ICU stays and a higher mortality rate [7].

There are isolated case reports of thromboembolic disease following shoulder arthroscopy [8,9]. Sager et al. [4] reported that BMI greater than 30 is a risk factor associated with venous thromboembolism after rotator cuff repair. Burkhart [10] reported a case of complete thrombosis of the basilic vein after shoul-

der arthroscopy. Further evaluation of the patient revealed previously undiagnosed Hodgkin disease. The venous thrombosis was attributed to a hypercoagulable state. Given the rarity of thromboembolic disease, the author recommended evaluation of systemic and local disturbances in cases of occurrence.

Polzhofer et al. [3] reported an isolated case of pulmonary embolism after arthroscopic subacromial decompression. In that patient, neither coagulopathy nor anatomical changes were observed. With no clear etiology, the authors [3] suggested that the cause of the subclavian irritation could have been compression with a powered aspirator.

Although extremely rare, thromboembolic disease can occur after shoulder arthroscopy. Awareness and early detection are the best approach to this serious complication. Currently, antithrombotic prophylaxis is not recommended in shoulder arthroscopy; however, due to the changes in circumstances, prior COVID-19 infection should be considered in selected patients.

We report a case of thromboembolism during shoulder arthroscopy and discuss the increase of such cases during the COVID-19 pandemic. Such cases will help increase our knowledge about the effects of the SARS-CoV-2 virus and reflect on whether or not such patients should receive routine antithrombotic prophylaxis before surgery.

ORCID

Alejandro Holgado-Rodríguez de Lizana

<https://orcid.org/0000-0003-4631-7014>

Alberto Izquierdo-Fernandez

<https://orcid.org/0000-0002-4270-0852>

Jesus Manuel Mendez-Sanchez

<https://orcid.org/0000-0002-5445-5874>

<https://doi.org/10.5397/cise.2021.00500>

Jose Carlos Diaz-Miñarro <https://orcid.org/0000-0002-4491-0124>

REFERENCES

1. Andren L, Lundberg BJ. Treatment of rigid shoulders by joint distension during arthrography. *Acta Orthop Scand* 1965;36:45-53.
2. Small NC. Complications in arthroscopy: the knee and other joints. Committee on Complications of the Arthroscopy Association of North America. *Arthroscopy* 1986;2:253-8.
3. Polzhofer GK, Petersen W, Hassenpflug J. Thromboembolic complication after arthroscopic shoulder surgery. *Arthroscopy* 2003;19:E129-32.
4. Sager B, Ahn J, Tran J, Khazzam M. Timing and risk factors for venous thromboembolism after rotator cuff repair in the 30-day perioperative period. *Arthroscopy* 2019;35:3011-8.
5. Goswami J, MacArthur TA, Sridharan M, et al. A review of pathophysiology, clinical features, and management options of COVID-19 associated coagulopathy. *Shock* 2021;55:700-16.
6. Chauhan A, Villacis D, Boente R, Romeo AA. Venous thromboembolism after arthroscopic rotator cuff repair in a patient with a negative presurgical SARS-CoV-2 test who developed symptomatic COVID-19 three days after surgery. *J Shoulder Elbow Surg* 2021;30:e251-5.
7. Chang H, Rockman CB, Jacobowitz GR, et al. Deep vein thrombosis in hospitalized patients with coronavirus disease 2019. *J Vasc Surg Venous Lymphat Disord* 2021;9:597-604.
8. Starch DW, Clevenger CE, Slauterbeck JR. Thrombosis of the brachial vein and pulmonary embolism after subacromial decompression of the shoulder. *Orthopedics* 2001;24:63-5.
9. Yagnatovsky M, Dai AZ, Zacchilli M, Jazrawi LM. Acute pulmonary embolism after arthroscopic glenoid labral repair and subacromial decompression: case report and review of the literature. *Phys Sportsmed* 2018;46:135-8.
10. Burkhart SS. Deep venous thrombosis after shoulder arthroscopy. *Arthroscopy* 1990;6:61-3.