

The humeral suspension technique: a novel operation for deltoid paralysis

Stijn GCJ de Joode^{1,2,3}, Ralf Walbeehm¹, Martijn GM Schotanus^{1,3,4}, Ferry A van Nie⁵,
Lodewijk W van Rhijn^{3,4}, Steven K Samijo¹

¹Department of Orthopedic Surgery and Traumatology, Zuyderland Medical Center, Sittard-Heerlen, The Netherlands

²Department of Orthopedic Surgery, Balgrist University Hospital, Zürich, Switzerland

³School of Care and Public Health Research Institute (CAPHRI), Faculty of Health, Medicine and Life Sciences, Maastricht, The Netherlands

⁴Department of Orthopedic Surgery and Traumatology, Maastricht University Medical Center, Maastricht, The Netherlands

⁵Department of Neurosurgery, Zuyderland Medical Center, Heerlen, The Netherlands

Isolated deltoid paralysis is a rare pathology that can occur after axillary nerve injury due to shoulder trauma or infection. This condition leads to loss of deltoid function that can cause glenohumeral instability and inferior subluxation, resulting in rotator cuff muscle fatigue and pain. To establish dynamic glenohumeral stability, a novel technique was invented. Humeral suspension is achieved using a double button implant with non-resorbable high strength cords between the acromion and humeral head. This novel technique was used in two patients with isolated deltoid paralysis due to axillary nerve injury. The results indicate that the humeral suspension technique is a method that supports centralizing the humeral head and simultaneously dynamically stabilizes the glenohumeral joint. This approach yielded high patient satisfaction and reduced pain. Glenohumeral alignment was improved and remained intact 5 years postoperative. The humeral suspension technique is a promising surgical method for subluxated glenohumeral joint instability due to isolated deltoid paralysis.

Keywords: Deltoid muscle paralysis; Humeral suspension technique; Brachial plexus neuropathies; Axillary nerve injury; Glenohumeral instability

Isolated deltoid paralysis can occur after axillary nerve injury due to lateral traction on the patient's neck or shoulder trauma. Less common causes are infection leading to brachial plexus neuritis and the quadrilateral space syndrome [1]. The interplay between the rotator cuff muscles and the deltoid enables stability of the glenohumeral joint. In the case of deltoid paralysis with a normal rotator cuff, shoulder function can be maintained, although glenohumeral stability may be reduced. As a consequence, the rota-

tor cuff muscles will be easily exhausted by repetitive shoulder movements [1,2]. This can lead to pain, fatigability in the shoulder region, and positive sulcus sign due to inferior glenohumeral subluxation. In addition, sensibility loss over the lateral aspect of the shoulder can be observed [2]. To clinically diagnose deltoid paralysis, three tests can be used: the Bertelli test, the swallowtail test, and the deltoid extension lag test, of which the Bertelli test is the most reliable [2,3]. Within 2–4 weeks after trauma, electro-

Received: October 16, 2021 Revised: January 6, 2022 Accepted: January 13, 2022

Correspondence to: Stijn GCJ de Joode

Department of Orthopedic Surgery and Traumatology, Zuyderland Medical Center, Dr. H. van der Hoffplein 1, PO Box 5500, 6162 BG Sittard-Geleen, The Netherlands

Tel: +31-6-22829553, E-mail: sdejoode55@gmail.com, ORCID: <https://orcid.org/0000-0002-8217-0120>

Financial support: None.

Conflict of interest: None.

Copyright© 2022 Korean Shoulder and Elbow Society.

This is an Open Access article distributed under the terms of the Creative Commons Attribution Non-Commercial License (<http://creativecommons.org/licenses/by-nc/4.0/>) which permits unrestricted non-commercial use, distribution, and reproduction in any medium, provided the original work is properly cited.

myography should be performed to confirm the diagnosis and to establish baseline values. After diagnosing deltoid paralysis, conservative treatment with physiotherapy should be started to preserve shoulder strength and mobility [1]. Most axillary nerve lesions recover spontaneously. However, if no clinical improvements are seen after 3 months, neurosurgery should be considered. Neurolysis, neurorrhaphy, nerve grafting, and nerve transfers are described as surgical options and should be performed within 6 months after injury [1,4]. After primary surgical reconstruction, secondary surgical procedures, such as a trapezius tendon transfer [5], biceps tendon transfer [6], pectoralis major inverse plasty [7], and latissimus dorsi tendon transfer [8] may be of added value to improve upper extremity function. Reverse shoulder arthroplasty combined with pectoralis major and trapezius transfer is another surgical option for deltoid paralysis patients [9]. These secondary surgical procedures lead to partial or complete loss of the original function of the transferred muscle. As a last surgical option, glenohumeral arthrodesis can reduce pain and create stability, but does decrease shoulder range of motion [10].

Two male patients aged 47 and 79 years old presented to our institution with shoulder pain and isolated deltoid paralysis combined with glenohumeral subluxation and instability due to traumatic axillary nerve injury (Fig. 1). Their shoulder pain could be relieved by pushing the humerus cranially, thereby aligning the humeral head in an improved glenohumeral position. Glenohumeral alignment and stability were improved by humeral suspen-

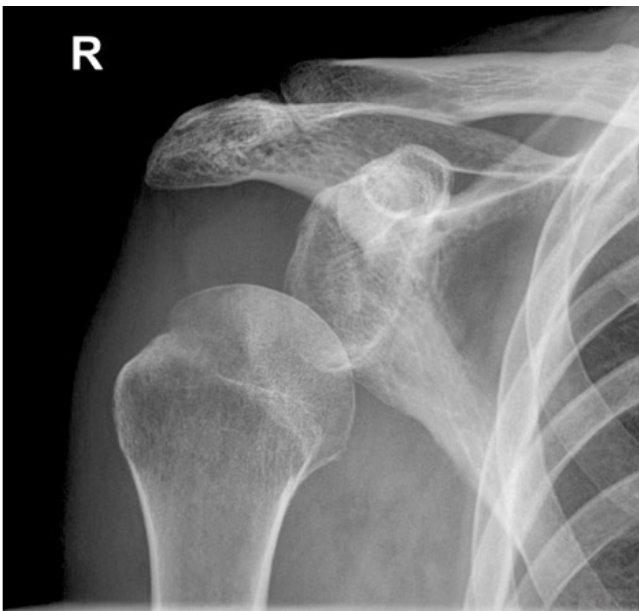


Fig. 1. Preoperative anteroposterior X-ray of the right shoulder of patient 1 with inferior subluxation.

sion, which leads to less stretching of the brachial plexus and shoulder muscles. To establish dynamic stabilization and suspension of the glenohumeral joint in deltoid paralyzed patients, a novel surgical technique was developed.

The study protocol was approved by the Institutional Review Board of METC Zuyderland Medical Center (File nr. 2021021) and written informed consent was obtained from all patients. In this article, we present this new operation technique and its promising short-term follow-up results.

TECHNIQUE

A standard anterior deltopectoral approach is used. An incision is made from the coracoid process, which extends distally for 8 cm to the upper arm. Subcutaneously, the plane between the deltoid and pectoralis major is opened, whereby the cephalic vein is preserved. Releasing fibrotic adhesions in the subdeltoid space. The humeral head is then moved anterior in a subluxated position, which is not difficult because of glenohumeral laxity. Inspection of the rotator cuff muscles is performed to ensure there are no rotator cuff tears. A second incision 2 cm in length is made at the midline of the lateral border of the acromion medial to lateral with dissection on the acromion bone.

Two bicortical holes 3 mm in diameter are made in the acromion. The two ends of the Fibertape (Arthrex, Naples, FL, USA) are channeled through an AC Dog Bone Button (Arthrex) and then the two ends are channeled from cranial to caudal through the acromion. This step is repeated for the other bicortical hole in the acromion. Divergent drilling of 4 monocortical holes 3

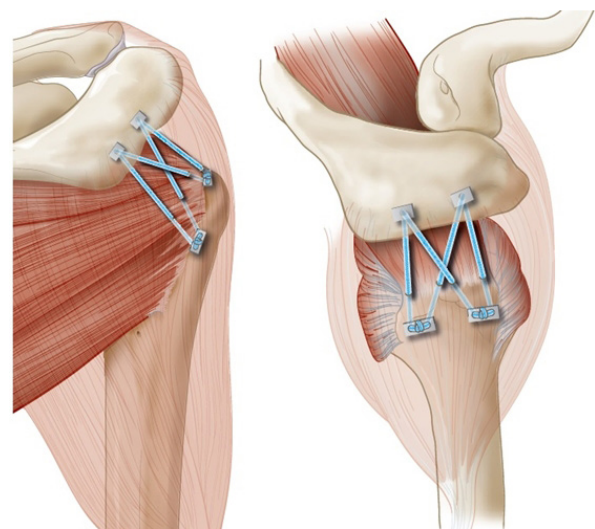


Fig. 2. Anteroposterior and lateral views of the right shoulder with Fibertape channeled through the acromion and proximal humerus.

mm in diameter is performed at the footprint of the greater tubercle. Drill hole is made anterolateral at the insertion of the superior glenohumeral ligament, and drill hole 2 is made 1 cm lateral of hole 1. Holes 3 and 4 are drilled on the posterolateral side of the greater tubercle, whereby hole 4 is made between the insertion of the infraspinatus and supraspinatus and hole 3 1 cm anterior to it. The next step is channeling the Fibertape anterior to posterior through the drill holes. The first Fibertape is channeled through holes 1 and 3 and the second Fibertape through holes 2 and 4, then the ends of the Fibertape are channeled through an AC Dog Bone and tightened from posterior to anterior (Fig. 2). Attention should be paid to alignment of the center of the humeral head with the glenoid fossa to prevent overtightening so that at abduction there is no impingement of the major tubercle at the acromion and internal rotation is still possible to the buttock, while external rotation in adduction is still possible for at least 30°. The glenohumeral anterior-posterior translation is tested, followed by rinsing, closing, and dressing the wound.

Postoperative, the shoulder is immobilized in a sling for 2 weeks without mobilization restrictions. Clinical and radiological evaluation should be conducted at 2, 6 and 12 months postoperative.

DISCUSSION

This novel surgical technique is a method to suspend the humeral head and dynamically stabilize the glenohumeral joint in deltoid paralysis. This technique can improve glenohumeral alignment, which may lead to improved function of the rotator cuff muscles, less fatigue, less pain, and less elongation of the brachial plexus and joint capsule. The basic idea is to reconstruct the function of the glenohumeral ligaments through tensioning of the deltoid. Although native tensioning cannot be imitated, this technique does not disturb the original function of shoulder musculature as is the case in tendon transfers. In addition, the theoretical risk of elongation of the transferred tendon is eliminated. Also, this technique maintains the option for future tendon transfer, shoulder arthroplasty, or glenohumeral arthrodesis if shoulder function is not improved, since no structural changes are made to the original anatomy.

The postoperative results were promising, with a numeric rating scale (NRS) for patient satisfaction of 9 and 8 for patients 1 and 2, respectively. Pain was reduced from NRS 9 to 1 and NRS 8 to 6 for patients 1 and 2, respectively. Both patients reported that they would undergo the operation again if they were in the same situation as before. As is shown in Fig. 3, there was no elongation of the Fibertape, and glenohumeral alignment remained intact

after 5 years of follow-up. At the final follow-up, shoulder function was measured using the Disabilities of the Arm, Shoulder and Hand (DASH) and Constant-Murley scores. DASH score was 29 and 32 and Constant-Murley score was 56 and 22 for patients 1 and 2, respectively. No complications were reported.

It should be emphasized that the indication for this novel technique is pain that originates from muscle and tendon fatigue, and not from a neurological cause. If the pain is relieved by manually suspending the upper arm, this novel humeral suspension technique could be of value.

A contraindication for this technique is omarthrosis, since pain will not be reduced with this novel technique in these patients. Whether partial deltoid paralysis should be a contraindication for this technique remains unclear. It is hypothesized that such a muscular imbalance in different parts of the deltoid could affect active and passive shoulder function. Whether patients with anatomical glenohumeral arthroplasty or patients with os acromiale are candidates for this technique remains to be determined.

Possible drawbacks of this technique may be that in time, elongation or rupture of the Fibertape could occur. Another limitation is channeling of the Dog Bone through the acromion due to constant loading. Whether the amount of stabilization and suspension of the glenohumeral joint remains consistent during shoulder abduction is also unclear, since Fibertape tension is reduced due to the position of the upper arm. However, deltoid tension is anatomically reduced in abduction and neither patient

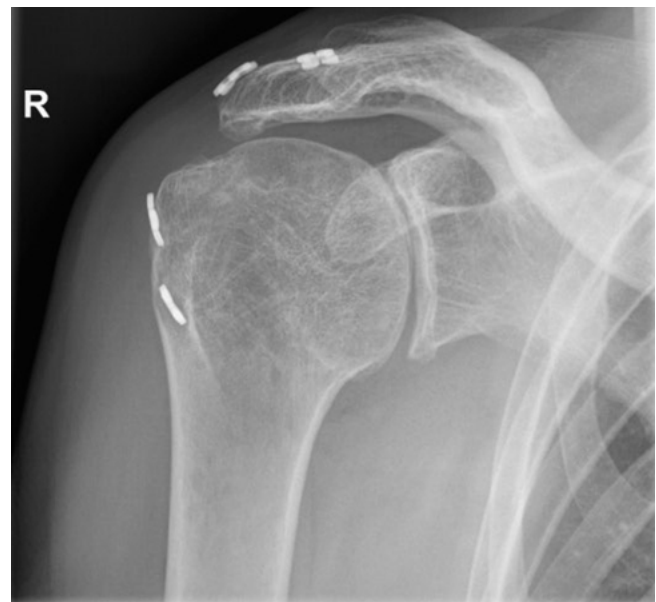


Fig. 3. Anteroposterior X-ray of the right shoulder of patient 1 at postoperative 5 years.

mentioned a feeling of subluxation during shoulder abduction or flexion. The preliminary outcomes of this new technique are promising; however, more research with a larger study population is needed to identify the short- and long-term results of this technique.

ORCID

Stijn GCJ de Joode <https://orcid.org/0000-0002-8217-0120>
 Martijn GM Schotanus <https://orcid.org/0000-0002-3975-6337>

REFERENCES

1. Steinmann SP, Moran EA. Axillary nerve injury: diagnosis and treatment. *J Am Acad Orthop Surg* 2001;9:328-35.
2. Werthel JD, Bertelli J, Elhassan BT. Shoulder function in patients with deltoid paralysis and intact rotator cuff. *Orthop Traumatol Surg Res* 2017;103:869-73.
3. Bertelli JA, Ghizoni MF. Abduction in internal rotation: a test for the diagnosis of axillary nerve palsy. *J Hand Surg Am* 2011; 36:2017-23.
4. Koshy JC, Agrawal NA, Seruya M. Nerve transfer versus interpositional nerve graft reconstruction for posttraumatic, isolated axillary nerve injuries: a systematic review. *Plast Reconstr Surg* 2017;140:953-60.
5. Kotwal PP, Mittal R, Malhotra R. Trapezius transfer for deltoid paralysis. *J Bone Joint Surg Br* 1998;80:114-6.
6. Namdari S, Keenan MA. Outcomes of the biceps suspension procedure for painful inferior glenohumeral subluxation in hemiplegic patients. *J Bone Joint Surg Am* 2010;92:2589-97.
7. Resch H, Povacz P, Maurer H, Koller H, Tauber M. Pectoralis major inverse plasty for functional reconstruction in patients with anterolateral deltoid deficiency. *J Bone Joint Surg Br* 2008;90:757-63.
8. Itoh Y, Sasaki T, Ishiguro T, Uchinishi K, Yabe Y, Fukuda H. Transfer of latissimus dorsi to replace a paralysed anterior deltoid: a new technique using an inverted pedicled graft. *J Bone Joint Surg Br* 1987;69:647-51.
9. Kermarrec G, Werthel JD, Canales P, Valenti P. Review and clinical presentation in reverse shoulder arthroplasty in deltoid palsy. *Eur J Orthop Surg Traumatol* 2018;28:747-51.
10. Wagner ER, McLaughlin R, Sarfani S, et al. Long-term outcomes of glenohumeral arthrodesis. *J Bone Joint Surg Am* 2018; 100:598-604.