

Case Report

pISSN 2466-1384 · eISSN 2466-1392
Korean J Vet Res 2022;62(3):e22
<https://doi.org/10.14405/kjvr.20220006>

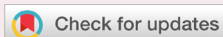*Corresponding author:

Jin-Young Chung
Department of Veterinary Internal Medicine
and Institute of Veterinary Science, College
of Veterinary Medicine, Kangwon National
University, 1 Gangwondaehak-gil,
Chuncheon 24341, Korea
Tel: +82-33-250-8656
Fax: +82-33-259-5625
E-mail: jychung77@gmail.com

ORCID:
<https://orcid.org/0000-0001-6729-9834>

Conflict of interest:
The authors declare no conflict of interest.

Received: May 3, 2022
Revised: Jun 13, 2022
Accepted: Jul 20, 2022



© 2022 The Korean Society of Veterinary Science.
© This is an open-access article distributed under the terms of the Creative Commons Attribution Non-Commercial license (<http://creativecommons.org/licenses/by-nc/4.0/>), which permits unrestricted non-commercial use, distribution, and reproduction in any medium, provided the original work is properly cited.

Sodium nitroprusside on acute cardiogenic pulmonary edema in dogs: case reports

Mangil Han^{1,2}, Yoonhwan Kim¹, Yunho Jeong¹, Jin-Ok Ahn¹,
Jin-Young Chung^{1,*}

¹Department of Veterinary Internal Medicine and Institute of Veterinary Science, College of Veterinary Medicine, Kangwon National University, Chuncheon 24341, Korea
²W Animal Medical Center, Seoul 04029, Korea

Abstract

This study reports the efficacy of the vasodilator sodium nitroprusside (SNP), for treatment of acute cardiogenic pulmonary edema in dogs. For this study, the patients were divided into the SNP only treatment group, the SNP, furosemide and dobutamine treatment group, and non-SNP treatment group. Seven dogs, 6 dogs and 2 dogs were favorable responders in SNP only group, group with SNP, furosemide and dobutamine and non-SNP treatment group, each. The results of this study suggest that SNP can be an effective alternative therapy for dogs with acute cardiogenic pulmonary edema.

Keywords: cardiogenic pulmonary edema; dogs; sodium nitroprusside

Pulmonary edema, which is an abnormal accumulation of extravascular lung water [1], is not a disease, but a consequence of disease. The mechanism of pulmonary edema is same as general mechanisms that cause edema elsewhere in the body. Major mechanisms of pulmonary edema include decreased plasma oncotic pressure, vascular overload, lymphatic obstruction and increased vascular permeability [2]. The disorders that produce these problems can be divided into cardiogenic and non-cardiogenic causes. Because the therapies used to treat cardiogenic and non-cardiogenic pulmonary edema differ, the cause of pulmonary edema should be confirmed prior to treatment. The factors predisposing development of non-cardiogenic pulmonary edema are neurogenic pulmonary edema, post-obstructive pulmonary edema, systemic diseases (e.g., sepsis, shock, uremia), direct pulmonary injury, profound hypoalbuminemia, and impaired lymphatic drainage. Conversely, cardiogenic edema, which follows increased venous pulmonary hydrostatic pressure associated with left-sided heart failure, is treated by diuretic administration, afterload reduction, and any specific therapy aimed at treating congestive heart failure. Common causes of left-sided heart failure include dilated cardiomyopathy, acquired mitral valve regurgitation, and hypertrophic cardiomyopathy [3].

The clinical features of pulmonary edema are cough, tachypnea and respiratory distress. Respiratory distress is a syndrome in which seriously ill patients develop acute hypoxemic respiratory failure, which is an emergency situation [4]. Pulmonary edema in most dogs and cats is diagnosed based on typical radiographic changes in the lungs and clinical evidence. Early pulmonary edema assumes an interstitial pattern on radiographs, which progresses to become an alveolar pattern [2].

Vascular permeability edema can usually result in the full range of compromise, which is spontaneously resolved. However, the frequently fatal, fulminant process of acute respiratory distress syndrome can occur after the balance is broken [2]. Acute cardiogenic pulmonary edema, which has one of the most classic and dramatic clinical presentations of any medical disorder [1], is usually treated with oxygen supplement, diuresis, angiotensin converting enzyme (ACE) inhibitors, and positive inotropes [5,6]. However, in some cases, the efficacy of traditional drugs is limited. Direct vasodilators can be beneficial to treatment of patients with pulmonary edema who do not respond to more conservative therapies.

In this study, we evaluated the efficacy of the vasodilator sodium nitroprusside (SNP) for treatment of acute cardiogenic pulmonary edema in dogs and compared with conservative therapies.

This prospective study was based on dogs with acute cardiogenic pulmonary edema secondary to acute congestive heart failure, mitral valve regurgitation (Supplementary Fig. 1). A total of twenty dogs were recruited for this study. Including criteria for SNP (NITROPRESS; Mckesson Pharmaceutical., USA) treatment comprised dogs that had a respiratory rate of 100 breaths per minute, a vertebral heart score (VHS) of more than 10.5 and were diagnosed with acute congestive heart failure. Dogs that had pulmonary edema caused by non-cardiogenic or systemic organ-related diseases including neurological, adrenal, thyroidal, renal, or hepatic disease and neoplasia were excluded. The diagnostic work up consisted of physical examinations, radiography, echocardiography, and hematological examinations, including measurement of electrolyte, blood urea nitrogen and creatinine. Among the recruited dogs with SNP treatment, 9 dogs were treated with SNP only and 7 dogs were treated with SNP, furosemide and dobutamine. The other 4 dogs, which had respiratory rate less than 100 times per minute, as well as the VHS of more than 10.5 and were diagnosed with acute congestive heart failure, were categorized as a group of non-SNP treatment.

The SNP in SNP only group was administered at a dose of 2 µg/kg/min [3]. In the group with SNP, furosemide and dobutamine treatment, the dosage of SNP was 1 µg/kg/min, the dosage of furosemide was 2 mg/kg/h, and the dosage of dobutamine was 5 µg/kg/min. In the non-SNP treatment group only furosemide (2 mg/kg/h) and dobutamine (5 µg/kg/min) were administered. The total period of the administration of SNP were 24 hours.

Changes in the respiratory rate, VHS and blood pressure between before treatment and 24 hours after treatment were ana-

lyzed by the Mann Whitney test. P values were two-tailed and statistical significance was accepted for $p < 0.05$.

In this study, the participants included 4 Schnauzers, 10 Maltese, 1 Cocker Spaniel, 1 ShihTzu, 1 Poodle, 1 Minipin and 2 mixed breed dog. Additionally, 5 were intact females, 6 were spayed females, 3 was an intact male and 6 were castrated males. The mean age was 13.75 years.

The diagnostic work up revealed that dogs suffered from respiratory distress, as indicated by an increased respiratory rate and respiratory crackles. The electrolyte, blood urea nitrogen, and creatinine levels in all dogs were within the normal range. Acute congestive heart failure was diagnosed in all dogs by radiography and echocardiography.

Among 9 dogs in the SNP only group, 7 were favorable responders and survived to discharge. The respiratory rates were significantly decreased ($p = 0.0019$) (Fig. 1) and the VHS and systolic blood pressure were not changed significantly ($p = 0.304$, $p = 0.349$, each) (Figs. 2, 3) in the favorable responders following SNP administration. Two dogs were unfavorable responders with this treatment.

Among 7 dogs in the group with SNP, furosemide and dobutamine, 6 were favorable responders and survived to discharge. The respiratory rates were significantly decreased ($p = 0.0043$) (Fig. 1) and the VHS and systolic blood pressure were not changed significantly ($p = 0.3095$, $p = 0.8051$, each) (Figs. 2, 3) in the favorable responders following SNP administration. One dog was unfavorable responders with this treatment.

In the non-SNP treatment group, the respiratory rates were significantly decreased ($p = 0.0286$) (Fig. 1) and the VHS and

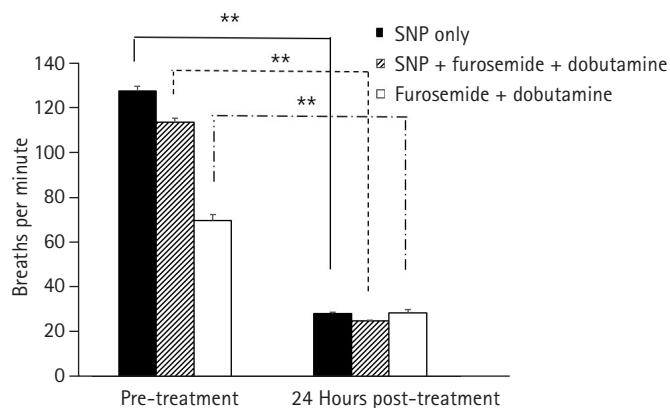


Fig. 1. Comparison of respiratory rate between before treatment and 24 hours after treatment. The respiratory rates in the sodium nitroprusside (SNP) only, SNP + furosemide + dobutamine, and furosemide + dobutamine treatment groups were significantly decreased ($p = 0.0019$; $p = 0.0043$; $p = 0.0286$, each) after 24 hours. ** $p < 0.05$.

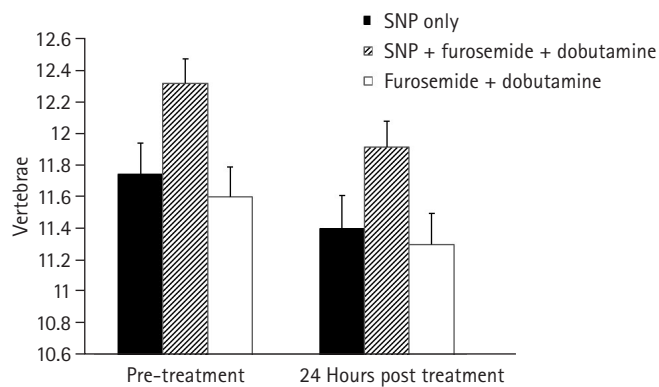


Fig. 2. Comparison of vertebral heart score (VHS) between before treatment and 24 hours after treatment. The VHSs in the sodium nitroprusside (SNP) only, SNP + furosemide + dobutamine, and furosemide + dobutamine treatment groups were not changed significantly ($p = 0.304$, $p = 0.6857$, $p = 0.6857$, each) after 24 hours.

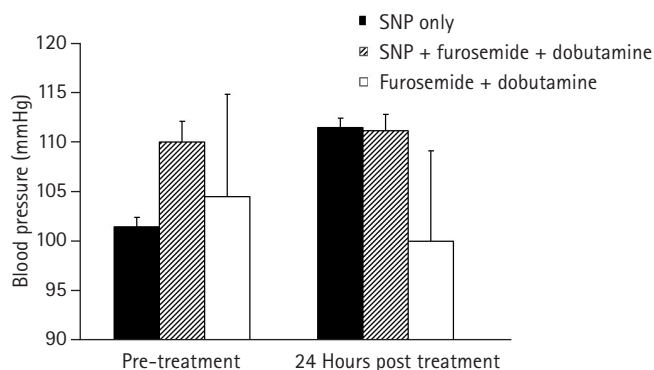


Fig. 3. Comparison of blood pressure between before treatment and 24 hours after treatment. The blood pressures in the sodium nitroprusside (SNP) only, SNP + furosemide + dobutamine, and furosemide + dobutamine treatment groups were not changed significantly ($p = 0.349$, $p = 0.8051$, $p = 1$, each) after 24 hours.

systolic blood pressure were not changed significantly ($p = 0.6857$, $p = 1$, each) (Fig. 2, 3).

Acute cardiogenic pulmonary edema is a common problem in the emergency department of human medicine, with a reported in-hospital mortality of 15% to 20% [1,6]. Although no studies have reported the in-hospital mortality of acute cardiogenic pulmonary edema in veterinary medicine, it is assumed that there is high mortality with acute cardiogenic pulmonary edema.

Acute cardiogenic pulmonary edema is a major medical disorder that shows dramatic clinical presentation. Therefore, rapid response for alleviation of the clinical signs is important and the goal of therapy for acute pulmonary edema is to decrease pulmonary capillary and venous pressure by removing fluid from the body or shifting fluid to other vascular areas [1].

Although diuretics and ACE inhibitors are the first line treatments and good for alleviation of cardiogenic pulmonary edema, sometimes they produce results that are not satisfactory. Additionally, treatment with diuretics is problematic because many patients continue to have systemic congestion, even with an initial symptomatic response [7]. Moreover, treatment with ACE inhibitors usually requires more immediate afterload reduction for acute cardiogenic pulmonary edema [2].

Several studies have suggested that vasodilators provide more benefit than traditional drugs for treatment of cardiogenic pulmonary edema [1,2,6]. Vasodilators can reduce pulmonary edema by increasing systemic venous capacitance, lowering pulmonary venous pressure, and reducing systemic arterial resistance. We applied SNP in this study, which is a potent arteriolar and venous dilator that acts directly on vascular smooth muscle. Additionally, SNP is a basic type of nitro dilator that releases nitric oxide (NO) spontaneously. The released NO then activates smooth muscle soluble guanylate cyclase to form cyclic guanosine monophosphate (cGMP). Increased intracellular cGMP inhibits calcium entry into the cell, decreasing intracellular calcium concentrations and causing smooth muscle [8,9].

Thoracic radiography, electrocardiography and echocardiography are routinely used for diagnosis of heart disease. However, the severity of disease, response to treatment and prognosis of individual patients are not certain with these diagnostic tools. The cardiac specific blood based biomarker cTn-I has been measured to provide information regarding the level of cardiac disease exposure, extent of injury and prognosis [10,11]. In human medicine, cardiac troponin assays are used as a diagnostic standard of care in suspected cases of acute cardiac disorder [12]. Interestingly, in this study, the cTn-I concentration in the group that responded unfavorably to SNP was severely high (> 1 ng/mL). We can assume that the prognosis of patients with high cTn-I concentrations is poor, despite rapid treatment for alleviation of the clinical signs of cardiogenic pulmonary edema.

Management of cardiogenic pulmonary edema with intravenous vasodilators, including SNP, is common in human medicine [1]. However, no clinical studies of the use of SNP to treat acute cardiogenic pulmonary edema have been conducted in veterinary medicine. Vasodilators have a great effect on lowering blood pressure, which can result in worse outcomes through iatrogenic hypotension. Fortunately, in this study, there is no worse outcomes of hypotension. The population of this study was small, so we assume that iatrogenic hypotension can be occurred with large scale study. Afterward, more studies will be needed with large number of patients.

In conclusion, the results of the present study suggest that use of SNP for treatment of dogs with acute cardiogenic pulmonary edema secondary to acute congestive heart failure resulted in improvement of respiratory distress in 7 of 9 dogs, indicating that it may be an effective alternative therapy for dogs with acute cardiogenic pulmonary edema due to acute congestive heart failure.

Acknowledgments

This work was supported by Basic Science Research Program through the National Research Foundation of Korea (NRF) funded by the Ministry of Science, ICT & Future Planning (NRF-2014R1A1A1004339, NRF-2020R1F1A1073007).

ORCID

Mangil Han, <https://orcid.org/0000-0001-9549-1444>

Yoonhwan Kim, <https://orcid.org/0000-0002-0727-9927>

Yunho Jeong, <https://orcid.org/0000-0001-9445-3606>

Jin-Ok Ahn, <https://orcid.org/0000-0002-3300-6084>

Jin-Young Chung, <https://orcid.org/0000-0001-6729-9834>

Supplementary Materials

Supplementary data are available at <https://doi.org/10.14405/kjvr.20220006>.

References

1. Johnson MR. Acute pulmonary edema. *Curr Treat Options Cardiovasc Med* 1999;1:269–276.
2. Nelson RW, Couto CG. *Small Animal Internal Medicine*. 5th ed. Elsevier/Mosby, St. Louis, 2014.
3. Ettinger SJ, Feldman EC, Côté E. *Textbook of Veterinary Internal Medicine: Diseases of the Dog and the Cat*. 8th ed. Elsevier, St. Louis, 2017.
4. Prewitt RM, McCarthy J, Wood LD. Treatment of acute low pressure pulmonary edema in dogs: relative effects of hydrostatic and oncotic pressure, nitroprusside, and positive end-expiratory pressure. *J Clin Invest* 1981;67:409–418.
5. Goutal CM, Keir I, Kenney S, Rush JE, Freeman LM. Evaluation of acute congestive heart failure in dogs and cats: 145 cases (2007-2008). *J Vet Emerg Crit Care (San Antonio)* 2010;20:330–337.
6. Graham CA. Pharmacological therapy of acute cardiogenic pulmonary oedema in the emergency department. *Emerg Med Australas* 2004;16:47–54.
7. Kirk JD, Parissis JT, Filippatos G. Pharmacologic stabilization and management of acute heart failure syndromes in the emergency department. *Heart Fail Clin* 2009;5:43–54.
8. Hollenberg SM. Vasodilators in acute heart failure. *Heart Fail Rev* 2007;12:143–147.
9. Piper S, McDonagh T. The role of intravenous vasodilators in acute heart failure management. *Eur J Heart Fail* 2014;16:827–834.
10. Oyama MA, Sisson DD. Cardiac troponin-I concentration in dogs with cardiac disease. *J Vet Intern Med* 2004;18:831–839.
11. Sleeper MM, Clifford CA, Laster LL. Cardiac troponin I in the normal dog and cat. *J Vet Intern Med* 2001;15:501–503.
12. Alpert JS, Thygesen K, Antman E, Bassand JP. Myocardial infarction redefined: a consensus document of the Joint European Society of Cardiology/American College of Cardiology Committee for the redefinition of myocardial infarction. *J Am Coll Cardiol* 2000;36:959–969.