



# Femoral Shaft Fracture in Klippel–Trenaunay–Weber Syndrome Patients – What to Do to Reduce Bleeding Risk: A Case Report

Byung-Chan Choi, MD, Byung-Woo Min, MD, Kyung-Jae Lee, MD

*Department of Orthopedic Surgery, Dongsan Hospital, Keimyung University School of Medicine, Daegu, Korea*

A fracture of the affected extremity in patients with Klippel–Trenaunay–Weber syndrome can be fatal due to massive bleeding and show poor results. A 42-year-old male presented with an old fracture of the right femoral shaft with metal failure. We planned an operation to remove the previously fixed plate and to perform re-fixation using an intra-medullary nail. Preoperative angiography was performed and the arteriovenous malformations were embolized in order to reduce the risk of bleeding. After angiography, the previously fixed plate was removed. After the operation, a second angiography was performed immediately and the venous malformation was embolized. One week after the first operation, a second operation was performed in order to reduce the fracture and to perform re-fixation using an intramedullary nail. The patient is being followed without major complication over a period of seven years after surgery. We recommend careful planning of preoperative and postoperative angiography and embolization in order to reduce the risk of bleeding in patients with Klippel–Trenaunay–Weber syndrome.

**Key Words:** Klippel–Trenaunay–Weber syndrome, Kippel–Trenaunay syndrome, Femoral fracture, Fracture fixation, Angiography

Klippel–Trenaunay–Weber syndrome (KTWS) is a rare genetic disorder of the vascular system characterized by arteriovenous malformation with Klippel–Trenaunay syn-

drome (KTS). KTS occurs in approximately 1 in 30,000 live births. It is characterized by a clinical triad of vascular malformation, bone and soft tissue hypertrophy, and diffuse varicosity of veins<sup>1)</sup>. Although it usually affects one limb, some studies found in the literatures have reported that it can affect two limbs or more<sup>2)</sup>.

Poor results have been reported for fractures of the affected extremity in KTWS because of problems with wound healing, infection, and non-union. In addition, massive bleeding can lead to fatality. These complications should be considered in treatment of the fracture in patients with KTWS. However, there is still no consensus regarding management of complications and treatment of the fractures in patients with KTWS. In this study, we report on a patient who suffered a fracture of the femoral shaft who received operative treatment with minimal complication.

**Submitted:** July 4, 2022 **1st revision:** July 22, 2022

**Final acceptance:** August 9, 2022

**Address reprint request to**

**Kyung-Jae Lee, MD**

(<https://orcid.org/0000-0003-4811-574X>)

Department of Orthopaedic Surgery, Dongsan Hospital, Keimyung University School of Medicine, 1035 Dalgubeol-daero, Dalseo-gu, Daegu 42601, Korea

**TEL:** +82-53-258-7930 **FAX:** +82-53-258-4773

**E-mail:** oslee@dsmc.or.kr

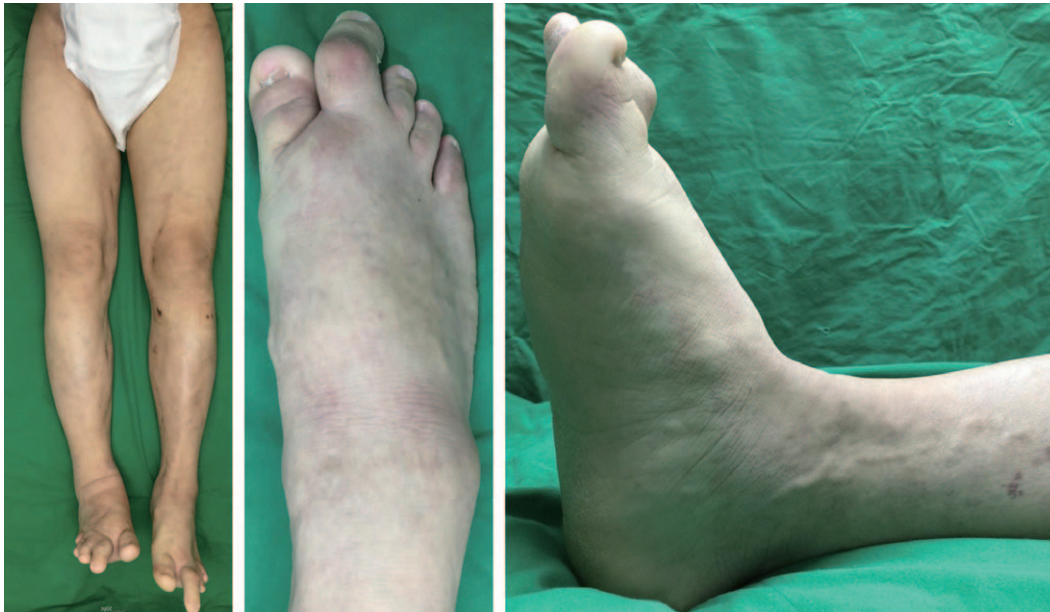
This is an Open Access article distributed under the terms of the Creative Commons Attribution Non-Commercial License (<http://creativecommons.org/licenses/by-nc/4.0>) which permits unrestricted non-commercial use, distribution, and reproduction in any medium, provided the original work is properly cited.

**CASE REPORT**

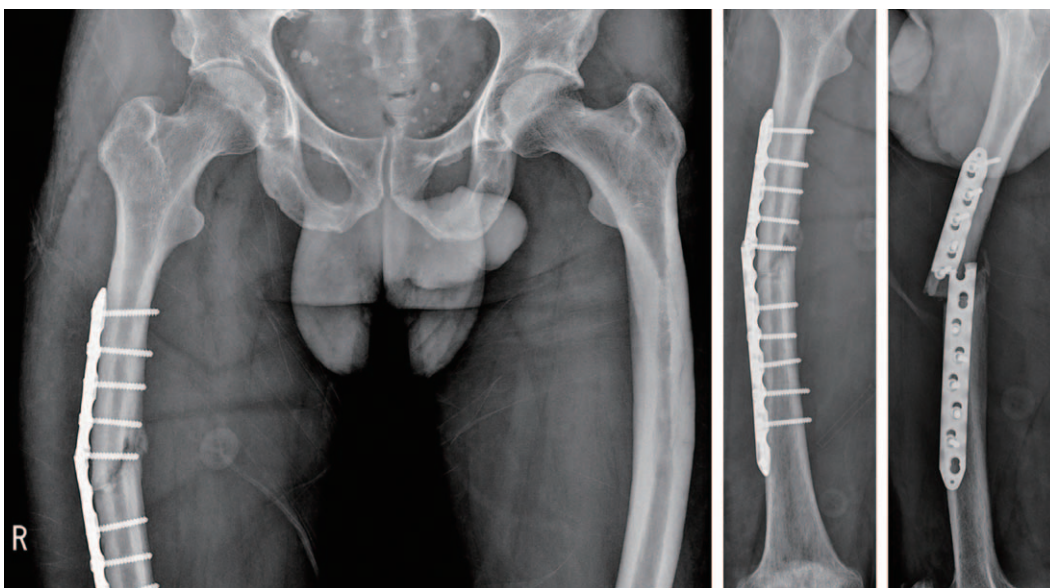
A 42-year-old male visited the emergency room with right mid-thigh pain after usual activity. He had hypertrophy of both lower limbs, second toe macrodactyly, a capillary malformation like lesion on the foot, and varicosity of both lower limbs (Fig. 1). He presented with an old fracture of the right femoral shaft with metal failure (Fig. 2). He had slipped and suffered a fall four months ago and underwent

surgery for treatment of the right femoral shaft fracture at a local medical center (Fig. 3).

Preoperative computed tomography angiography showed multiple arteriovenous malformations with a traumatic arteriovenous fistula in the right thigh. An operation was planned for removal of the previously fixed plate and to perform re-fixation using an intra-medullary (IM) nail. To reduce the risk of bleeding, angiography was performed and the arteriovenous malformation, which originated from the



**Fig. 1.** Both lower limb hypertrophy, second toe macrodactyly, a capillary malformation like lesion on the foot and both lower limb varicosity.

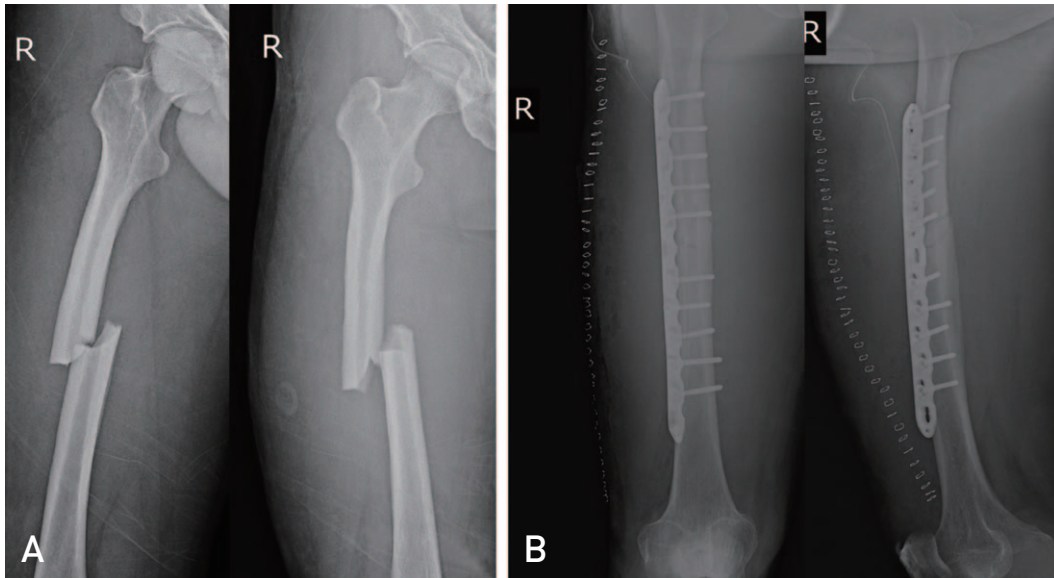


**Fig. 2.** A 42-year-old male presented with an old fracture of the right femoral shaft with metal failure.

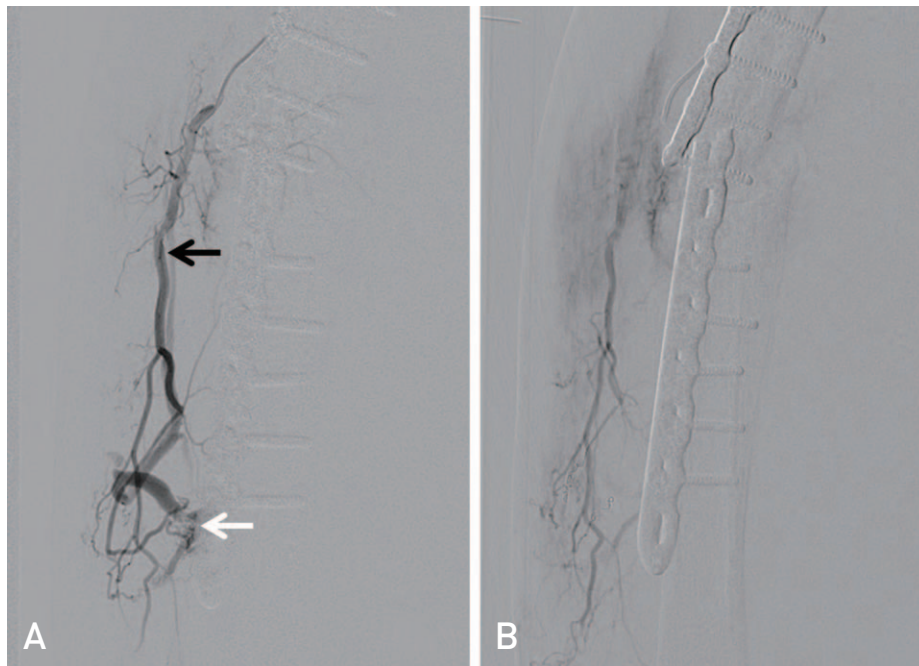
deep femoral artery, was embolized (Fig. 4).

Six days after angiography, we removed the previously fixed plate. The operation took 2 hours 35 minutes. The estimated intraoperative bleeding was 1,200 mL and the patient received five units of packed red blood cells (pRBC) and three units of fresh frozen plasma (FFP). After the operation, a second angiography was performed and a venous malfor-

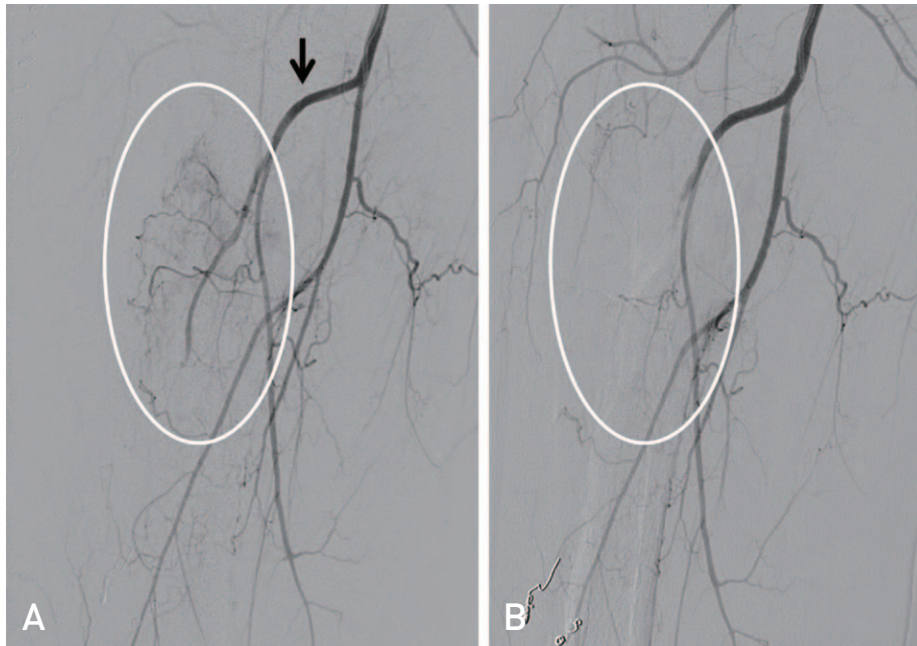
mation originating from the deep femoral artery was embolized in order to prevent additional bleeding (Fig. 5). Skeletal traction was then applied until the second operation in order to immobilize the fracture site (Fig. 6). Preoperative hemoglobin (Hb) was 13.0 g/dL and immediate postoperative Hb was 11.7 g/dL. After surgery, Hb was checked daily until postoperative day 4. The patient did not undergo blood transfu-



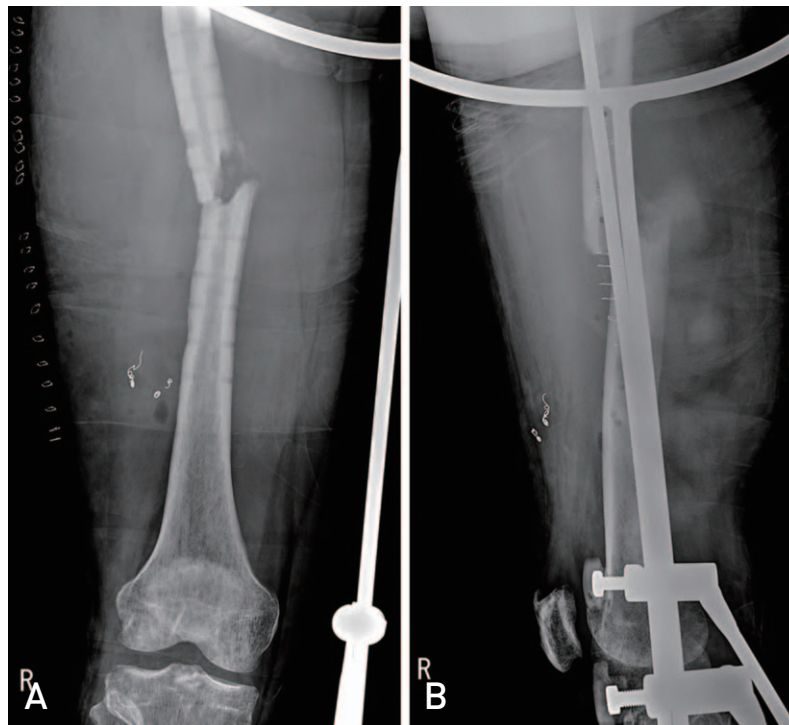
**Fig. 3.** He slipped and suffered a fall four months ago and underwent an operation for a right femoral shaft fracture at a local medical center. (A) Preoperative X-ray and (B) immediate postoperative X-ray at a local medical center.



**Fig. 4.** (A) arteriovenous malformation (white arrow) which originated from the deep femoral artery (black arrow). (B) After embolization, arteriovenous malformation disappeared.



**Fig. 5.** After removal of the previously fixed plate, we immediately performed second angiography. **(A)** Angiography showed multiple feeders for arteriovenous malformation from a branch of the deep femoral artery (black arrow). **(B)** After embolization, arteriovenous malformation disappeared.

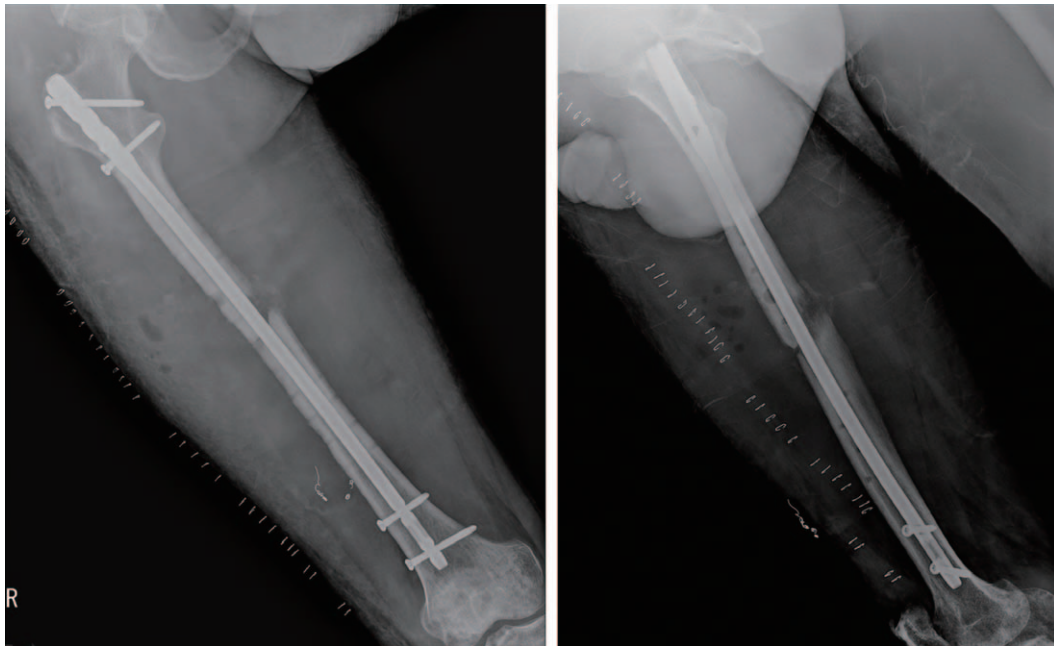


**Fig. 6.** After angiography, we applied skeletal traction until the second operation in order to immobilize the fracture site.

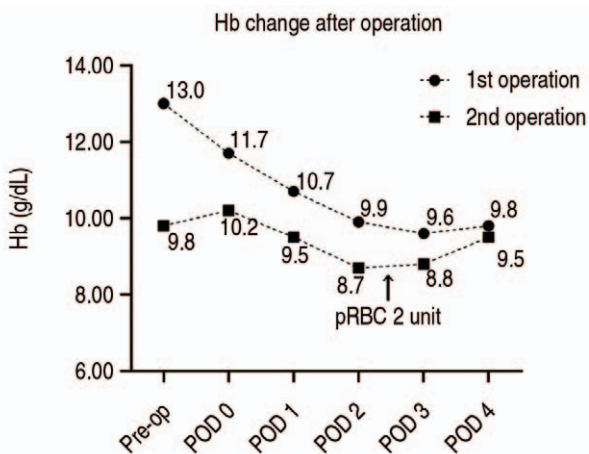
sion between the first operation and the second operation.

One week after the first operation, a second operation was performed in order to reduce the fracture and to perform re-

fixation using an IM nail. A reconstruction type nail was used after IM reaming due to a narrow medullary canal. The operation took 2 hours 5 minutes (Fig. 7). The estimated



**Fig. 7.** We performed the second operation in order to reduce the fracture and to perform re-fixation using an intramedullary nail. We used a reconstruction type nail.



**Fig. 8.** Hemoglobin (Hb) change after the first and second operation.

pRBC: packed red blood cells, Pre-op: preoperative, POD: postoperative day.

intraoperative bleeding was 400 mL and the patient received three units of pRBC and one unit of FFP. At three days before the second operation, preoperative Hb was 9.8 g/dL and immediate postoperative Hb was 10.2 g/dL. After surgery, Hb was checked daily until postoperative day 4. The patient underwent transfusion with two units of pRBC two days after the second operation (Fig. 8).

The patient ambulated using a wheelchair two days after the operation and ambulated using two crutches after 12 days

after the operation. The operative wound was clear without discharge during the admission period. The patient was discharged from the hospital 18 days after the operation. The patient ambulated using a cane eight months after the operation. Twenty-three months after the operation, radiologic union was achieved (Fig. 9). The patient is being followed without major complication seven years after surgery.

The patient was informed that this case would be submitted for publication and informed consent was obtained from the patient.

## DISCUSSION

This case highlights the fact that careful planning of peri-operative angiography and embolization of arteriovenous malformation can decrease bleeding in the femoral shaft fracture in patients with KTWS. During hospital admission, the patient did not receive intensive care, and there were no wound problems or massive transfusion. As a result, proper healing of the fracture was achieved without complication and good results were obtained in seven-year follow up.

Most cases of KTWS are sporadic and pathogenesis is elusive; therefore, diagnosis is difficult. Although some researchers have suggested autosomal dominant patterns of inheritance, it has not yet been proven<sup>3</sup>. Because there is no pathognomotic test, diagnosis should be based on clinical features such as vascular malformation (nevus flam-

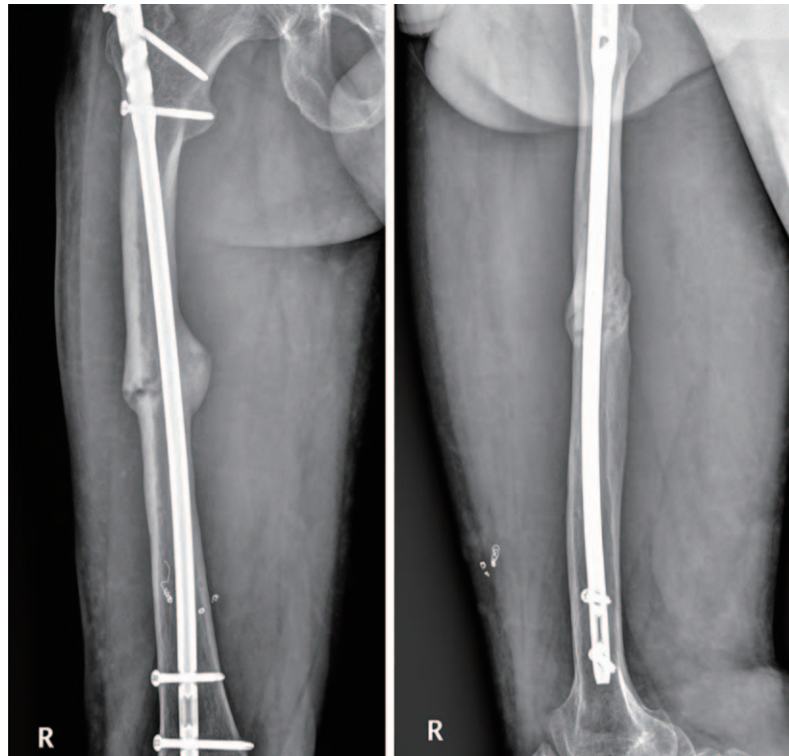


Fig. 9. Radiologic union after 23 months.

meus, “port wine stain”), soft tissue hypertrophy, and varicosity of the affected limb.

There are only a few cases involving treatment of a femoral shaft fracture in KTWS and KTS patients and poor results were reported in these cases. Mahjoub et al.<sup>4</sup> reported that conservative treatment such as skeletal traction and operative treatment such as open reduction and internal fixation (ORIF) or IM nail showed poor results in two cases of femoral shaft fracture in KTS patients. They eventually performed en bloc resection and reconstruction and insisted that it is a viable option<sup>4</sup>. Nahas et al.<sup>5</sup> reported that ORIF for treatment of femoral shaft fracture in KTS patients resulted in delayed union, and management with low intensity pulsed ultrasound was subsequently administered. Gupta et al.<sup>6</sup> reported union of a femoral shaft fracture in KTS patients with external fixation following skeletal traction. However, the patient described in this case report developed a limb length discrepancy of 5 cm. Only one case report described excellent results. Prasanna reported successful union of femoral shaft fractures in KTS patients using plate fixation with use of a minimally invasive osteosynthesis technique after fluoroscopic-guided foam sclerotherapy of the lower limb<sup>7</sup>.

Femoral shaft fracture itself is associated with a relative-high risk of bleeding. The high potential for bleeding in

KTWS and KTS should be of concern to many surgeons. The risk of bleeding is extremely high for femoral shaft fracture in these syndromes. Barbara and Wilson<sup>8</sup> reported that mean estimated bleeding was  $740 \pm 2,739$  mL (range, 20 to 18,000 mL) in 82 patients. Mahjoub et al.<sup>4</sup> estimated intraoperative blood loss of 3 L during performance of resection and reconstruction procedures. Nahas et al.<sup>5</sup> reported that 15 units of blood were required during the operation.

Excessive and uncontrollable bleeding can lead to poor results and intensive care. Many surgeons used an intraoperative common iliac artery balloon as a tourniquet for control of intraoperative bleeding<sup>4,8</sup>. However, a complicated surgical procedure and extended operative time may be required.

Several surgeons have performed and recommended magnetic resonance imaging (MRI) study for evaluation of soft tissue hypertrophy and vascular abnormality before the operation<sup>3,5,8</sup>. Evaluation using MRI study could not be performed due to the presence of a previously inserted metal implant. Eventually, evaluation using MRI study could not be performed after removal of the implant because skeletal traction was applied immediately. Nevertheless, bleeding was effectively decreased with perioperative angiography and embolization.

As a result, we highly recommend careful planning of pre-operative and postoperative angiography and embolization in order to reduce the risk of bleeding in patients with KTWS.

## CONFLICT OF INTEREST

The authors declare that there is no potential conflict of interest relevant to this article.

## REFERENCES

1. Klippel M, Trenaunay P. *Du naevus variqueux osteohypertrophique*. *Arch Gen Med*. 1900;185:641-72.
2. Viljoen DL. *Klippel-Trenaunay-Weber syndrome (angio-osteohypertrophy syndrome)*. *J Med Genet*. 1988;25:250-2. <https://doi.org/10.1136/jmg.25.4.250>
3. Wang SK, Drucker NA, Gupta AK, Marshalleck FE, Dalsing MC. *Diagnosis and management of the venous malformations of Klippel-Trénaunay syndrome*. *J Vasc Surg Venous Lymphat Disord*. 2017;5:587-95. <https://doi.org/10.1016/j.jvsv.2016.10.084>
4. Mahjoub A, Gilbert G, Turkula S, Mendez G, Graf K, Kim TWB. *Treatment of femoral shaft fractures in patients with Klippel-Trénaunay syndrome: a report of 2 cases*. *JBJS Case Connect*. 2021;11:e21.00136. <https://doi.org/10.2106/JBJS.CC.21.00136>
5. Nahas S, Wong F, Back D. *A case of femoral fracture in Klippel Trenaunay syndrome*. *Case Rep Orthop*. 2014;2014:548161. <https://doi.org/10.1155/2014/548161>
6. Gupta Y, Jha RK, Karn NK, Sah SK, Mishra BN, Bhattarai MK. *Management of femoral shaft fracture in Klippel-Trenaunay syndrome with external fixator*. *Case Rep Orthop*. 2016;2016:8505038. <https://doi.org/10.1155/2016/8505038>
7. Deshpande P, Chauhan R, Agrawal S, Rivi S, Nandan B, Dhawan M. *Klippel-Trenaunay syndrome and femoral fracture: a literature review and case report*. *Curr Orthop Pract*. 2022;33:204-7. <https://doi.org/10.1097/BCO.0000000000001090>
8. Barbara DW, Wilson JL. *Anesthesia for surgery related to Klippel-Trenaunay syndrome: a review of 136 anesthetics*. *Anesth Analg*. 2011;113:98-102. <https://doi.org/10.1213/ANE.0b013e31821a03c2>