



# Hip Resurfacing Arthroplasty after Failure of Tantalum Rod Insertion in Patients with Osteonecrosis of the Femoral Head

Yoon Je Cho, MD, Kee Hyung Rhyu, MD, Young Soo Chun, MD\*, Hyun Gon Gwak, MD\*

*Department of Orthopaedic Surgery, Kyung Hee University Hospital, College of Medicine, Kyung Hee University, Seoul, Korea*

*Department of Orthopaedic Surgery, Kyung Hee University Hospital at Gangdong, College of Medicine, Kyung Hee University, Seoul, Korea\**

**Purpose:** The purpose of this study was to examine the clinical outcomes and efficacy of hip resurfacing arthroplasty (HRA) in patients with osteonecrosis of the femoral head after the failure of porous tantalum rod insertion without rod removal.

**Materials and Methods:** Conversion to hip resurfacing arthroplasty was performed in 10 patients (11 hips) with a mean period of 14.9 months after the primary surgery. The mean follow-up period was 73.7 months. Analysis of pre and postoperative range of motion (ROM), University of California at Los Angeles (UCLA) activity score, modified Harris hip score, and visual analog scale (VAS) pain score was performed. Radiographic analysis of component loosening and osteolysis was performed.

**Results:** The postoperative ROM showed significant improvement ( $P<0.05$ ), excluding flexion contracture. The modified Harris hip score showed improvement from 65.82 to 96.18, the UCLA score showed improvement from 4.18 to 8.00, and the VAS pain score was reduced from 6.09 to 1.80. All scores showed statistically significant improvement ( $P<0.05$ ). No component loosening or osteolysis was detected by radiographic analysis.

**Conclusion:** Satisfactory results were obtained from conversion hip resurfacing arthroplasty after failure of porous tantalum rod insertion without rod removal. The findings of this study demonstrate the advantages of HRA, including no risk of trochanteric fracture and no bone loss around the tantalum rod. In addition, the remaining porous tantalum rod provided mechanical support, which reduced the potential risk of femoral neck fracture or loosening. This technique can be regarded as a favorable treatment option.

**Key Words:** Osteonecrosis of the femoral head, Tantalum rod, Hip resurfacing arthroplasty

Submitted: April 17, 2022 1st revision: August 7, 2022  
2nd revision: September 27, 2022 Final acceptance: October 16, 2022  
Address reprint request to

Young Soo Chun, MD

(<https://orcid.org/0000-0001-9344-5188>)

Department of Orthopaedic Surgery, Kyung Hee University  
Hospital at Gangdong, College of Medicine, Kyung Hee University,  
892 Dongnam-ro, Gangdong-gu, Seoul 05278, Korea

TEL: +82-2-440-6155 FAX: +82-2-440-7498

E-mail: [mozart13@khu.ac.kr](mailto:mozart13@khu.ac.kr)

This is an Open Access article distributed under the terms of the Creative Commons Attribution Non-Commercial License (<http://creativecommons.org/licenses/by-nc/4.0>) which permits unrestricted non-commercial use, distribution, and reproduction in any medium, provided the original work is properly cited.

## INTRODUCTION

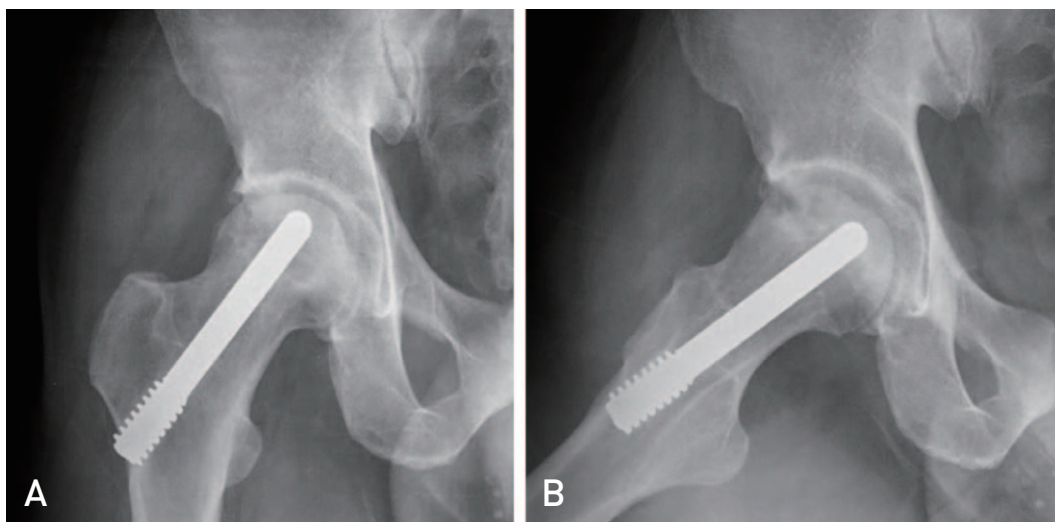
Implantation of a porous tantalum rod is an option for treatment of early-stage osteonecrosis of the femoral head (ONFH). When utilizing this surgical technique, there is no requirement for graft harvesting and it can be performed without donor-site morbidity<sup>1-5</sup>. The high-volume porosity of porous tantalum is greater than 80% and its pores are interconnected, enabling rapid and firm bone ingrowth<sup>6</sup>. Furthermore, this material, which has a modulus of elasticity similar to that of bone, can endure a transfer of physiological load after insertion, thus minimizing stress shielding<sup>4,7</sup>. Because of these characteristics, tantalum rod insertion can be performed by addition of core decompression in order to provide structural reinforcement at the early stage of ONFH. Despite these beneficial attributes, unfavorable clinical outcomes from use of porous tantalum rods for the treatment of ONFH have been reported<sup>3,8-14</sup>.

Hip arthroplasty after failure of porous tantalum rod implantation is necessary for patients who are refractory to conservative treatment<sup>15</sup>. Several recent studies have reported promising outcomes following conversion to total hip arthroplasty after failure of tantalum rod insertion. Removal of a porous tantalum rod during performance of total hip arthroplasty may result in an increase of bone loss and a reduction of mechanical support for the lateral cortex of the proximal femur. Furthermore, a longer period of time and greater effort is required in performance of this procedure, and extension of operating time may result in increased blood loss and the need for transfusion, eventually leading to development of complications<sup>5,16</sup>. In addition, production

of metal debris can occur during removal of the implanted tantalum rod, leading to development of other complications caused by the metal 3rd bodies<sup>5</sup>. Literature regarding the outcome of hip resurfacing arthroplasty (HRA) after failure of tantalum rod insertion in patients with ONFH is limited. Therefore, in this study, HRA, where the bone stock of the femoral head and neck is preserved without removal of the rod, was attempted. The aim of this study was to report on related surgical techniques and to evaluate their short-term follow-up results.

## MATERIALS AND METHODS

In this study, after obtaining approval by the Institutional Review Board (IRB) of Kyung Hee University Hospital (No. 2016-04-205-004), the charts and radiographs of the patients were reviewed retrospectively. Due to its retrospective nature, exemption from informed consent was obtained from the IRB. Among 22 patients who underwent core decompression with tantalum rod insertion at another hospital, 10 patients (11 hips) who underwent HRA without rod removal between May 2009 and April 2014 were included in this study. The mean age of the patients was 37.2 years (range, 26-49 years) at the time of the tantalum rod insertion. HRA was performed in the following cases. Clinical failure of porous tantalum rod insertion was defined as the presence of a subchondral bone fracture or collapse of the femoral head as observed on plain radiographs (Fig. 1) and a complaint of pain that worsened after implantation of the rod in patients diagnosed with ONFH. The extent of necrosis was determined by computed tomography per-

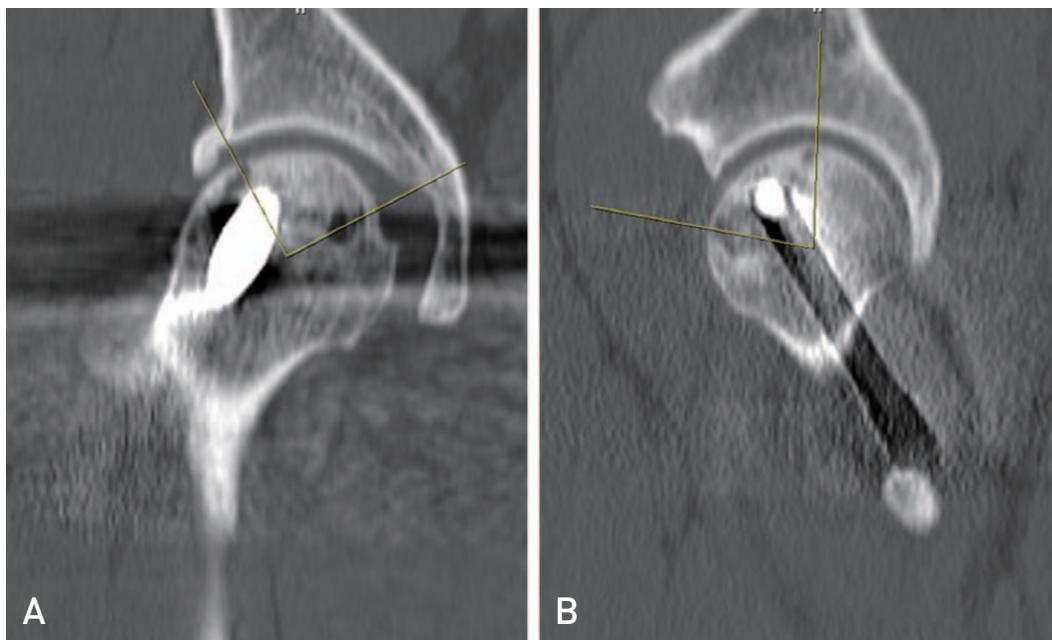


**Fig. 1.** The presence of a subchondral bone fracture was observed on both hip anteroposterior (A) and frog leg lateral (B) radiographs.

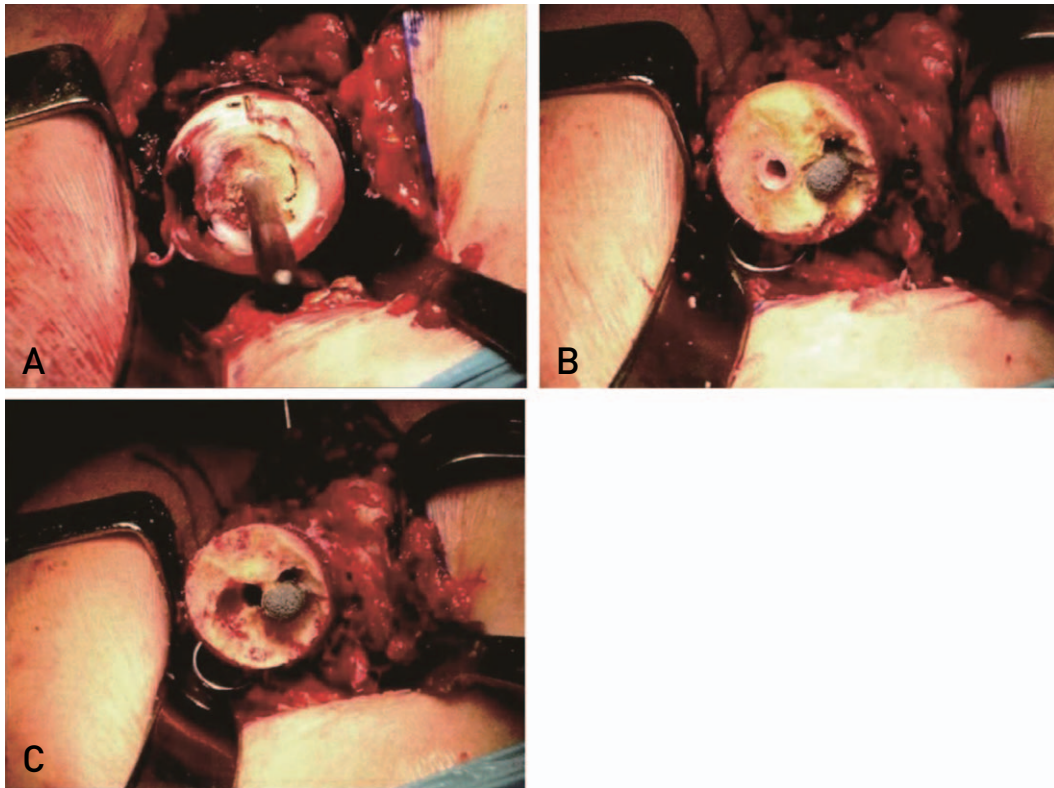
formed prior to surgery. After marking the margins of the necrotic lesion on both the midcoronal and the midsagittal image, measurement of the necrotic angles was performed using PACS (Picture Archiving and Communication System)<sup>17,18)</sup> (Fig. 2). Steinberg's formula was used for calculation of the index of necrosis<sup>19)</sup>. In order to reduce the risk of implant loosening or femoral neck fracture due to a weak necrotic portion of the femoral head, HRA was performed when the size of the necrotic lesion was less than 50% and the area of the necrotic lesion did not extend to the head-neck junction<sup>20)</sup>. The final decision was made intraoperatively for patients with small necrotic lesions, and when the tantalum rod located in the necrotic area did not cause disturbance during performance of the resurfacing procedure. The mean age of the patients was 38.6 years (range, 26-50 years) at the time of conversion to resurfacing arthroplasty. All of the subjects were male. Five and six right- and left-sided hips were included, respectively. HRA was performed 14.9 months (range, 5-56 months) after porous tantalum rod insertion. The mean follow-up period was 73.7 months (range, 13-159 months).

All surgeries were performed by a single high-burden surgeon, in the lateral position, under general anesthesia using the posterolateral approach (modified Gibson approach). Excision of the short external rotator, 1 cm from the bony attachment, was performed, and the incision performed on the quadratus femoris was minimized in order to preserve

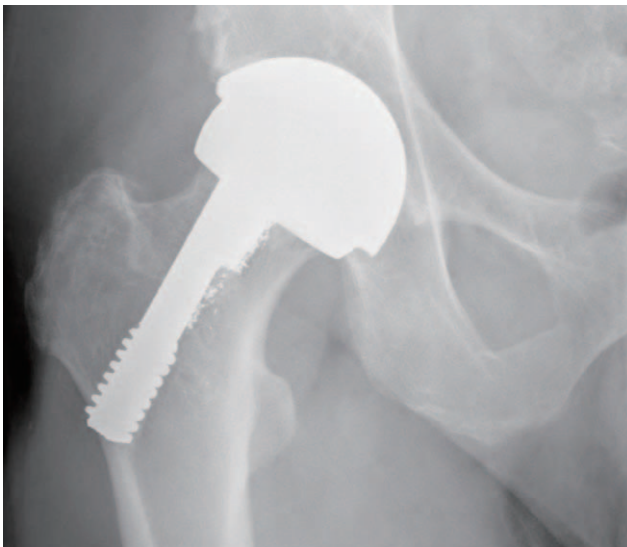the medial femoral circumflex artery. The target neck-shaft angle was  $135^{\circ}$ ; however, if there was a concern about the femoral component contacting the implanted tantalum rod, it was compromised in order to avoid contact with the previously installed porous tantalum rod. The direction of the guide pin was modified by the surgeon and a guide pin was placed down the central axis of the femoral head and neck in order to determine the position of the femoral component (Fig. 3A). In most cases, the tantalum rod is inserted into the anterosuperior portion of the femoral head, where osteonecrosis is most commonly observed, thus avoiding impingement between the tantalum rod and the stem of the femoral component. If the post reamer encountered the tantalum rod during the process of post reaming along the guide pin, the distal part of the stem of the femoral component was removed using a Hercules Steinmann pin cutter in order to avoid impingement between the tantalum rod and the stem of the femoral component (Fig. 4). Complete removal of the necrotic portion was performed, while the rod was not removed unless the protruding rod was long enough to impede placement of the femoral component. Finally, insertion of the femoral implant was performed using bone cement (Fig. 3B, C). The Durom (Zimmer, Warsaw, IN, USA) implant was used in seven hips, MMCTM (Zimmer) in two hips, an advanced ceramic-coated implant system (ACCIS; Implantcast GmbH, Buxtehude, Germany) in one hip, and Conserve Plus (Wright Medical Tech, Memphis,



**Fig. 2.** The necrotic angles from computed tomography. (A) The angle of the necrotic area in the midcoronal image. (B) The angle of the necrotic area in the midsagittal image.



**Fig. 3.** (A) The target neck-shaft angle of  $135^\circ$  was maintained by avoiding contact with the previously implanted porous tantalum rod at the femoral head and neck, and the position of the femoral component was determined by placement of a guide pin down the central axis of the femoral head and neck. (B) The surrounding cartilage and soft tissue were removed. (C) Removal of the necrotic bone before cementing.



**Fig. 4.** Plain radiograph demonstrating the hip resurfacing arthroplasty performed after removal of a portion of the femoral component rod in contact with the porous tantalum rod.

TN, USA) in one hip. A cementless acetabular cup was

used in all hips, and fixation of the femoral components was performed using bone cement (Simplex P; Stryker, Mahwah, NJ, USA).

For clinical analysis, measurements of the operation time, blood loss, and transfusion volume were taken during performance of resurfacing arthroplasty, and intraoperative assessment of the extent of necrosis of the femoral head was performed. Evaluation of the range of motion (ROM), University of California at Los Angeles (UCLA) activity score, modified Harris hip score (HHS), and visual analog scale (VAS) pain score was performed postoperatively and at the last follow-up visit. Analysis of potential postoperative complications, including infection, dislocation, venous thromboembolism, heterotopic ossification, femoral neck fracture, pseudotumors, and metal allergic reactions, was performed. Radiographic analysis was performed using preoperative plain radiographs, and identification of a subchondral bone fracture was based on both hip anteroposterior (AP) and frog-leg lateral views (Fig. 1). In addition, evaluation of femoral component position, osteolysis, and component loosening was performed using both hip AP, groin

lateral, and frog-leg views at follow-up.

IBM SPSS Statistical software (ver. 21.0; IBM, Armonk, NY, USA) was used in performance of statistical analyses. Comparison of preoperative and postoperative ROM, UCLA activity score, modified HHS, and VAS pain score was performed using the Wilcoxon signed-rank test. Statistical significance was set at  $P < 0.05$ .

## RESULTS

As confirmed in the operating room, the degree of necrosis of the femoral head was  $34.0 \pm 9.4\%$ . The mean size of implants was  $55.6 \pm 2.3$  mm for the cup and  $48.8 \pm 1.7$  mm for the head. The mean duration of surgery was  $156 \pm 18$  minutes. The mean intraoperative blood loss was  $660 \pm 320$  mL, and the mean intraoperative transfusion volume was  $224 \pm 288$  mL. The preoperative and postoperative ROM showed improvement from  $1.36^\circ$  to  $0^\circ$  for flexion contracture, from  $106.82^\circ$  to  $118.18^\circ$  for forward flexion, from  $12.73^\circ$  to  $21.82^\circ$  for internal rotation, from  $33.18^\circ$  to  $43.18^\circ$  for external rotation, from  $20.45^\circ$  to  $27.27^\circ$  for adduction, and from  $33.18^\circ$  to  $40.45^\circ$  for abduction. Excluding flexion contracture, the ROM values showed a significant increase ( $P < 0.05$ ) (Table 1). The modified HHS showed improvement from 65.82 preoperatively to 96.18 postoperatively at the last follow-up visit, whereas the UCLA

score showed improvement from 4.18 to 8.00, and the VAS pain score was reduced from 6.09 to 1.80. All scores showed statistically significant improvement ( $P < 0.05$ ) (Table 2). The mean postoperative acetabular cup inclination was  $44.4 \pm 2.1^\circ$  and the mean neck-shaft angle of the femoral component was  $135.9 \pm 4.7^\circ$ . Loosening and osteolysis of the acetabular and femoral components were not observed (Fig. 5). Neck narrowing was observed in one case. However, no progression or symptoms were observed; thus, the patient underwent outpatient follow-up. No other complications were observed, including infection, dislocation, or venous thromboembolism. In addition, there were no cases of femoral neck fracture, a common complication associated with HRA at an early stage, or a pseudotumor due to metal-on-metal articulations. The presence of metal debris generated during the process of post reaming caused by impingement between the post reamer and the portion of the rod was detected on radiographs in three cases, which were confined to the medullary canal of the neck. No significant correlation was observed between the tantalum debris detected on postoperative radiographs and functional outcome scores at the last follow-up visit.

## DISCUSSION

A wide range of results on the survival rate of porous tan-

**Table 1.** Changes in Preoperative and Postoperative Hip ROM

	Preoperative ROM (°)	Postoperative ROM (°)	P-value*
FC	1.36±3.23	0.0	0.18
FF	106.82±11.46	118.18±5.60	0.035
IR	12.73±8.17	21.82±4.05	0.016
ER	33.18±10.79	43.18±4.62	0.015
ADD	20.45±5.68	27.27±4.10	0.006
ABD	33.18±4.05	40.45±3.50	0.011

Values are presented as mean±standard deviation.

ROM: range of motion, FC: flexion contracture, FF: forward flexion, IR: internal rotation, ER: external rotation, ADD: adduction, ABD: abduction.

\* Statistical significance was set at  $P$ -value<0.05.

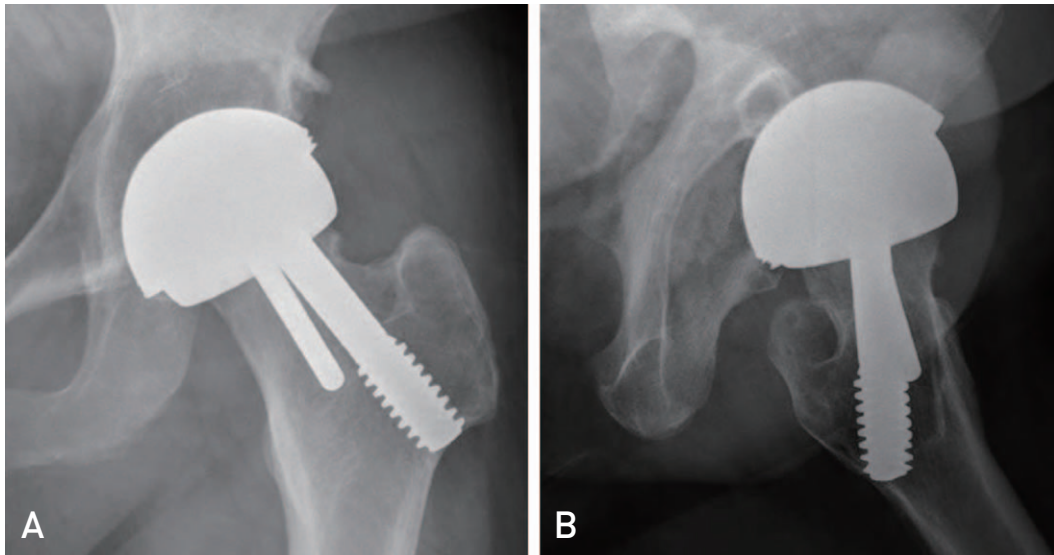
**Table 2.** Changes in Preoperative and Postoperative Modified HHS, UCLA Activity Score, and VAS Pain Score

	Preoperative score	Postoperative score	P-value*
Modified HHS	65.82±10.35	96.18±5.56	0.003
UCLA activity score	4.18±1.17	8.00±0.77	0.003
VAS pain score	6.09±1.14	1.80±0.87	0.003

Values are presented as mean±standard deviation.

HHS: Harris hip score, UCLA: University of California at Los Angeles, VAS: visual analog scale.

\* Statistical significance was set at  $P$ -value<0.05.



**Fig. 5.** Osteolysis or component loosening was not observed on hip anteroposterior (A) and lateral (B) radiographs taken at the 94-month follow-up after surgery.

talum rods has been reported in previous studies. Tsao et al.<sup>9</sup> reported a survival rate of 72.5% in patients who underwent primary tantalum rod insertion at 48 months; conversion total hip arthroplasty was performed in 22 of 113 hips three years after primary tantalum rod insertion surgery for treatment during early stages of ONFH. Veillette et al.<sup>13</sup>, who conducted an evaluation of 58 hips that underwent tantalum rod insertion, reported a survival rate of 68.1% at 48 months. Of these patients, conversion total hip arthroplasty was performed in nine of the 58 hips. Floerkemeier et al.<sup>3</sup> reported a reduction in the survival rate to 44% at a mean of 1.45 years after surgery. Olsen et al.<sup>5</sup> reported a failure rate of 56% at 18 months after primary tantalum rod insertion for treatment of ONFH. Many other studies have also reported unfavorable results after performance of tantalum rod insertion in the early stages of ONFH. According to the findings of histopathologic retrieval analysis conducted by Tanzer et al.<sup>21</sup>, possible reasons for these results could be that the porous tantalum rod provided insufficient mechanical support for the subchondral bone of the necrotic area, and that there was no occurrence of bone regeneration in the necrotic area. Findings from multiple studies have reported on failure after porous tantalum rod insertion in a large number of patients, and conservative management is not an option for these patients. Thus, conversion to hip arthroplasty is the preferred treatment in most cases. Conversion total hip arthroplasty is the conventional treatment option after failure of rod insertion<sup>9</sup>. Rod removal in conversion total hip arthroplasty is a technically demanding procedure due to the high volume of interconnected porosity on the surface

of the tantalum rod, which enables strong osseointegration and rapid bone growth<sup>22,23</sup>. In addition, the risks of rod removal include tantalum debris, increased operation time, blood and bone loss, and increased risk of femoral fracture<sup>16,23</sup>. Lee et al.<sup>4</sup>, who used the trephination technique for removal of the existing rod for conversion to total hip arthroplasty, reported on the inevitable occurrence of bone loss and metallic debris during performance of this procedure. Periprosthetic osteolysis or subsidence was not observed during a follow-up period of three years<sup>4</sup>. Olsen et al.<sup>5</sup>, who performed 21 conversion total hip arthroplasty procedures after failure of rod insertion, reported that radiographic tantalum debris was observed in 21 cases. No increase in liner wear resulting from metallic debris was observed during the short-term follow-up. In addition, no significant differences were observed with regard to the clinical or radiographic outcomes compared with those of primary total hip arthroplasty<sup>5</sup>. Residue associated with metallic debris during the removal of implanted tantalum rods is unavoidable. However, research on the long-term follow-up for evaluation of the potential complications related to metallic debris is limited.

Although several studies have reported on conversion total hip arthroplasty after failure of rod insertion, few studies examining HRA performed after failure of porous tantalum rod insertion have been reported. As demonstrated by the clinical results of this study, advantages of HRA after failure of tantalum rod insertion in ONFH include no risk of trochanter fracture and no bone loss, which can occur during removal of a tantalum rod, and it enables a higher activ-

ities than total hip arthroplasty. Metal debris generated during the process of removing a portion of the rod is confined to the medullary canal of the neck and the amount generated is less than that for the removal of implanted tantalum rods. Therefore, in this study, HRA was performed without removal of the tantalum rod, which reduces the potential risks associated with removal of the rod, as in conversion total hip arthroplasty. As described in the results section, ROM, modified HHS, UCLA activity score, and VAS pain score showed significant postoperative improvement. In addition, no component loosening or osteolysis was observed by radiographic analysis, and there was no occurrence of pseudotumors, a complication associated with metal-on-metal articulations.

As demonstrated in this study, patients who chose to undergo conversion HRA were more likely to be younger and to participate in vigorous physical activity. A larger-sized femoral head can be used with metal-on-metal articulation in performance of hip-resurfacing arthroplasty. When compared with ceramic-on-ceramic articulation, use of this procedure enables participation in vigorous activities involving relatively high impacts, with a lower risk of dislocation with a wide ROM, and no risk of ceramic fracture<sup>24-27</sup>). Another advantage of resurfacing arthroplasty is that the previously inserted rod is maintained, providing mechanical support to the femoral component by filling the bone defect and securing stability of the femoral component. The remaining tantalum rod provides mechanical support to the femoral neck; therefore, it is expected that its presence will reduce the risk of femoral neck fracture, a common complication associated with HRA<sup>3,28</sup>).

This study has several limitations. First, the sample size was relatively small. Second, the mid-term follow-up period was relatively short (73.7 months). As such, conduct of long-term follow-up studies will be required in order to further evaluate pseudotumors, allergic reactions, and other adverse reactions to metal on metal articulations, and to examine the effect of the femoral component after implantation of a porous tantalum rod. Third, conduct of a comparative analysis will be required in order to compare the operation time, blood loss, and transfusion volume in the group of patients who underwent total hip arthroplasty. Finally, conduct of further studies including measurement of serum metal ion levels will be required in order to determine the correlation between metal ion levels and clinical outcomes.

## CONCLUSION

In this study, favorable radiographic and clinical results were obtained from performance of HRA without rod removal after failure of the porous tantalum rod in patients with ONFH, suggesting that HRA offers some advantages, including no risk of trochanteric fracture and no bone loss around the tantalum rod. In addition, by providing mechanical support to the femoral head and neck, the presence of the remaining porous tantalum rod can reduce the potential risk of femoral neck fracture or loosening following HRA. Therefore, HRA without rod removal can be regarded as a favorable and alternative option for treatment of patients with ONFH after failure of porous tantalum rod insertion.

## CONFLICT OF INTEREST

The authors declare that there is no potential conflict of interest relevant to this article.

## REFERENCES

- Vail TP, Urbaniak JR. Donor-site morbidity with use of vascularized autogenous fibular grafts. *J Bone Joint Surg Am.* 1996;78:204-11. <https://doi.org/10.2106/00004623-199602000-00006>
- Tang CL, Mahoney JL, McKee MD, Richards RR, Waddell JP, Louie B. Donor site morbidity following vascularized fibular grafting. *Microsurgery.* 1998;18:383-6. [https://doi.org/10.1002/\(sici\)1098-2752\(1998\)18:6<383::aid-micr8>3.0.co;2-5](https://doi.org/10.1002/(sici)1098-2752(1998)18:6<383::aid-micr8>3.0.co;2-5)
- Floerkemeier T, Thorey F, Daentzer D, et al. Clinical and radiological outcome of the treatment of osteonecrosis of the femoral head using the osteonecrosis intervention implant. *Int Orthop.* 2011;35:489-95. <https://doi.org/10.1007/s00264-009-0940-9>
- Lee GW, Park KS, Kim DY, Lee YM, Eshnazarov KE, Yoon TR. Results of total hip arthroplasty after core decompression with tantalum rod for osteonecrosis of the femoral head. *Clin Orthop Surg.* 2016;8:38-44. <https://doi.org/10.4055/cios.2016.8.1.38>
- Olsen M, Lewis PM, Morrison Z, McKee MD, Waddell JP, Schemitsch EH. Total hip arthroplasty following failure of core decompression and tantalum rod implantation. *Bone Joint J.* 2016;98-B:1175-9. <https://doi.org/10.1302/0301-620X.98B9.37252>
- Bobyn JD, Stackpool GJ, Hacking SA, Tanzer M, Krygier JJ. Characteristics of bone ingrowth and interface mechanics of a new porous tantalum biomaterial. *J Bone Joint Surg Br.* 1999;81:907-14. <https://doi.org/10.1302/0301-620x.81b5.9283>
- Bobyn JD, Poggie RA, Krygier JJ, et al. Clinical validation of a structural porous tantalum biomaterial for adult reconstruction. *J Bone Joint Surg Am.* 2004;86-A Suppl 2:123-9.

- <https://doi.org/10.2106/00004623-200412002-00017>
8. Varitimidis SE, Dimitroulias AP, Karachalios TS, Dailiana ZH, Malizos KN. *Outcome after tantalum rod implantation for treatment of femoral head osteonecrosis: 26 hips followed for an average of 3 years. Acta Orthop.* 2009;80:20-5. <https://doi.org/10.1080/17453670902804877>
  9. Tsao AK, Roberson JR, Christie MJ, et al. *Biomechanical and clinical evaluations of a porous tantalum implant for the treatment of early-stage osteonecrosis. J Bone Joint Surg Am.* 2005;87 Suppl 2:22-7. <https://doi.org/10.2106/JBJS.E.00490>
  10. Aldegheri R, Tagliavero G, Berizzi A. *The tantalum screw for treating femoral head necrosis: rationale and results. Strategies Trauma Limb Reconstr.* 2007;2:63-8. <https://doi.org/10.1007/s11751-007-0021-9>
  11. Nadeau M, Séguin C, Theodoropoulos JS, Harvey EJ. *Short term clinical outcome of a porous tantalum implant for the treatment of advanced osteonecrosis of the femoral head. McGill J Med.* 2007;10:4-10. <https://doi.org/10.26443/mjm.v10i1.462>
  12. Shuler MS, Rooks MD, Roberson JR. *Porous tantalum implant in early osteonecrosis of the hip: preliminary report on operative, survival, and outcomes results. J Arthroplasty.* 2007;22:26-31. <https://doi.org/10.1016/j.arth.2006.03.007>
  13. Veillette CJ, Mehdi H, Schemitsch EH, McKee MD. *Survivorship analysis and radiographic outcome following tantalum rod insertion for osteonecrosis of the femoral head. J Bone Joint Surg Am.* 2006;88 Suppl 3:48-55. <https://doi.org/10.2106/JBJS.F.00538>
  14. Liu G, Wang J, Yang S, Xu W, Ye S, Xia T. *Effect of a porous tantalum rod on early and intermediate stages of necrosis of the femoral head. Biomed Mater.* 2010;5:065003. <https://doi.org/10.1088/1748-6041/5/6/065003>
  15. Beaulé PE, Amstutz HC. *Management of Ficat stage III and IV osteonecrosis of the hip. J Am Acad Orthop Surg.* 2004;12:96-105. <https://doi.org/10.5435/00124635-200403000-00005>
  16. Owens JB, Ely EE, Guilliani NM, Suarez JC, Patel PD. *Removal of trabecular metal osteonecrosis intervention implant and conversion to primary total hip arthroplasty. J Arthroplasty.* 2012;27:1251-3. <https://doi.org/10.1016/j.arth.2012.01.025>
  17. Kerboul M, Thomine J, Postel M, Merle d'Aubigné R. *The conservative surgical treatment of idiopathic aseptic necrosis of the femoral head. J Bone Joint Surg Br.* 1974;56:291-6. <https://doi.org/10.1302/0301-620X.56B2.291>
  18. Ha YC, Jung WH, Kim JR, Seong NH, Kim SY, Koo KH. *Prediction of collapse in femoral head osteonecrosis: a modified Kerboul method with use of magnetic resonance images. J Bone Joint Surg Am.* 2006;88 Suppl 3:35-40. <https://doi.org/10.2106/JBJS.F.00535>
  19. Steinberg ME, Oh SC, Khoury V, Udupa JK, Steinberg DR. *Lesion size measurement in femoral head necrosis. Int Orthop.* 2018;42:1585-91. <https://doi.org/10.1007/s00264-018-3912-0>
  20. Park CW, Lim SJ, Kim JH, Park YS. *Hip resurfacing arthroplasty for osteonecrosis of the femoral head: implant-specific outcomes and risk factors for failure. J Orthop Translat.* 2020;21:41-8. <https://doi.org/10.1016/j.jot.2019.12.005>
  21. Tanzer M, Bobyn JD, Krygier JJ, Karabasz D. *Histopathologic retrieval analysis of clinically failed porous tantalum osteonecrosis implants. J Bone Joint Surg Am.* 2008;90:1282-9. <https://doi.org/10.2106/JBJS.F.00847>
  22. Zhang X, Wang J, Xiao J, Shi Z. *Early failures of porous tantalum osteonecrosis implants: a case series with retrieval analysis. Int Orthop.* 2016;40:1827-34. <https://doi.org/10.1007/s00264-015-3087-x>
  23. Fernández-Fairen M, Murcia A, Iglesias R, Sevilla P, Manero JM, Gil FJ. *Analysis of tantalum implants used for avascular necrosis of the femoral head: a review of five retrieved specimens. J Appl Biomater Funct Mater.* 2012;10:29-36. <https://doi.org/10.5301/JABFM.2012.9273>
  24. Daniel J, Pynsent PB, McMinn DJ. *Metal-on-metal resurfacing of the hip in patients under the age of 55 years with osteoarthritis. J Bone Joint Surg Br.* 2004;86:177-84. <https://doi.org/10.1302/0301-620x.86b2.14600>
  25. Clarke MT, Lee PT, Villar RN. *Dislocation after total hip replacement in relation to metal-on-metal bearing surfaces. J Bone Joint Surg Br.* 2003;85:650-4. <https://doi.org/10.1302/0301-620X.85B5.13993>
  26. Shimmin AJ, Bare J, Back DL. *Complications associated with hip resurfacing arthroplasty. Orthop Clin North Am.* 2005;36:187-93, ix. <https://doi.org/10.1016/j.ocl.2005.01.002>
  27. Mont MA, Seyler TM, Marker DR, Marulanda GA, Delanois RE. *Use of metal-on-metal total hip resurfacing for the treatment of osteonecrosis of the femoral head. J Bone Joint Surg Am.* 2006;88 Suppl 3:90-7. <https://doi.org/10.2106/JBJS.F.00543>
  28. Tai CL, Chen YC, Hsieh PH. *The effects of necrotic lesion size and orientation of the femoral component on stress alterations in the proximal femur in hip resurfacing- a finite element simulation. BMC Musculoskelet Disord.* 2014;15:262. <https://doi.org/10.1186/1471-2474-15-262>