



Short-Term Results of Osteochondral Autologous Transfer and Femoral Neck Osteochondroplasty for the Treatment of Osteochondral Lesions of the Femoral Head and Concomitant Femoroacetabular Impingement Syndrome: A Case Series

Fernando Díaz-Dilernia, MD, MSc, Franco Astore, MD*, Martin Buttaró, MD*, Gerardo Zanotti, MD*

*Sunnybrook Health Sciences Centre/Holland Orthopaedic & Arthritic Centre, Division of Orthopaedic Surgery, Department of Surgery, Faculty of Medicine, University of Toronto, Toronto, ON, Canada
Hip Surgery Unit, Institute of Orthopaedics “Carlos E. Ottolenghi”, Italian Hospital of Buenos Aires, Buenos Aires, Argentina**

This study aimed to analyse the initial results of five patients with symptomatic osteochondral lesions (OCL) and femoroacetabular impingement (FAI) who were treated successfully with osteochondral autologous transfer (OAT) and femoral neck osteochondroplasty (OCP) through surgical dislocation of the hip. Five patients with FAI and OCL of the femoral head who underwent surgery between 2015-2018 were studied retrospectively. All patients had a grade IV OCL, and the median defect size was 2 cm² (interquartile range [IQR], 2-2). At the final follow-up, the modified Harris hip score showed a median value of 94 (IQR, 91-95) ($P=0.04$). Pain evaluation using the visual analogue scale showed a median value of 1 (IQR, 1-2) ($P=0.04$). Adequate graft union and healthy formation of the chondral surface were observed by magnetic resonance imaging. Although the procedure is demanding, the combination of OAT and femoral neck OCP appears to be an effective alternative in young patients.

Key Words: Femoral head, Osteochondral lesion, Femoroacetabular impingement, Surgical hip dislocation, Osteochondral autologous transplantation

Submitted: April 7, 2022 **1st revision:** June 13, 2022

Final acceptance: June 23, 2022

Address reprint request to

Fernando Díaz-Dilernia, MD, MSc

(<https://orcid.org/0000-0002-7830-2207>)

Sunnybrook Health Sciences Centre/Holland Orthopaedic & Arthritic Centre, Division of Orthopaedic Surgery, Department of Surgery, Faculty of Medicine, University of Toronto, 43 Wellesley St E, Toronto, ON M4Y 1H1, Canada

TEL: +1-416-967-8500 **FAX:** +1-416-967-8500

E-mail: fernandodiazdilernia@gmail.com

This is an Open Access article distributed under the terms of the Creative Commons Attribution Non-Commercial License (<http://creativecommons.org/licenses/by-nc/4.0>) which permits unrestricted non-commercial use, distribution, and reproduction in any medium, provided the original work is properly cited.

Osteoarthritis of the hip is a multifactorial disease involving mechanical, biological, and biochemical variables¹. As a result of the profound anatomy and complex biomechanics management of osteochondral lesions (OCL) of the hip is challenging^{2,3}. Despite apparent differences with regard to the biomechanics and the anatomy between the hip and the knee joint, multiple alternative techniques have been developed for the hip based on the knee joint⁴⁻⁸.

Total hip arthroplasty has been the most effective procedure for use in the elderly population; however, it might not be the best option for treatment of young, active patients. Patients are usually referred for pain and decreased functionality, and, unfortunately, there is potential for development of degenerative osteoarthritis⁹. OCL have also been reported in other pathologies, including osteonecrosis, labral tears, loose bodies, femoroacetabular impingement (FAI), arthritis, and hip dysplasia. Some authors have reported on a possible association between parafoveal OCL and cam impingement as part of FAI syndrome¹⁰⁻¹².

Multiple techniques have been developed for preservation of the hip; these include chondroplasty, marrow stimulation, autologous chondrocyte implantation, osteochondral autologous transfer (OAT), and osteochondral allograft (OCA) transplantation^{9,13}. OAT is a well-known surgical technique for treatment of full-thickness cartilage defects, particularly around the knee, ankle, and elbow^{6,14}. OAT has also been identified as an effective technique for treatment of osteochondritis dissecans (OCD) in these joints, even in cases where the injury is unstable^{6,14}. Nevertheless, the available data regarding the outcomes of these techniques for treatment of OCL of the femoral head is limited¹⁵⁻¹⁷.

In this case series we report on the short-term outcomes of five patients with symptomatic cam impingement and extensive OCL (>2 cm²) of the femoral head who were treated successfully with OAT and femoral neck osteochondroplasty (OCP) through surgical dislocation of the hip. This combined therapy utilizing OAT plus femoral neck OCP appears to be a suitable alternative for simultaneous treatment of the cam deformity of FAI syndrome and parafoveal OCL of the femoral head.

CASE REPORT

The five patients provided written informed consent for inclusion and for submission of their data for publication. All procedures performed involving human participants were in accordance with the ethical standards of

the institutional research committee and with the Helsinki Declaration (2013) and its later amendments or comparable ethical standards. The study was approved by the Italian Hospital of Buenos Aires’s Research Ethics Board (No. IRB00010193).

Five male patients with symptomatic parafoveal OCL of the femoral head and concomitant FAI syndrome who underwent surgery between 2015-2018 were studied retrospectively. The median follow-up period was 49 months (interquartile range [IQR], 44-54), and the median age was 24 years (IQR, 23-34). Demographic characteristics are shown in Table 1.

Similar clinical presentations with a history of FAI syndrome and longstanding groin pain during impact activities were observed for all patients. All patients used to practice sports at an amateur level including, running, soccer, and martial arts. Impingement tests performed during physical examination showed positive results, with a fully preserved range of motion. The median preoperative modified Harris hip score (mHHS) and pain evaluation according to the visual analogue scale (VAS) was 63 (IQR, 54-63) and 8 (IQR, 8-9), respectively.

After the initial assessment, a grade IV OCL of the femoral head was observed by magnetic resonance imaging (MRI) in all patients according to the Outerbridge Grading System (Fig. 1). The median defect size was 2 cm² (IQR, 2-2). All patients were also diagnosed with a cam deformity on the femoral neck. No evidence of a pincer sign was observed on the acetabulum, and there was no diagnosis of a labrum

Table 1. Demographics Characteristics of the Series

Variable	Value
No. of patients (=hips)	5
Median age (yr)	24 (23-34)
Median body mass index (kg/m ²)	24 (24-25)
Sex, male	5 (100)
Side, left/right	3/2 (60.0/40.0)
Tönnis classification	
0	3 (60.0)
1	2 (40.0)
Patients with prior surgeries	1 (20.0)
Initial diagnosis (hips)	
Femoroacetabular impingement	5 (100)
Median lesion size (cm ²)	2 (2-2)
Median operative time (min)	147 (130-151)
Median number of grafts used	2 (2-3)
Median follow-up (mo)	49 (44-54)

Values are presented as number only, median (interquartile range), or number (%).

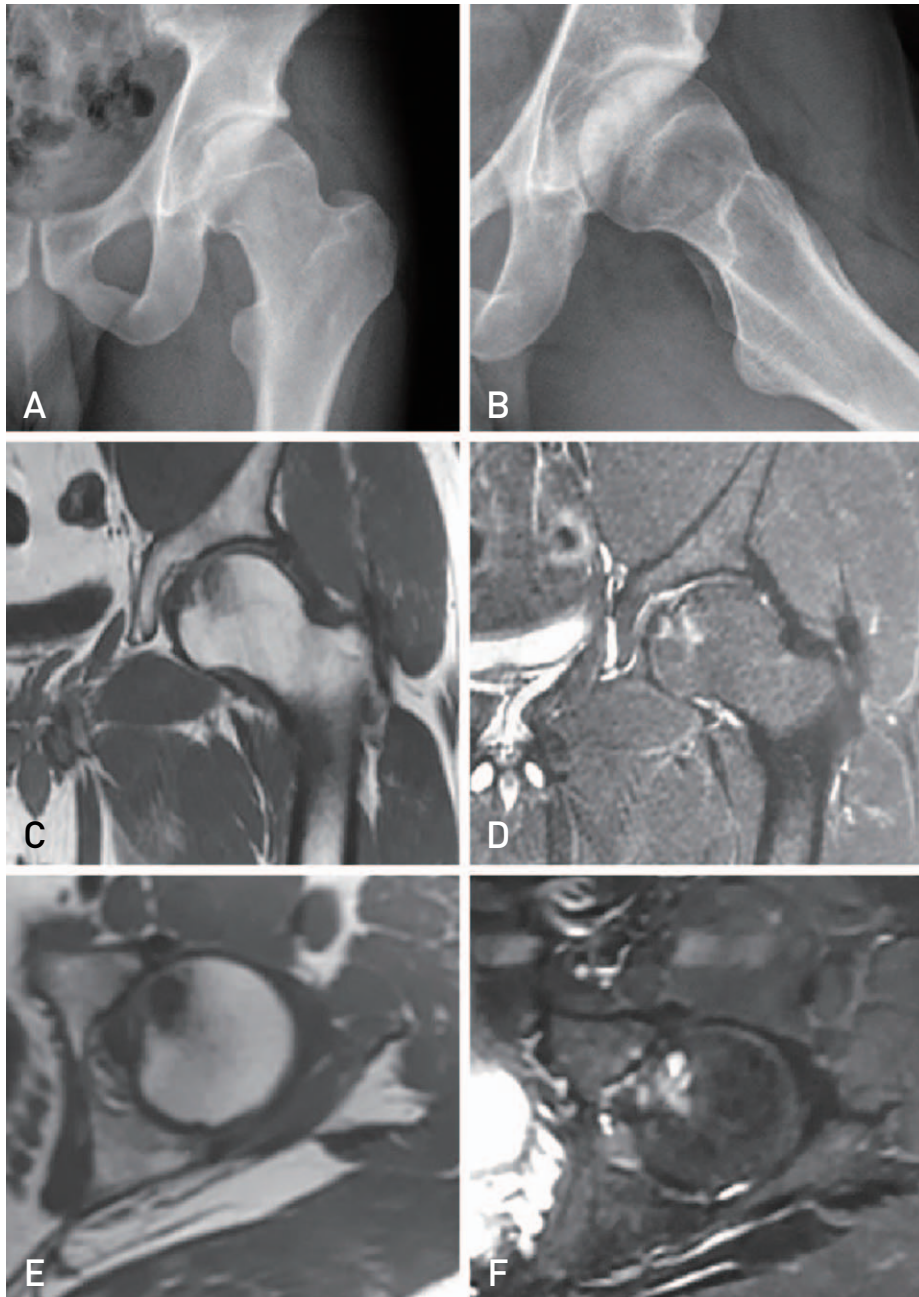


Fig. 1. Preoperative imaging studies of a 21-year-old male with a symptomatic osteochondral lesions (OCL) of the left femoral head. **(A)** Anteroposterior and **(B)** lateral radiograph views show a well-preserved joint space and cam deformity. **(C)** Coronal T1-weighted and **(D)** fat-saturated T2-weighted magnetic resonance imaging (MRI) images showing the OCL. **(E)** Axial T1-weighted and **(F)** fat-saturated T2-weighted MRI images showing the OCL.

tear.

Spinal anaesthesia was administered to all patients, who were placed in lateral decubitus position. A Gibson¹⁸⁾ approach was used by the same surgeon (G.Z.) in all cases. The posterior border of the gluteus medius was observed, and a trochanteric osteotomy was performed using the technique described by Ganz et al.¹⁹⁾. Following exposure of the cap-

sule, an inverse Z shape capsulotomy was performed in order to access the joint. Anterior dislocation of the hip was then performed after hip flexion and external rotation and the leg was placed in a sterile bag. An evaluation of the acetabular cartilage was then performed, followed by treatment, anchoring, or resection of any labral tear if needed. Any loose bodies or cartilage tissues were removed.

An assessment of the chondral lesion on the femoral head was performed, with debridement of unstable cartilage until stable edges were identified, exposing the subchondral bone. Preparation and measurement of the base of the defect was performed using different moulds and a metal ruler. Mosaicplasty was planned with osteochondral autologous grafts and all patients underwent OAT and femoral neck OCP (Fig. 2). According to the size of the defect, different sizes of osteochondral plugs were harvested from the lateral femoral condyle of the ipsilateral knee and then implanted into the prepared drill holes. Bleeding from the femoral head was confirmed throughout the surgical procedure. The joint was then reduced, and the capsule was closed, avoiding excessive tensioning after confirming the absence of any intra-articular interposition. The trochanteric osteotomy was reduced and fixed with two 3.5 mm cortical screws.

No intraoperative complications were recorded, and none of the patients required blood transfusion. The median surgical time was 147 minutes (IQR, 130-151). Postoperative rehabilitation included exercises for passive range of motion and quadriceps strengthening for the first seven days. A maximum of 90° of hip flexion was indicated for 21 days.

Active abduction was restricted for 45 days and toe-touch weight-bearing on the side that underwent surgery was indicated for the first six weeks with progression to total weight-bearing as tolerated. No surgical complications were recorded during the postoperative period. One patient suffered an acute deep vein thrombosis, which was treated successfully with oral medication without further complications. No further surgeries were required in any case, and no signs of osteonecrosis or advanced osteoarthritis were observed in the final review (Fig. 3).

After discharge, follow-up radiographs were taken at six weeks, three months, and yearly. Patients were allowed to return to regular activities after 4-6 months. Postoperative MRI was indicated after three months for assessment of autograft incorporation and cartilage healing in all cases. Adequate graft union and healthy formation of the chondral surface was observed on MRI at a median time of three months (IQR, 3-3). A summary of the details is shown in Table 2.

Comparison of preoperative and postoperative values showed significant improvement in the functional scores. At the final follow-up, the median mHHS had improved

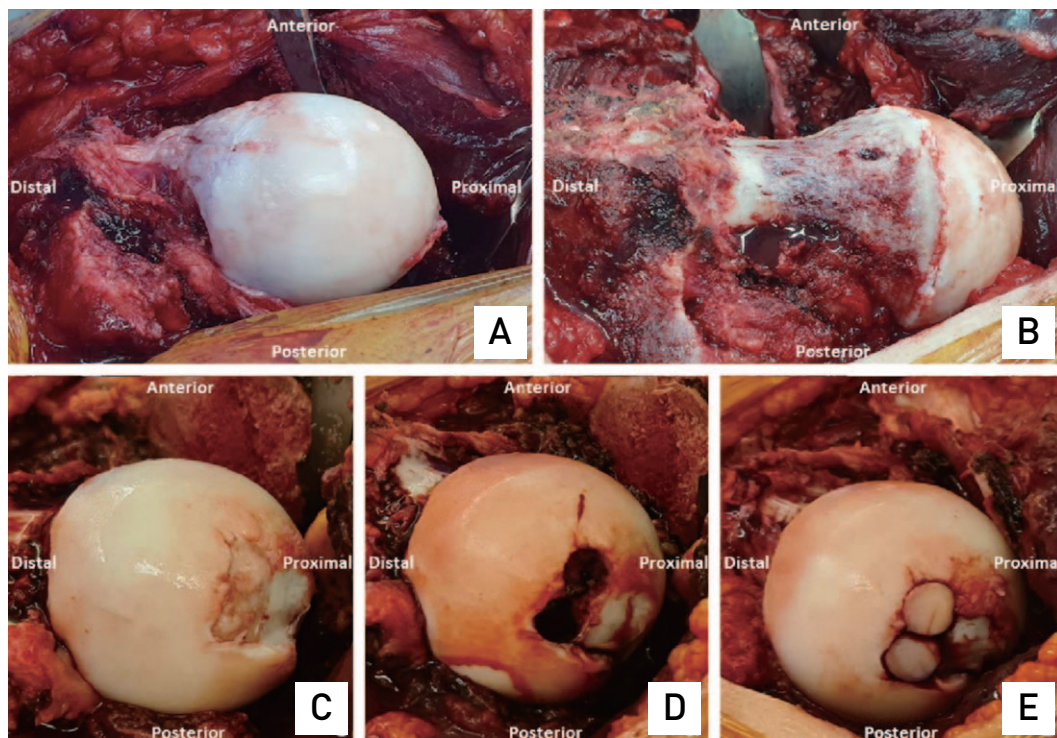


Fig. 2. Intraoperative photographs. (A) Intraoperative view of the concomitant cam deformity of the femoral neck. (B) Intraoperative image of the additional femoral neck osteochondroplasty of the concomitant cam deformity. (C) Intraoperative evidence of a parafoveal osteochondral lesions (OCL) of the femoral head before debridement. (D) Intraoperative view of the parafoveal OCL after debridement and preparation of the lesion site. (E) Final image of the femoral head after osteochondral autologous transfer obtained from the ipsilateral knee.

from 63 (IQR, 54-63) to 94 (IQR, 91-95) ($P=0.04$). The median VAS improved from 8 (IQR, 8-9) to 1 (IQR, 1-2) ($P=0.04$). Median preoperative and postoperative functional scores are shown in Table 3.

Continuous variables were expressed as median and IQR. Categorical variables were reported as frequencies and per-

centages. Comparison of continuous variables was performed using the independent-samples t-test, where data showed a normal distribution, and the Mann-Whitney U test was used otherwise. Variables at $P<0.05$ were considered statistically significant. Stata 13 statistical software (StataCorp, College Station, TX, USA) was used in performance of all

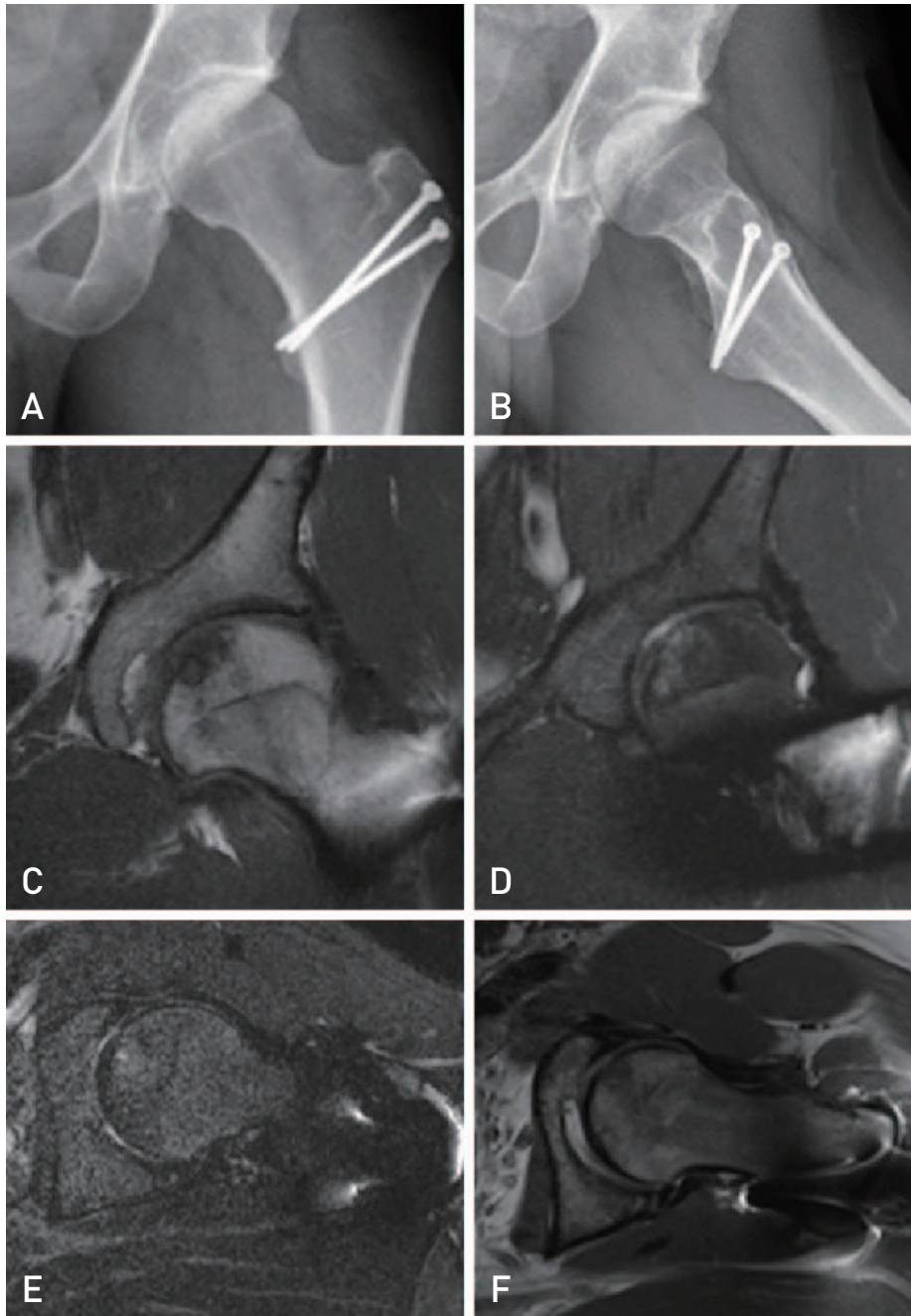


Fig. 3. Postoperative imaging studies. (A) Anteroposterior and (B) lateral radiographs at final follow-up without progressive degenerative changes. (C) Coronal T1-weighted and (D) fat-saturated T2-weighted, and (E) axial STIR (short-TI inversion recovery)-weighted and (F) fat-saturated T2-weighted magnetic resonance imaging images showing adequate graft union and healthy chondral surface formation.

Table 2. Intraoperative Results Patient Demographics, Radiographic Evaluation, and Postoperative Results

Variable	Case 1	Case 2	Case 3	Case 4	Case 5
Age (yr)	21	44	34	24	23
Sex	Male	Male	Male	Male	Male
Side	Left	Right	Left	Right	Left
Sport	Soccer	Marathonist	Martial arts	Soccer	Soccer
Previous surgeries	N/A	N/A	Arthroscopy (1)	N/A	N/A
Symptoms	Hip pain during impact activities				
X-rays findings	FAI syndrome - cam deformity				
MRI findings	Grade IV OCL of the femoral head+cam deformity				
Surgical procedure	OAT+OCP through surgical hip dislocation				
Donor site	Ipsilateral knee				
Graft incorporation (mo)	3	3	4	3	3
Complications	N/A	N/A	N/A	N/A	DVT
Follow-up (mo)	54	49	44	37	74
Latest VAS	1	2	3	1	1
Latest mHHS	94	91	91	95	95

N/A: not applicable, FAI: femoroacetabular impingement, MRI: magnetic resonance imaging, OCL: osteochondral lesion, OAT: osteochondral autologous transfer, OCP: osteochondroplasty, DVT: deep vein thrombosis, VAS: visual analogue scale, mHHS: modified Harris hip score.

Table 3. Preoperative and Postoperative Clinical Outcomes

Functional scores	Median preoperative value	Median postoperative value	P-value
mHHS	63 (54-63)	94 (91-95)	0.04
Merle d’Aubigné	12 (10-12)	17 (16-18)	0.04
UCLA	7 (6-7)	8 (7-9)	0.04
VAS	8 (8-9)	1 (1-2)	0.04

Values are presented as median (interquartile range).

mHHS: modified Harris hip score, UCLA: The University of California, Los Angeles, VAS: visual analogue scale.

analyses.

DISCUSSION

There are multiple difficulties associated with treatment of OCL of the femoral head due to the deep anatomy and the challenge of exposing the surface of the joint. Over the last decade, improvements in arthroscopic surgery and the already well-known technique for surgical dislocation of the hip described by Ganz et al.²⁰ have resulted in the increasing popularity of hip preservation surgery, which has become a viable option for treatment of OCL of the femoral head^{10,12,20-22}. The current data from analysis of the different surgical techniques such as arthroscopic debridement, labrum repair, femoral neck OCP, microfracture and bone marrow stimulation, autogenous chondrocyte implantation, OAT, and OCA transplantation is limited^{10,12,21,22}.

Several authors who analysed OAT for treatment of OCL of the femoral head have reported good outcomes, regard-

less of the initial diagnosis^{8,10,23,24}. In addition, OCL of the femoral head may be a consequence of several conditions. The etiologies described most often in the literature include osteonecrosis^{8,25}, posttraumatic^{23,24}, Legg–Calve–Perthes disease¹⁶, OCD¹⁶, and lateral impact injury²⁶. Overall, it appears that these studies reported encouraging results, except for the case series reported by Rittmeister et al.²⁵.

FAI syndrome is a well-known cause of OCL of the hip joint¹². Decreased range of motion and abnormal hip biomechanics are reported in patients with cam deformities, which can influence development of osteoarthritis of the hip. As opposed to a simple local impingement, Charbonnier et al.²² reported a temporary subluxation of the hip in patients with FAI syndrome. Consequently, these undesired translational movements of the hip may result in exposure of the joint to load abnormalities, and the overall effect may produce OCL of the femoral head. Beck et al.¹² reported on OCL of the acetabulum due to pincer and cam impingement. However, published evidence regarding OCL of the femoral

head related to FAI syndrome is scarce.

Regarding treatment alternatives, Güngör et al.¹¹⁾ reported that good short-term outcomes were achieved from use of a combination of OAT and OCP in patients with FAI syndrome. On the other hand, Zaltz and Leunig¹⁰⁾, who conducted an analysis of the results from use of different surgical techniques for treatment of ten patients with OCL of the femoral head associated with symptomatic FAI syndrome, reported that the femoral cartilage defect might have been caused by hip instability and the resulting shear forces. Treatment with femoral neck OCP and labral repair or debridement was administered in all ten cases. In addition, regarding OCL of the femoral head, 7/10 patients underwent treatment with microfracture and combined microfracture with autologous matrix-induced chondrogenesis was administered in the remaining three cases. All patients, except for one, had returned to their previous functional level at final follow-up.

OCA transplantation has been reported as a suitable alternative for treatment of OCL of the knee; however, data from analysis of the results of OCL of the femoral head is limited^{16,21)}. Khanna et al.¹⁶⁾, who conducted an analysis of the outcomes of 17 patients with OCL of the femoral head who were treated with OCA, reported fair to good functional results at a mean follow-up of 41.6 months in 76% of cases. Several conditions were identified, including OCD, osteonecrosis, Legg–Calve–Perthes, and a fracture of the femoral head. According to the conclusion made by the authors of the study, the perfect candidate would include a young patient with minimum osteoarthritic compromise or abnormality and no association with chronic steroid therapy¹⁶⁾. Similarly, in a study of ten patients, Oladeji et al.¹⁵⁾ reported 70% good results at a mean follow-up of 1.4 years. Acetabular compromise, osteonecrosis, smoking, and combined therapies were associated with inferior results.

The short-term outcomes of five patients with OCL of the femoral head and concomitant cam deformity who were treated successfully with a combination of OAT and femoral neck OCP through surgical dislocation of the hip have been reported in this case series. To the best of our knowledge, the current literature includes only a few cases involving use of this combined treatment. Despite its location far from the parafoveal area, we believe that cam impingement might have been involved in the genesis of OCL in the parafoveal region of the femoral head in these patients, providing support for the existing evidence showing that cam impingement in the context of FAI syndrome may be involved in the pathogenesis of OCL of the femoral head^{10,21,22)}.

OCL of the parafoveal region of the femoral head continues to be a challenge in orthopaedic practice. A diagnosis of OCL of the femoral head is not uncommon in patients with early degenerative osteoarthritis in the context of FAI syndrome. However, in all five cases the patients were young and active with a fully preserved range of hip motion. This case series demonstrates that, although it is a demanding procedure, OAT combined with femoral neck OCP through surgical dislocation of the hip appears to be a suitable surgical technique for treatment of young, active patients with extensive OCL of the femoral head and cam deformity. Use of this technique can result in restoration of hyaline cartilage and the underlying subchondral bone and repair of the impingement abnormality with restoration of hip biomechanics. Use of this technique might be helpful in achieving improvement of the functional outcomes and decreasing pain at short-term follow-up; however, conduct of further studies regarding long-term outcomes and progression of osteoarthritis will be required.

CONFLICT OF INTEREST

The authors declare that there is no potential conflict of interest relevant to this article.

REFERENCES

1. Atik OŞ. *The role of metabolomics in osteoarthritis for early diagnosis, monitoring prognosis and treatment. Eklem Hastalik Cerrahisi.* 2015;26:1. <https://doi.org/10.5606/ehc.2015.01>
2. D’Lima DD, Fregly BJ, Colwell CW Jr. *Implantable sensor technology: measuring bone and joint biomechanics of daily life in vivo. Arthritis Res Ther.* 2013;15:203. <https://doi.org/10.1186/ar4138>
3. Bowman KF Jr, Fox J, Sekiya JK. *A clinically relevant review of hip biomechanics. Arthroscopy.* 2010;26:1118-29. <https://doi.org/10.1016/j.arthro.2010.01.027>
4. Sotereanos NG, DeMeo PJ, Hughes TB, Bargiotas K, Wohlrab D. *Autogenous osteochondral transfer in the femoral head after osteonecrosis. Orthopedics.* 2008;31:177. <https://doi.org/10.3928/01477447-20080201-33>
5. McDonald JE, Herzog MM, Philippon MJ. *Return to play after hip arthroscopy with microfracture in elite athletes. Arthroscopy.* 2013;29:330-5. <https://doi.org/10.1016/j.arthro.2012.08.028>
6. Hangody L, Vásárhelyi G, Hangody LR, et al. *Autologous osteochondral grafting--technique and long-term results. Injury.* 2008;39 Suppl 1:S32-9. <https://doi.org/10.1016/j.injury.2008.01.041>
7. Fontana A, Bistolfi A, Crova M, Rosso F, Massazza G. *Arthroscopic treatment of hip chondral defects: autologous chondrocyte transplantation versus simple debridement--a pilot study. Arthroscopy.* 2012;28:322-9.

- <https://doi.org/10.1016/j.arthro.2011.08.304>
8. Gagala J, Tarczyńska M, Gawęda K. *Clinical and radiological outcomes of treatment of avascular necrosis of the femoral head using autologous osteochondral transfer (mosaicplasty): preliminary report.* *Int Orthop.* 2013;37:1239-44. <https://doi.org/10.1007/s00264-013-1893-6>
 9. Dallich AA, Rath E, Atzmon R, et al. *Chondral lesions in the hip: a review of relevant anatomy, imaging and treatment modalities.* *J Hip Preserv Surg.* 2019;6:3-15. <https://doi.org/10.1093/jhps/hnz002>
 10. Zaltz I, Leunig M. *Parafoveal chondral defects associated with femoroacetabular impingement.* *Clin Orthop Relat Res.* 2012;470:3383-9. <https://doi.org/10.1007/s11999-012-2453-x>
 11. Güngör HR, Kiter E, Ök N, Çatak A. *Osteochondral mosaicplasty along with osteochondroplasty of the femoral head in femoroacetabular impingement: a case report.* *Eklem Hastalik Cerrahisi.* 2015;26:181-4. <https://doi.org/10.5606/ehc.2015.37>
 12. Beck M, Kalhor M, Leunig M, Ganz R. *Hip morphology influences the pattern of damage to the acetabular cartilage: femoroacetabular impingement as a cause of early osteoarthritis of the hip.* *J Bone Joint Surg Br.* 2005;87:1012-8. <https://doi.org/10.1302/0301-620X.87B7.15203>
 13. El Bitar YF, Lindner D, Jackson TJ, Domb BG. *Joint-preserving surgical options for management of chondral injuries of the hip.* *J Am Acad Orthop Surg.* 2014;22:46-56. <https://doi.org/10.5435/JAAOS-22-01-46>
 14. Yamamoto Y, Ishibashi Y, Tsuda E, Sato H, Toh S. *Osteochondral autograft transplantation for osteochondritis dissecans of the elbow in juvenile baseball players: minimum 2-year follow-up.* *Am J Sports Med.* 2006;34:714-20. <https://doi.org/10.1177/0363546505282620>
 15. Oladeji LO, Cook JL, Stannard JP, Crist BD. *Large fresh osteochondral allografts for the hip: growing the evidence.* *Hip Int.* 2018;28:284-90. <https://doi.org/10.5301/hipint.5000568>
 16. Khanna V, Tushinski DM, Drexler M, et al. *Cartilage restoration of the hip using fresh osteochondral allograft: resurfacing the potholes.* *Bone Joint J.* 2014;96-B(11 Supple A):11-6. <https://doi.org/10.1302/0301-620X.96B11.34734>
 17. Jordan MA, Van Thiel GS, Chahal J, Nho SJ. *Operative treatment of chondral defects in the hip joint: a systematic review.* *Curr Rev Musculoskelet Med.* 2012;5:244-53. <https://doi.org/10.1007/s12178-012-9134-y>
 18. Gibson A. *Posterior exposure of the hip joint.* *J Bone Joint Surg Br.* 1950;32-B:183-6. <https://doi.org/10.1302/0301-620X.32B2.183>
 19. Ganz R, Gill TJ, Gautier E, Ganz K, Krügel N, Berlemann U. *Surgical dislocation of the adult hip a technique with full access to the femoral head and acetabulum without the risk of avascular necrosis.* *J Bone Joint Surg Br.* 2001;83:1119-24. <https://doi.org/10.1302/0301-620X.83b8.11964>
 20. Ganz R, Parvizi J, Beck M, Leunig M, Nötzli H, Siebenrock KA. *Femoroacetabular impingement: a cause for osteoarthritis of the hip.* *Clin Orthop Relat Res.* 2003;(417):112-20.
 21. Garcia-Mansilla I, Jones KJ, Sassoon AA. *Surgical hip dislocation and fresh osteochondral allograft transplantation for femoroacetabular impingement and concomitant chondral lesion.* *Arthrosc Tech.* 2020;9:e1857-63. <https://doi.org/10.1016/j.eats.2020.08.012>
 22. Charbonnier C, Kolo FC, Duthon VB, et al. *Assessment of congruence and impingement of the hip joint in professional ballet dancers: a motion capture study.* *Am J Sports Med.* 2011;39:557-66. <https://doi.org/10.1177/0363546510386002>
 23. Krych AJ, Lorch DG, Kelly BT. *Osteochondral autograft transfer for a posttraumatic osteochondral defect of the femoral head.* *Am J Orthop (Belle Mead NJ).* 2012;41:472-6.
 24. Nam D, Shindle MK, Buly RL, Kelly BT, Lorch DG. *Traumatic osteochondral injury of the femoral head treated by mosaicplasty: a report of two cases.* *HSS J.* 2010;6:228-34. <https://doi.org/10.1007/s11420-010-9159-y>
 25. Rittmeister M, Hochmuth K, Kriener S, Richolt J. *[Five-year results following autogenous osteochondral transplantation to the femoral head].* *Orthopade.* 2005;34:320, 322-6. <https://doi.org/10.1007/s00132-005-0776-y>
 26. Byrd JW. *Lateral impact injury. A source of occult hip pathology.* *Clin Sports Med.* 2001;20:801-15. [https://doi.org/10.1016/S0278-5919\(05\)70286-6](https://doi.org/10.1016/S0278-5919(05)70286-6)