



Pathologic Fracture of Femoral Neck in a Patient with Tumoral Calcinosis

Seong-San Park, MD, Soo Jae Yim, MD, PhD, Sin Hyung Park, MD, PhD

Department of Orthopedic Surgery, Soonchunhyang University Bucheon Hospital, Bucheon, Korea

Tumoral calcinosis is a rare disease characterized by massive subcutaneous soft tissue deposits of calcium phosphate around large joints in patients with chronic kidney disease. Invasion of bone by tumoral calcinosis is rare. We experienced a case involving a femoral neck pathologic fracture due to bony invasion of tumoral calcinosis in a 46-year-old female with chronic kidney disease who had been on dialysis for 15 years. Successful outcomes were obtained by performance of total hip arthroplasty for treatment of the pathologic fracture of the femoral neck. Careful precaution is necessary to prevent pathologic fractures in patients with tumoral calcinosis around the hip joint.

Key Words: Tumoral calcinosis, Total hip arthroplasty, Pathologic fracture

A clinical case of a calcific cystic tumor of soft tissue was first introduced by Duret in 1899. These calcific tumors were named tumoral calcinosis by Inclin in 1943. Tumoral calcinosis is a rare disease, characterized by the deposition of calcium and hydroxyapatite in the soft tissues around the joints, and generally has a lobed shape¹⁾. Tumoral calcification usually occurs around large joints; the most common areas are the hip joint, elbow joint, and shoulder joint²⁻³⁾. Diagnosis of tumoral calcinosis is usually made according to clinical symptoms and imaging methods include plain

radiographs, computed tomography (CT), and magnetic resonance imaging (MRI). This should be differentiated from diseases such as milk-alkali syndrome or hyperparathyroidism, osteochondroma, and chondrosarcoma^{4,5)}.

Tumoral calcinosis is a rare complication of chronic kidney disease (CKD). It was reported to occur in approximately 1.6% of dialysis patients in a Japanese study. It does not respond well to medical treatment in patients with CKD. Therefore, surgical treatment is required in most cases⁶⁾. Although there is usually no involvement of bone, rare cases of intraosseous penetration have been reported⁷⁾. We experienced a case involving a pathologic fracture that occurred without trauma due to bone marrow invasion of tumoral calcinosis. To the best of our knowledge, no case of tumoral calcinosis invading into the bone marrow and causing pathologic fractures has been reported.

This article describes a case of pathologic femoral neck fracture that occurred without trauma due to bone invasion of tumoral calcinosis.

CASE REPORT

A 46-year-old female patient visited the emergency room with a chief complaint of pain over the left hip joint with

Submitted: September 23, 2021 **1st revision:** October 27, 2021

Final acceptance: October 29, 2021

Address reprint request to

Sin Hyung Park, MD, PhD

(<https://orcid.org/0000-0003-1804-0986>)

Department of Orthopedic Surgery, Soonchunhyang University Bucheon Hospital, 170 Jomaru-ro, Wonmi-gu, Bucheon 14584, Korea

TEL: +82-32-621-6706 **FAX:** +82-32-621-6950

E-mail: greatsin@empal.com

This is an Open Access article distributed under the terms of the Creative Commons Attribution Non-Commercial License (<http://creativecommons.org/licenses/by-nc/4.0>) which permits unrestricted non-commercial use, distribution, and reproduction in any medium, provided the original work is properly cited.

no history of trauma the day before. She ordinarily had a mass-like lesion around the left thigh and intermittent pain around the hip joint. The pain had become aggravated the day before as she could not place her foot on the ground. She has undergone hemodialysis three times a week after diagnosis with CKD 15 years ago. In addition, she has taken medication for hypertension diagnosed 15 years ago. On physical examination, the left hip was abducted and externally rotated; a positive Patrick sign and loss of range of motion of the left hip joint was observed. However, no neurological or vascular deficits were observed. A mass-like lesion was observed around the left thigh. The mass measured 15 cm × 15 cm in size. It had a fixed lobulated round shape with tenderness. No other specific findings were observed around the skin.

Simple radiographs of the pelvis (anteroposterior view) showed the presence of a multiple calcified mass around the left hip joint (Fig. 1). CT images of the pelvis confirmed the presence of multiple calcified masses at the soft tissue level, containing fluid-calcium level (called to sedimentation sign). In particular, a calcified mass had infiltrated into the trabecular space of the femoral neck. In addition, a fracture in the femoral neck of Garden type III was confirmed (Fig. 2). An MRI showed that the lesion had in-homogeneous high-signal intensity with T2-weighted. A T1-weight-

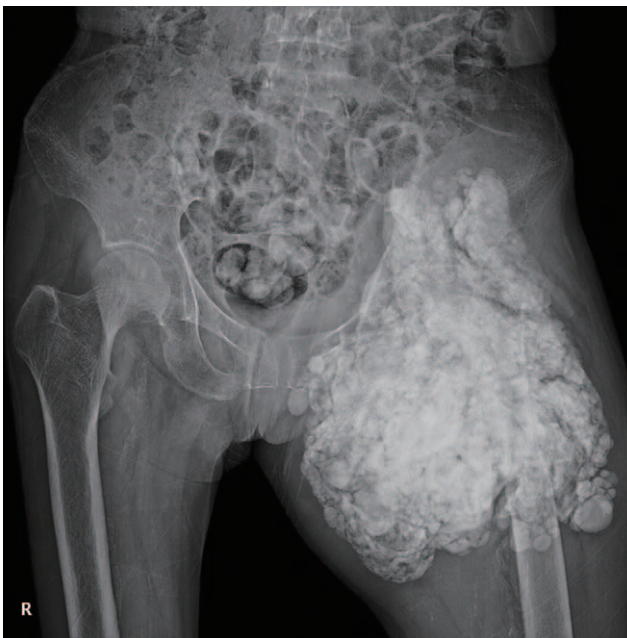

Fig. 1. Preoperative plain radiographs of the femoral neck fracture with tumoral calcinosis. The presence of a multiple calcified mass was observed around the left hip joint. The femur neck fracture is not presented clearly because of calcific deposits.

ed image showed low signal in-homogeneous lesions. Multiple masses infiltrated the left iliopsoas, obturator internus, piriformis, other proximal thigh muscle, and femoral neck with proximal marrow accompanied by a pathologic fracture of the femoral neck (Fig. 3).

A laboratory evaluation showed that total calcium level and phosphorus level had increased to 10.4 mg/dL and 6.0 mg/dL. The parathyroid hormone (PTH) level also increased to 695.30 pg/mL. An ultrasound of the neck and thyroid showed a hypoechoic nodule measuring 3.5 cm in size with internal microcalcification in the right middle pole. A parathyroid methoxyisobutylisonitrile (MIBI) scan showed focal MIBI uptake in the posterior aspect of the right thyroid gland mid pole with microcalcifications. Thus, parathyroid adenoma was estimated. Phosphate binder (sevelamer) and the inhibitor of PTH (calcitriol) were prescribed first. However, the symptoms did not improve. Therefore, a parathyroidectomy is planned, and will be performed simultaneously with performance of total hip arthroplasty.

Total hip arthroplasty was performed for the pathological fracture of the femoral neck (Fig. 4). Hemodialysis was performed the day before surgery, and on the day of surgery, the patient was placed in a lateral position under general anesthesia, and the modified Watson-Jones approach was used. A 15-cm skin incision was made, and the fascia lata was split and an incision was made approximately 1 cm distal to the gluteus medius muscle until the gluteus minimus muscle was exposed, and the middle of the tendon of the gluteus minimus muscle was incised. A hormann retractor was used to expose the capsule and the articular membrane was excised in a reverse ‘T’ shape, followed by removal

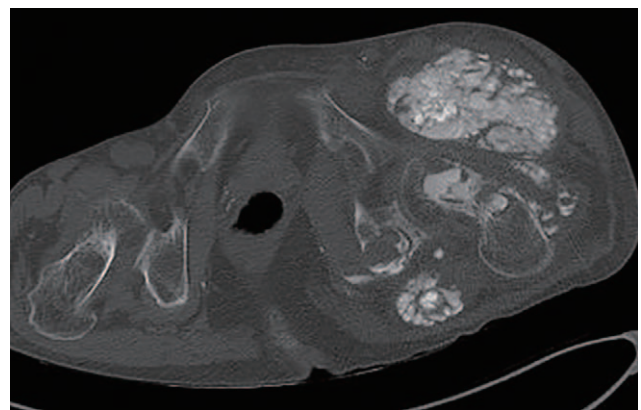


Fig. 2. Preoperative axial view of the pelvic computed tomography. It showed intramedullary invasion of the tumoral calcinosis accompanied by pathologic fractures of the femoral neck.

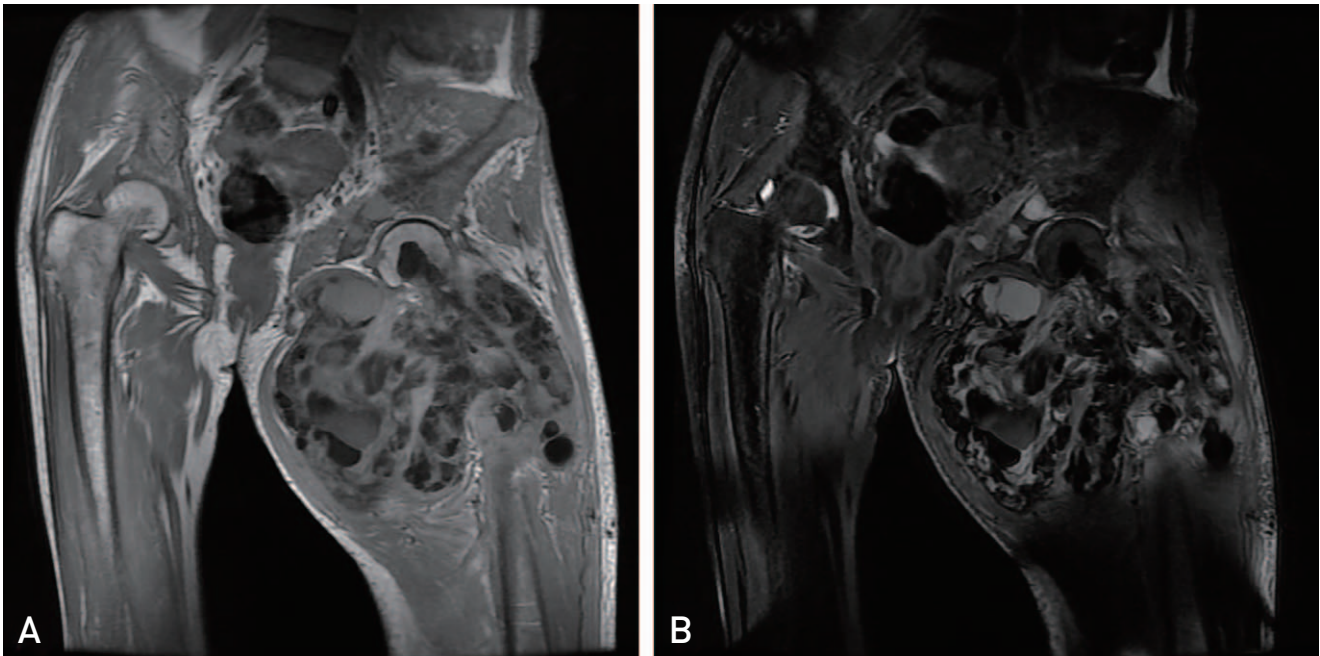


Fig. 3. Preoperative coronal view of magnetic resonance imaging. (A) T2-weighted sequence of the pelvis. (B) T1-weighted sequence of the pelvis. The lesion had in-homogeneous high-signal intensity with T2-weighted image and in-homogeneous low signal with T1-weighted image. It showed bony invasion of tumoral calcinosis in the femoral neck.

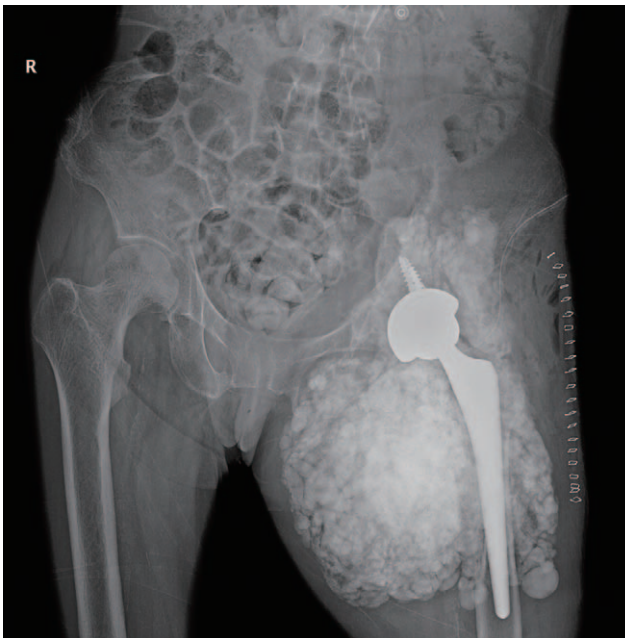


Fig. 4. Postoperative plain radiographs after left total hip arthroplasty.

of the femoral head. The acetabular cup was inserted first, and the femur was externally rotated for insertion of a femoral prosthesis. The calcific tumor had a gray, mucinous gum shape and invaded the femoral neck and some of the femoral shaft. Because the calcified tumors had extensive-

ly invaded the soft tissues of the hip joint, only those that interfered with the operation were removed while approaching without removing them all. The result of histologic finding showed extensive calcification consistent with tumoral calcinosis cutis.

Thromboprophylaxis and antibiotic prophylaxis were administered after surgery. The patient was allowed to stand on the second or third postoperative day and to progress to full weight bearing with a walker as tolerated. The patient was discharged without complications after surgery. She visited the out-patient clinic at three months, six months, and one year to undergo clinical and radiologic examination. She walked very well without limping or crutch. The radiologic evaluation found no complications.

The authors confirm that the patient provided informed consent for publication of this case report.

DISCUSSION

Tumoral calcinosis is a disease first named by Inclan in 1943; secondary, uremic tumoral calcinosis caused by chronic nephropathy, is a rare phenomenon occurring in 0.5% to 3% of patients with renal failure⁸⁾. Although the cause of this disease has not been clearly elucidated, the most important factor among various causes is hyperphosphatemia, which was found in most patients regardless of serum calcium lev-

els⁹). Tumoral calcinosis is manifested as various forms on imaging tests. In the hip joint, a simple radiograph shows multiple nodules on the lateral side of the joint, and calcific materials are separated by translucent bands⁴). The CT image shows the characteristic 'sedimentation sign' observed due to the calcium-fluid layer in the tumor. On MRI, the T1- and T2-weighted images are shown to be mixed; however, most show low signals¹⁰). Pathological findings show calcium accumulation. Histological diagnosis is possible due to the density of giant cells and inflammatory cells at the edges accompanied by the accumulation¹¹).

Tumoral calcinosis is usually classified as primary or secondary form. The primary tumoral calcinosis known as hyperphosphatemic familial tumoral calcinosis (HFTC) is caused by genetic mutations in genes including fibroblast growth factor 23 (FGF23) related to phosphate regulation and results in hyperphosphatemia^{12,13}). Secondary tumoral calcinosis, which occurs mainly in patients with CKD, causes hyperparathyroidism. In chronic hemodialysis patients, hyperparathyroidism increases the uncontrolled secretion of PTH. The unremitting release of calcium from bone increases the formation of calcium-phosphate product, and enhances the extra-articular deposition of hydroxyapatite^{14,15}).

Invasion of bone by tumoral calcinosis is rare, and has rarely been reported. Girard et al.⁷) reported a case of a 55-year-old female with chronic renal failure and secondary tumoral calcinosis with rare intraosseous penetration of the humerus. Steinbach et al.¹⁰), who reviewed radiologic findings, medical records, and pathologic findings of 12 patients with tumoral calcinosis, reported osseous erosion adjacent to the mass in three cases. In one case, erosion was observed along the undersurface of the humeral head, and a large erosion of the femoral neck was observed in another case. Meltzer et al.¹⁶) reported a case of a 73-year-old female with erosion of the iliac crest due to tumoral calcinosis. In our case, a large area of tumoral calcinosis was observed around the hip joint, which invaded into the bone marrow of the femur. Therefore, a pathologic fracture occurred without trauma due to bone marrow invasion of tumoral calcinosis. To the best of our knowledge, no case of tumoral calcinosis invading into the bone marrow and causing pathologic fractures has been reported.

Medical therapy is one of the options for treatment of tumoral calcinosis. The method of therapy can differ with regard to etiologies of tumoral calcinosis. In cases involving tumoral calcinosis that occurred due to uremic calcinosis, elevation of calcium phosphate can occur due to hyperphosphatemia^{8,17}). Therefore, treatment of chronic hyperphosphatemia in patients with CKD includes a low calcium diet, low phosphate diet, and phosphate binders^{9,18}). Also, administration of acetazolamide is required to increase excretion of urinary phosphate¹⁹). If the medical treatment fails, subtotal parathyroidectomy and surgical resection can be performed²⁰). In the current report, total hip arthroplasty was selected as a treatment for pathologic fractures of the femoral neck. Because the calcified mass of tumoral calcinosis was huge, and loss of soft tissue and increased bleeding could have occurred if a resection was performed, we did not resect the entire mass of tumoral calcinosis. And the patient did not have pain from the calcified mass prior to occurrence of the pathologic fracture. There was concern that accessing the hip joint would be difficult due to the mass; however, it was possible to reach the hip joint without problems.

Because tumoral calcinosis is a rare disease, making a diagnosis before surgery or to provide appropriate treatment is difficult. Tumoral calcinosis is usually found in soft tissues around large joints. Invasion of bone by tumoral calcinosis is rare. In our case, it was found that tumoral calcinosis can invade into the bone of the femoral neck and can cause pathological fractures. Successful outcomes were obtained by performance of total hip arthroplasty for treatment of the pathologic fracture of the femoral neck. Careful precaution is necessary to prevent pathologic fractures in patients with tumoral calcinosis around the hip joint.

Because tumoral calcinosis is a rare disease, making a diagnosis before surgery or to provide appropriate treatment is difficult. Tumoral calcinosis is usually found in soft tissues around large joints. Invasion of bone by tumoral calcinosis is rare. In our case, it was found that tumoral calcinosis can invade into the bone of the femoral neck and can cause pathological fractures. Successful outcomes were obtained by performance of total hip arthroplasty for treatment of the pathologic fracture of the femoral neck. Careful precaution is necessary to prevent pathologic fractures in patients with tumoral calcinosis around the hip joint.

CONFLICT OF INTEREST

The authors declare that there is no potential conflict of interest relevant to this article.

REFERENCES

1. Olsen KM, Chew FS. *Tumoral calcinosis: pearls, polemics, and alternative possibilities. Radiographics.* 2006;26:871-85.
2. Chaabane S, Chelli-Bouaziz M, Jelassi H, Mrad K, Smida M, Ladeb MF. *Idiopathic tumoral calcinosis. Acta Orthop Belg.* 2008;74:837-45.
3. Knowles SA, Declerck G, Anthony PP. *Tumoral calcinosis. Br J Surg.* 1983;70:105-7.
4. Martinez S, Vogler JB 3rd, Harrelson JM, Lyles KW. *Imaging of tumoral calcinosis: new observations. Radiology.* 1990;174:215-22.
5. Bishop AF, Destouet JM, Murphy WA, Gilula LA. *Tumoral calcinosis: case report and review. Skeletal Radiol.* 1982;8:269-74.
6. Kim Y, Hwang E, Park S. *Resolution of uremic tumoral calcinosis in a patient on peritoneal dialysis with long-term low-calcium dialysate treatment. Kidney Res Clin Pract.* 2014;33:226-8.

7. Girard CJ 2nd, Wasserman PL, Lenchik L. *Secondary tumoral calcinosis with intraosseous penetration. Radiol Case Rep.* 2016;4:213.
8. Chu HY, Chu P, Lin YF, Chou HK, Lin SH. *Uremic tumoral calcinosis in patients on peritoneal dialysis: clinical, radiologic, and laboratory features. Perit Dial Int.* 2011;31:430-9.
9. Sunder S, Verma H, Venkataramanan K. *Cervical tumoral calcinosis with secondary hyperparathyroidism in a chronic hemodialysis patient. Hemodial Int.* 2013;17:458-62.
10. Steinbach LS, Johnston JO, Tepper EF, Honda GD, Martel W. *Tumoral calcinosis: radiologic-pathologic correlation. Skeletal Radiol.* 1995;24:573-8.
11. Kindblom LG, Gunterberg B. *Tumoral calcinosis. An ultrastructural analysis and consideration of pathogenesis. APMIS.* 1988;96:368-76.
12. Boyce AM, Lee AE, Roszko KL, Gafni RI. *Hyperphosphatemic tumoral calcinosis: pathogenesis, clinical presentation, and challenges in management. Front Endocrinol (Lausanne).* 2020;11:293.
13. Carmichael KD, Bynum JA, Evans EB. *Familial tumoral calcinosis: a forty-year follow-up on one family. J Bone Joint Surg Am.* 2009;91:664-71.
14. Hamada J, Tamai K, Ono W, Saotome K. *Uremic tumoral calcinosis in hemodialysis patients: clinicopathological findings and identification of calcific deposits. J Rheumatol.* 2006;33:119-26.
15. Younes M, Belghali S, Zrour-Hassen S, Béjia I, Touzi M, Bergaoui N. *Complete reversal of tumoral calcinosis after subtotal parathyroidectomy in a hemodialysis patient. Joint Bone Spine.* 2008;75:606-9.
16. Meltzer CC, Fishman EK, Scott WW Jr. *Tumoral calcinosis causing bone erosion in a renal dialysis patient. Clin Imaging.* 1992;16:49-51.
17. Lebl DR, Girardi FP. *Isolated cervical spine facet joint tumoral calcinosis. Spine J.* 2013;13:208-9.
18. Eddington H, Hoefield R, Sinha S, et al. *Serum phosphate and mortality in patients with chronic kidney disease. Clin J Am Soc Nephrol.* 2010;5:2251-7.
19. Yamaguchi T, Sugimoto T, Imai Y, Fukase M, Fujita T, Chihara K. *Successful treatment of hyperphosphatemic tumoral calcinosis with long-term acetazolamide. Bone.* 1995;16(4 Suppl):247S-50S.
20. Möckel G, Buttgereit F, Labs K, Perka C. *Tumoral calcinosis revisited: pathophysiology and treatment. Rheumatol Int.* 2005;25:55-9.