



# Biomechanical Comparative Study for Osteosynthesis of Pauwels Type III Femoral Neck Fractures: Conventional Devices versus Novel Fixed Angle Devices

Dae-Hyun Park, MD, Young-Chae Seo, MD, Yong-Uk Kwon, MD, Soo-Hwan Jung, MD, Seung-Jin Yoo\*

*Department of Orthopedic Surgery, Inje University Busan Paik Hospital, Inje University College of Medicine, Busan, Korea  
R&D Center, IKEY Co., Ltd., Busan, Korea\**

**Purpose:** Osteosynthesis has been recommended for treatment of Pauwels type III femoral neck fractures in young patients. However, no implant of choice has been reported so far. This study was conducted in order to compare the fixation stability of two conventional fixation methods with three different novel fixed angle devices in this type of fracture.

**Materials and Methods:** A total of 25 composite femurs (4th Generation Saw bone; Pacific Research Laboratories, USA) corresponding to human bone were used. Pauwels type III fracture type was uniformly reproduced. Specimens were fixed with a cannulated screw, cannulated screw with cable, and Intertan nail, dynamic hip screw, and IKEY nail. Measurement of failure loads and the rotational change of the femoral head fragment was performed for evaluation of fixation stability.

**Results:** All implants were compared with cannulated screw and dynamic hip screw. No meaningful improvement was observed for the cannulated screw with cable compared with the cannulated screw and dynamic hip screw. Meaningful improvement in load-to-failure and y-rotation and z-rotation was observed for both the Intertan nail and IKEY nail compared with the cannulated screw. However, compared with the dynamic hip screw, only the IKEY nail showed improvement in the same profile but the Intertan nail did not.

**Conclusion:** Among novel fixed angle devices, meaningful improvement was observed for the IKEY nail compared with conventional implants. Strengths of this implant include biomechanical stability and simplicity of surgical technique, indicating that it may be another good option for osteosynthesis of Pauwels type III femoral neck fractures.

**Key Words:** Femoral neck fractures, Fracture fixation, Bone screws, Femur

**Submitted:** July 12, 2021 **1st revision:** September 22, 2021  
**2nd revision:** November 10, 2021 **Final acceptance:** November 10, 2021

**Address reprint request to**

**Yong-Uk Kwon, MD**

(<https://orcid.org/0000-0003-0472-5044>)

Department of Orthopedic Surgery, Inje University Busan Paik Hospital, 75 Bokji-ro, Busanjin-gu, Busan 47392, Korea

**TEL:** +82-51-890-6257 **FAX:** +82-51-890-5804

**E-mail:** kyw2848@hanmail.net

This is an Open Access article distributed under the terms of the Creative Commons Attribution Non-Commercial License (<http://creativecommons.org/licenses/by-nc/4.0>) which permits unrestricted non-commercial use, distribution, and reproduction in any medium, provided the original work is properly cited.

## INTRODUCTION

Femoral neck fractures typically occur in young patients as a result of high-energy trauma or in elderly patients with osteoporosis<sup>1,2</sup>. Fractures occurring in the former age group commonly show a pattern of Pauwels type III fractures. Osteosynthesis has been a treatment of choice for this type of fracture due to longer life expectancy and high activity level<sup>3-5</sup>. Internal fixation using three cannulated screws, which is sufficient for management of Pauwels type I and II femoral neck fractures<sup>3,6</sup>, resulted in high complication rates, including femoral neck shortening, non-union, and avascular necrosis. Fixed angle devices including dynamic hip screws have been introduced in an effort to resist the shearing force, not only the compressive forces<sup>7,8</sup>. Currently, cannulated screw fixation and dynamic hip screw fixation have been proposed as a conventional method<sup>1,9</sup>. Meanwhile, numerous biomechanical and clinical studies regarding other types of fixed angle devices are being conducted; however, an implant of choice has yet to be identified. In an effort to discover optimal methods, our study was conducted as a biomechanical comparison of two types of conventional devices (cannulated screws, dynamic hip screw) with three types of novel fixed-angle devices; cannulated screws with cable, Intertan nail, and IKEY nail.

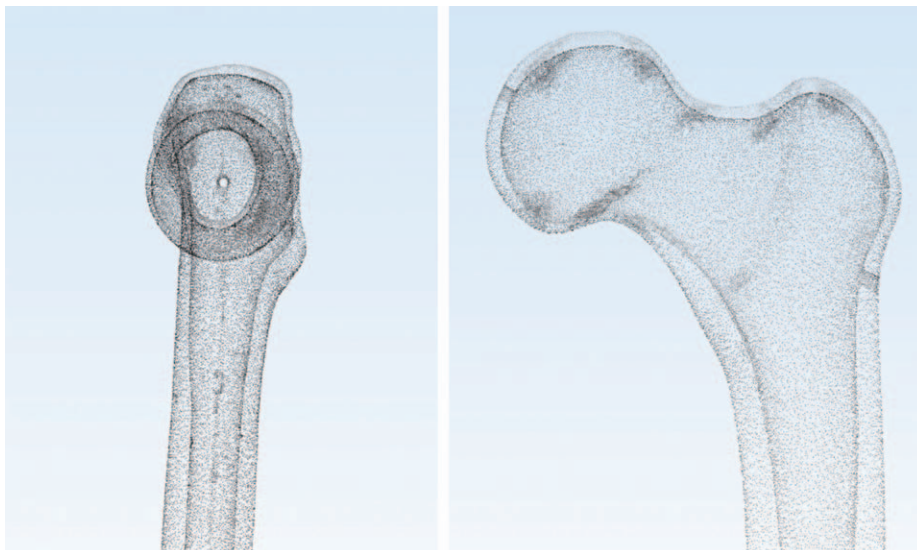
## MATERIALS AND METHODS

### 1. Specimen Preparation


A total of 25 composite femurs (4th Generation Saw bone; Pacific Research Laboratories, Vashon, WA, USA) corresponding to human bone were used. All specimens had a 2-mm diameter canal passing through the center of the femoral head and neck, which is used as a landmark for insertion of screws (Fig. 1). In order to ensure similar bone quality, C-arm radiographs were used in evaluation of all specimen femurs to exclude any specimen with pathologic lesions. Pauwels type III fracture type was uniformly reproduced in 25 composite femur models using custom-made saw guides, showing a 70° oblique fracture line (Fig. 2).

### 2. Surgical Technique


Specimens were fixed with a cannulated screw (Type 1), cannulated screw with cable (Type 2), Intertan nail (Type 3), dynamic hip screw (Type 4), and IKEY nail system (Type 5) (Fig. 3). The surgical procedure for these models was established by one orthopedic surgeon. Cannulated screw fixation was performed using the partially threaded 7.0 mm IKEY cannulated screw system. In order to reproduce uniform implant fixation, screws are inserted in an inverted triangular shape, each at the point 5 mm away from the canal pass-



**Fig. 1.** 4th generation saw bone (Pacific Research Laboratories, USA) was used for femur specimen. All specimen have 2-mm diameter canal passing through center of femoral head and neck. This figure is image reconstructed by three-dimensional computed tomography, including the canal.



**Fig. 2.** (A) In order to reproduce uniform fracture line in 25 composite femur, custom-made saw guide is made. It consists of two parts, divided by 70° oblique line which represents Pauwels type III fracture. (B) Custom-made saw guide applied in cephalocervical area of the specimen. (C) After guide application, manual cutting was done along the line.



**Fig. 3.** Five different types of osteosynthesis were done in femur specimen. In order to reproduce uniform implant fixation in type I, cannulated screw was inserted 5 mm away from the central canal in inverted triangular fashion.


ing the specimen. The Type 2 method was performed by wrapping a cable after cannulated screw fixation. Following insertion of three cannulated screws, the same as Type 1, a cable was passed through a hole in the head of the cannulated screws. After passing the wire, which eventually formed a round shape, both ends of the cable were tightened and wrapped. Intertan nail and IKEY nail fixation was performed using a 9-mm diameter nail. The starting point was determined to be slightly medial to the tip of the greater trochanter. After nail insertion, two and three cephalocervical screws were fixed in each group, passing through apertures in each nail. Finally, distal locking screws were inserted. The Type 4 method was performed using the CHS Plate System (Orthotech, Hanam, Korea). Three-hole plates were used and secured to the femoral shaft with one lag screw and three cortical screws. After implant fixation in all five types, reduction was confirmed under C-arm radiographs. All specimens showed less than 2 mm of displacement and less than 5° of angulation in anterior-posterior view and axial view, which satisfied our conventional criteria of anatomical reduction<sup>10</sup>. The distal femoral condyles of all instrumented specimens were removed, and the femoral shafts were potted with zigs at an angle of valgus 25°. This degree of angle was set to simulate normal one-legged weight bearing stance (Fig. 4).

### 3. Biomechanical Testing

Tests were performed in the order of preliminary (100

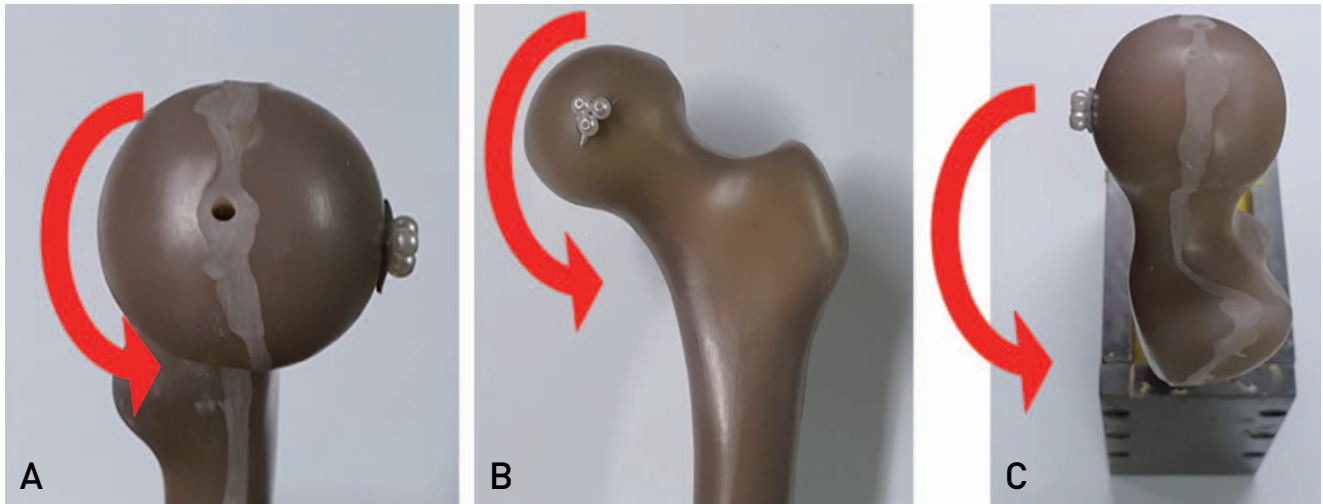
N, 20 N/min), dynamic (75-750 N, 10,000 cycles, 2 Hz), and static (10 mm/min) loading using a universal testing machine (MTS 858 Bionix test system; MTS System, Eden Prairie, MN, USA) (Fig. 4). These loading rates were selected to assume fast walking at the period of bone consolidation six weeks after surgery.

Measurement of failure loads and the rotational change of the femoral head fragment was performed for evaluation of fixation stability. Load-to-failure was measured at the time when the fracture of the specimen occurred. Rotatory deformities of the femoral head fragment were measured by tracking the position of three markers (diameter=1 mm) placed in front of the femoral head using a 3-D Coordinate Measuring Machine (Microscribe G2L; Immersion, San Jose, CA, USA). The x-rotation was defined as femoral head rotation occurring in the sagittal plane, viewing the specimen on the medial side. This type of rotation represents the rotation of the femoral head itself around the longitudinal axis of the femoral neck. The y-rotation was defined as femoral head rotation occurring in the coronal plane, viewing the specimen on the anterior side. This type of rotation represents the valgus or varus deformity of the fractured femoral neck. The z-rotation was defined as femoral head rotation occurring in the axial plane, viewing the specimen on the superior side. This type of rotation represents anterecurvatum deformity of the fractured femoral neck. The results were recorded as positive when the direction of the rotation is counterclockwise and vice versa in all three axes (Fig. 5).



**Fig. 4.** For the experiment, sawbone was fixed with the angle of 25, which presumes anatomical axis of femur. MTS 858 Bionix test system was used for preliminary, dynamic, and static loading. Each settings for loading were chosen to assume fast walking at the period of bone consolidation 6 weeks after surgery.





**Fig. 5.** Rotational deformity of the femoral head fragment was measured in three different planes. (A) X-rotation is rotation occurred in sagittal plane, representing femoral head rotation around the longitudinal axis of femoral head. (B) Y-rotation is rotation occurred in coronal plane, representing valgus or varus deformity. (C) Z-rotation is rotation occurred in axial plane, representing anterecurvatum deformity.

**Table 1.** Load-to-Failure of 5 Different Implants

	Type 1	Type 2	Type 3	Type 4	Type 5	P-value*
Load-to-failure (n)	2,039.57±252.46	2,613.72±291.33	3,549.28±544.20	2,957.75±87.54	4,533.28±86.87	<0.001

Values are presented as mean±standard deviation.

Type 1: cannulated screw, Type 2: cannulated screw with cable, Type 3: Intertan nail, Type 4: dynamic hip screw, Type 5: IKEY nail. \* Kruskal–Wallis test was done, and post-hoc analysis was performed with the significance level corrected by the Bonferroni method.

#### 4. Statistical Analysis

Statistical analysis was performed using the IBM SPSS Statistics software (ver. 25; IBM, Armonk, NY, USA). A normality test was performed for screening of normal distribution of load-to-failure and rotational deformities of each five groups. Because the distribution did not approximate a normal distribution, an analysis was performed using the Kruskal–Wallis test. Statistical significance was set at  $P < 0.05$ , and when a significant probability was found using the Kruskal–Wallis test, a post-hoc analysis was performed using the Bonferroni method. Because load-to-failure and rotational deformity showed statistical significance, we moved on to the next step. Statistical differences between all novel fixed angle devices (cannulated screw with cable, Intertan nail, IKEY nail) and conventional devices (cannulated screw, dynamic hip screw) were compared. Because the distribution did not approximate a normal distribution, statistical differences were assessed using the Wilcoxon rank sum test.

#### RESULTS

A summary of the mean and standard deviation of load-to-failure and the degree of rotational deformity for each types of device is shown in Tables 1 and 2, respectively. Means are visualized by graphs in Fig. 6 and 7. A summary of the comparison between conventional devices and novel fixed-angle devices is shown in Tables 3-6.

Overall, no meaningful improvement in load-to-failure and rotational deformity was observed for the cannulated screw with cable compared with conventional devices. Intertan nail and IKEY nail showed 3,549.28±544.20 N and 4,533.28±86.87 N each; both showing meaningful improvement ( $P < 0.05$ ) compared with the cannulated screw. Meanwhile, compared with the dynamic hip screw, the IKEY nail was the only device showing meaningful improvement in load-to-failure.

Regarding rotational deformity, there was no meaningful difference in x-axis rotation. Less degree of deformity was observed for both the Intertan nail and the IKEY nail

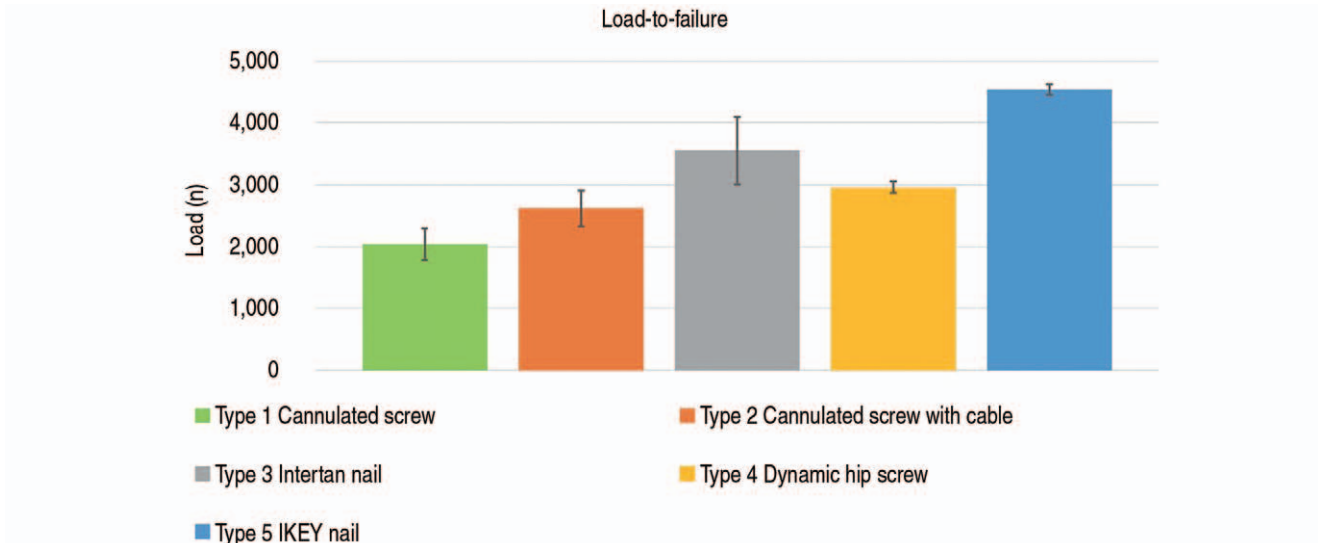
**Table 2.** Rotational Deformity of 5 Different Implants (unit: °, absolute value)

	Type 1	Type 2	Type 3	Type 4	Type 5	P-value*
X-axis	0.27±0.21	0.27±0.16	0.65±0.24	0.27±0.15	0.05±0.03	<0.001
Y-axis	1.44±1.07	1.27±0.89	0.22±0.11	1.19±0.46	0.05±0.03	0.007
Z-axis	2.25±1.78	1.32±0.85	1.03±0.44	2.05±0.72	0.04±0.02	0.01

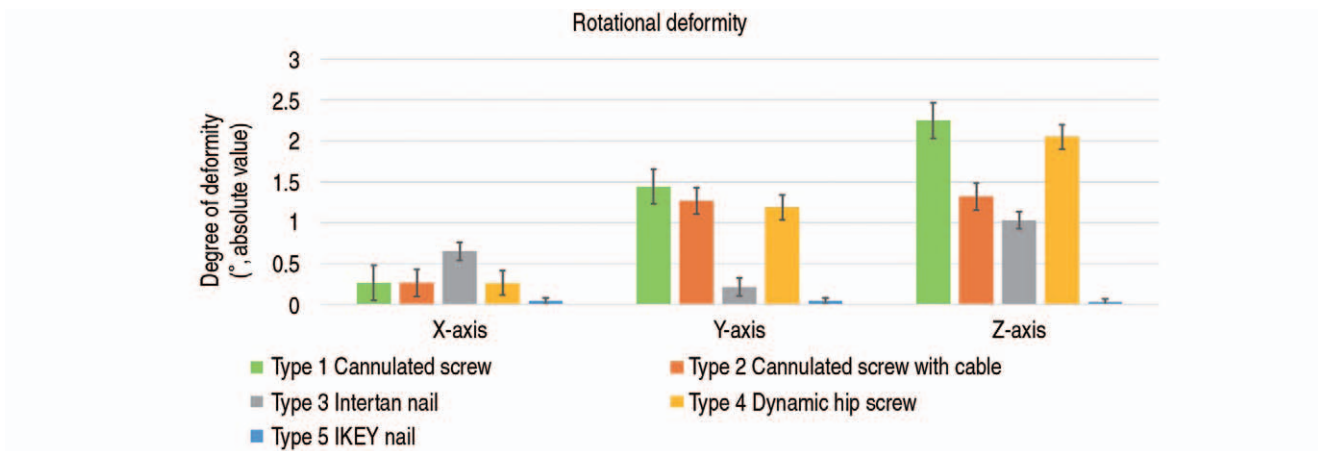
Values are presented as mean±standard deviation.

Type 1: cannulated screw, Type 2: cannulated screw with cable, Type 3: Intertan nail, Type 4: dynamic hip screw, Type 5: IKEY nail.

\* Kruskal–Wallis test was done, and post-hoc analysis was performed with the significance level corrected by the Bonferroni method.



**Fig. 6.** Bar and whisker chart for load-of-failure of each devices. Values are presented as mean±standard deviation.



**Fig. 7.** Bar and whisker chart for rotational deformity of each devices. Three separate charts stands for deformity of x-rotation, y-rotation, and z-rotation, respectively. Values are presented as mean±standard deviation.

compared with the cannulated screw in y-axis and z-axis. Compared with the dynamic hip screw, meaningful improvement in y-axis was observed for both, but only the IKEY nail showed improvement in z-axis.

## DISCUSSION

In Pauwels type III femoral neck fractures, vertical orientation of the pattern is known to be susceptible to greater

**Table 3.** Comparison of Load-to-Failure between Novel Fixed Angle Devices (Type 2, 3, 5) with Cannulated Screws Fixation (Type 1)

Load-to-failure (n)		P-value*
Type 1 2,035.57 (1,829.01-2,451.78)	Type 2 2,604.78 (2,319.06-3,084.39)	0.07
Type 1 2,035.57 (1,829.01-2,451.78)	Type 3 3,538.18 (2,801.09-4,338.52)	0.03
Type 1 2,035.57 (1,829.01-2,451.78)	Type 5 4,531.28 (4,415.29-4,649.39)	0.03

Values are presented as median (interquartile range).

Type 1: cannulated screw, Type 2: cannulated screw with cable, Type 3: Intertan nail, Type 5: IKEY nail.

\* Wilcoxon rank sum test.

**Table 4.** Comparison of Load-to-Failure between Novel Fixed Angle Devices (Type 2, 3, 5) with Dynamic Hip Screw Fixation (Type 4)

Load-to-failure (n)		P-value*
Type 4 2,957.76 (2,837.76-3,073.86)	Type 2 2,604.78 (2,319.06-3,084.39)	0.18
Type 4 2,957.76 (2,837.76-3,073.86)	Type 3 3,538.18 (2,801.09-4,338.52)	0.18
Type 4 2,957.76 (2,837.76-3,073.86)	Type 5 4,531.28 (4,415.29-4,649.39)	0.03

Values are presented as median (interquartile range).

Type 2: cannulated screw with cable, Type 3: Intertan nail, Type 4: dynamic hip screw, Type 5: IKEY nail.

\* Wilcoxon rank sum test.

**Table 5.** Comparison of Rotational Deformity between Novel Fixed Angle Devices (Type 2, 3, 5) with Cannulated Screws Fixation (Type 1)

Degree of deformity (°, absolute value)		P-value*	
X-axis	Type 1 0.21 (0.03-0.52)	Type 2 0.24 (0.05-0.46)	>0.99
Y-axis	0.81 (0.59-3.04)	0.71 (0.57-2.57)	0.69
Z-axis	1.50 (0.70-5.08)	0.92 (0.46-2.58)	0.43
X-axis	Type 1 0.21 (0.03-0.52)	Type 3 0.75 (0.35-0.93)	0.13
Y-axis	0.81 (0.59-3.04)	0.18 (0.10-0.38)	0.03
Z-axis	1.50 (0.70-5.08)	0.82 (0.62-1.63)	0.32
X-axis	Type 1 0.21 (0.03-0.52)	Type 5 0.06 (0.01-0.08)	0.09
Y-axis	0.81 (0.59-3.04)	0.06 (0.01-0.08)	0.03
Z-axis	1.50 (0.70-5.08)	0.03 (0.02-0.06)	0.03

Values are presented as median (interquartile range).

Type 1: cannulated screw, Type 2: cannulated screw with cable, Type 3: Intertan nail, Type 5: IKEY nail.

\* Wilcoxon rank sum test.

shear forces rather than compression forces<sup>1,2,11</sup>). Internal fixation using three cannulated screws, which is sufficient for management of Pauwels type I and II femoral neck fractures<sup>3,6</sup>, resulted in high complications, including femoral

neck shortening, non-union, and avascular necrosis. Fixed angle devices including dynamic hip screws have been introduced in an effort to resist the shearing force, not only the compressive forces<sup>7,8</sup>).

**Table 6.** Comparison of Rotational Deformity between Novel Fixed Angle Devices (Type 2, 3, 5) with Dynamic Hip Screw Fixation (Type 4)

	Degree of deformity (°, absolute value)		P-value*
	Type 4	Type 2	
X-axis	0.21 (0.08-0.44)	0.24 (0.05-0.46)	>0.99
Y-axis	1.03 (0.80-1.99)	0.71 (0.57-2.57)	0.55
Z-axis	2.01 (0.98-2.79)	0.92 (0.46-2.58)	0.13
	Type 4	Type 3	
X-axis	0.21 (0.08-0.44)	0.75 (0.35-0.93)	0.07
Y-axis	1.03 (0.80-1.99)	0.18 (0.10-0.38)	0.03
Z-axis	2.01 (0.98-2.79)	0.82 (0.62-1.63)	0.07
	Type 4	Type 5	
X-axis	0.21 (0.08-0.44)	0.06 (0.01-0.08)	0.07
Y-axis	1.03 (0.80-1.99)	0.06 (0.01-0.08)	0.03
Z-axis	2.01 (0.98-2.79)	0.03 (0.02-0.06)	0.03

Values are presented as median (interquartile range).

Type 2: cannulated screw with cable, Type 3: Intertan nail, Type 4: dynamic hip screw, Type 5: IKEY nail.

\* Wilcoxon rank sum test.

Despite its complications, the cannulated screw is still regarded as a conventional surgical technique for treatment of Pauwels type III femoral neck fractures due to short operation time and technical ease. When using cannulated screws, fixation of three parallel screws at least 6.5 mm in diameter and in an inverted triangular fashion has been proposed as ideal<sup>12-14</sup>. Among fixed angle devices, the dynamic hip screw is regarded as conventional. Dynamic hip screw fixation is a method that utilizes a single large screw at a fixed angle with a side-plate<sup>15,16</sup>. However, the clinical result is still not satisfying and many studies regarding the proper implant for Pauwels type III femoral neck fractures have been reported<sup>11,17-19</sup>.

Wrapping a cable around the screw head was proposed and biomechanically tested by Kuan et al.<sup>17</sup>. In this study, the cable was wrapped by passing through the space between three fixated cannulated screws, which was then tightened. In this study addition of the cable resulted in improved mechanical behaviors compared with only fixating three cannulated screw in terms of axial stiffness, cyclic displacement, and failure load and the cable is thought to perform as a fixed angle device.

The Intertan nail was introduced in 2005 for treatment of intertrochanteric fractures, showing good clinical outcomes and low complication rates<sup>20</sup>. This second generation intramedullary nail uses two cephalocervical screws, which can allow linear intraoperative compression and rotational stability of the head or neck fragments. Several biomechanical studies have suggested that the Intertan nail has a superior profile compared with other implants in Pauwels

type III femoral neck fractures. Rupprecht et al.<sup>18</sup> reported that the Intertan nail showed less inferior head displacement, higher loads to failure, and a longer survival under physiologic loads compared with the dynamic hip screw and cannulated screws. However, it still shows relative fragility in mechanical strength compared with intact femur.

The IKEY nail, which was introduced in 2021, allows three cephalocervical screws. There are three apertures allowing the insertion of one lag screw and two additional cannulated screws. Apertures are designed so that three screws are not aligned in a single plane. These profiles are expected to stabilize femoral head rotation sufficiently and enable easier performance of the surgical procedure.

Because there is no implant of choice in osteosynthesis of Pauwels type III fractures, introduction of many different types of novel fixed angle devices, including the aforementioned implants, continues. Many studies have reported superior outcome of novel fixed angle devices. The current study differs from other studies on three points. First, the cannulated screw with wiring was compared with the dynamic hip screw, not only the cannulated screw without wiring. Second, this study is the first to analyze biomechanical stability of supplementary cannulated screw fixation around an intramedullary nail in treatment of isolated Pauwels type III femoral neck fracture. Third, this study is the first to analyze the IKEY nail, which includes additional apertures allowing insertion of a supplementary cannulated screw.

Cannulated screw with wiring is technically simple. A previous study comparing this technique with the cannulated



ed screw reported improved stability in a 7° valgus and 25° valgus setting<sup>17</sup>). In the current study, load-to-failure and rotational deformity on the x-, y-, and z-axes were checked in a 25° valgus setting, and both cannulated screw and dynamic hip screw were used as controls. None of the superior results were observed compared with conventional devices. In brief, the results regarding the use of the cannulated screw with wiring in the 25° valgus setting differed significantly from those of the previous experiment when compared with the cannulated screw. It is considered that there is no biomechanical advantage compared with the dynamic hip screw.

Supplementary cannulated screw fixation around the intramedullary nail has been reported to show superior biomechanical stability in intertrochanteric fractures and combined ipsilateral femoral neck and shaft fractures<sup>21,22</sup>). Although biomechanical superiority has not been demonstrated in isolated Pauwels type III femoral neck fractures, supplementary cephalocervical screw fixation naturally enhances stability as in anti-rotational screw insertion in dynamic hip screws. Insertion of screws in free-handle fashion is the traditional method. For insertion of supplementary screws, it is important to secure sufficient space on the anterior side of the cephalocervical area. In order to achieve this, the authors prefer to insert the nail slightly posterior to the tip of the greater trochanter. After insertion of the nail and the cephalic screw, the guide-wire is inserted in the point anterior and proximal to the site of cephalic screw insertion, heading posteriorly. The cannulated screw is inserted subsequently, just adjacent to the intramedullary nail.

However, making a supplementary screw insertion around the nail in free-handle fashion is technically demanding<sup>23-25</sup>). Despite continued advancement in nail design and the fact that the Intertan nail has two proximal apertures allowing screw insertion, Tan et al.<sup>26</sup>) and Watson and Moed<sup>27</sup>) argued that two screws lie on a single plane in this type and are still insufficient for fixation of Pauwels type III femoral neck fracture. The IKEY nail has three apertures on the proximal portion, so that screws do not lie on a single plane when screws are inserted in all apertures, unlike the Intertan nail. This not only provides technical simplicity but also biomechanical stability similar to that of supplementary screw insertion with free-handle fashion. In the current study, improved stability in load-to-failure, y- and z-axes was observed for the IKEY nail compared with all conventional devices, while other novel fixed angle did not.

To the best of our knowledge, the current study is the first comparative analysis for supplementary cannulated screw around intramedullary nail in treatment of Pauwels type III

femoral neck fractures. Additional differentiation from previous study is that supplementary screw insertion was performed through additional apertures in the proximal portion of the nail, which was specially designed. However, because this study is the first to analyze the IKEY nail, its effectiveness is difficult to generalize. Follow-up study is required in order to determine whether the IKEY nail can show reproducible outcomes in other experimental settings.

There are some limitations of the current study. First, five femur specimens were used for each fixation group, which is relatively small. Second, although there was no breakage around proximal apertures using the IKEY nail in this study, further study is needed in order to determine the potential of this device. Third, all intramedullary nail tested in this study were the screw type of lag screw, not blade type. Because the blade type screw is one of the novel designs for anti-rotation of the femoral head, comparative study with this type of implant may have induced other meaningful results. Last, although promising biomechanical results have been obtained using this type of intramedullary nail, further study is needed in order to evaluate the clinical outcomes.

## CONCLUSION

To the best of our knowledge so far, there is no fixation of choice in treatment of Pauwels type III fracture. This study biomechanically compared two conventional methods with three novel fixed angle devices. Among all, the IKEY nail, the newly developed intramedullary nail, showed meaningful improvement in this study. Further study is needed in order to evaluate the outcome on a larger scale and regarding the clinical outcome.

## CONFLICT OF INTEREST

The authors declare that there is no potential conflict of interest relevant to this article.

## REFERENCES

1. Keating J. *Femoral neck fractures*. In: Rockwood CA Jr., Green DP, Bucholz RW, eds. *Rockwood & Green's fractures in adults*. Philadelphia: Lippincott Williams & Wilkins; 2010.
2. Weinlein J. *Fractures and dislocations of the hip*. In: Azar FM, Beaty JH, Campbell WC, Canale ST, eds. *Campbell's operative orthopaedics*. 13th ed. Philadelphia: Elsevier; 2017.
3. Florschütz AV, Langford JR, Haidukewych GJ, Koval KJ. *Femoral neck fractures: current management*. *J Orthop Trauma*. 2015;29:121-9.

4. Frihagen F, Figved W, Madsen JE, Lofthus CM, Støen RØ, Nordsletten L. [The treatment of femoral neck fractures]. *Tidsskr Nor Laegeforen*. 2010;130:1614-7. Norwegian.
5. Davidovitch RI, Jordan CJ, Egol KA, Vrahas MS. Challenges in the treatment of femoral neck fractures in the nonelderly adult. *J Trauma*. 2010;68:236-42.
6. Sheehan SE, Shyu JY, Weaver MJ, Sodickson AD, Khurana B. Proximal femoral fractures: what the orthopedic surgeon wants to know. *Radiographics*. 2015;35:1563-84. Erratum in: *Radiographics*. 2015;35:1624.
7. Baitner AC, Maurer SG, Hickey DG, et al. Vertical shear fractures of the femoral neck. A biomechanical study. *Clin Orthop Relat Res*. 1999;(367):300-5.
8. Aminian A, Gao F, Fedorow WW, Zhang LQ, Kalainov DM, Merk BR. Vertically oriented femoral neck fractures: mechanical analysis of four fixation techniques. *J Orthop Trauma*. 2007;21:544-8.
9. Liporace F, Gaines R, Collinge C, Haidukewych GJ. Results of internal fixation of Pauwels type-3 vertical femoral neck fractures. *J Bone Joint Surg Am*. 2008;90:1654-9.
10. Haidukewych GJ, Rothwell WS, Jacofsky DJ, Torchia ME, Berry DJ. Operative treatment of femoral neck fractures in patients between the ages of fifteen and fifty years. *J Bone Joint Surg Am*. 2004;86:1711-6.
11. Cha YH, Yoo JI, Hwang SY, et al. Biomechanical evaluation of internal fixation of Pauwels type III femoral neck fractures: a systematic review of various fixation methods. *Clin Orthop Surg*. 2019;11:1-14.
12. Lindequist S. Cortical screw support in femoral neck fractures. A radiographic analysis of 87 fractures with a new mensuration technique. *Acta Orthop Scand*. 1993;64:289-93.
13. Maurer SG, Wright KE, Kummer FJ, Zuckerman JD, Koval KJ. Two or three screws for fixation of femoral neck fractures? *Am J Orthop (Belle Mead NJ)*. 2003;32:438-42.
14. Parker MJ, Porter KM, Eastwood DM, Schembi Wismayer M, Bernard AA. Intracapsular fractures of the neck of femur. Parallel or crossed garden screws? *J Bone Joint Surg Br*. 1991;73:826-7.
15. Burkes J, Cannada LK, Olson SA, Schemitsch EH, Kyle RF. New developments in hip fracture treatment to reduce morbidity and mortality. *Instr Course Lect*. 2021;70:85-100.
16. Fixation using Alternative Implants for the Treatment of Hip fractures (FAITH) Investigators. Fracture fixation in the operative management of hip fractures (FAITH): an international, multicentre, randomised controlled trial. *Lancet*. 2017;389:1519-27.
17. Kuan FC, Yeh ML, Hong CK, et al. Augmentation by cerclage wire improves fixation of vertical shear femoral neck fractures—a biomechanical analysis. *Injury*. 2016;47:2081-6.
18. Rupperecht M, Grossterlinden L, Ruecker AH, et al. A comparative biomechanical analysis of fixation devices for unstable femoral neck fractures: the Intertan versus cannulated screws or a dynamic hip screw. *J Trauma*. 2011;71:625-34.
19. Rupperecht M, Grossterlinden L, Sellenschloh K, et al. Internal fixation of femoral neck fractures with posterior comminution: a biomechanical comparison of DHS<sup>®</sup> and Intertan nail<sup>®</sup>. *Int Orthop*. 2011;35:1695-701.
20. Ruecker AH, Rupperecht M, Gruber M, et al. The treatment of intertrochanteric fractures: results using an intramedullary nail with integrated cephalocervical screws and linear compression. *J Orthop Trauma*. 2009;23:22-30. Erratum in: *J Orthop Trauma*. 2009;23:378.
21. Bennett FS, Zinar DM, Kilgus DJ. Ipsilateral hip and femoral shaft fractures. *Clin Orthop Relat Res*. 1993;(296):168-77.
22. Wu CC, Shih CH. Ipsilateral femoral neck and shaft fractures. Retrospective study of 33 cases. *Acta Orthop Scand*. 1991;62:346-51.
23. Hossam ElShafie M, Adel Morsey H, Emad Eid Y. Ipsilateral fracture of the femoral neck and shaft, treatment by reconstruction interlocking nail. *Arch Orthop Trauma Surg*. 2001;121:71-4.
24. Jain P, Maini L, Mishra P, Upadhyay A, Agarwal A. Cephalomedullary interlocked nail for ipsilateral hip and femoral shaft fractures. *Injury*. 2004;35:1031-8.
25. Randelli P, Landi S, Fanton F, Hoover GK, Morandi M. Treatment of ipsilateral femoral neck and shaft fractures with the Russell-Taylor reconstructive nail. *Orthopedics*. 1999;22:673-6.
26. Tan V, Wong KL, Born CT, Harten R, DeLong WG Jr. Two-screw femoral neck fracture fixation: a biomechanical analysis of 2 different configurations. *Am J Orthop (Belle Mead NJ)*. 2007;36:481-5.
27. Watson JT, Moed BR. Ipsilateral femoral neck and shaft fractures: complications and their treatment. *Clin Orthop Relat Res*. 2002;(399):78-86.