



The Use of Arteriovenous Bundle Interposition Grafts in Microsurgical Reconstruction: A Systematic Review of the Literature

Aurora M. Kareh, MD¹ Kashyap Komarraju Tadisina, MD¹ Magnus Chun, BS² Sumesh Kaswan, MD¹
Kyle Y. Xu, MD³

¹Division of Plastic and Reconstructive Surgery, Saint Louis University School of Medicine, St. Louis, Missouri

²Tulane University School of Medicine, New Orleans, Louisiana

³Division of Plastic Surgery, University of Miami Miller School of Medicine, Miami, Florida

Address for correspondence Kyle Y. Xu, MD, Department of Surgery, Division of Plastic Surgery, University of Miami Miller School of Medicine, 1120 NW 14th Street, 4th Floor, Miami, FL 33136 (e-mail: drkylexu@gmail.com).

Arch Plast Surg 2022;49:543–548.

Abstract

Microvascular reconstruction frequently requires anastomosis outside of the zone of injury for successful reconstruction. Multiple options exist for pedicle lengthening including vein grafts, arteriovenous loops, and arteriovenous bundle interposition grafts. The authors performed a systematic review of arteriovenous bundle interposition grafts to elucidate indications and outcomes of arteriovenous grafts in microvascular reconstruction. A systematic review of the literature was performed using targeted keywords. Data extraction was performed by two independent authors, and descriptive statistics were used to analyze pooled data. Forty-four patients underwent pedicle lengthening with an arteriovenous graft from the descending branch of the lateral circumflex femoral artery. Most common indications for flap reconstruction were malignancy ($n=12$), trauma ($n=7$), and diabetic ulceration ($n=4$). The most commonly used free flap was the anterolateral thigh flap ($n=18$). There were five complications, with one resulting in flap loss. Arteriovenous bundle interposition grafts are a viable option for pedicle lengthening when free flap distant anastomosis is required. The descending branch of the lateral circumflex femoral artery may be used for a variety of defects and can be used in conjunction with fasciocutaneous, osteocutaneous, muscle, and chimeric free flaps.

Keywords

- ▶ arteriovenous bundle interposition grafts
- ▶ pedicle lengthening
- ▶ arteriovenous loop
- ▶ arteriovenous grafts

Large traumatic zones of injury, underlying vascular disease, radiation, or extensive oncologic resection can pose a significant challenge for the reconstructive microvascular surgeon. In these instances, there are often large length discrepancies between available recipient vessels and the area needing reconstruction. Despite thoughtful flap selec-

tion to optimize pedicle length, vessel lengthening to reach recipient vessels outside of the zone of injury may still be necessary.

Multiple options exist when additional length is needed between recipient vessels and flap pedicle, including vein grafts, arteriovenous (AV) loops, and AV bundle interposition

DOI <https://doi.org/10.1055/s-0042-1744424>.
ISSN 2234-6163.

© 2022. The Korean Society of Plastic and Reconstructive Surgeons. All rights reserved.

This is an open access article published by Thieme under the terms of the Creative Commons Attribution-NonDerivative-NonCommercial-License, permitting copying and reproduction so long as the original work is given appropriate credit. Contents may not be used for commercial purposes, or adapted, remixed, transformed or built upon. (<https://creativecommons.org/licenses/by-nc-nd/4.0/>)

Thieme Medical Publishers, Inc., 333 Seventh Avenue, 18th Floor, New York, NY 10001, USA

grafts. Vein grafts have many available donor sites, are easy to harvest, and are frequently used for smaller vessel gaps. Although they are useful and relatively easy to access, they have been associated with increased thrombosis and complications, particularly when longer in length, unplanned, or used for salvage.¹⁻³ AV loops are another viable option for vessel lengthening, particularly in very long vessel defects or simultaneous arterial and venous gaps. Advantages of AV loops are their utilization in a staged manner to verify perfusion and function of the loop as well as quality of the wound bed prior to free tissue transfer. However, this technique often results in a significant size mismatch between the AV loop donor vessel and recipient vessels, predisposing patients to increased flap complications.^{4,5} Additionally, the lack of soft-tissue support around an AV loop decreases intrinsic perfusion of the graft and may predispose to kinking.⁵

AV bundle interposition grafts have been used and described in the cardiothoracic and neurosurgical literature since the 1980s. However, they have been intermittently reported in the plastic surgery microsurgery literature. AV bundle grafts are pedicles that are harvested as one soft-tissue graft that contains an artery and a vein with preserved interconnections between the vessels. These bundle grafts are then interposed between available recipient vessels and the reconstructive flap pedicle. AV grafts require half the length of AV loops and are physiologically more similar to recipient vessels than vein grafts or AV loops.⁶ Published use of AV grafts in microvascular reconstruction has been limited to small case series and single-patient case reports, although results have been promising. Cited advantages of this technique are closer anatomic match between arteries and veins, less size mismatch, decreased donor site morbidity, neovascularization produced by the pedicled, pressure equilibration from pedicle interconnections, flexibility of length and diameter, and less susceptibility to comorbidities than superficial veins. In this study, the authors seek to define indications, techniques, and outcomes of AV bundle interposition grafts used in complex reconstruction to evaluate their potential as a preferred option in microvascular lengthening. We present a systematic review of AV grafts focusing on technique, indications, and complications.

Methods

A comprehensive literature search was conducted according to Preferred Reporting Items for Systematic Reviews and Meta-Analyses (PRISMA) guidelines.⁷ The PubMed, Embase, and Web of Science databases were searched for all publications through October 1, 2020 using the following keywords and/or MeSH terms: ["free flap reconstruction" AND "interposition grafts" OR "arteriovenous interposition grafts"]. After eliminating duplicates, pertinent articles were identified and reviewed. Two independent reviewers screened each study for relevance. References of relevant studies were also reviewed for additional articles. Cohort studies, case series, and case studies describing use of AV grafts with reported patient outcomes were included.

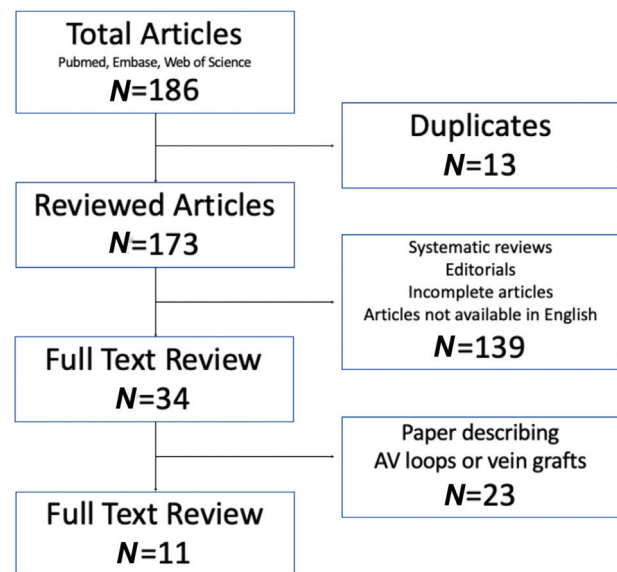


Fig. 1 Systematic review flow diagram.

Demographic data, indications, technique used, and clinical data were collected and analyzed using descriptive statistics.

Results

Our systematic review yielded 173 unique articles for review. Systematic reviews, editorials, incomplete articles, and articles that were not available in English were excluded and full-text review was performed on the remaining 34 studies. After full-text screening for relevance, 11 articles were included in this study. Full details are found in ►Fig. 1.

A total of 44 patients underwent reconstruction with the use of AV bundle interposition grafts across 11 studies. Patients' age ranged from 6 to 84 years (average 48.4 years). Of those reported, 31 were males and 13 were females. Indications for reconstruction were malignancy ($n=12$), trauma ($n=7$), diabetic ulcer ($n=4$), osteoradionecrosis ($n=3$), congenital ($n=3$), facial paralysis ($n=2$), fibrous dysplasia ($n=2$), reconstruction after aesthetic surgery ($n=1$), infection ($n=1$), and radiation ($n=1$).

All 44 AV grafts were harvested from the descending branch of the lateral circumflex femoral artery (LCFA). The most commonly used free flap was the anterolateral thigh (ALT) flap ($n=18$) followed by preauricular ($n=7$), fibula ($n=5$), latissimus dorsi ($n=5$), gracilis ($n=3$), rectus abdominis ($n=2$), chimeric ALT and vastus lateralis ($n=1$), iliac bone ($n=1$), radial forearm ($n=1$), and vastus lateralis ($n=1$).

Three different techniques of AV bundle grafting were described:

- The most common was "recipient lengthening": The AV graft was anastomosed to the recipient vessels and the flap was anastomosed to the AV graft ($n=32$; ►Fig. 2).
- The next most common was "flap lengthening": The flap was anastomosed to the AV graft in situ and then the

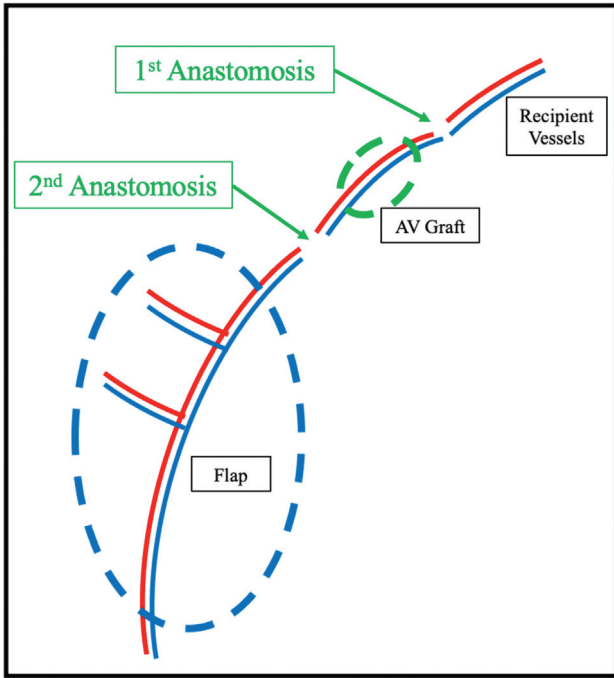


Fig. 2 Recipient lengthening technique. AV, arteriovenous.

proximal aspect of the AV graft was anastomosed to the recipient vessels ($n = 11$; ► **Fig. 3**).

- One case described revascularization of a lower extremity with the AV graft and concomitant soft-tissue coverage with an ALT flap reliant on the same proximal pedicle (► **Fig. 4**).

Overall, there were five complications reported (11%): 1 arterial thrombus due to embolization of an atherosclerotic plaque from proximal recipient vessels that eventually resulted in flap loss, 1 partial flap necrosis, 1 flap wound dehiscence, 1 seroma, and 1 venous thrombosis. Results are summarized in ► **Table 1**.

Discussion

Standard preoperative planning for microvascular reconstruction includes analysis of flap pedicle length, recipient

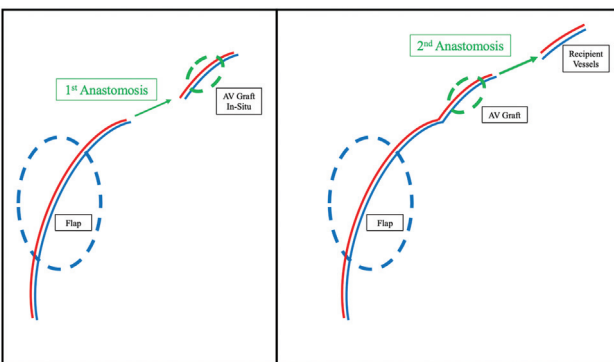


Fig. 3 Flap lengthening technique. AV, arteriovenous.

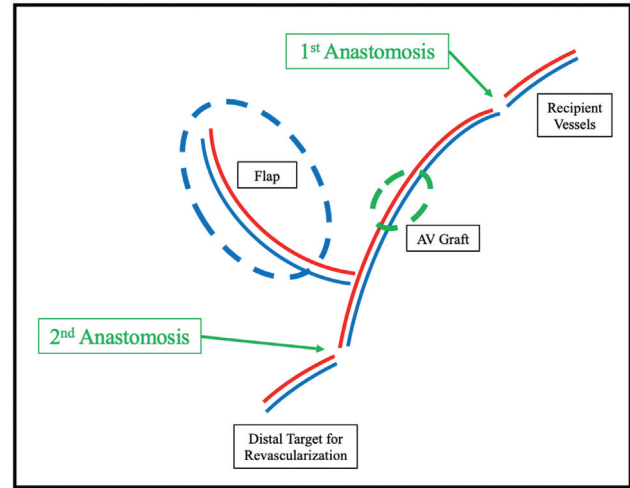


Fig. 4 Revascularization technique. AV, arteriovenous.

vessel selection, and geometry of the anastomosis.⁸ Despite judicious preoperative free flap planning, additional pedicle length may be required in instances of previous failed reconstruction, intraoperative vessel thrombosis, short flap pedicle length, or a large zone of injury. Flap pedicles may be lengthened through the use of interposition vein grafts, AV loops, or AV bundle interposition grafts. Godina described the advantages of arterial grafts for arterial defects in a 1986 paper, citing the advantage of a thicker wall, less elasticity, and absence of valves over the potential flow disturbances and size mismatch that come with using venous grafts.⁹ This has been confirmed in the cardiothoracic literature.^{10,11} Using AV pedicles for revascularization has been proposed in the hand literature. Using pedicles from the ring or middle finger digital neurovascular bundles for replantation of the thumb has been described.^{12,13} The authors reviewed technique and outcomes of AV bundle grafts used for microsurgical reconstruction.

Advantages

AV bundle grafts are physiologically advantageous over vein grafts and AV loops for multiple reasons. Common donor veins for AV loops are the cephalic and saphenous veins, both of which have frequent size mismatch to most recipient vessels in microvascular reconstruction.¹⁴ This is further exacerbated once flow is established, as the vein cannot withstand normal arterial pressure and dilates far more than the recipient artery, leading to potential flow disturbance and eventual vessel thrombosis.^{6,9} Donor site morbidity is decreased with AV grafts compared with AV loops, as AV grafts require half the length of AV loops to lengthen a pedicle by the same amount. The length of the descending LCFA is shorter than traditional AV loop donor vessels, making the AV loop inherently advantageous in the cases with long vascular defects or a large zone of injury. Unlike a traditional vein graft, AV grafts contain vasa vasorum around the vascular bundle that supply the vessels themselves and perfuse the graft. This prevents endothelial damage and maintains the graft patent initially after grafting.¹⁵

Table 1 Summary of arteriovenous graft results

Results summary		n	%
Demographics (total = 44)	Male	31	70.45
	Female	13	29.55
Indications (total = 44)	Malignancy	12	27.27
	Trauma	7	15.91
	Diabetic ulcer	4	9.09
	Osteoradionecrosis	3	6.82
	Congenital	3	6.82
	Facial paralysis	2	4.55
	Fibrous dysplasia	2	4.55
	Reconstruction after aesthetic surgery	1	2.27
	Infection	1	2.27
	Radiation	1	2.27
	Not reported	8	18.18
Flap (total = 44)	Anterolateral thigh	18	40.91
	Preauricular	7	15.91
	Fibula	5	11.36
	Latissimus dorsi	5	11.36
	Gracilis	3	6.82
	Rectus abdominis	2	4.55
	Anterolateral thigh and vastus lateralis	1	2.27
	Iliac bone	1	2.27
	Radial forearm	1	2.27
	Vastus lateralis	1	2.27
Technique	Recipient lengthening	32	72.7
	Flap lengthening	11	25
	Revascularization	1	2.3
Complications (total = 5)	Arterial thrombus	1	20
	Partial flap necrosis	1	20
	Wound dehiscence at flap site	1	20
	Seroma	1	20
	Venous thrombosis	1	20

The technical skill required for harvest of the descending branch of the LCFA as an AV graft should already exist within the microsurgeon's armamentarium, as it is encountered during dissection of the ALT flap.^{5,16,17} The descending branch of the LCFA can be up to 20 cm long and its arterial caliber matches closely to common recipient vessels throughout the body, making it ideal for use as an AV graft. The anatomic reliability of the descending branch of the LCFA has been well described and further confirmed with angiographic studies.¹⁸⁻²⁰ Additionally, the descending branch of the LCFA appears to be relatively spared from atherosclerotic disease, making it an ideal donor for interposition grafting.¹⁹

Zenn et al wrote an excellent article describing both an anatomic cadaveric study and clinical series using this pedicle for multiple uses, including extremity flow through revascularization, flap prefabrication, and alternative to AV loops as an interposition graft.⁵ This study also reviewed many of the principal advantages of using an AV interposition graft. The cadaveric study had findings of mean pedicle length of 20.5 cm, proximal arterial diameter of 3.4 mm, distal arterial diameter of 1.9 mm, proximal venous diameter of 3.9 mm, and distal inflow venous diameter of 2.4 mm. Sixty percent of cadavers studied had two veins and 40% had one vein. The long length of the pedicle allows multiple variations of the pedicle to be used based on the caliber of the recipient vessel.⁵

The descending branch of the LCFA is often accompanied by two venae comitantes that can be used to augment venous outflow of the flap. AV and venovenous interconnections between the graft vessels maintain adequate flow through the veins, thus avoiding low flow states that can lead to thrombosis.⁵ Studies have shown that these same interconnections promote neovascularization of nearby tissues, which has led to the use of AV grafts in prefabricated flaps.²¹ Zenn et al described the use of the AV graft in a small free preauricular flap for nasal reconstruction, where the interposition graft was used to connect the flap's superficial temporal vessels to the recipient facial vessels.⁵ The authors describe that small flaps generate small amounts of venous outflow, and having interconnections within the pedicle maintain flow through the vein, thus preventing thrombosis due low flow.⁵ This line of thinking can be extended to other small flaps such as vascularized lymph node transplants or medial femoral condyle flaps. This is also why skeletonization of pedicles is discouraged in microsurgery. Further, these interconnections make anatomic positioning easier to identify and provide structural support to the graft, preventing pedicle kinking that may be seen in AV loops.^{5,17,22}

Disadvantages

Disadvantages of AV grafts have not been well elucidated in the literature. However, the main disadvantages include limited donor site availability and potential inability to use the ipsilateral ALT flap after LCFA AV graft harvest. Given the frequent need for a "back-up plan" due to the complexity of microvascular reconstruction, these disadvantages must be considered on a case-by-case basis.

Interposition Techniques

Recipient Lengthening

The recipient lengthening technique was most commonly used across all studies (73%). In this technique, the AV graft is harvested and anastomosed to the recipient vessels prior to flap ischemia time. Recipient lengthening leads to shorter free flap ischemia time and allows the arterial supply through the graft to be verified easily prior to flap anastomosis, but this technique makes it difficult to verify venous return of the AV graft.⁶

Flap Lengthening

In this technique, the flap is raised and anastomosed to the distal aspect of the AV graft first, followed by anastomosis to the recipient vessels. The flap lengthening type or “double-ischemia” transfer allows for both arterial supply and venous return to be readily assessed through the AV graft prior to performing the second anastomosis.⁶ Although this technique leads to longer flap ischemia time, there is an opportunity for mid-procedure reperfusion of the flap on the descending branch of the LCFA in situ with this technique. A significant advantage of the double-ischemia transfer is the ability to re-perfuse the free flap during cases where donor site preparation is anticipated to take longer than flap elevation.¹⁷ This is particularly pertinent in the cases where mid-procedure repositioning of the patient from lateral decubitus for flap elevation to supine for flap inset is necessary, which is frequently seen in the cases where the latissimus dorsi, scapular, or parascapular flaps are raised.

The descending branch of the LCFA may be safely raised concurrently with an ipsilateral ALT flap. Han et al described raising the ALT flap on a shortened pedicle and harvesting the descending LCFA distal to the flap perforators as an AV graft.²³ The same group later described interposition of the AV graft as an interposition graft within the native flap pedicle to overcome vessel size discrepancy.²⁴ Interposition grafting based on size discrepancy was used in the cases where the proximal pedicle and the distal AV graft had a discrepancy of over 2 mm.²⁴

Concurrent Limb Revascularization and Flap Reconstruction

Lim et al described elevation of an ALT flap and an AV graft concurrently on one proximal pedicle for lower limb salvage after significant trauma.²⁵ The AV graft was anastomosed to the anterior tibial vessels proximally and the dorsalis pedis distally to provide revascularization of the lower extremity. The ALT flap was perfused via the same proximal anastomosis. At 1 month after surgery, the AV graft had intact flow and the lower extremity remained perfused.²⁵

Future Directions

The authors believe AV graft to be a safe and reliable option for microvascular pedicle lengthening in complex microsurgical reconstruction. The principle of an expendable pedicle has been demonstrated in flap prefabrication as well as pedicled neovascularization of cartilage and even bone.^{26–29} Future studies are needed to elucidate the full utility of AV grafts, more options for donor sites, and to perform head-to-head comparison of AV grafts to vein grafts and AV loops to delineate indications for each technique of pedicle lengthening.

Conclusion

Free tissue transfer frequently requires anastomosis to vessels outside the zone of injury for successful reconstruction. AV bundle interposition grafting is a viable option for flap or

recipient vessel lengthening in the cases where additional pedicle length is required. The descending branch of the LCFA is a reliable donor for AV grafting and can be used in microvascular reconstruction of the head and neck, trunk, or extremities. Further studies directly comparing vein grafts, AV loops, and AV bundle interposition grafts are needed.

Author Contributions

All authors listed were involved equally in conceiving and designing the study, data collection and analysis, and manuscript writing and editing.

Conflict of Interest

None declared.

References

- Di Taranto G, Chen SH, Elia R, et al. Outcomes following head neck free flap reconstruction requiring interposition vein graft or vascular bridge flap. *Head Neck* 2019;41(09):2914–2920
- Maricevich M, Lin LO, Liu J, Chang EI, Hanasono MM. Interposition vein grafting in head and neck free flap reconstruction. *Plast Reconstr Surg* 2018;142(04):1025–1034
- Inbal A, Silva AK, Humphries LS, Teven CM, Gottlieb LJ. Bridging the gap: a 20-year experience with vein grafts for free flap reconstruction. The odds for success. *Plast Reconstr Surg* 2018;142(03):786–794
- Lee ZH, Alfonso AR, Stranix JT, et al. Vein size mismatch increases flap failure in lower extremity trauma free flap reconstruction. *J Reconstr Microsurg* 2019;35(08):587–593
- Zenn MR, Pribaz J, Walsh M. Use of the descending lateral femoral circumflex artery and vein for vascular grafting: a better alternative to an arteriovenous loop. *Plast Reconstr Surg* 2010;126(01):140–142
- Kim YH, Kim JW, Kim TG, Lee JH, Chung KJ, Yeo CH. Ischemic time in free-flap surgery with arteriovenous bundle interposition graft: comparison of two anastomosis sequences. *J Craniofac Surg* 2019;30(02):493–496
- Moher D, Liberati A, Tetzlaff J, Altman DG. PRISMA Group. Preferred reporting items for systematic reviews and meta-analyses: the PRISMA statement. *Ann Intern Med* 2009;151(04):264–269
- Park JH, Min KH, Eun SC, Lee JH, Hong SH, Kim CW. Scalp free flap reconstruction using anterolateral thigh flap pedicle for interposition artery and vein grafts. *Arch Plast Surg* 2012;39(01):55–58
- Godina M. Arterial autografts in microvascular surgery. *Plast Reconstr Surg* 1986;78(03):293–294
- Fabbrocini M, Fattouch K, Camporini G, et al. The descending branch of lateral femoral circumflex artery in arterial CABG: early and midterm results. *Ann Thorac Surg* 2003;75(06):1836–1841
- Suma H. Arterial grafts in coronary bypass surgery. *Ann Thorac Cardiovasc Surg* 1999;5(03):141–145
- Lobay GW, Moysa GL. Primary neurovascular bundle transfer in the management of avulsed thumbs. *J Hand Surg Am* 1981;6(01):31–34
- Doi K. Replantation of an avulsed thumb, with application of a neuro-vascular pedicle. *Hand* 1976;8(03):258–260
- Bianchi B, Copelli C, Ferrari S, Ferri A, Sesenna E. Anterolateral thigh flap pedicle for interposition artery and vein grafts in head and neck reconstruction: a case report. *Microsurgery* 2009;29(02):136–137
- Sano K, Okuda T, Aoki R, Kimura K, Ozeki S. Usefulness of vascular bundle interposition of the descending branch of the lateral circumflex femoral vessels for free flap reconstruction of the calvarial defect. *Microsurgery* 2008;28(07):551–554

- 16 Lakhiani C, Lee MR, Saint-Cyr M. Vascular anatomy of the anterolateral thigh flap: a systematic review. *Plast Reconstr Surg* 2012; 130(06):1254–1268
- 17 Frommer SA, Teal LN, Myers RP, Kelley PK, Henry SL. Extending the reach of craniofacial free flaps using the descending branch of the lateral circumflex femoral vessels. *Plast Reconstr Surg* 2021; 147(02):260e–264e
- 18 Fukuda H, Ashida M, Ishii R, Abe S, Ibukuro K. Anatomical variants of the lateral femoral circumflex artery: an angiographic study. *Surg Radiol Anat* 2005; 27(03):260–264
- 19 Halvorson EG, Taylor HOB, Orgill DP. Patency of the descending branch of the lateral circumflex femoral artery in patients with vascular disease. *Plast Reconstr Surg* 2008; 121(01):121–129
- 20 Yamashita Y, Fukuda S, Kigawa I, Wanibuchi Y. Preoperative angiographic evaluation of the descending branch of the lateral femoral circumflex artery as a free graft in coronary artery bypass graft. *Jpn J Thorac Cardiovasc Surg* 2005; 53(09):477–480
- 21 Lokmic Z, Stillaert F, Morrison WA, Thompson EW, Mitchell GM. An arteriovenous loop in a protected space generates a permanent, highly vascular, tissue-engineered construct. *FASEB J* 2007; 21(02):511–522
- 22 Yim S, Eun SC. Chondrocutaneous preauricular free flap for reconstruction of nasal defects aided by interposition vascular graft. *J Craniofac Surg* 2017; 28(07):1842–1846
- 23 Han HH, Choi EJ, Oh DY, Moon SH. The usefulness of microsurgical pedicle lengthening in free anterolateral thigh flaps. *Microsurgery* 2016; 36(07):559–566
- 24 Han HH, Jun D, Mun GH, Moon SH. Modification of pedicle lengthening through perforator transposition in free anterolateral thigh flaps with pedicle size discrepancy: A case report. *Microsurgery* 2018; 38(01):94–97
- 25 Lim J, Kwon H, Lee KM, Pak C. Immediate lower extremity reconstruction using an anterolateral thigh free flap with simultaneous interposition graft of descending branches of lateral circumflex femoral vessels. *Int J Low Extrem Wounds* 2019; 18(01):89–93
- 26 Simmons SP, Tobias B, Lichtman DM. Lunate revascularization with artery implantation and bone grafting. *J Hand Surg Am* 2009; 34(01):155–160
- 27 Maitz PK, Pribaz JJ, Duffy FJ, Hergueter CA. The value of the delay phenomenon in flap prefabrication: an experimental study in rabbits. *Br J Plast Surg* 1994; 47(03):149–154
- 28 Pribaz JJ, Fine N, Orgill DP. Flap prefabrication in the head and neck: a 10-year experience. *Plast Reconstr Surg* 1999; 103(03):808–820
- 29 Hori Y, Tamai S, Okuda H, Sakamoto H, Takita T, Masuhara K. Blood vessel transplantation to bone. *J Hand Surg Am* 1979; 4(01):23–33