




Unexpected Presence of *Blastocystis* Subtype 1-3 DNA in Human Vaginal and Sperm Samples Coinfected with *Trichomonas vaginalis*

Guihdani Villalobos¹ , Fabiola Sanchez-Aguillon¹, Marcia Veronica Carmona-Maldonado², Nelly Raquel Gonzalez-Arenas¹, Eduardo Lopez-Escamilla¹, Rigoberto Hernandez-Castro¹, Mirza Romero-Valdovinos¹, Williams Arony Martinez-Flores¹, Juan Pablo Ramirez-Hinojosa¹, Pablo Maravilla^{1,*} , Fernando Martinez-Hernandez^{1,*} 

¹Hospital General "Dr. Manuel Gea Gonzalez", Mexico City 14080, Mexico; ²Biolab, Laboratorio de Andrologia, Mexico City 07300, Mexico

Abstract: There have been few reports on extra-enteric infections by *Blastocystis* STs and none have been molecularly identified in samples from human reproductive organs. We report for the first time the identification of 3 different subtypes of *Blastocystis* (ST1-3) in vaginal and sperm samples, from patients infected with *Trichomonas vaginalis*. *Blastocystis* STs were identified by PCR-sequencing and by phylogenetic inferences using 28 vaginal swab samples and 7 sperm samples from patients trichomoniasis. *Blastocystis* STs were identified in 6 of 28 vaginal swabs (21.4%) and in 3 of 7 sperm samples (42.8%). In both biological samples, STs 1-3 were found; one vaginal sample showed subtype co-infection with ST1 and ST3. High genetic variation was observed in the sequences obtained and no specific clustering in the phylogenetic trees was detected. Most of the haplotypes identified were placed far from the main dispersal centers. Our finding suggested that incorrect cleaning of the genital area or a contamination by combination of anal and vaginal intercourse.

Key words: *Blastocystis* subtypes, *Trichomonas vaginalis*, extra-enteric blastocystosis

Blastocystis is among the most common intestinal microeukaryote identified in stool samples worldwide. Its pathogenic role remains controversial; several studies have linked this microbe to the development of dermatological and intestinal disorders, while others have not. *Blastocystis* exhibits a great variability in the size and shape of its main stages observed under the light microscope (granular and vacuolar forms). Furthermore, it displays a marked genetic polymorphism. Up to 28 ribosomal lineages proposed, known as subtypes (STs), have been described by analyzing the small subunit 18S ribosomal RNA (18S rRNA) [1].

There are few cases of extra-enteric *Blastocystis* in humans, such as those found in knee synovial fluid [2], liver, and splenic abscess [3-5]. A previous study examined vaginal parasites in 312 Polish peasant women and found 47 persons infected with *Blastocystis* (11.5%) [6]. A case of *Blastocystis* in the uterine

cervix of a Mexican patient with minimal cervicitis symptoms was recently reported [7]. Interestingly, in all cases, the vacuolar stage was clearly identified by microscopy but molecular diagnosis of STs has not been conducted.

On the other hand, the protozoan *Trichomonas vaginalis* is the most common nonviral sexually transmitted infection (STI) in the world. *T. vaginalis* inhabits the vagina, causing vaginitis and cervicitis. In male it colonizes the urethra, epididymis, and prostate gland, but usually asymptomatic. More importantly, however, *Trichomonas* infections can cause infertility in both men and women [8].

Identification of *Blastocystis* in the cervix of a Mexican patient who was coinfecting with *T. vaginalis* led us to investigate the *Blastocystis* STs in these samples. In the present study, we report the unexpected identification of *Blastocystis* STs in human vaginal and sperm samples coinfecting with *T. vaginalis*.

Twenty-eight women who attended the gynecology public service at the Hospital General Dr. Manuel Gea Gonzalez (HGMGG) for routine check-ups were analyzed. The indications for sampling included i) not having ingested any antibiotics for at least 10 days prior to medical appointment, ii) without the application of ovules or vaginal creams, iii) not

•Received 4 March 2022, revised 16 May 2022, accepted 12 June 2022.

*Corresponding authors (maravillap@yahoo.com; fherxyz@yahoo.com)

© 2022, Korean Society for Parasitology and Tropical Medicine

This is an Open Access article distributed under the terms of the Creative Commons Attribution Non-Commercial License (<https://creativecommons.org/licenses/by-nc/4.0>) which permits unrestricted non-commercial use, distribution, and reproduction in any medium, provided the original work is properly cited.

having had sexual intercourse for at least 3 days, iv) not menstruating or with abnormal bleeding, and iv) properly cleaned. The samples of vaginal swabs were put in containers BD Vacutainer with sterile physiological saline and diagnosed with *T. vaginalis* by microscopy. Immediately after diagnosis, the samples were kept at -70°C . In men, aliquots of 7 sperm samples that were employed for spermatobioscopy or assisted reproduction treatment were donated from the private fertility clinic of Biolab, Andrology laboratory. The indications for semen sampling included i) not having had sexual intercourse for at least 3 days, ii) not having taken any antibiotics for at least 10 days, and iii) properly cleaned. The samples were obtained in sterile plastic containers of 50 ml and analyzed as recommended by the World Health Organization [9]. These samples were diagnosed by microscopy with *T. vaginalis*, all patients were asymptomatic; the samples were frozen at -70°C .

As part of a routine process, clinical and microbiology data were obtained from medical records of each woman. We also requested diagnosis for other STI such as *Gardnerella vaginalis*, *Ureaplasma urealyticum*, *Mycoplasma hominis*, and *Chlamydia* spp., as well as microbiological and mycological cultures. All samples were collected from 2015 to 2019.

Ethics and Research Committees of the HGMGG approved the study with the reference number 12-75-2015. Written informed consent was obtained from all patients.

Total DNA was extracted from approximately 500 μl of the physiological saline immersed with vaginal swabs or 100 μl of sperm samples using Puregene DNA Purification System (Gentra Systems, Germany) according to the manufacturer's protocol. To confirm the presence of *T. vaginalis* in vaginal and

sperm samples, internal transcribed spacer 1 (ITS1)-5.8 S rRNA-ITS2 region was amplified using primers described previously [10]. Additionally, the presence of *Blastocystis* ST [11] was searched by PCR-sequencing. To rule out STs co-infections, PCR using ST-specific primers (for ST1, ST2, and ST3) were performed: Primers SB83 F 5'-GAAGGACTCTCTGACGATGA-3' and R 5'-GTCCAAATGAAAGGCAGC-3' for ST1, yielding an amplicon of 351bp; SB340 F 5'-TGTTCTGTGTCTTCTCAGCTC-3' and R 5'-TTCITTCACACTCCCCTCAT-3' for ST2, yielding an amplicon of 704 bp; SB227 F 5'-TAGGATTGGTGTGGAGA-3' and R 5'-TTAGAAGTGAAGGAGATGGAAG-3' for ST3, yielding an amplicon of 526 bp [12,13]. Samples with mixed STs infections were submitted to sequencing 3 more times to obtain the sequences for both STs.

The PCR products were purified and sequenced in both directions. All sequences were subjected to a BLAST search in the GenBank database (MZ700049-MZ700058). Multiple alignments were performed using the MUSCLE tool from the MEGA Program. The algorithms used to obtain the phylogenetic analyses were Neighbor Joining (NJ), maximum likelihood (ML), and Bayesian algorithms (BA). NJ and ML were performed with 1,000 bootstrap replicas under the Tamura-Nei model of evolution, and the algorithms were implemented in MEGA7. For the BA reconstruction, the General Time Reversible model of evolution specifying a gamma distribution and invariable sites (GTR+G+I) was used. Mr. Bayes version 3.4 was used [14], and the analysis was performed with 5×10^6 generations, sampling trees every 100 generations. Trees with a score lower than those at the stationary phase (burn-in) were discarded, and trees that reached the stationary phase were collected and used to build consensus trees. Sequences of *Blastocystis* spp. (isolates representing ST1-ST14) were taken from

Table 1. Main clinical status and microbiological co-infections identified in 28 vaginal samples from symptomatic women and 7 asymptomatic men

Status	No. of positives/Total No. of samples (%)	No. of positives to <i>Blastocystis</i>
Pregnancy	12/28 (42.8)*	3*
Overweight/obesity	13 [9 female + 4 male]/35 (37.1)	2 [both female]
Gestational diabetes	5/28 (17.8)*	2*
Co-infections		
<i>Gardnerella vaginalis</i>	9/28 (32.1)*	3*
<i>Ureaplasma urealyticum</i>	11/28 (39.3)*	3*
<i>Mycoplasma hominis</i>	7/28 (25)*	2*
<i>Enterococcus faecalis</i>	1/28 (3.6)*	0
<i>Trichomonas vaginalis</i>	35/35 (100)	9
<i>Chlamydia</i>	0	0

*Data analyzed only in women.

Table 2. No. of *Blastocystis* STs identified in vaginal and sperm samples

<i>Blastocystis</i> identification	No. of positives/Total No. of samples (%)	GenBank access
In vaginal samples		
ST2	4/28 (14.2)	MZ700049, MZ700052-3, MZ700055
ST3	1/28 (3.6)	MZ700054
ST1+ST3 (coinfections)	1/28 (3.6)	MZ700050-1
In sperm samples		
ST1	1/7 (14.3)	MZ700058
ST2	1/7 (14.3)	MZ700057
ST3	1/7 (14.3)	MZ700056

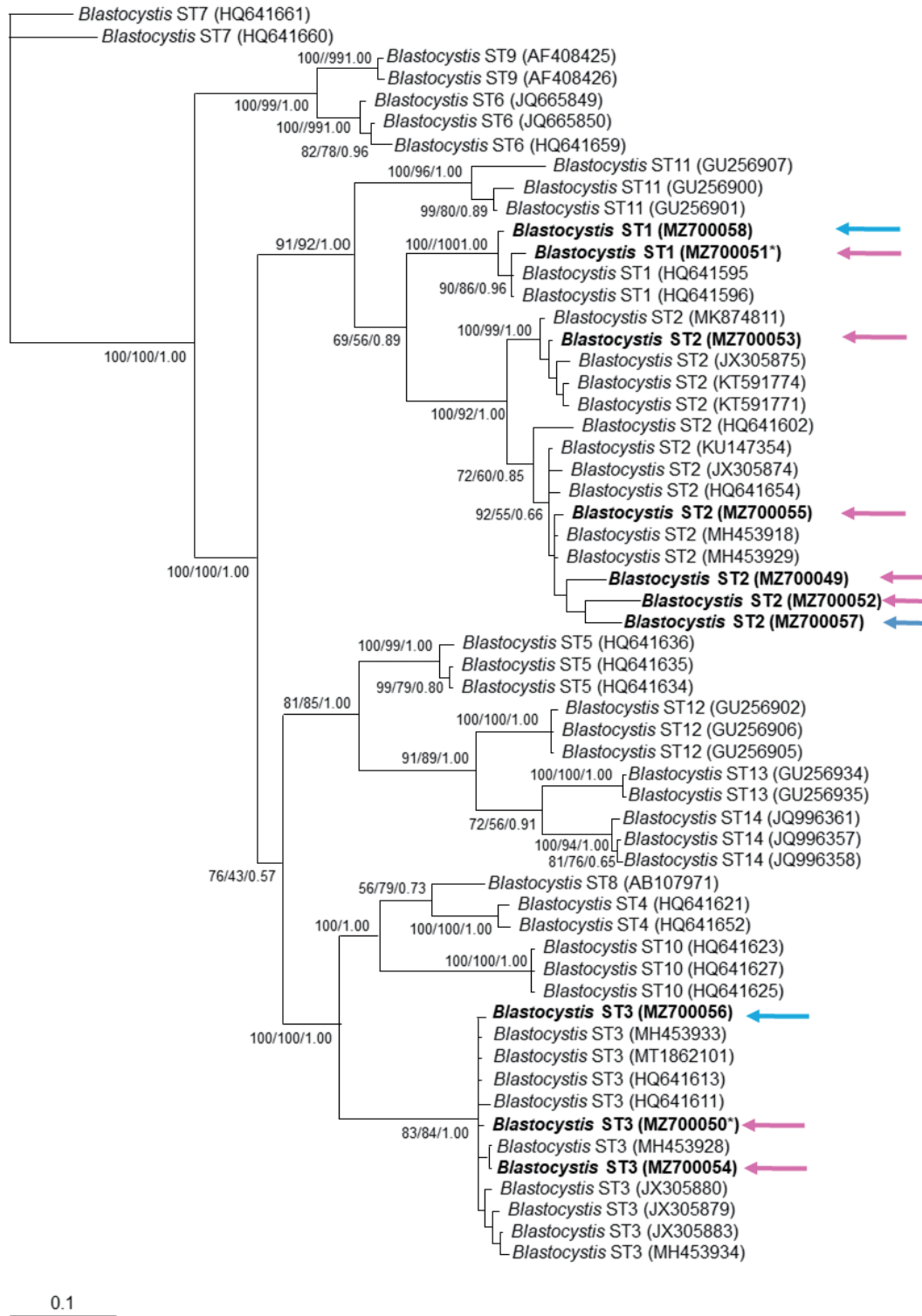


Fig. 1. Phylogenetic inference of 18S rRNA gene partial sequence of *Blastocystis* STs. The values of the nodes indicate the bootstrap proportions and Bayesian posterior probabilities in the following order: Neighbor Joining/maximum likelihood/Bayesian analysis. GenBank accession number are shown at the end of each branch in bold letters. Pink arrows show sequences obtained from vaginal samples, while blue arrows show those for sperm samples. *indicates the sample with mixed *Blastocystis* STs infection.

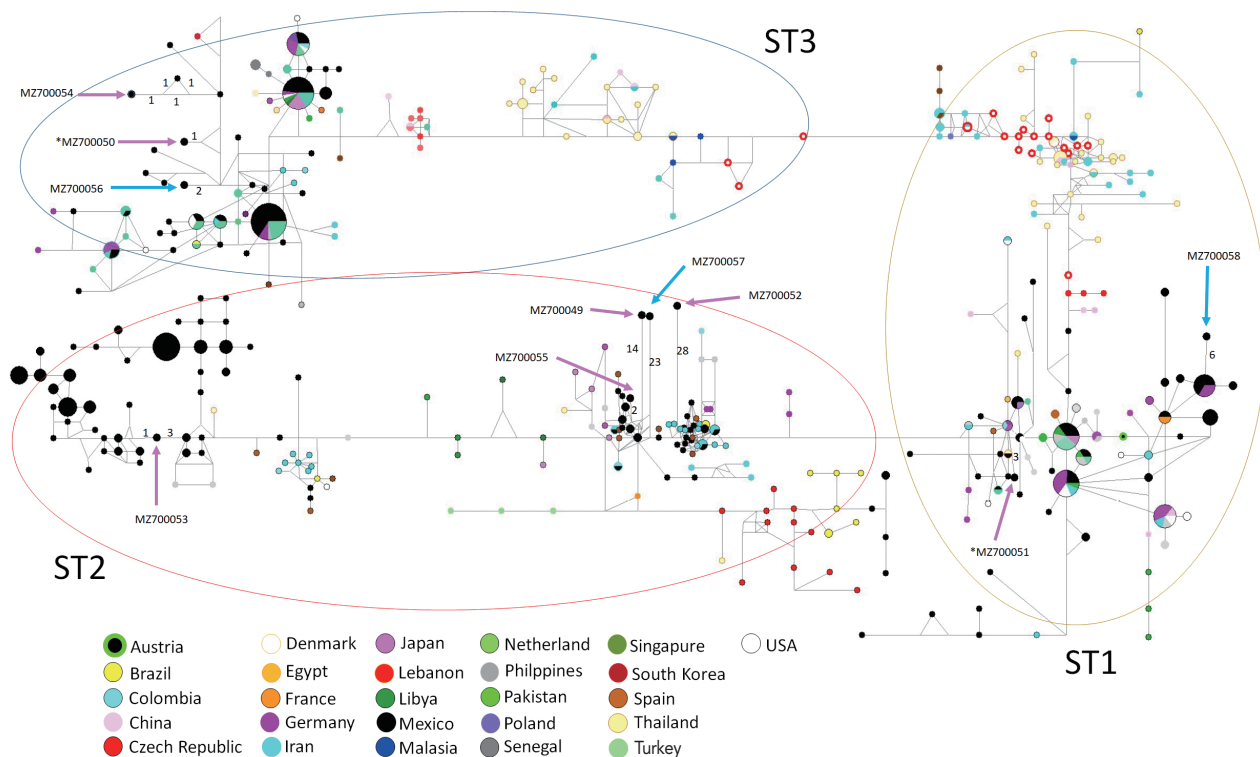


Fig. 2. Haplotype networks for *Blastocystis* ST1-3 using 18S rRNA sequences from different countries for ST1 to ST3. Numbers in branches refer to mutational changes; sizes of circles and colors are proportional to haplotype frequencies. Arrows show the haplotypes identified in the present study. Pink arrows show sequences obtained from vaginal samples, while blue arrows show those for sperm samples. *indicates the sample with mixed *Blastocystis* ST infections.

the GenBank and incorporated into the phylogenetic analysis. A Median Joining Network analysis was performed using NETWORK 4.611 with 906 sequences (Supplementary Table S1) obtained from the GenBank, which showed high identity with the samples obtained in the present study according to the BLAST search, haplotype networks were established by default settings and assumptions.

Descriptive statistics are expressed as mean and standard deviation (SD). Analysis by Mantel-Haenszel test was performed to find associations. Data analysis was performed with SSPS software Version 15.0 (SPSS Institute, Chicago, Illinois, USA).

The mean female age was 34 (SD= 13.7) years and for men it was 32 (SD=2.9) years; all patients lived in Mexico City. Table 1 summarizes the main clinical and microbiological characteristics of the patients whose samples were analyzed in this study. Amplicons corresponding to *Blastocystis* STs were identified in 6 out of 28 vaginal samples (21.4%) and in 3 out of 7 sperm samples (42.8%) (Supplementary Fig. S1). In both biological samples STs 1-3 were found; interestingly, 1 vaginal sample showed a mixed infection with ST1 and ST3 (Table 2).

No statistical associations between variables were found.

The phylogenetic tree supported the grouping for found sequences inside ST1-3 clusters (Fig. 1). Similarly, the haplotype network tree grouped sequences in each ST according to other Mexican haplotypes and no specific clustering for the vaginal or sperm samples was observed. Interestingly, most haplotypes identified in the present study were placed far from the main dispersal centers, as “isolated haplotypes” due to some mutations that moved them away from their closest haplotype (Fig. 2).

To our knowledge, this is the first report of unusual *Blastocystis* ST1-3. The presence of *Blastocystis* DNA in vaginal and sperm samples is relevant, suggesting that this microorganism has great plasticity in colonizing niches, unlike to other report [7], where *Blastocystis* was only observed morphologically in a vaginal sample by Papanicolaou staining and parasite presence was not clearly identified.

Interestingly, all the samples analyzed for *Blastocystis* were *Trichomonas* positive by microscopy. The associations between infection by *T. vaginalis* and other STIs, particularly of viral in-

fections such as HIV, HSV-2, and HVP have been described [15]. These studies have shown that there is a high risk of acquiring a viral infection in the women infected with *T. vaginalis*. The susceptibility to a viral infection could be increased due to the following reasons: i) the inflammatory response to *Trichomonas* infection can promote a greater appearance of target cells; ii) *Trichomonas* can damage the mechanical barrier against the virus, and iii) change the normal vaginal microbiota making it more permissive for bacterial vaginosis [16]. The presence of *T. vaginalis* could also increase the susceptibility to *Blastocystis* infection. Future prospective cohort study is warranted to identify possible associations between the coinfection of *Trichomonas* and *Blastocystis*, in addition to seek other potential risk factors.

Previous studies assumed that the women acquired *Blastocystis* by anal-genital transmission during incorrect cleaning of the genital area or by combining anal and vaginal intercourse [6,7]. This statement is strengthened because *Enterococcus faecalis* was documented in her medical record. Since sperm samples can be infected in the same manner, *Blastocysts* are likely to be present in the male reproductive system. Among the sexually transmitted parasitic protozoa, only 5 species have been demonstrated in human seminal fluid samples, which included *Entamoeba histolytica*, *Schistosoma haematobium*, *Trichomonas vaginalis*, *Trypanosoma cruzi*, and *Toxoplasma gondii* [17]. Furthermore, the presence of *E. histolytica* in human seminal fluid was reported once in 1923 in a 28-year-old patient who had chronic amebic dysentery with a history of STIs [18]. We speculate that high-risk sexual activity related to STIs could increase susceptibility to acquire *Blastocystis*. Further elucidation by appropriate causal study design in the future awaits.

The sequences obtained here were clearly grouped into clusters ST1, ST2, and ST3, without a specific distribution according to host's symptomatology, which is similar to other molecular phylogenetic trees from symptomatic and asymptomatic *Blastocystis* carriers [13]. There was only a vaginal sample with a mixed infection with ST1 and ST3. This finding is consistent with a previous study reporting mixed infections of ST1 and other ST (approximately 10%) [19]. *Blastocystis* ST3 was found in splenic cysts [5], but our study showed that ST1 and ST2 genotypes were also found in extra-intestinal site.

An interesting distribution in the network tree was observed. Most haplotypes identified in this study is located far from the main dispersal centers and appear to "isolate haplotypes". Some mutations have driven them away from their closest haplotypes that contain great genetic diversity. It has been ar-

gued that *Blastocystis* can infect several host species and colonize new environments (generalist parasites), this capacity may be the key process for maintaining their genetic diversity and population diversification to parasitize some particular species or niches [20].

This study included several limitations. First, fecal samples were not collected from participants to microscopically identify *Blastocystis* or compare the genomes of intestinal and extra-intestinal parasites from the same host. However, it is worth reporting that *T. vaginalis*-infected sperm and vaginal samples were simultaneously infected with the *Blastocystis* ST 1-3 haplotype. Second, we speculate that it is an anal-genital transmission, either during incorrect cleaning of the genital area or during combining anal and vaginal intercourse because the same *Blastocystis* haplotypes are identified in intestinal and vaginal samples. The possibility of a colonization process of new niches by this microorganism should be tested in future studies.

ACKNOWLEDGMENTS

To patients who provided samples and authorities of the General Hospital Dr. Manuel Gea Gonzalez.

CONFLICT OF INTEREST

The authors declare no conflict of interest

REFERENCES

1. Poppruk S, Adao DEV, Rivera WL. Epidemiology and subtype distribution of *Blastocystis* in humans: a review. *Infect Genet Evol* 2021; 95: 105085. <https://doi.org/10.1016/j.meegid.2021.105085>
2. Lee MG, Rawlins SC, Didier M, De Ceulaer K. Infective arthritis due to *Blastocystis hominis*. *Ann Rheum Dis* 1990; 49: 192-193. <https://doi.org/10.1136/ard.49.3.192>
3. Hu KC, Lin CC, Wang TE, Liu CY, Chen MJ, Chang WH. Amoebic liver abscess or is it? *Gut* 2008; 57: 627. <https://doi.org/10.1136/gut.2006.119149>
4. Prodeus TV, Zeila OP, Khlebnikova TA, Pikul' DA. Extraenteric infection caused by *Blastocystis* spp. in a female patient with liver abscess. *Med Parazitol (Mosk)* 2014; 2: 6-9 (in Russian).
5. Santos HL, Sodr  FC, de Macedo HW. *Blastocystis* sp. in splenic cysts: causative agent or accidental association? A unique case report. *Parasit Vectors* 2014; 7: 207. <https://doi.org/10.1186/1756-3305-7-207>
6. Wolyńska M, Soroczan W. *Blastocystis hominis* Brumpt, 1912, (Phycomycetes) in the female genital tract. *Pol Tyg Lek* 1972; 27:

- 788-791 (in Polish).
7. Escutia-Guzman Y, Martinez-Flores WA, Martinez-Ocaña J, Martinez-Pimentel R, Benitez-Ramirez M, Martinez-Hernandez F, Arroyo-Escalante S, Romero-Valdovinos M, Orozco-Mosqueda GE, Maravilla P. An unusual case of extra-enteric *Blastocystis* in the uterine cervix. *Korean J Parasitol* 2020; 58: 571-576. <https://doi.org/10.3347/kjp.2020.58.5.571>
 8. Shiadeh MN, Niyayi M, Fallahi S, Rostami A. Human parasitic protozoan infection to infertility: a systematic review. *Parasitol Res* 2016; 115: 469-477. <https://doi.org/10.1007/s00436-015-4827-y>
 9. World Health Organization. WHO Laboratory Manual for the Examination and Processing of Human Semen. 6th ed. World Health Organization Geneva, Switzerland. 2021, pp 68-69.
 10. Lopez-Escamilla E, Sanchez-Aguillon E, Alatorre-Fernandez CP, Aguilar-Zapata D, Arroyo-Escalante S, Arellano T, Moncada-Barron D, Romero-Valdovinos M, Martinez-Hernandez F, Rodriguez-Zulueta P, Maravilla P. New *Tetratrichomonas* species in two patients with pleural empiema. *J Clin Microbiol* 2013; 51: 3143-3146. <https://doi.org/10.1128/JCM.01056-13>
 11. Santín M, Gómez-Muñoz MT, Solano-Aguilar G, Fayer R. Development of a new PCR protocol to detect and subtype *Blastocystis* spp. from humans and animals. *Parasitol Res* 2011; 109: 205-212. <https://doi.org/10.1007/s00436-010-2244-9>
 12. Yoshikawa H, Wu Z, Nagano I, Takahashi Y. Molecular comparative studies among *Blastocystis* isolates obtained from humans and animals. *J Parasitol* 2003; 89: 585-594. [https://doi.org/10.1645/0022-3395\(2003\)089\[0585:MCSABI\]2.0.CO;2](https://doi.org/10.1645/0022-3395(2003)089[0585:MCSABI]2.0.CO;2)
 13. Gonzalez-Arenas NR, Villalobos G, Vargas-Sanchez GB, Avalos-Galarza CA, Marquez-Valdelamar LM, Ramirez-Miranda ME, Olivo-Diaz A, Romero-Valdovinos M, Martinez-Hernandez F, Maravilla P. Is the genetic variability of Cathepsin B important in the pathogenesis of *Blastocystis* spp.? *Parasitol Res* 2018; 117: 3935-3943. <https://doi.org/10.1007/s00436-018-6103-4>
 14. Ronquist F, Huelsenbeck JP. MrBayes 3: Bayesian phylogenetic inference under mixed models. *Bioinformatics* 2003; 19: 1572-1574. <https://doi.org/10.1093/bioinformatics/btg180>
 15. Kissinger P. *Trichomonas vaginalis*: a review of epidemiologic, clinical and treatment issues. *BMC Infect Dis* 2015; 15: 307. <https://doi.org/10.1186/s12879-015-1055-0>
 16. Moodley P, Connolly C, Sturm AW. Interrelationships among human immunodeficiency virus type 1 infection, bacterial vaginosis, trichomoniasis, and the presence of yeasts. *J Infect Dis* 2002; 185: 69-73. <https://doi.org/10.1086/338027>
 17. Crespillo-Andujar C, Díaz-Menéndez M, Mora-Rillo M. Evidence for previously unidentified sexual transmission of protozoan parasites. *Emerg Infect Dis* 2018; 24: 602-603. <https://doi.org/10.3201/eid2403.171838>
 18. Hines LA. *Entamoeba histolytica* in seminal fluid in a case of amebic dysentery. *JAMA* 1923; 81: 274-275. <https://doi.org/10.1001/jama.1923.02650040014003>
 19. Pandey PK, Verma P, Marathe N, Shetty S, Bavdekar A, Patole MS, Stensvold CR, Shouche YS. Prevalence and subtype analysis of *Blastocystis* in healthy Indian individuals. *Infect Genet Evol* 2015; 31: 296-299. <https://doi.org/10.1016/j.meegid.2015.02.012>
 20. Villanueva-Garcia C, Gordillo-Chavez EJ, Lopez-Escamilla E, Rendón-Franco E, Muñoz-García CI, Gama L, Martínez-Flores WA, González-Rodríguez N, Romero-Valdovinos M, Díaz-López H, Galian J, Villalobos G, Maravilla P, Martínez-Hernández F. Clarifying the cryptic host specificity of *Blastocystis* spp. isolates from *Alouatta palliata* and *A. pigra* howler monkeys. *PLoS One* 2017; 12: e0169637. <https://doi.org/10.1371/journal.pone.0169637>