



# Digital Breast Tomosynthesis versus MRI as an Adjunct to Full-Field Digital Mammography for Preoperative Evaluation of Breast Cancer according to Mammographic Density

Haejung Kim<sup>1\*</sup>, So Yeon Yang<sup>1, 2\*</sup>, Joong Hyun Ahn<sup>3</sup>, Eun Young Ko<sup>1</sup>, Eun Sook Ko<sup>1</sup>,  
Boo-Kyung Han<sup>1</sup>, Ji Soo Choi<sup>1, 4</sup>

<sup>1</sup>Department of Radiology and Center for Imaging Science, Samsung Medical Center, Sungkyunkwan University School of Medicine, Seoul, Korea;

<sup>2</sup>Department of Radiology, Gangnam Severance Hospital, Yonsei University College of Medicine, Seoul, Korea; <sup>3</sup>Biomedical Statistics Center, Samsung Medical Center, Seoul, Korea; <sup>4</sup>Department of Digital Health, SAIHST, Sungkyunkwan University, Seoul, Korea

**Objective:** To compare digital breast tomosynthesis (DBT) and MRI as an adjunct to full-field digital mammography (FFDM) for the preoperative evaluation of women with breast cancer based on mammographic density.

**Materials and Methods:** This retrospective study enrolled 280 patients with breast cancer who had undergone FFDM, DBT, and MRI for preoperative local tumor staging. Three radiologists independently sought the index cancer and additional ipsilateral and contralateral breast cancers using either FFDM alone, DBT plus FFDM, or MRI plus FFDM. Diagnostic performances across the three radiologists were compared among the reading modes in all patients and subgroups with dense ( $n = 186$ ) and non-dense breasts ( $n = 94$ ) according to mammographic density.

**Results:** Of 280 patients, 46 (16.4%) had 48 additional (39 ipsilateral and nine contralateral) cancers in addition to the index cancer. For index cancers, both DBT plus FFDM and MRI plus FFDM showed sensitivities of 100% in the non-dense group. In the dense group, DBT plus FFDM showed lower sensitivity than that of MRI plus FFDM (94.6% vs. 99.6%,  $p < 0.001$ ). For additional ipsilateral cancers, DBT plus FFDM showed specificity and positive predictive value (PPV) of 100% in the non-dense group, but sensitivity and negative predictive value (NPV) were not statistically different from those of MRI plus FFDM ( $p > 0.05$ ). In the dense group, DBT plus FFDM showed higher specificity (98.2% vs. 94.1%,  $p = 0.005$ ) and PPV (83.1% vs. 65.4%;  $p = 0.036$ ) than those of MRI plus FFDM, but lower sensitivity (59.9% vs. 75.3%;  $p = 0.049$ ). For contralateral cancers, DBT plus FFDM showed higher specificity than that of MRI plus FFDM (99.0% vs. 96.7%,  $p = 0.014$ ), however, the other values did not differ (all  $p > 0.05$ ) in the dense group.

**Conclusion:** DBT plus FFDM showed an overall higher specificity than that of MRI plus FFDM regardless of breast density, perhaps without substantial loss in sensitivity and NPV in the diagnosis of additional cancers. Thus, DBT may have the potential to be used as a preoperative breast cancer staging tool.

**Keywords:** Digital breast tomosynthesis; MRI; Breast; Breast cancer; Full-field digital mammography; Breast density

## INTRODUCTION

Digital breast tomosynthesis (DBT) allows radiologists

to obtain three-dimensional views of the breast through a series of thin-slice images, thus improving the sensitivity and specificity of full-field digital mammography (FFDM)

**Received:** April 16, 2021 **Revised:** August 11, 2022 **Accepted:** August 18, 2022

\*These authors contributed equally to this work.

**Corresponding author:** Ji Soo Choi, MD, PhD, Department of Radiology and Center for Imaging Science, Samsung Medical Center, Department of Digital Health, SAIHST, Sungkyunkwan University, 25-1 Seonggyunwan-ro, Jongno-gu, Seoul 03063, Korea.

• E-mail: jisoo.choi@samsung.com

This is an Open Access article distributed under the terms of the Creative Commons Attribution Non-Commercial License (<https://creativecommons.org/licenses/by-nc/4.0>) which permits unrestricted non-commercial use, distribution, and reproduction in any medium, provided the original work is properly cited.

[1-3]. Since DBT originates from mammography, its diagnostic performance may vary depending on breast density and patient age. Prospective [3-7] and retrospective [8-12] studies have shown that the addition of DBT to FFDM improves cancer detection and recall rates for both dense and non-dense breasts, in all age groups relevant for mammography screening. However, these improvements were mainly due to improved outcomes in women with scattered fibroglandular densities and heterogeneously dense breasts but not in women with extremely dense breast tissue [10,11].

Dynamic contrast-enhanced breast MRI is more sensitive than other imaging modalities for detecting additional breast lesions that are mammographically occult in women with newly diagnosed breast cancers [13-17]. However, the detection of additional diseases has not improved disease-free survival [13]. In addition, breast MRI is more expensive and time-consuming than other imaging modalities. Consequently, preoperative MRI is recommended for local tumor staging in young women, women with dense breasts, and women with invasive lobular cancer [18,19]; however, its use in all breast cancer patients remains controversial [13].

Although DBT is actively used for screening asymptomatic women, evaluating symptomatic women, and diagnostic work-up of suspicious mammography findings [20], there are no recommendations for the local tumor staging of breast cancer. However, only a few studies have compared DBT and MRI for preoperative staging of breast cancer. A previous study that compared the diagnostic performance of DBT and MRI as an adjunct to mammography in women with known breast cancers reported lower diagnostic performance but higher positive predictive value (PPV) with DBT than with MRI [21]. However, subgroup analyses were not performed according to the breast density. In another study, MRI showed higher diagnostic performance than DBT in women with dense breasts but with a relatively small sample size [22]. Furthermore, these studies did not separately analyze the index cancer (i.e., breast cancer of primary interest) and additional breast lesions, including coexisting ipsilateral and contralateral cancers. However, because the preoperative identification of additional ipsilateral or contralateral cancers can determine treatment options, it is necessary to evaluate the diagnostic accuracy of a preoperative imaging modality for cancers additionally detected after the diagnosis of index cancers.

Therefore, the purpose of this study was to compare

DBT and MRI as an adjunct to FFDM for the preoperative evaluation of women with newly diagnosed breast cancers according to mammographic density.

## MATERIALS AND METHODS

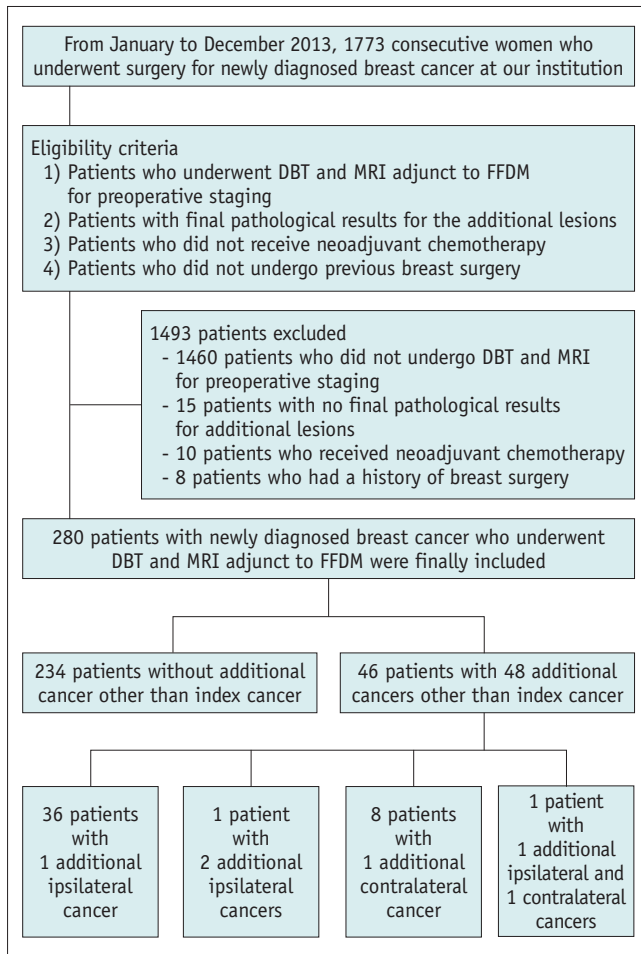
### Patient Enrollment

This retrospective study was approved by the Institutional Review Board of the Samsung Medical Center, and the requirement for written informed consent was waived (IRB No. 2018-04-147). Patients who underwent curative surgery for newly diagnosed breast cancer between January 2013 and December 2013 (n = 1773) were screened for inclusion in our study, and their electronic medical records were reviewed. The inclusion criteria were as follows: 1) patients who had undergone FFDM, DBT, and MRI for preoperative staging, 2) patients with final pathological results for additional lesions, 3) patients who did not receive neoadjuvant chemotherapy, and 4) patients with no previous breast surgery. After applying this final criterion, 280 patients (age range, 37–78 years; mean  $\pm$  standard deviation [SD], 52.5  $\pm$  8.5 years) (Fig. 1) were included in our study population. Of the 280 patients, 156 (55.7%) had symptoms (e.g., palpable mass, nipple discharge) related to malignancy, and 124 (44.3%) were asymptomatic.

### Imaging Techniques

DBT and FFDM (two-view: craniocaudal and mediolateral oblique) were performed using the same mammography unit (Selenia Dimensions, Hologic) for both breasts in each patient. DBT and FFDM images of each breast were acquired sequentially during single breast compression per view. An automated exposure control was used. The average glandular dose was automatically calculated using the imaging system.

MRI was performed using a 1.5T or 3T Philips Achieva MR system (Philips Medical Systems) with a dedicated bilateral phased-array breast coil and the patient in the prone position. MRI examination consisted of turbo spin-echo T1- and T2-weighted sequences and a three-dimensional dynamic contrast-enhanced sequence (Supplementary Methods). A 0.1-mmol/kg bolus of gadobutrol (Gadovist; Bayer Healthcare Pharmaceutical) was injected, followed by a 20 mL saline flush. Images were acquired 60, 120, 180, 240, 300, and 360 seconds after the contrast injection. After image acquisition, subtraction images (pre-contrast images subtracted from the early post-contrast images)



**Fig. 1. Flow chart of the study population.** DBT = digital breast tomosynthesis, FFDM = full-field digital mammography

were obtained automatically on a pixel-by-pixel basis. The scan duration ranged from 25 to 27 minutes. Time intervals between mammography with DBT and MRI ranged from 0 to 30 days (mean, 4.7 days).

### Reader Study

Three radiologists independently interpreted FFDM, DBT plus FFDM, and MRI plus FFDM datasets. Each radiologist reviewed the three datasets, split them into three sessions, with an interval of at least one month between each session. Each session contained cases shown in all the three imaging modes. The order of the cases for each session was random, and there were no duplicates for the same patient within each session. Before the review, any information that could identify patients, such as age, name, and imaging parameters, was concealed to minimize learning bias. Information on patient history, other imaging findings, and final histopathological diagnosis were also concealed.

Image reading sessions were performed independently using dedicated workstations (SecurView; Hologic, for DBT or FFDM and GE Centricity; GE Healthcare).

The readers were aware of the overall study goal prior to the reading sessions and that all patients had been diagnosed with breast cancer. However, they were blinded to the locations of all the breast lesions. They were asked to record all visible lesions and their size, anatomic location (left or right, clock position, and distance from nipple), and morphological type using a standardized template. When multiple lesions were observed, readers documented the size and location of each lesion in more detail to avoid lesion misallocation. For each lesion, readers assessed the Breast Imaging Reporting and Data System (BI-RADS) category (1, 2, 3, 4A, 4B, 4C, or 5) [23]. When readers detected multiple suspicious lesions assessed as BI-RADS category 4 or 5, they determined the probabilities of those lesions being multifocal, multicentric, or bilateral cancers using BI-RADS category ratings. To evaluate the agreement between the index cancer sizes measured with each reading mode and the pathologic tumor sizes, the readers measured the diameters of detected lesions in each reading mode.

### Data Collection

Electronic medical records were reviewed to collect clinical and pathological data, including patient age, symptoms, type of surgery, histological type, and tumor size at histopathologic examination. All 280 patients underwent curative surgery (mastectomy or breast-conserving surgery), sentinel lymph node biopsy, or axillary lymph node dissection.

Of the 280 patients, 76 had additional lesions detected by preoperative FFDM, DBT, or MRI, which were pathologically confirmed by imaging-guided biopsy or surgical excision (Supplementary Table 1). Among these 76 patients, three had two additional lesions other than the index cancer (two patients with one additional ipsilateral lesion and one contralateral lesion and one patient with two additional ipsilateral lesions), and 73 had only one additional lesion (56 patients with one ipsilateral additional lesion and 17 patients with one contralateral additional lesion). Thirty-nine cancers and 21 benign lesions were identified in the ipsilateral breast (separated from the index lesion by at least 2 cm), and nine cancers and 10 benign lesions were identified in the contralateral breast.

The lesions were matched between each imaging modality and pathology in consensus by two breast radiologists, who

had not participated in the reading study. They received information on the final histological diagnoses, other imaging findings, and findings reported using standardized templates in the image review. Lesions detected on other imaging modalities were considered the same when they were located within 2 cm of each other, and breast lesions were considered to be located accurately if they were not more than 2 cm from the lesion location described in the pathological reports.

Mammographic breast density was also classified as non-dense (almost entirely fatty or scattered areas of fibroglandular density) and dense (heterogeneously or extremely dense) for subgroup analyses [23].

### Statistical Analysis

Clinicopathological and imaging characteristics were compared using the chi-square test and Fisher's exact test for categorical variables and the Student's *t* test for continuous variables between mammographic density groups (non-dense vs. dense).

The diagnostic performance of the three reading modes (FFDM alone, DBT plus FFDM, and MRI plus FFDM) was calculated with respect to the identification of the index cancer (i.e., breast cancer of primary interest) and additional ipsilateral (multifocal or multicentric) and contralateral (bilateral) cancer lesions using pathology as the reference standard. For analysis, the final assessments of the readers for each reading mode were classified as cancer-positive (BI-RADS scores 4–5) and cancer-negative (BI-RADS scores 1–3). For the identification of index cancers, the sensitivity (percentage of detected index cancers per total index cancers) was compared among the three reading modes for all patients and separately for the two subgroups (non-dense and dense). For the preoperative estimation of index cancer size, agreements between index cancer sizes measured with each reading mode and histopathological examination were evaluated using intraclass correlation coefficient (ICC) analysis. Only index cancers that could be identified and measured at the three reading modes were included in this analysis. The ICC defined agreements between the three imaging modalities and histopathological reports as follows: poor, 0.00–0.20; fair, 0.21–0.40; moderate, 0.41–0.60; good, 0.61–0.80; and excellent, 0.81–1.00.

For the diagnosis of additional ipsilateral and contralateral cancers, the sensitivity, specificity, PPV, and negative predictive value (NPV) were compared among the

three reading modes for all patients and separately for the two subgroups (non-dense and dense). The sensitivity and PPV were calculated on a per-lesion basis. Specificity and NPV were calculated on a per-patient basis.

We compared the diagnostic performance of the three reading modes across the three readers using a multivariable logistic regression model, for which parameters were estimated using generalized estimating equations with exchangeable or independent structures. The regression model included reading mode as the main factor and reader as a covariate. An adjusted odds ratio > 1 indicated a higher performance with the two combination reading modes than with FFDM alone (the reference category).

Statistical significance was set at  $p < 0.05$ . Statistical analyses were performed using SAS statistical software (SAS System for Windows, version 9.1.3; SAS Institute).

## RESULTS

### Patients and Lesions

The characteristics of the participants are presented in Table 1. Of the 280 patients, 186 (66.4%) had dense breasts and 94 (33.6%) had non-dense breasts on FFDM. In total, 234 (83.6%) patients had index cancer only, and 46 patients (16.4%) had 48 additional cancers other than the index cancers. Forty-four patients had one additional cancer (36 ipsilateral and eight contralateral), one patient had two additional ipsilateral cancers, and another patient had one additional ipsilateral and one contralateral cancer (Fig. 1). DBT plus FFDM or MRI plus FFDM additionally detected 79 lesions after excluding 280 index cancers, of which 54 (31 malignant and 23 benign) were detected in the dense group and 25 (17 malignant and 8 benign) were detected in the non-dense group (Supplementary Table 1).

The mean age of the non-dense group was significantly higher than that of the dense group ( $p < 0.001$ ). Other characteristics, including symptoms, presence of additional cancer, pathologic T/N stage, surgery type, index cancer size, histologic diagnoses, and imaging findings, were not significantly different between the two subgroups (Table 1).

### Identification and Size Estimation of Index Cancers

For all patients, the readers depicted 254–262 (sensitivities, 90.7%–93.6%) of 280 index cancers with FFDM alone, 267–272 (95.4%–97.1%) with DBT plus FFDM, and 278–280 (99.3%–100.0%) with MRI plus FFDM. The pooled sensitivity of FFDM alone (91.8%) was lower than

that of other combination reading modes ( $p < 0.001$ ). The pooled sensitivity of DBT plus FFDM was lower than that of MRI plus FFDM (96.4% vs. 99.8%,  $p < 0.001$ ).

In the non-dense group, the sensitivities for identifying index cancers were similar among the three reading modes (FFDM alone, 97.9%–98.9%; DBT plus FFDM, 100%; MRI

**Table 1. Characteristics of the Study Patients**

Patient Characteristics	All Patients (n = 280)	Non-Dense Breast Group (n = 94)	Dense Breast Group (n = 186)	<i>p</i>
Age, years	52.5 ± 8.5	57.8 ± 9.0	49.8 ± 6.9	< 0.001
Symptom				0.634
No	124 (44.3)	44 (46.8)	80 (43.0)	
Yes	156 (55.7)	50 (53.2)	106 (57.0)	
Pathologic tumor size of index cancers, mm	30.7 ± 22.0	29.0 ± 19.8	31.6 ± 23.0	0.342
Pathologic diagnosis of index cancers				0.618
Invasive ductal carcinoma	227 (81.1)	80 (85.1)	147 (79.0)	
Ductal carcinoma in situ	24 (8.6)	7 (7.5)	17 (9.1)	
Invasive lobular carcinoma	14 (5.0)	3 (3.2)	11 (5.9)	
Metaplastic carcinoma	5 (1.8)	2 (2.1)	3 (1.6)	
Mucinous carcinoma	6 (2.1)	2 (2.1)	4 (2.2)	
Invasive papillary carcinoma	4 (1.4)	0 (0.0)	4 (2.2)	
Presence of additional cancer				0.661
No	234 (83.6)	78 (83.0)	156 (83.9)	
Yes*	46 (16.4)	16 (17.0)	30 (16.1)	
T stage				0.224
Tis	18 (6.4)	6 (6.4)	12 (6.5)	
T1	152 (54.3)	44 (46.8)	108 (58.1)	
T2	94 (33.6)	40 (42.6)	54 (29.0)	
T3	15 (5.3)	4 (4.3)	11 (5.9)	
T4	1 (0.4)	0 (0.0)	1 (0.5)	
N stage				0.530
N0	171 (61.1)	54 (57.4)	117 (62.9)	
N1	83 (29.6)	29 (30.9)	54 (29.0)	
N2	19 (6.8)	7 (7.4)	12 (6.5)	
N3	7 (2.5)	4 (4.3)	3 (1.6)	
Surgery type				0.999
Mastectomy	79 (28.2)	27 (28.7)	52 (28.0)	
Breast conserving surgery	201 (71.8)	67 (71.3)	134 (72.0)	
Imaging finding				0.088
DBT				
Mass	181 (64.6)	70 (74.5)	111 (59.7)	
Calcification	45 (16.1)	11 (11.7)	34 (18.3)	
Focal asymmetry	40 (14.3)	12 (12.8)	28 (15.1)	
Asymmetry	2 (0.7)	0 (0.0)	2 (1.1)	
Architectural distortion	4 (1.4)	1 (1.1)	3 (1.6)	
Not visible	8 (2.9)	0 (0.0)	8 (4.3)	
MRI				
Mass	218 (77.9)	78 (83.0)	140 (75.3)	
NME	62 (22.1)	16 (17.0)	46 (24.7)	

Data are mean ± standard deviation or number of patients or lesions with percentage in parentheses. *p* values were calculated to determine the significance of differences between the non-dense and dense breast group. \*46 patients had 48 additional cancers other than index cancers; 44 patients with one additional (ipsilateral, n = 36; contralateral, n = 8) cancer and two patients with two additional (one ipsilateral and one contralateral, n = 1; two additional ipsilateral, n = 1) cancers. DBT = digital breast tomosynthesis, NME = non-mass enhancement, Tis = refers to carcinoma in situ



plus FFDM, 100%). The pooled sensitivities of FFDM alone, DBT plus FFDM, and MRI plus FFDM were 98.7%, 100%, and 100%, respectively ( $p =$  not available). In the dense group, sensitivities of FFDM alone (87.1%–90.9%) were lower than those of the other combination reading modes (DBT plus

FFDM, 93.0%–95.7%; MRI plus FFDM, 98.9%–100%). The pooled sensitivity of FFDM alone (88.3%) was lower than that of other combination reading modes ( $p < 0.001$ ). The pooled sensitivity of DBT plus FFDM was lower than that of MRI plus FFDM alone (94.6% vs. 99.6%,  $p < 0.001$ ).

**Table 2. Diagnostic Performance of FFDM Alone, DBT Plus FFDM and MRI Plus FFDM for Additional Ipsilateral Cancers**

	FFDM Alone	DBT Plus FFDM	MRI Plus FFDM	$P^*$	$P^†$	$P^‡$
<b>For all patients</b>						
<b>Sensitivity</b>						
Pooled	45.3 (53/117; 32.1–59.1)	70.3 (82/117; 56.3–81.3)	81.4 (95/117; 70.2–89.0)	< 0.001	< 0.001	0.096
Reader 1	43.6 (17/39; 29.4–58.9)	76.9 (30/39; 61.1–87.6)	92.3 (36/39; 78.7–97.5)			
Reader 2	51.3 (20/39; 35.6–66.7)	71.8 (28/39; 55.7–83.7)	69.2 (27/39; 53.1–81.7)			
Reader 3	41.0 (16/39; 26.4–57.4)	61.5 (24/39; 45.4–75.5)	82.1 (32/39; 66.8–91.2)			
<b>Specificity</b>						
Pooled	98.3 (714/726; 96.4–99.2)	98.7 (717/726; 96.9–99.5)	94.4 (685/726; 91.3–96.4)	0.255	0.001	< 0.001
Reader 1	97.1 (235/242; 94.1–98.6)	98.3 (238/242; 95.7–99.4)	93.8 (227/242; 90.0–96.2)			
Reader 2	99.2 (240/242; 96.8–99.8)	99.6 (241/242; 97.1–99.9)	95.9 (232/242; 92.5–97.8)			
Reader 3	98.8 (239/242; 96.2–99.6)	98.3 (238/242; 95.7–99.4)	93.4 (226/242; 89.5–95.9)			
<b>PPV</b>						
Pooled	81.8 (53/65; 64.1–91.9)	90.4 (82/91; 77.2–96.3)	70.9 (95/136; 57.6–81.3)	0.009	0.146	0.003
Reader 1	70.8 (17/24; 50.2–85.4)	88.2 (30/34; 72.5–95.5)	70.6 (36/51; 56.7–81.5)			
Reader 2	90.9 (20/22; 69.9–97.7)	96.6 (28/29; 79.2–99.5)	73.0 (27/37; 56.5–84.9)			
Reader 3	84.2 (16/19; 60.6–94.9)	85.7 (24/28; 67.4–94.6)	66.7 (32/48; 52.2–78.6)			
<b>NPV</b>						
Pooled	91.4 (714/782; 87.5–94.1)	94.9 (717/756; 91.7–96.9)	96.5 (685/710; 94.0–98.0)	< 0.001	< 0.001	0.105
Reader 1	91.4 (235/257; 87.3–94.3)	96.0 (238/248; 92.7–97.8)	97.8 (227/232; 94.9–99.1)			
Reader 2	92.0 (240/261; 88.0–94.7)	95.3 (241/253; 91.8–97.3)	95.1 (232/244; 91.5–97.2)			
Reader 3	90.5 (239/264; 86.4–93.5)	93.3 (238/255; 89.5–95.8)	96.6 (226/234; 93.3–98.3)			
<b>For non-dense breast group</b>						
<b>Sensitivity</b>						
Pooled	44.4 (20/45; 30.2–59.5)	86.8 (39/45; 73.4–93.9)	91.2 (41/45; 78.4–96.7)	< 0.001	< 0.001	0.508
<b>Specificity</b>						
Pooled	98.9 (237/240; 96.9–99.6)	100 (240/240; 100–100)	95.9 (229/240; 89.1–98.5)	< 0.001	0.047	< 0.001
<b>PPV</b>						
Pooled	88.1 (20/23; 68.7–96.1)	100 (39/39; 100–100)	81.1 (41/52; 56.2–93.2)	< 0.001	0.407	< 0.001
<b>NPV</b>						
Pooled	90.9 (237/261; 83.4–95.2)	97.6 (240/246; 92.1–99.3)	98.7 (229/232; 96.1–99.6)	0.006	< 0.001	0.301
<b>For dense breast group</b>						
<b>Sensitivity</b>						
Pooled	45.8 (33/72; 28.8–63.8)	59.9 (43/72; 42.4–75.2)	75.3 (54/72; 59.8–86.2)	0.095	< 0.001	0.049
<b>Specificity</b>						
Pooled	98.2 (477/486; 95.2–99.4)	98.2 (477/486; 95.2–99.3)	94.1 (456/486; 90.3–96.4)	0.999	0.010	0.005
<b>PPV</b>						
Pooled	79.0 (33/42; 54.0–92.3)	83.1 (43/52; 62.7–93.5)	65.4 (54/84; 48.7–79.0)	0.288	0.186	0.036
<b>NPV</b>						
Pooled	91.6 (477/521; 86.7–94.8)	93.6 (477/510; 89.2–96.3)	95.4 (456/478; 91.8–97.5)	0.007	0.006	0.173

Data are percentages (raw number; 95% confidence interval). Sensitivity and PPV were calculated on a per-lesion basis. Specificity and NPV were calculated on a per-patient basis. Supplementary results are present in Supplementary Table 2. \*Between FFDM alone and DBT plus FFDM, †Between FFDM alone and MRI plus FFDM, ‡Between DBT plus FFDM and MRI plus FFDM. DBT = digital breast tomosynthesis, FFDM = full-field digital mammography, NPV = negative predictive value, PPV = positive predictive value

DBT versus MRI for Preoperative Evaluation of Breast Cancer

The ICC for agreement between the sizes of index cancers measured with each reading mode and histopathologic examination was 0.63 (95% confidence interval [CI], 0.63–0.64) for FFDM alone, 0.63 (95% CI, 0.63–0.64) for DBT plus FFDM, and 0.70 (95% CI, 0.70–0.71) for MRI plus FFDM, showing good agreement.

**Diagnostic Performance for Additional Ipsilateral Cancers**

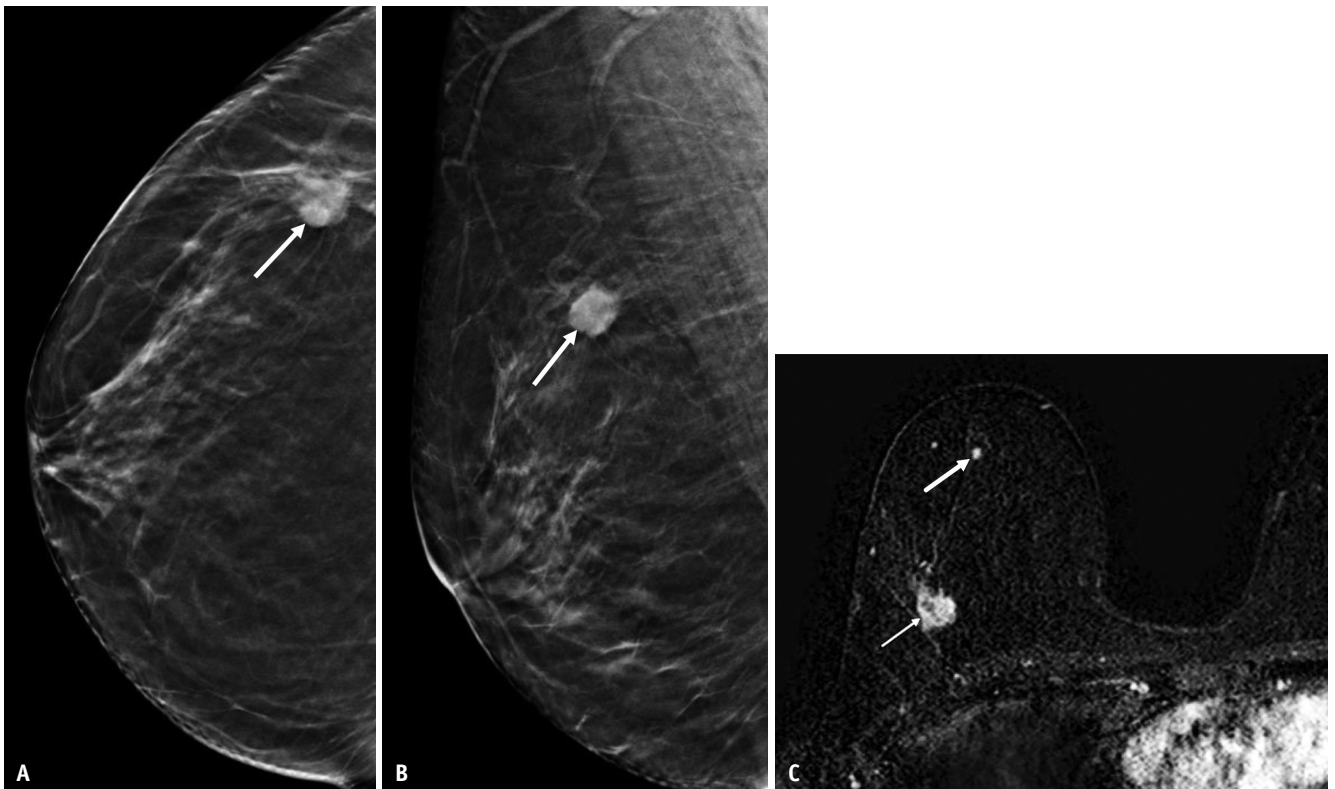The diagnostic performances for additional ipsilateral cancers with FFDM alone, DBT plus FFDM, and MRI plus FFDM are described in Table 2. In all patients, the specificity and PPV were higher with DBT plus FFDM than with MRI plus FFDM (pooled specificity of 98.7% vs. 94.4%, respectively [ $p < 0.001$ ]; pooled PPV of 90.4% vs. 70.9%, respectively [ $p = 0.003$ ]). Sensitivity and NPV with DBT plus FFDM tended to be lower than those with MRI plus FFDM, but the differences were not statistically significant (Supplementary Table 2).

In the non-dense group, DBT plus FFDM showed specificity and PPV of 100% for diagnosing additional ipsilateral cancers (Fig. 2). The sensitivity and NPV did not differ significantly between DBT plus FFDM and MRI plus FFDM. FFDM alone showed lower sensitivity and NPV than that of the combination reading modes (all  $p < 0.05$ ).

In the dense group, DBT plus FFDM showed a higher specificity (98.2% vs. 94.1%,  $p = 0.005$ ) and PPV (83.1% vs. 65.4%;  $p = 0.036$ ) than MRI plus FFDM (Fig. 3). The sensitivity was lower with DBT plus FFDM than with MRI plus FFDM (59.9% vs. 75.3%;  $p = 0.049$ ), but the NPV was not statistically different. FFDM alone showed a lower sensitivity and NPV than MRI plus FFDM, and it showed a lower NPV than that of DBT plus FFDM (all  $p < 0.05$ ).

**Diagnostic Performance for Additional Contralateral Cancers**

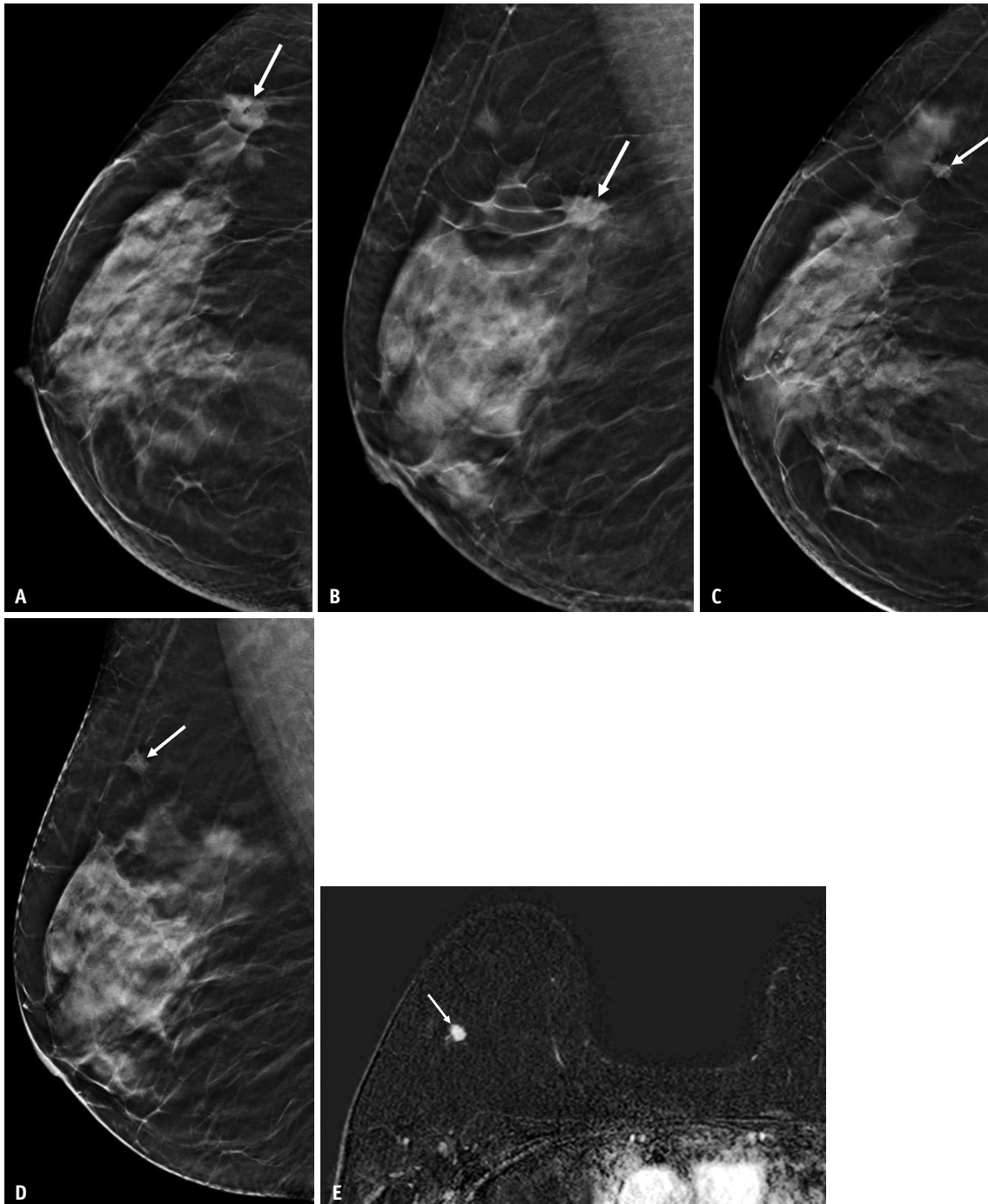
The diagnostic performances for additional contralateral



**Fig. 2. A 60-year-old woman with a 1.5 cm invasive ductal carcinoma in the right breast with almost entirely-fatty breast tissue. A, B.** Craniocaudal (A) and mediolateral oblique DBT (B) images show an irregular hyperdense mass in the right upper outer quadrant (arrows). This mass was diagnosed as invasive ductal carcinoma. All three reviewers found no additional lesion other than the index cancer with DBT plus FFDM. **C.** Axial T1-weighted contrast-enhanced subtraction MR image shows the index cancer also seen on DBT images (thin arrow). The MR image additionally demonstrates an enhancing focus showing an early rapid enhancement with washout curve, 4 cm away from the index cancer in the direction of the nipple, which was detected by two reviewers (thick arrow) with MRI plus FFDM. This additional lesion was detected in a second-look US image and confirmed as stromal fibrosis by excision biopsy after US-guided wire localization. In conclusion, MRI found a false-positive lesion other than the index cancer, leading to an unnecessary biopsy. DBT = digital breast tomosynthesis, FFDM = full-field digital mammography, US = ultrasound

cancers with FFDM alone, DBT plus FFDM, and MRI plus FFDM are described in Table 3. In all patients, DBT plus FFDM showed higher specificity (99.2% vs. 97.8%,  $p =$

0.020) and PPV (73.0% vs. 50.0%,  $p = 0.045$ ) than those of MRI plus FFDM alone. These combination modes did not show significant differences in sensitivity or NPV



**Fig. 3. A 54-year-old woman with a 1.3 cm invasive ductal carcinoma in the right breast with extremely dense breast tissue.** A, B. Craniocaudal (A) and mediolateral oblique DBT (B) images show an irregular hyperdense mass in the right upper outer quadrant (arrows). This mass was diagnosed as invasive ductal carcinoma. C, D. Craniocaudal (C) and mediolateral oblique DBT (D) images additionally demonstrate a 0.6 cm irregular isodense mass (arrows), 3 cm away from the index cancer in the periphery direction, which all three reviewers detected with DBT plus FFDM. E. Axial T1-weighted contrast-enhanced subtraction MR image shows an irregular, heterogeneous enhancing mass in the right upper outer quadrant (arrow), corresponding to the additional ipsilateral lesion detected by DBT plus FFDM. All three reviewers detected this additional lesion with MRI plus FFDM. This additional ipsilateral lesion was detected in a second-look US image and confirmed as invasive ductal carcinoma by excision after US-guided tattooing localization. DBT = digital breast tomosynthesis, FFDM = full-field digital mammography, US = ultrasound



**Table 3. Diagnostic Performance of FFDM Alone, DBT Plus FFDM and MRI Plus FFDM for Additional Contralateral Cancers**

	FFDM Alone	DBT Plus FFDM	MRI Plus FFDM	<i>P</i> <sup>*</sup>	<i>P</i> <sup>†</sup>	<i>P</i> <sup>‡</sup>
For all patients						
Sensitivity						
Pooled	51.6 (14/27; 28.7–73.8)	63.0 (17/27; 37.1–83.1)	66.9 (18/27; 37.9–87.0)	0.048	0.319	0.765
Reader 1	55.6 (5/9; 25.1–82.3)	66.7 (6/9; 33.3–88.9)	77.8 (7/9; 42.1–94.4)			
Reader 2	44.4 (4/9; 17.7–74.9)	44.4 (4/9; 17.7–74.9)	55.6 (5/9; 25.1–82.3)			
Reader 3	55.6 (5/9; 25.1–82.3)	77.8 (7/9; 42.1–94.4)	66.7 (6/9; 33.3–88.9)			
Specificity						
Pooled	99.0 (804/813; 97.6–99.6)	99.2 (806/813; 97.7–99.7)	97.8 (794/813; 95.7–98.9)	0.359	0.014	0.020
Reader 1	99.3 (269/271; 97.1–99.8)	99.3 (269/271; 97.1–99.8)	96.7 (262/271; 93.7–98.3)			
Reader 2	99.3 (269/271; 97.1–99.8)	99.6 (270/271; 97.4–99.9)	98.9 (268/271; 96.6–99.6)			
Reader 3	98.2 (266/271; 95.6–99.2)	98.5 (267/271; 96.1–99.4)	97.4 (264/271; 94.7–98.8)			
PPV						
Pooled	62.6 (14/23; 34.4–84.2)	73.0 (17/24; 40.8–91.4)	50.0 (18/37; 26.2–73.8)	0.134	0.190	0.045
Reader 1	71.4 (5/7; 32.7–92.8)	75.0 (6/8; 37.7–93.7)	43.8 (7/16; 22.5–67.6)			
Reader 2	66.7 (4/6; 26.8–91.6)	80.0 (4/5; 30.9–97.3)	62.5 (5/8; 28.5–87.5)			
Reader 3	50.0 (5/10; 22.5–77.5)	63.6 (7/11; 33.9–85.7)	46.2 (6/13; 22.4–71.8)			
NPV						
Pooled	98.4 (804/817; 96.5–99.3)	98.8 (806/816; 97.0–99.5)	98.9 (795/804; 97.0–99.6)	0.077	0.341	0.792
Reader 1	98.5 (268/273; 96.2–99.4)	98.9 (269/272; 96.6–99.6)	99.2 (262/264; 97.0–99.8)			
Reader 2	98.2 (269/274; 95.7–99.2)	98.2 (270/275; 95.7–99.2)	98.5 (269/273; 96.2–99.4)			
Reader 3	98.5 (266/270; 96.1–99.4)	99.3 (267/269; 97.1–99.8)	98.9 (264/267; 96.6–99.6)			
Dense breast group <sup>§</sup>						
Sensitivity						
Pooled	52.4 (11/21; 25.0–78.5)	57.3 (12/21; 28.8–81.7)	62.2 (13/21; 29.8–86.4)	0.291	0.594	0.764
Specificity						
Pooled	98.7 (530/537; 96.8–99.6)	99.0 (531/537; 96.5–99.7)	96.7 (518/537; 93.5–98.3)	0.589	0.002	0.014
PPV						
Pooled	62.5 (11/18; 29.7–86.8)	68.3 (12/18; 31.5–91.0)	41.7 (13/32; 18.9–68.8)	0.411	0.064	0.053
NPV						
Pooled	98.2 (530/540; 95.3–99.3)	98.4 (531/540; 95.6–99.4)	98.5 (519/527; 95.5–99.5)	0.293	0.633	0.810

Data are percentages (raw number; 95% confidence interval). Sensitivity and PPV were calculated on a per-lesion basis. Specificity and NPV were calculated on a per-patient basis. Supplementary results are present in Supplementary Table 3. \*Between FFDM alone and DBT plus FFDM, †Between FFDM alone and MRI plus FFDM, ‡Between DBT plus FFDM and MRI plus FFDM, §In the non-dense breast group, there were only two contralateral cancers, so a statistical comparison could not be performed. DBT = digital breast tomosynthesis, FFDM = full-field digital mammography, NPV = negative predictive value, PPV = positive predictive value

(Supplementary Table 3) (Fig. 4). In the dense group, DBT plus FFDM showed higher specificity (99.0% vs. 96.7%, *p* = 0.014) than MRI plus FFDM, but the other values were not different (all *p* > 0.05).

## DISCUSSION

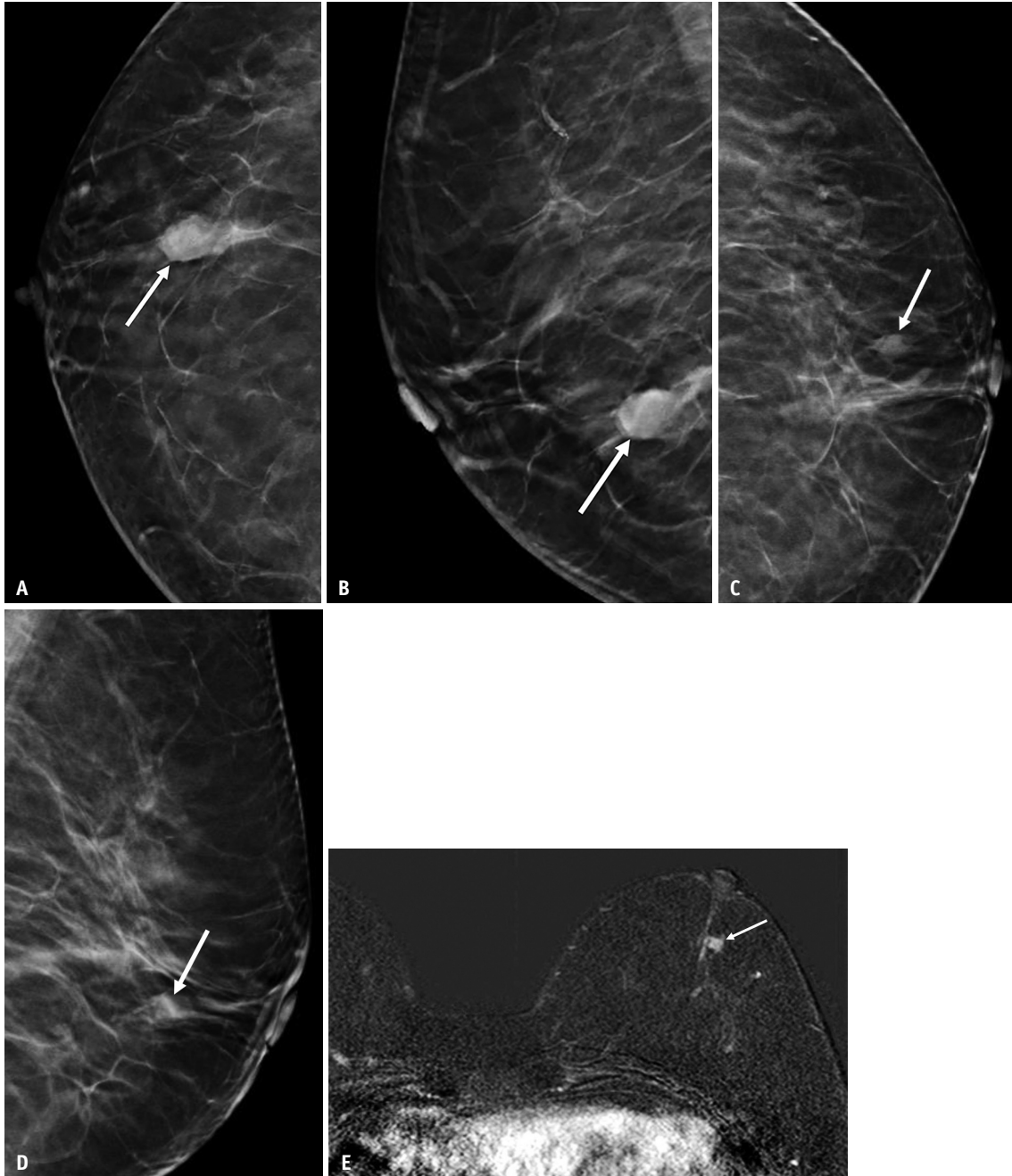
In the preoperative diagnosis of additional ipsilateral cancers, the specificity and PPV were higher with DBT plus FFDM than with MRI plus FFDM among all patients. The sensitivity and NPV of DBT plus FFDM tended to be lower than those of MRI plus FFDM; however, the differences were not statistically significant. For additional contralateral

cancers, the specificity and PPV were higher with DBT plus FFDM than with MRI plus FFDM in all patients, whereas the sensitivity and NPV were not statistically different. For the diagnosis of additional cancers, MRI plus FFDM showed significantly higher false-positive rates than DBT plus FFDM (Supplementary Table 4). These findings indicate that MRI plus FFDM may not be superior to DBT plus FFDM in the diagnosis of cancers other than index cancers.

When patients were divided according to mammographic density, the added value of DBT to FFDM tended to be more pronounced in the non-dense group than in the dense group for additional ipsilateral cancers. The added value of DBT to FFDM in terms of specificity and PPV was maximized

in the non-dense group (specificity and PPV both 100%) without loss of sensitivity and NPV. In the dense group, DBT plus FFDM showed higher specificity (98.2% vs. 94.1%,  $p = 0.005$ ) and PPV (83.1% vs. 65.4%,  $p = 0.036$ ) than

those of MRI plus FFDM, as seen in the non-dense group. Although the sensitivity of DBT plus FFDM was lower than that of MRI plus FFDM at the borderline significance level (59.9% vs. 75.3%;  $p = 0.049$ ), the NPV was not statistically



**Fig. 4.** A 76-year-old woman with a 1.5 cm invasive ductal carcinoma in the right breast with scattered fibroglandular breast tissue.

**A, B.** Craniocaudal (A) and mediolateral oblique DBT (B) images show an irregular hyperdense mass in the right lower outer quadrant (arrows). This mass was diagnosed as invasive ductal carcinoma. **C, D.** Craniocaudal (C) and mediolateral oblique DBT (D) images show a 1 cm additional irregular isodense mass in the left subareolar area (arrows), which all three reviewers detected this additional lesion with DBT plus FFDM. **E.** Axial T1-weighted contrast-enhanced subtraction MR image shows an irregular heterogeneous enhancing mass in the left subareolar area (arrow), corresponding to the additional lesion detected by DBT plus FFDM. All three reviewers detected this additional lesion with MRI plus FFDM. This additional contralateral lesion was detected in a second-look US image and confirmed as ductal carcinoma in situ by US-guided core needle biopsy and subsequent surgery. DBT = digital breast tomosynthesis, FFDM = full-field digital mammography, US = ultrasound

different. For additional contralateral cancers, these combination modes could not be compared in the non-dense group because only two cases of contralateral cancer were included in this group. However, in the dense group, DBT plus FFDM showed a higher specificity than that of MRI plus FFDM, but the other values did not differ.

For the identification of index cancers, the sensitivities of DBT plus FFDM were lower than those of MRI plus FFDM in both the overall and dense groups. However, the sensitivities of DBT plus FFDM and MRI plus FFDM were 100% in the non-dense group. For agreements between index cancer sizes measured with each reading mode and histopathologic examinations, both DBT plus FFDM and MRI plus FFDM showed good agreement between the measured tumor size and pathologic tumor size. However, the correlation coefficient between DBT plus FFDM and histopathology (0.63) in this study was lower than the range of coefficient values reported for DBT (0.73–0.86) in previous studies [22,24,25] and that for MRI plus FFDM (0.70).

In this study, DBT plus FFDM showed a better diagnostic performance in the non-dense group than in the dense group. Similar results were observed in a recent study that found the combination of DBT and FFDM to improve diagnostic accuracy when detecting additional cancer in women with non-dense breasts and known breast cancer [26]. Mariscotti et al. [27] reported that adding MRI did not improve the accuracy of preoperative disease extent evaluation in women who underwent DBT in addition to conventional imaging. Moreover, a few studies have shown that the benefit of preoperative MRI is diminished in women with non-dense breasts who have undergone DBT [28,29]. Therefore, in women who have been diagnosed with breast cancer by screening DBT, especially if they have mammographically non-dense breasts, additional MRI for preoperative staging may not be required. For these patients, screening and diagnosis can be done at the same time with DBT, saving patients both time and money. In addition, based on our results, we believe that DBT can be proposed as an imaging method for preoperative local tumor staging in breast cancer patients for whom MRI is contraindicated (e.g., MR-unsafe implanted devices, allergic reaction to contrast agents, and claustrophobia) [30]. However, our study had a retrospective design and did not include many women with non-dense breasts. Therefore, future studies with a larger number of breast cancer patients are needed to validate the role of DBT in preoperative local

tumor staging.

The benefits of using preoperative MRI to assess the tumor extent are particularly strong in invasive lobular carcinomas [13,19,31,32]. In contrast, low-grade or small-sized ductal carcinoma in situ (DCIS) lesions may be occult on MRI [13]. Therefore, the performance of DBT and MRI as preoperative staging tools may differ based on the pathological diagnosis of the index cancer. In this study, the index cancer in most patients (81.1%) was invasive ductal carcinoma. However, the number of index cancers diagnosed as invasive lobular carcinoma ( $n = 14$ ) or DCIS ( $n = 24$ ) was too small for a viable comparison of DBT and MRI in this subgroup. Therefore, in the future, we need to determine whether DBT and MRI are equivalent preoperative staging methods in patients with breast cancer diagnosed with invasive lobular carcinoma or DCIS.

Our study had several limitations. First, all patients with breast cancer were enrolled. As readers were aware of the inclusion criteria, they knew that breast cancer was likely to be observed prior to image interpretation. This may have introduced a bias that resulted in overestimated sensitivity when diagnosing the index cancers. However, if DBT is incorporated into clinical practice for preoperative local tumor staging, radiologists will likely have knowledge of the biopsy-confirmed breast cancers. Therefore, this study design reflects the realities of clinical practice, and we believe that our results are still meaningful. Second, since the number of patients with bilateral cancers was relatively small, the diagnostic performance of each preoperative imaging method for additional contralateral cancers in this study has limited value. Rather, the measured diagnostic values should be regarded as an indication of the potential of each combination of reading modes. Finally, this was a single-center retrospective study, which may have limited its internal and external validity.

In conclusion, DBT added to FFDM showed an overall higher specificity than MRI plus FFDM regardless of breast density, perhaps without substantial loss in sensitivity and NPV, in the diagnosis of additional cancers in women with newly diagnosed breast cancers. Thus, DBT may have the potential to be used as a preoperative breast cancer staging tool.

## Supplement

The Supplement is available with this article at <https://doi.org/10.3348/kjr.2021.0967>.

### Availability of Data and Material

The datasets generated or analyzed during the study are available from the corresponding author on reasonable request.

### Conflicts of Interest

The authors have no potential conflicts of interest to disclose.

### Author Contributions

Conceptualization: Haejung Kim, So Yeon Yang, Ji Soo Choi. Data curation: Haejung Kim, So Yeon Yang, Ji Soo Choi, Eun Young Ko, Eun Sook Ko, Boo-Kyung Han. Formal analysis: Haejung Kim, So Yeon Yang, Joong Hyun Ahn, Ji Soo Choi. Investigation: Haejung Kim, So Yeon Yang, Joong Hyun Ahn, Ji Soo Choi. Methodology: Haejung Kim, So Yeon Yang, Joong Hyun Ahn, Ji Soo Choi. Project administration: Haejung Kim, So Yeon Yang, Ji Soo Choi. Resources: Haejung Kim, So Yeon Yang, Ji Soo Choi, Eun Young Ko, Eun Sook Ko, Boo-Kyung Han. Software: Haejung Kim, So Yeon Yang, Joong Hyun Ahn, Ji Soo Choi. Supervision: Ji Soo Choi. Validation: all authors. Visualization: Haejung Kim, So Yeon Yang, Ji Soo Choi. Writing—original draft: So Yeon Yang, Ji Soo Choi. Writing—review & editing: Haejung Kim, Ji Soo Choi.

### ORCID iDs

Haejung Kim

<https://orcid.org/0000-0003-4855-9711>

So Yeon Yang

<https://orcid.org/0000-0002-6044-9235>

Joong Hyun Ahn

<https://orcid.org/0000-0002-5768-5990>

Eun Young Ko

<https://orcid.org/0000-0001-6679-9650>

Eun Sook Ko

<https://orcid.org/0000-0002-0399-7956>

Boo-Kyung Han

<https://orcid.org/0000-0003-1896-0571>

Ji Soo Choi

<https://orcid.org/0000-0003-1361-5269>

### Funding Statement

None

## REFERENCES

1. Skaane P, Gullien R, Bjørndal H, Eben EB, Ekseth U, Haakenaasen U, et al. Digital breast tomosynthesis (DBT): initial experience in a clinical setting. *Acta Radiol* 2012;53:524-529
2. Roth RG, Maidment AD, Weinstein SP, Roth SO, Conant EF. Digital breast tomosynthesis: lessons learned from early clinical implementation. *Radiographics* 2014;34:E89-E102
3. Zackrisson S, Lång K, Rosso A, Johnson K, Dustler M, Förnvik D, et al. One-view breast tomosynthesis versus two-view mammography in the Malmö Breast Tomosynthesis Screening Trial (MBTST): a prospective, population-based, diagnostic accuracy study. *Lancet Oncol* 2018;19:1493-1503
4. Hovda T, Holen ÅS, Lång K, Albertsen JL, Bjørndal H, Brandal SHB, et al. Interval and consecutive round breast cancer after digital breast tomosynthesis and synthetic 2D mammography versus standard 2D digital mammography in BreastScreen Norway. *Radiology* 2020;294:256-264
5. Hofvind S, Holen ÅS, Aase HS, Houssami N, Sebuødegård S, Moger TA, et al. Two-view digital breast tomosynthesis versus digital mammography in a population-based breast cancer screening programme (To-Be): a randomised, controlled trial. *Lancet Oncol* 2019;20:795-805
6. Bernardi D, Macaskill P, Pellegrini M, Valentini M, Fantò C, Ostillo L, et al. Breast cancer screening with tomosynthesis (3D mammography) with acquired or synthetic 2D mammography compared with 2D mammography alone (STORM-2): a population-based prospective study. *Lancet Oncol* 2016;17:1105-1113
7. Ciatto S, Houssami N, Bernardi D, Caumo F, Pellegrini M, Brunelli S, et al. Integration of 3D digital mammography with tomosynthesis for population breast-cancer screening (STORM): a prospective comparison study. *Lancet Oncol* 2013;14:583-589
8. Østerås BH, Martinsen ACT, Gullien R, Skaane P. Digital mammography versus breast tomosynthesis: impact of breast density on diagnostic performance in population-based screening. *Radiology* 2019;293:60-68
9. Conant EF, Zuckerman SP, McDonald ES, Weinstein SP, Korhonen KE, Birnbaum JA, et al. Five consecutive years of screening with digital breast tomosynthesis: outcomes by screening year and round. *Radiology* 2020;295:285-293
10. Bahl M, Mercaldo S, Dang PA, McCarthy AM, Lowry KP, Lehman CD. Breast cancer screening with digital breast tomosynthesis: are initial benefits sustained? *Radiology* 2020;295:529-539
11. Rafferty EA, Durand MA, Conant EF, Copit DS, Friedewald SM, Plecha DM, et al. Breast cancer screening using tomosynthesis and digital mammography in dense and nondense breasts. *JAMA* 2016;315:1784-1786
12. Caumo F, Zorzi M, Brunelli S, Romanucci G, Rella R, Cugola L, et al. Digital breast tomosynthesis with synthesized two-dimensional images versus full-field digital mammography for population screening: outcomes from the Verona screening



- program. *Radiology* 2018;287:37-46
13. Mann RM, Cho N, Moy L. Breast MRI: state of the art. *Radiology* 2019;292:520-536
  14. Berg WA, Zhang Z, Lehrer D, Jong RA, Pisano ED, Barr RG, et al. Detection of breast cancer with addition of annual screening ultrasound or a single screening MRI to mammography in women with elevated breast cancer risk. *JAMA* 2012;307:1394-1404
  15. Berg WA, Gutierrez L, NessAiver MS, Carter WB, Bhargavan M, Lewis RS, et al. Diagnostic accuracy of mammography, clinical examination, US, and MR imaging in preoperative assessment of breast cancer. *Radiology* 2004;233:830-849
  16. Orel SG, Schnall MD. MR imaging of the breast for the detection, diagnosis, and staging of breast cancer. *Radiology* 2001;220:13-30
  17. Fischer U, Kopka L, Grabbe E. Breast carcinoma: effect of preoperative contrast-enhanced MR imaging on the therapeutic approach. *Radiology* 1999;213:881-888
  18. Sardanelli F, Boetes C, Borisch B, Decker T, Federico M, Gilbert FJ, et al. Magnetic resonance imaging of the breast: recommendations from the EUSOMA working group. *Eur J Cancer* 2010;46:1296-1316
  19. Mann RM, Kuhl CK, Kinkel K, Boetes C. Breast MRI: guidelines from the European Society of Breast Imaging. *Eur Radiol* 2008;18:1307-1318
  20. Bernardi D, Belli P, Benelli E, Brancato B, Bucchi L, Calabrese M, et al. Digital breast tomosynthesis (DBT): recommendations from the Italian college of breast radiologists (ICBR) by the Italian society of medical radiology (SIRM) and the Italian group for mammography screening (GISMa). *Radiol Med* 2017;122:723-730
  21. Kim WH, Chang JM, Moon HG, Yi A, Koo HR, Gweon HM, et al. Comparison of the diagnostic performance of digital breast tomosynthesis and magnetic resonance imaging added to digital mammography in women with known breast cancers. *Eur Radiol* 2016;26:1556-1564
  22. Förnvik D, Kataoka M, Iima M, Ohashi A, Kanao S, Toi M, et al. The role of breast tomosynthesis in a predominantly dense breast population at a tertiary breast centre: breast density assessment and diagnostic performance in comparison with MRI. *Eur Radiol* 2018;28:3194-3203
  23. D'Orsi CJ, Sickles EA, Mendelson EB, Morris EA. *ACR BI-RADS atlas: breast imaging reporting and data system*. Reston, VA: American College of Radiology, 2013
  24. Luparia A, Mariscotti G, Durando M, Ciatto S, Bosco D, Campanino PP, et al. Accuracy of tumour size assessment in the preoperative staging of breast cancer: comparison of digital mammography, tomosynthesis, ultrasound and MRI. *Radiol Med* 2013;118:1119-1136
  25. Förnvik D, Zackrisson S, Ljungberg O, Svahn T, Timberg P, Tingberg A, et al. Breast tomosynthesis: accuracy of tumor measurement compared with digital mammography and ultrasonography. *Acta Radiol* 2010;51:240-247
  26. Fontaine M, Tourasse C, Pages E, Laurent N, Laffargue G, Millet I, et al. Local tumor staging of breast cancer: digital mammography versus digital mammography plus tomosynthesis. *Radiology* 2019;291:594-603
  27. Mariscotti G, Houssami N, Durando M, Bergamasco L, Campanino PP, Ruggieri C, et al. Accuracy of mammography, digital breast tomosynthesis, ultrasound and MR imaging in preoperative assessment of breast cancer. *Anticancer Res* 2014;34:1219-1225
  28. Elmi A, Conant EF, Kozlov A, Young AJ, Long Q, Doot RK, et al. Preoperative breast MR imaging in newly diagnosed breast cancer: comparison of outcomes based on mammographic modality, breast density and breast parenchymal enhancement. *Clin Imaging* 2021;70:18-24
  29. Chudgar AV, Conant EF, Weinstein SP, Keller BM, Synnestvedt M, Yamartino P, et al. Assessment of disease extent on contrast-enhanced MRI in breast cancer detected at digital breast tomosynthesis versus digital mammography alone. *Clin Radiol* 2017;72:573-579
  30. Mann RM, Balleyguier C, Baltzer PA, Bick U, Colin C, Cornford E, et al. Breast MRI: EUSOBI recommendations for women's information. *Eur Radiol* 2015;25:3669-3678
  31. Selvi V, Nori J, Meattini I, Francolini G, Morelli N, De Benedetto D, et al. Role of magnetic resonance imaging in the preoperative staging and work-up of patients affected by invasive lobular carcinoma or invasive ductolobular carcinoma. *Biomed Res Int* 2018;2018:1569060
  32. Parvaiz MA, Yang P, Razia E, Mascarenhas M, Deacon C, Matey P, et al. Breast MRI in invasive lobular carcinoma: a useful investigation in surgical planning? *Breast J* 2016;22:143-150