



Low-Dose Three-Dimensional Rotational Angiography for Evaluating Intracranial Aneurysms: Analysis of Image Quality and Radiation Dose

Hee Jong Ki¹, Bum-soo Kim², Jun-Ki Kim¹, Jai Ho Choi¹, Yong Sam Shin¹, Yangsean Choi², Na-Young Shin², Jinhee Jang², Kook-jin Ahn²

Departments of ¹Neurosurgery and ²Radiology, College of Medicine, Seoul St. Mary's Hospital, The Catholic University of Korea, Seoul, Korea

Objective: This study aimed to evaluate the image quality and dose reduction of low-dose three-dimensional (3D) rotational angiography (RA) for evaluating intracranial aneurysms.

Materials and Methods: We retrospectively evaluated the clinical data and 3D RA datasets obtained from 146 prospectively registered patients (male:female, 46:100; median age, 58 years; range, 19–81 years). The subjective image quality of 79 examinations obtained from a conventional method and 67 examinations obtained from a low-dose (5-seconds and 0.10- μ Gy/frame) method was assessed by two neurointerventionists using a 3-point scale for four evaluation criteria. The total image quality score was then obtained as the average of the four scores. The image quality scores were compared between the two methods using a noninferiority statistical testing, with a margin of -0.2 (i.e., score of low-dose group – score of conventional group). For the evaluation of dose reduction, dose-area product (DAP) and air kerma (AK) were analyzed and compared between the two groups.

Results: The mean total image quality score \pm standard deviation of the 3D RA was 2.97 ± 0.17 by reader 1 and 2.95 ± 0.20 by reader 2 for conventional group and 2.92 ± 0.30 and 2.95 ± 0.22 , respectively, for low-dose group. The image quality of the 3D RA in the low-dose group was not inferior to that of the conventional group according to the total image quality score as well as individual scores for the four criteria in both readers. The mean DAP and AK per rotation were $5.87 \text{ Gy}\cdot\text{cm}^2$ and 0.56 Gy , respectively, in the conventional group, and $1.32 \text{ Gy}\cdot\text{cm}^2$ ($p < 0.001$) and 0.17 Gy ($p < 0.001$), respectively, in the low-dose group.

Conclusion: Low-dose 3D RA was not inferior in image quality and reduced the radiation dose by 70%–77% compared to the conventional 3D RA in evaluating intracranial aneurysms.

Keywords: Low-dose 3D rotational angiography; Image quality; Radiation dose; Intracranial aneurysm

INTRODUCTION

Cerebral angiography is considered to be the gold standard imaging method for evaluating patients with intracranial

aneurysms, and three-dimensional (3D) rotational angiography (RA) plays a pivotal role in the detection, assessment of size, location, and relationship of the neck to the parent artery of the aneurysm [1-6]. However, these complex neurovascular procedures may expose patients and operators to high doses of radiation. With increased awareness of the need to reduce the radiation dose during cerebral angiography, many techniques and strategies, including low-dose fluoroscopy, angiography, and 3D RA acquisitions, have been applied to reduce unnecessary radiation doses while maintaining adequate image quality for accurate diagnoses [7-13].

Implementation of dose-reduction strategies using low-dose cerebral angiography, in our experience, also

Received: July 17, 2020 **Revised:** September 29, 2021

Accepted: September 30, 2021

Corresponding author: Bum-soo Kim, MD, PhD, Department of Radiology, College of Medicine, Seoul St. Mary's Hospital, The Catholic University of Korea, 222 Banpo-daero, Seocho-gu, Seoul 06591, Korea.

• E-mail: bumrad@catholic.ac.kr

This is an Open Access article distributed under the terms of the Creative Commons Attribution Non-Commercial License (<https://creativecommons.org/licenses/by-nc/4.0>) which permits unrestricted non-commercial use, distribution, and reproduction in any medium, provided the original work is properly cited.

significantly reduced radiation doses in patients undergoing diagnostic angiography for intracranial aneurysms, whereas the proportion of the radiation dose by 3D RA has been paradoxically increased [14]. Although there have been reports showing the feasibility of low-dose 3D RA, little work has been done to study the image quality of low-dose 3D RA and its effectiveness in a clinical setting [11].

Since June 2016, after pilot evaluation by an *in vitro* phantom study using a 3D replica of an intracranial aneurysm, our clinic has implemented the low-dose 3D RA (from 5 seconds 0.36 μ Gy/frame to 5 seconds 0.10 μ Gy/frame) in the evaluation of patients with intracranial aneurysms [15]. The aim of this study was to compare low-dose 3D RA and conventional 3D RA in the evaluation of intracranial aneurysms, with an emphasis on image quality.

MATERIALS AND METHODS

This retrospective study was approved by the Institutional Review Board of our institution (IRB No. KC20RASI0395), and the requirement to obtain informed consent was waived. We performed a retrospective review of a prospectively collected database of 146 patients (median age, 58 years; age range, 19–81 years) between March 2016 and September 2016. We selected the patients by periodic imaging protocol, from March to May 2016 for the conventional group and from June to August 2016 for the low-dose group. The inclusion criteria were patients (age > 18 years) who were assessed with cerebral angiography for unruptured intracranial aneurysms suspected on CT angiography or MR angiography. Diagnostic procedures performed for follow-up after aneurysm clipping or coiling or with unavailable radiation-dose data were excluded. A flow diagram of the patient selection and classification is shown in Figure 1.

The angiographic system used was a biplane angiographic unit (Axiom Artis Zee; Siemens) with a flat panel detector: A and B planes (48 cm) with variable field of views including 42 cm, 32 cm, 22 cm and 16 cm. The angiography unit had three pulsed fluoroscopy modes of 10, 15, and 30 P/s, of which 15 P/s was used most frequently with variable copper filtration of up to 0.9 mm. The system had a dose-area product (DAP) meter, including verification of the air kerma (AK) and DAP displayed values against an external dosimeter during the quality assurance process at least once a year. During cerebral angiography, intermittent flushing of the catheter with heparinized saline was performed

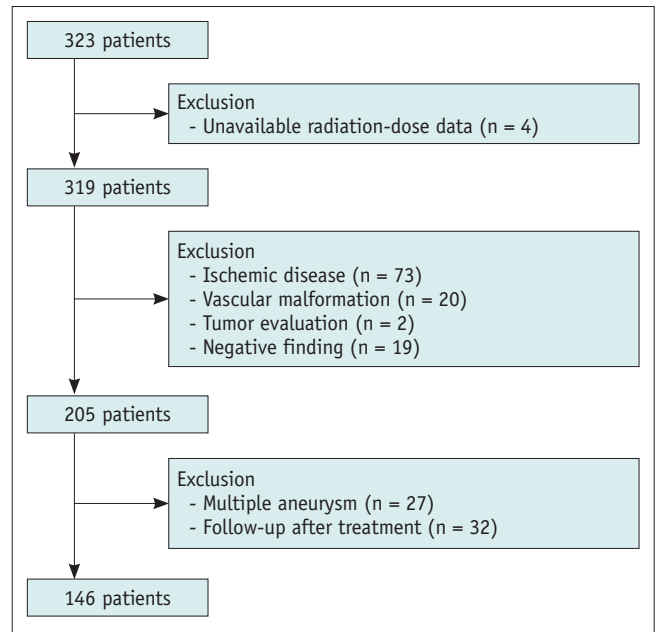


Fig. 1. Flowchart shows the study selection according to the exclusion criteria.

to protect against thromboembolic complications [16]. Angiographic procedures included acquisition of internal carotid and vertebral arteriography in anteroposterior and lateral views. When an intracranial aneurysm was suspected on 2D cerebral angiography, 3D RA was performed. The contrast medium (270 mg of iodine per milliliter of iodixanol, Visipaque 270; Amersham Health) was injected using a 5-Fr diagnostic catheter via a power injector (Angiomat Illumena; Liebel-Flarsheim). The injection rate ranged from 2.0 to 3.0 mL/s, and the delay time from injection to scanning was 1 or 1.5 seconds. The 3D RA examination was started with the contrast medium filled to the catheter tip, and injection was continued until scanning was completed. The duration of injection was 5 seconds, and the total injection volume ranged from 10 to 15 mL.

Since June 2016, our institution has applied low-dose 3D RA in clinical protocols for the evaluation of intracranial aneurysms. For the conventional 3D RA, 5-seconds dual run (named 5-seconds DSA by the manufacturer) for mask and contrast-enhanced images with a radiation dose of 0.36 μ Gy/frame was done; a low-dose 3D RA was done using a single run (named DRCARE by the manufacturer) with 0.10 μ Gy/frame. Because the existing conventional protocol in our institute was a 5-second dual run, we had to compare low-dose 3D RA with dual-run conventional 3D RA. The 3D reconstruction images of the 3D RA were collected for the analysis of image quality. The parameters of the radiation

dose for relevant 3D RA were also recorded from the database, as were DAP in Gy-cm², and AK in Gy.

Volume rendered (VR) reconstruction images of 3D RA of intracranial aneurysms were sorted in random order and evaluated by blinded, offline readings. Two experienced neurointerventionists graded image quality [11]. They reviewed all VR reconstruction images of 3D RA using four evaluation criteria (A. overall diagnosis for the aneurysm, B. assessment of relationship between the parent artery and the aneurysm to define the neck of the aneurysm, C. visualization of the perforating and branch arteries, D. degree of artifact) while blinded to the examination date to avoid knowing the dose category. They analyzed each item on a scale of 3, with a higher number indicating better image quality: 1 (no diagnostic), 2 (with some limitation, but with diagnostic quality), and 3 (no limitation for diagnosis). The total image quality score was then defined as the average of all four image quality scores (A, B, C, and D).

Statistical Analysis

We used noninferiority statistical testing to compare the image quality scores of reconstructed 3D images of aneurysms between the conventional and low-dose groups. The margin of noninferiority for image quality score was set at -0.2 (i.e., score of low-dose group – score of conventional group) [17-19]. In the absence of published data, this margin was selected because we considered a larger difference as clinically relevant. Inter-rater agreement was tested using the Cohen's kappa coefficient. The differences in radiation dose parameters (DAP and AK)

between the two groups were tested with a Student's *t* test. SPSS (IBM Corp.) was used for statistical analysis. The statistical significance criterion was two-sided at 0.05.

RESULTS

Baseline clinical characteristics of the patients are shown in Table 1. The subjective data for the clinical image quality of the two groups assessed by the two neurointerventionists are presented in Table 2. The mean total image quality score ± standard deviation of the 3D RA were 2.97 ± 0.17 by reader 1 and 2.95 ± 0.20 by reader 2 for the conventional group, and 2.92 ± 0.30 by reader 1 and 2.95 ± 0.22 by reader 2 for the low-dose group. As shown in Table 2, the lower margins of the 95% confidence intervals of the mean difference (i.e., score of low-dose group – score of conventional group) of the total and four categorical (A, B, C, D) image quality scores of the two raters were above the predefined non-inferiority margin of -0.2. Therefore, the noninferiority of low-dose 3D RA in the image quality was demonstrated in all categories. The inter-rater correlation between the two observers showed moderate to fair strength of agreement ($\kappa = 0.495$, criteria A; $\kappa = 0.495$, criteria B; $\kappa = 0.333$, criteria C; and $\kappa = 0.553$, criteria D).

The quantitative radiation dose data are presented in Table 3 and Figure 2. Before the application of the low-dose 3D RA protocol (5 seconds-DSA), mean DAP and AK per rotation were 5.87 ± 1.28 Gy-cm² and 0.56 ± 0.09 Gy, respectively. After application of the low-dose 3D RA protocol (DRCARE), mean DAP and AK per a rotation were

Table 1. Demographics and Clinical Characteristics of the Study Population

Parameter	Total (n = 146)	Conventional Group (n = 79)	Low-Dose Group (n = 67)	P
Age at diagnosis, years	58.0 (51.0–68.0)	59.0 (52.5–68.0)	57.0 (49.5–65.5)	0.474
Sex				0.142
Male	46 (31.5)	29 (36.7)	17 (25.4)	
Female	100 (68.5)	50 (63.3)	50 (74.6)	
Aneurysm location				0.638
Anterior circulation	137 (93.8)	76 (52.0)	61 (41.8)	
Anterior complex	43 (29.4)	23 (15.7)	20 (13.7)	
Middle cerebral artery	34 (23.2)	17 (11.6)	17 (11.6)	
Internal carotid artery	39 (26.7)	24 (16.4)	15 (10.3)	
Posterior communicating artery	16 (10.9)	9 (6.1)	7 (4.8)	
Anterior choroidal artery	5 (3.4)	3 (2.0)	2 (1.4)	
Posterior circulation	9 (6.1)	3 (2.0)	6 (4.1)	
Vertebral artery	5 (3.4)	2 (1.3)	3 (2.1)	
Basilar artery	3 (2.1)	1 (0.7)	2 (1.4)	
Posterior cerebral artery	1 (0.7)	0 (0.0)	1 (0.7)	

Data are median (interquartile range) for age and, otherwise, number of patients with percentage in parentheses.

Table 2. Image Quality Score of 3D Rotational Angiography by Two Separate Readers in the Conventional Group Versus the Low-Dose Group

	Reader 1			Reader 2		
	Low-Dose Group (n = 67)	Conventional Group (n = 79)	95% CI of the Mean Difference	Low-Dose Group (n = 67)	Conventional Group (n = 79)	95% CI of the Mean Difference
A*	2.98 ± 0.21	3.00 ± 0.00	-0.07 to 0.03	3.00 ± 0.00	3.00 ± 0.00	0
B†	2.96 ± 0.21	3.00 ± 0.00	-0.09 to 0.01	3.00 ± 0.00	3.00 ± 0.00	0
C‡	2.92 ± 0.33	2.96 ± 0.19	-0.13 to 0.05	2.91 ± 0.29	2.95 ± 0.22	-0.14 to 0.06
D§	2.90 ± 0.39	2.92 ± 0.27	-0.13 to 0.09	2.90 ± 0.31	2.89 ± 0.32	-0.09 to 0.11
Total	2.92 ± 0.30	2.97 ± 0.17	-0.13 to 0.03	2.95 ± 0.22	2.95 ± 0.20	-0.06 to 0.06

Data are mean ± standard deviation. The 95% CIs are for 'score of low-dose group – score of conventional group', and noninferiority was established if the lower margin is greater than -0.2. *Overall diagnosis for the aneurysm, †Assessment of relationship between the parent artery and the aneurysm, ‡Visualization of the perforating and branch arteries, §Degree of artifact, ||The average of all four categorical (A, B, C, and D) scores. CI = confidence interval, 3D = three-dimensional

Table 3. Mean and Third Quartile Results for Dose Parameters (DAP, AK) Per a Rotation before and after the Low-Dose 3D Rotational Angiography Protocol

	DAP (Gy-cm ²)	AK (Gy)
Conventional group (n = 79)		
Mean ± standard deviation	5.87 ± 1.28	0.56 ± 0.09
3rd quartile	6.66	0.62
Low-dose group (n = 67)		
Mean ± standard deviation	1.32 ± 0.47	0.17 ± 0.08
3rd quartile	1.41	0.21
p value	< 0.001	< 0.001

AK = air kerma, DAP = dose-area product, 3D = three-dimensional

1.32 ± 0.47 Gy-cm² and 0.17 ± 0.08 Gy, respectively. There was a significant difference between the mean DAP per rotation ($p < 0.001$) and mean AK per rotation ($p < 0.001$) before and after the implementation of the low-dose 3D RA protocol for diagnostic cerebral angiography.

DISCUSSION

3D RA plays a pivotal role in the evaluation of intracranial aneurysms and detection and assessment of location and size, relationship of the parent artery and the aneurysm including the neck, and perforating and branch vessels related to the aneurysm [1-6]. Our study from this early data showed that the subjective image quality of low-dose 3D RA with 5 seconds 0.10 μGy/frame was not clinically inferior to that with a 5 seconds 0.36 μGy/frame in patients at initial diagnostic evaluation of an intracranial aneurysm, in terms of overall image quality (A), relationship between the parent artery and the aneurysm to define neck of the aneurysm (B), visualization of perforating and branch arteries (C), and degree of artifact (D). As in our experience,

category C is important for the evaluation of aneurysms that have small incorporating arteries, such as anterior choroidal artery aneurysms. The reason for the relatively lower interrater agreement for category C is thought to be due to the variability in the evaluation of small blood vessels compared to larger vessels for other criteria. However, our statistical results also showed non-inferiority of the low-dose group in category C, and the examples are presented in Figure 3. Pearl et al. [11] reported the diagnostic quality and accuracy of low-dose 3D RA in the clinical evaluation of patients with intracranial aneurysms. In comparing conventional dose (0.36 μGy/frame) with three protocols of low-dose 3D RA (0.24, 0.17, and 0.10 μGy/frame) in 12 patients, intraindividual comparison with each low-dose was done in only four subjects, respectively, and their results showed that low dose 3D RA was achievable with preserved image quality. In their study, the average subjective rating of image quality was lowest with 0.10 μGy/frame; however, statistical comparison was not performed. In contrast, this study analyzed a prospectively collected database of clinical images from a larger number of patients and demonstrated the non-inferiority of low-dose 3D by specific statistical comparison.

In our study, by switching the 3D RA from the conventional dose (0.36 μGy/frame) to a low dose (0.10 μGy/frame), it was theoretically expected that a 72% decrease in radiation dose per single rotation would be incurred. This expectation was confirmed by our results: 77.4% (DAP) and 69.8% (AK) reduction in the radiation dose per rotation (Table 3). In our clinical protocol, we have changed from double-rotation 3D RA for the conventional protocol to single-rotation 3D RA for the low-dose protocol. Therefore, the reduction of patient

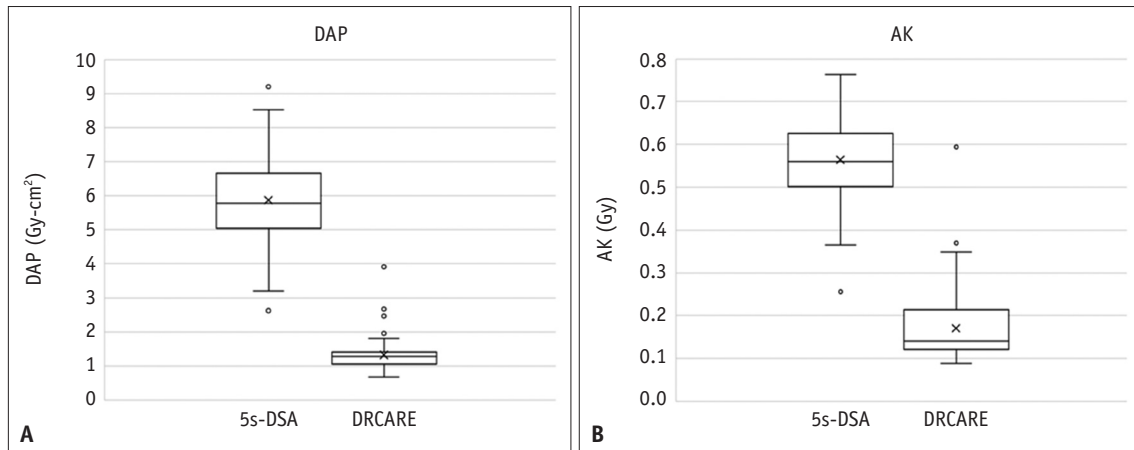


Fig. 2. Boxplots of radiation dose data per rotation for three-dimensional rotational angiography.
A. DAP in the 5 seconds-DSA group (conventional dose with 5 seconds 0.36 Gy/frame) versus the DRCARE group (low dose with 5 seconds 0.10 Gy/frame). **B.** AK in the 5 seconds-DSA group versus the DRCARE group. AK = air kerma, DAP = dose-area product

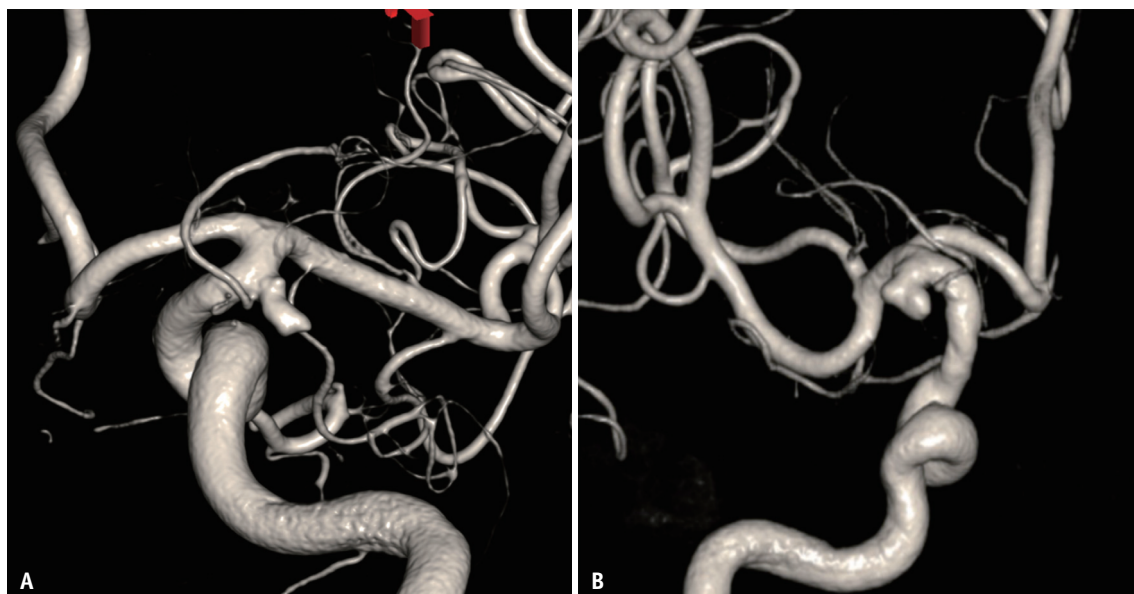


Fig. 3. Representative examples of 3D RA comparing the low-dose group with the conventional group.
A. Conventional 3D RA image in a 58-year-old male with a right anterior choroidal aneurysm. **B.** Low-dose 3D RA image in a 77-year-old female with a left anterior choroidal aneurysm. RA = rotational angiography, 3D = three-dimensional

radiation dose is going to be reduced more than our result of dose per rotation. Double rotation can show clear vasculature by subtraction and can be used for evaluation after endovascular treatment, such as clipping, coiling, or stenting [20]. On the other hand, single rotation can reduce the radiation dose by half and be efficient for the evaluation of intracranial aneurysms when the concentration of vascular contrast is maintained adequately, as in our low-dose protocol. Therefore, as a clinical protocol at present, our institute has been using low-dose 3D RA (single rotation) for initial diagnostic evaluations of intracranial aneurysms, and conventional 3D RA (with a slightly reduced

dose, 5 seconds 0.24 μ Gy/frame, double rotation) is reserved for follow-up evaluation of patients with metallic materials after aneurysm treatment. The effectiveness and benefits of our clinical protocol need to be validated in patient cohorts, and this project is ongoing.

In our previous report, the proportion of the radiation dose by 3D RA was 34.1% of the total radiation dose in patients who underwent diagnostic angiography for evaluation of an intracranial aneurysm [14,21]. As a consequence, with our cerebral angiographic protocol using low-dose 3D RA, we may expect a 20% reduction in the total patient radiation dose in patients with diagnostic

angiographic evaluation of intracranial aneurysms, and only about 10% of all patients' radiation dose is expected from RA. Validation of this assumption is ongoing by further studies with a larger patient cohort.

Although the effective skin dose is appropriate for estimating the biological effect of radiation, DAP and AK are more practical, not only for monitoring the patient radiation dose but also as a reference level [7,8,13,14,21-23]. Therefore, many authors have reported various techniques and strategies in an effort to reduce the radiation dose during cerebral angiography by comparing DAP and/or AK. Kahn et al. [24] revealed that altering factory settings on equipment allows a significant decrease in radiation exposure. Söderman et al. [7,8] reported that a real-time noise-reduction algorithm reduces the patient entrance dose without loss of image quality. Schneider et al. [9] reported that dose reduction strategies including default angiographic frame rates decreased from 4 f/s to 2 f/s, resulting in significantly lower radiation doses for diagnostic cerebral angiography. Other reports also revealed that the use of low-dose fluoroscopy parameters and appropriate examinations contributed significantly to reducing radiation doses on digital subtraction angiography [10,23,25,26]. In comparison to the above reports, some authors have concentrated on the dose reduction of 3D RA. Volume-of-interest C-arm CT provided high-quality diagnostic images of intracranial devices and their relationship to the vasculature with very low additional radiation exposure [27,28]. Recently, Lang et al. [29] introduced artificial intelligence-based 3D RA as a promising method that might help reduce patient radiation while maintaining diagnostic image quality.

There are some limitations to our study. First, this was a retrospective study. Even though the database was built prospectively, the study was retrospective and vulnerable to selection and information biases. Second, the cases analyzed were limited to aneurysms. We used only aneurysms because they are the most frequent vascular diseases and can be used as representative cases. However, limiting cases makes it difficult to generalize the results of this study.

In conclusion, the low-dose (5-seconds and 0.10- μ Gy/frame) cerebral 3D RA was not inferior in image quality and reduced the radiation dose per rotation by 70%–77% compared to the conventional 3D RA in evaluating intracranial aneurysms.

Availability of Data and Material

The datasets generated or analyzed during the study are available from the corresponding author on reasonable request.

Conflicts of Interest

Jinhee Jang who is on the editorial board of the *Korean Journal of Radiology* was not involved in the editorial evaluation or decision to publish this article. All remaining authors have declared no conflicts of interest.

Author Contributions

Conceptualization: all authors. Data curation: Hee Jong Ki, Bum-soo Kim, Jun-Ki Kim. Formal analysis: Hee Jong Ki, Bum-soo Kim. Investigation: Hee Jong Ki, Jun-Ki Kim. Methodology: Hee Jong Ki, Bum-soo Kim. Project administration: Bum-soo Kim. Resources: Jai Ho Choi, Yong Sam Shin. Supervision: Bum-soo Kim. Validation: Bum-soo Kim. Visualization: Hee Jong Ki. Writing—original draft: Hee Jong Ki. Writing—review & editing: Bum-soo Kim.

ORCID iDs

Hee Jong Ki
<https://orcid.org/0000-0003-0914-5516>
 Bum-soo Kim
<https://orcid.org/0000-0002-3870-6813>
 Jun-Ki Kim
<https://orcid.org/0000-0001-7872-0583>
 Jai Ho Choi
<https://orcid.org/0000-0001-6838-0343>
 Yong Sam Shin
<https://orcid.org/0000-0002-4250-1896>
 Yangsean Choi
<https://orcid.org/0000-0003-1674-7101>
 Na-Young Shin
<https://orcid.org/0000-0003-1157-6366>
 Jinhee Jang
<https://orcid.org/0000-0002-3386-1208>
 Kook-jin Ahn
<https://orcid.org/0000-0001-6081-7360>

Funding Statement

None

REFERENCES

1. Gauvrit JY, Leclerc X, Vermandel M, Lubicz B, Despretz D,

- Lejeune JP, et al. 3D rotational angiography: use of propeller rotation for the evaluation of intracranial aneurysms. *AJNR Am J Neuroradiol* 2005;26:163-165
2. Hochmuth A, Spetzger U, Schumacher M. Comparison of three-dimensional rotational angiography with digital subtraction angiography in the assessment of ruptured cerebral aneurysms. *AJNR Am J Neuroradiol* 2002;23:1199-1205
 3. Abe T, Hirohata M, Tanaka N, Uchiyama Y, Kojima K, Fujimoto K, et al. Clinical benefits of rotational 3D angiography in endovascular treatment of ruptured cerebral aneurysm. *AJNR Am J Neuroradiol* 2002;23:686-688
 4. Sugahara T, Korogi Y, Nakashima K, Hamatake S, Honda S, Takahashi M. Comparison of 2D and 3D digital subtraction angiography in evaluation of intracranial aneurysms. *AJNR Am J Neuroradiol* 2002;23:1545-1552
 5. van Rooij WJ, Sprengers ME, de Gast AN, Peluso JP, Sluzewski M. 3D rotational angiography: the new gold standard in the detection of additional intracranial aneurysms. *AJNR Am J Neuroradiol* 2008;29:976-979
 6. Anxionnat R, Bracard S, Ducrocq X, Troussat Y, Launay L, Kerrien E, et al. Intracranial aneurysms: clinical value of 3D digital subtraction angiography in the therapeutic decision and endovascular treatment. *Radiology* 2001;218:799-808
 7. Söderman M, Holmin S, Andersson T, Palmgren C, Babić D, Hoornaert B. Image noise reduction algorithm for digital subtraction angiography: clinical results. *Radiology* 2016;278:962
 8. Söderman M, Mauti M, Boon S, Omar A, Marteinsdóttir M, Andersson T, et al. Radiation dose in neuroangiography using image noise reduction technology: a population study based on 614 patients. *Neuroradiology* 2013;55:1365-1372
 9. Schneider T, Wyse E, Pearl MS. Analysis of radiation doses incurred during diagnostic cerebral angiography after the implementation of dose reduction strategies. *J Neurointerv Surg* 2017;9:384-388
 10. Honarmand AR, Shaibani A, Pashae T, Syed FH, Hurley MC, Sammet CL, et al. Subjective and objective evaluation of image quality in biplane cerebral digital subtraction angiography following significant acquisition dose reduction in a clinical setting. *J Neurointerv Surg* 2017;9:297-301
 11. Pearl MS, Torok C, Katz Z, Messina SA, Blasco J, Tamargo RJ, et al. Diagnostic quality and accuracy of low dose 3D-DSA protocols in the evaluation of intracranial aneurysms. *J Neurointerv Surg* 2015;7:386-390
 12. Vano E, Fernandez JM, Sanchez RM, Martinez D, Ibor LL, Gil A, et al. Patient radiation dose management in the follow-up of potential skin injuries in neuroradiology. *AJNR Am J Neuroradiol* 2013;34:277-282
 13. Ihn YK, Kim BS, Byun JS, Suh SH, Won YD, Lee DH, et al. Patient radiation exposure during diagnostic and therapeutic procedures for intracranial aneurysms: a multicenter study. *Neurointervention* 2016;11:78-85
 14. Choi J, Kim B, Choi Y, Shin NY, Jang J, Choi HS, et al. Image quality of low-dose cerebral angiography and effectiveness of clinical implementation on diagnostic and neurointerventional procedures for intracranial aneurysms. *AJNR Am J Neuroradiol* 2019;40:827-833
 15. Ki HJ, Kim BS, Kim JK, Choi JH, Shin YS, Choi Y, et al. Low-dose 3D rotational angiography in measuring the size of intracranial aneurysm: in vitro feasibility study using aneurysm phantom. *Neurointervention* 2021;16:59-63
 16. Lee HJ, Yang PS, Lee SB, Yi JS, Ryu SY, Kim TW, et al. The influence of flush methods on transfemoral catheter cerebral angiography: continuous flush versus intermittent flush. *J Vasc Interv Radiol* 2016;27:651-657
 17. Park IK, Park J, Kim TH, Lee J, Han K, Oh C, et al. Non-inferior low-dose coronary computed tomography angiography image quality with knowledge-based iterative model reconstruction for overweight patients. *PLoS One* 2018;13:e0209243
 18. Hausleiter J, Martinoff S, Hadamitzky M, Martuscelli E, Pschierer I, Feuchtner GM, et al. Image quality and radiation exposure with a low tube voltage protocol for coronary CT angiography results of the PROTECTION II Trial. *JACC Cardiovasc Imaging* 2010;3:1113-1123
 19. Ahn S, Park SH, Lee KH. How to demonstrate similarity by using noninferiority and equivalence statistical testing in radiology research. *Radiology* 2013;267:328-338
 20. Adeeb N, Griessenauer CJ, Patel AS, Moore J, Dolati-Ardejani P, Gupta R, et al. Reliability of dual- vs single-volume reconstruction of three-dimensional digital subtraction angiography for follow-up evaluation of endovascularly treated intracranial aneurysms. *Interv Neuroradiol* 2016;22:687-692
 21. Chun CW, Kim BS, Lee CH, Ihn YK, Shin YS. Patient radiation dose in diagnostic and interventional procedures for intracranial aneurysms: experience at a single center. *Korean J Radiol* 2014;15:844-849
 22. D'Ercole L, Thyron FZ, Bocchiola M, Mantovani L, Klersy C. Proposed local diagnostic reference levels in angiography and interventional neuroradiology and a preliminary analysis according to the complexity of the procedures. *Phys Med* 2012;28:61-70
 23. Kim DJ, Park MK, Jung DE, Kang JH, Kim BM. Radiation dose reduction without compromise to image quality by alterations of filtration and focal spot size in cerebral angiography. *Korean J Radiol* 2017;18:722-728
 24. Kahn EN, Gemmete JJ, Chaudhary N, Thompson BG, Chen K, Christodoulou EG, et al. Radiation dose reduction during neurointerventional procedures by modification of default settings on biplane angiography equipment. *J Neurointerv Surg* 2016;8:819-823
 25. Maeng JY, Song Y, Sung YS, Kim TI, Lee DH, Kim TH. Feasibility of ultra-low radiation dose digital subtraction angiography: preliminary study in a simplified cerebral angiography phantom. *Interv Neuroradiol* 2019;25:589-595
 26. Yi HJ, Sung JH, Lee DH, Kim SW, Lee SW. Analysis of radiation doses and dose reduction strategies during cerebral digital subtraction angiography. *World Neurosurg* 2017;100:216-223

27. Chintalapani G, Chinnadurai P, Maier A, Xia Y, Bauer S, Shaltoni H, et al. The added value of volume-of-interest C-arm CT imaging during endovascular treatment of intracranial aneurysms. *AJNR Am J Neuroradiol* 2016;37:660-666
28. Yang P, Ahmed A, Schafer S, Niemann D, Aagaard-Kienitz B, Royalty K, et al. Low-dose volume-of-interest C-arm CT imaging of intracranial stents and flow diverters. *AJNR Am J Neuroradiol* 2016;37:648-654
29. Lang S, Hoelter P, Schmidt M, Eisenhut F, Kaethner C, Kowarschik M, et al. Evaluation of an artificial intelligence-based 3D-angiography for visualization of cerebral vasculature. *Clin Neuroradiol* 2020;30:705-712