









# Treating Sudden Onset Hepatic Encephalopathy with Coil Embolization in a Patient with a Congenital Intrahepatic Portosystemic Venous Shunt: A Case Report

갑자기 간성뇌증이 발생한 선천성 간내 문맥정맥단락  
환자의 코일 색전술 치료: 증례 보고


Yeonsoo Choi, MD<sup>1</sup> , Jin Hyeok Kim, MD<sup>1\*</sup> , Ung Bae Jeon, MD<sup>1,2</sup> ,  
Joo Yeon Jang, MD<sup>1</sup> , Tae Un Kim, MD<sup>1,2</sup> , Hwaseong Ryu, MD<sup>1</sup> 

<sup>1</sup>Department of Radiology, Pusan National University Yangsan Hospital, Yangsan, Korea

<sup>2</sup>Department of Radiology, School of Medicine, Pusan National University, Yangsan, Korea


## ORCID iDs


Yeonsoo Choi  <https://orcid.org/0000-0001-5864-7454>

Jin Hyeok Kim  <https://orcid.org/0000-0001-6703-2419>

Ung Bae Jeon  <https://orcid.org/0000-0002-7731-162X>

Joo Yeon Jang  <https://orcid.org/0000-0001-7936-9924>

Tae Un Kim  <https://orcid.org/0000-0003-1017-6926>

Hwaseong Ryu  <https://orcid.org/0000-0003-3143-3733>

Intrahepatic portosystemic venous shunt (IPSVS) is a rare vascular abnormality that involves abnormal communication between the intrahepatic portal vein and systemic veins, such as the hepatic vein or inferior vena cava. Patients with IPSVS are typically asymptomatic, and IPSVS is incidentally discovered via imaging while evaluating other diseases. However, endovascular closure of the shunt should be considered in symptomatic patients with a high-flow shunt. This report presents a patient with congenital IPSVS with sudden onset hepatic encephalopathy treated using percutaneous transhepatic embolization.

**Index terms** Embolization, Therapeutic; Hepatic Encephalopathy; Portosystemic Shunt

Received February 3, 2022

Revised April 7, 2022

Accepted May 1, 2022

\*Corresponding author

Jin Hyeok Kim, MD

Department of Radiology,

Pusan National University

Yangsan Hospital,

20 Geumo-ro, Mulgeum-eup,

Yangsan 50612, Korea.

Tel 82-55-360-1840

Fax 82-55-360-1848

E-mail romario11@hananet.net

This is an Open Access article distributed under the terms of the Creative Commons Attribution Non-Commercial License (<https://creativecommons.org/licenses/by-nc/4.0>) which permits unrestricted non-commercial use, distribution, and reproduction in any medium, provided the original work is properly cited.

## INTRODUCTION

Congenital intrahepatic portosystemic venous shunt (IPSVS) is a rare condition that involves abnormal communication between the intrahepatic portal vein (PV) and systemic vein, such as the hepatic vein (HV) or inferior vena cava. It is caused by abnormal development or involution of the fetal circulation elements (1). Since IPSVS usually presents asymptotically, it is incidentally discovered via imaging during evaluation of unrelated diseases (2). Its clinical symptoms vary depending on the amount of shunt flow. When symptomatic with high-flow shunts, patients may present with hepatic encephalopathy, pulmonary hypertension, and hepatopulmonary syndrome (1, 3). We present a patient with congenital IPSVS who suddenly developed progressive hepatic encephalopathy and was treated using transhepatic coil embolization.

## CASE REPORT

An 80-year-old female patient was referred to an interventional radiologist with drowsiness and hyperammonemia for 3 days despite continuous renal replacement therapy and lactulose enema. She had a medical history of chronic kidney disease (CKD) and hypertension. She was previously hospitalized in an oriental medicine hospital for supportive care. The medications she received during her hospitalization were unclear. Laboratory results showed azotemia with a blood urea nitrogen of 60.3 mg/dL and serum creatinine of 2.75 mg/dL. The serum ammonia level was elevated at 250  $\mu\text{mol/L}$ . Electrolyte imbalance was not reported. No specific findings were observed except for diffuse brain atrophy on brain CT. Three-phase contrast-enhanced abdominal CT revealed aneurysmal communications between the HVs and PVs in segments 3 and 5 of the liver, respectively (Fig. 1A). The patient didn't have clinical features or imaging findings of liver cirrhosis (LC) and any other predisposing factors that cause hyperammonemia were not detected. Thus, the patient was diagnosed with hepatic encephalopathy due to a congenital IPSVS. These lesions had already been detected on CT, and the patient was suspected of having diverticular bleeding in the ascending colon 4 years and 6 months ago. However, the patient was asymptomatic for IPSVS at that time.

Under US guidance, the PV in liver segment 5 was punctured using a 21G Chiba needle (A&A MD, Seongnam, Korea). After change to a 0.035" guidewire, a 5-Fr sheath (Radifocus Introducer II; Terumo Corporation, Tokyo, Japan) was inserted into the PV along the wire. On direct portography and selective portography using 5-Fr catheters (Park's bright and Park's biliary; A&A MD), two tubular structures, connecting the HVs and PVs (P3-left HV and P5-accessory right inferior HV), were observed (Fig. 1B). The shunt flows were embolized with detachable coils (0.018" Concerto Detachable Coil; Medtronic, Minneapolis, MN, USA) using a 1.9-Fr microcatheter (Tellus, Asahi Intecc, Seto, Japan), followed by 0.035" pushable coils (Nester embolization coil; Cook Medical, Bloomington, IN, USA) (Fig. 1C). The transhepatic portal venous access tract was also embolized using a 0.035" coil (Nester embolization coil, Cook Medical). The serum ammonia levels decreased (250  $\rightarrow$  56  $\mu\text{mol/L}$ ) after 1 hour of embolization and normalized the next day (Fig. 1D). There was a temporary increase in the level of liver enzymes but normalized on the 5th day of the procedure. Despite the embolization of

IPSVS, the patient's mental status did not recover. She stayed in the intensive care unit due to her CKD and worsening general condition and expired 3 months after the procedure for pneumonia and multiorgan failure.

This study was approved by the Institutional Review Board of our institution (IRB No. 05-2021-218), and the requirement for informed consent was waived.

**Fig. 1.** An 80-year-old female patient with a congenital IPSVS.

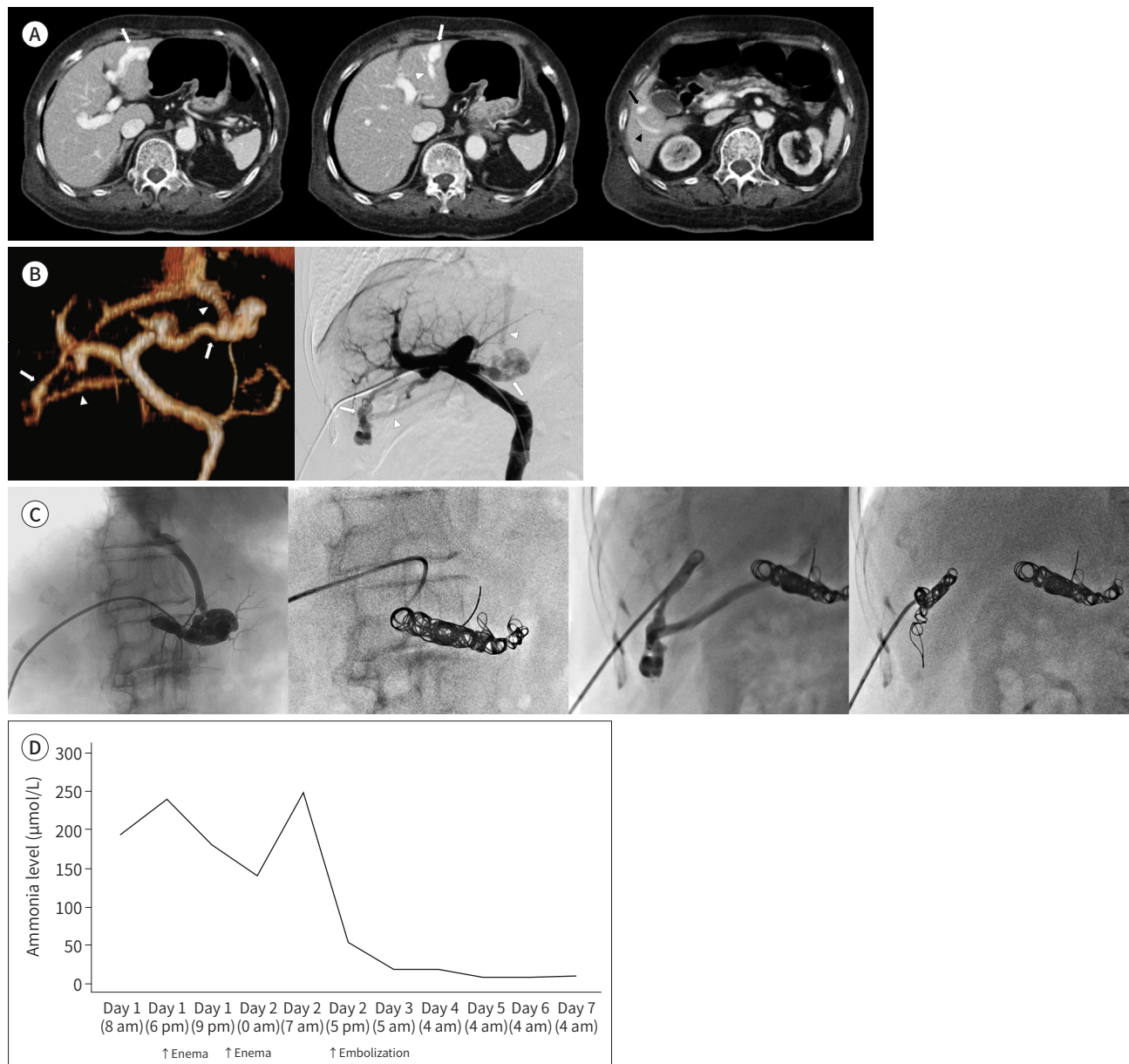
**A.** Contrast-enhanced CT images showing communication between the left PV (P3, white arrows) and left HV (white arrowhead); as well as a shunt tract between the right anterior PV (P5, black arrow) and the accessory right inferior HV (black arrowhead).

**B.** IPSVS in both hepatic lobes visualized using a 3-dimensional reconstructed CT image and a direct portography (PVs, arrows; HVs, arrowheads).

**C.** After selecting the IPSVS using a 5-Fr catheter, the shunt flows are embolized with multiple coils.

**D.** The serum ammonia levels decrease 1 hour after embolization and normalized a day later.

HV = hepatic vein, IPSVS = intrahepatic portosystemic venous shunt, PV = portal vein



## DISCUSSION

The cause of IPSVS remains controversial. It is typically due to congenital abnormalities. One theory for congenital IPSVS proposed that the persistent communication between the cranial and caudal hepatic sinusoids were formed by vitelline veins and an umbilical vein (1, 4). In acquired cases, IPSVS also results from portal hypertension due to LC, traumatic conditions, or other iatrogenic causes (2).

IPSVSs are classified into four types. The most common type is type I, which involves a single large tubular-shaped vessel, connecting the PV and inferior vena cava. Type II involves one or multiple peripheral shunts between the peripheral branches of the PV and HV in a single hepatic segment. Type III is defined as an aneurysmal connection between the peripheral PV and HV. Type IV involves multiple hepatic lobe anastomoses of the peripheral PV and HV (5). In addition, the persistent ductus venosus has been suggested as type V (6). In our case, the patient had type III IPSVSs because there were aneurysmal connections between the peripheral PV and HV in liver segments 3 and 5.

Contrast-enhanced CT imaging and US are commonly used to confirm IPSVS. Doppler US is used to determine the porto-venous shunt ratio (dividing the blood flow volume in the shunt by the total portal flow) (7). An increased shunt ratio of > 60% should be corrected to prevent hepatic encephalopathy and liver dysfunction (2, 6). Tubular or cystic structures, communicating between the portal and hepatic venous branches, have been observed in patients with IPSVS. CT imaging provides a more detailed visualization with coronal and sagittal reconstruction (2).

Asymptomatic congenital IPSVS spontaneously regresses within the first year of life. In cases in which congenital asymptomatic shunts remained undetected until adulthood, the treatment varies, depending on the patient's symptoms and shunt ratio (1). For symptomatic IPSVS or in case of the porto-venous shunt ratio is > 60%, transcatheter embolization is required (2). Several studies reported the safety and efficacy of the endovascular treatment for IPSVS and it can be performed using the transileocolic, percutaneous transhepatic, and retrograde transcaval routes (3, 4, 8). After embolization, ascites or variceal bleeding due to portal hypertension was reported as a potential complication (8, 9). However, no definite clinical and imaging findings suggestive of portal hypertension were observed during the follow-up period in this case, even though we did not checked the portal pressure after the shunt occlusion.

In asymptomatic and untreated congenital IPSVS cases, the initial symptoms may develop when the patient is over 50 years of age (1). The occurrence of hepatic encephalopathy increases with the age, probably due to decreasing tolerance of the brain to toxic metabolites (2, 8). Patients with a low shunt ratio can also develop hepatic encephalopathy when precipitating conditions occur, such as gastrointestinal bleeding or constipation, which elevate the serum ammonia levels (1). In this case, the patient had become symptomatic IPSVS with hepatic encephalopathy for unknown predisposing factors. Her CKD and hypertension likely worsened her general condition during her hospitalization at the oriental medicine hospital. A history of diverticular bleeding in the ascending colon more than 4 years ago likely to be the clue of the development of hepatic encephalopathy as well. However, gastrointestinal bleeding was not confirmed on pre-procedural CT images.

In conclusion, we reported a patient with IPSVS who suddenly developed hepatic encephalopathy and was treated with transhepatic coil embolization. IPSVS should be considered in patients who have hyperammonemia without LC. Endovascular treatment is a safe and efficient method for symptomatic patients, even in an old age with underlying diseases.

### Author Contributions

Conceptualization, all authors; data curation, K.J.H., K.T.U., R.H.; investigation, C.Y., J.U.B., J.J.Y.; project administration, C.Y., K.J.H.; resources, C.Y., K.J.H.; supervision, K.J.H.; visualization, C.Y., K.J.H.; writing—original draft, C.Y., K.J.H.; and writing—review & editing, C.Y., K.J.H., J.U.B.

### Conflicts of Interest

Ung Bae Jeon has been a Section Editor of the Journal of the Korean Society of Radiology since 2021; however, he was not involved in the peer reviewer selection, evaluation, or decision process of this article. Otherwise, no other potential conflicts of interest relevant to this article were reported.

### Funding

This study was supported by a 2022 research grant from Pusan National University Yangsan Hospital.

## REFERENCES

1. Papamichail M, Pizani M, Heaton N. Congenital portosystemic venous shunt. *Eur J Pediatr* 2018;177:285-294
2. Tsiouridis I, Sotiriadis C, Michaelides M, Dimarellos V, Tsiouridis K, Stratilati S. Intrahepatic portosystemic venous shunts: radiological evaluation. *Diagn Interv Radiol* 2009;15:182-187
3. Tanoue S, Kiyosue H, Komatsu E, Hori Y, Maeda T, Mori H. Symptomatic intrahepatic portosystemic venous shunt: embolization with an alternative approach. *AJR Am J Roentgenol* 2003;181:71-78
4. Chandrasekharan R, Pullara SK, Thomas T, Kader NP, Moorthy S. Congenital intrahepatic portosystemic shunts: imaging findings and endovascular management. *Indian J Radiol Imaging* 2016;26:92-94
5. Park JH, Cha SH, Han JK, Han MC. Intrahepatic portosystemic venous shunt. *AJR Am J Roentgenol* 1990; 155:527-528
6. Gallego C, Miralles M, Marín C, Muyor P, González G, García-Hidalgo E. Congenital hepatic shunts. *Radiographics* 2004;24:755-772
7. Caiulo VA, Presta G, Latini G, Mattioli G, Jasonni V. Diagnosis and follow-up of congenital intrahepatic portosystemic venous shunt by ultrasounds. *Acta Paediatr* 2001;90:1209-1210
8. Lee YJ, Shin BS, Lee IH, Ohm JY, Lee BS, Ahn M, et al. Intrahepatic portosystemic venous shunt: successful embolization using the Amplatzer Vascular Plug II. *Korean J Radiol* 2012;13:827-831
9. Hiraoka A, Kurose K, Hamada M, Azemoto N, Tokumoto Y, Hirooka M, et al. Hepatic encephalopathy due to intrahepatic portosystemic venous shunt successfully treated by interventional radiology. *Intern Med* 2005; 44:212-216

## 갑자기 간성뇌증이 발생한 선천성 간내 문맥정맥단락 환자의 코일 색전술 치료: 증례 보고

최연수<sup>1</sup> · 김진혁<sup>1\*</sup> · 전용배<sup>1,2</sup> · 장주연<sup>1</sup> · 김태언<sup>1,2</sup> · 류화성<sup>1</sup>

간내 문맥정맥단락은 간문맥-대정맥 또는 간문맥-간정맥이 연결되어 있는 드문 혈관 질환이다. 간내 문맥정맥단락은 주로 무증상을 보이며, 다른 질환으로 영상 검사를 하였을 때 우연히 발견될 수 있다. 하지만 단락양이 많거나 증상이 있는 경우 단락 색전술을 고려하여야 한다. 저자들은 선천성 간내 문맥정맥단락 환자에서 갑자기 간성뇌증이 발생하여 이를 경간 코일 색전술로 치료한 증례를 보고하고자 한다.

<sup>1</sup>양산부산대학교병원 영상의학과,  
<sup>2</sup>부산대학교 의과대학 영상의학교실